

## Original Research Article

# **Risk Factors and Outcomes of Complete Heart Block in Children after Surgical Closure of Ventricular Septal Defects: The Role of Pacemaker Therapy**

### **Abstract**

**Background:** Many issues might arise with surgical closure, such as postoperative pain, sternotomy scar, and postoperative arrhythmias as well as heart block. The purpose of this study was to identify the risk factors for complete heart block (CHB) among children following surgical ventricular septal defect (VSD) closure.

**Methods:** This retrospective work was performed on 126 pediatric individuals, with a history of VSD closure surgically. There were two groups of participants: Group 1 (Post-surgical CHB group): (n=42) had CHB. and Group 2 (Post-surgical non CHB group): (n=84) without CHB.

**Results:** Temporary Pacemaker was needed in 11 cases (26.19%), temporary then endocardial pacemaker occurred in 21 cases (50%), epicardial pacemaker occurred in 3 cases (7.14%), and endocardial pacemaker in 7 cases (16.67%). No complications occurred in 38 cases (90.48%), sepsis after one week occurred in 1 case (2.38%). Body weight at closure, type of VSD, mean pulmonary arterial pressure (mPAP) before surgery and procedure time were independent significant predictors for occurrence of CHB ( $P < 0.05$ ).

**Conclusions:** Low body weight at closure, large peri-membranous and inlet VSD, high mPAP before surgery were independent significant risk factors or predictors for occurrence of CHB after surgical closure of VSD. Pacemaker therapy is the only beneficial therapy of post-operative CHB.

**Keywords:** Risk factors, Complete heart block, Pacemaker therapy, Ventricular septal defects, Surgical Closure

UNDER PEER REVIEW

## **Introduction:**

The most prevalent kind of congenital heart disease (CHD), which accounts for 20% of the total CHDs, is ventricular septal defect (VSD). The majority of VSDs, about 80% of them, are of the peri-membranous subtype (pm VSD). The penetration bundle of the regular cardiac conduction axis (bundle of His) travels across the core of the heart's fibrous body at the posteroinferior boundary of the VSD, which is where peri-membranous VSDs are situated next to the membranous portion of the ventricular septum <sup>[1]</sup>.

The right atrial floor contains the Koch triangle, where the AV node is located. From there, the His bundle travels through the right fibrous trigone and emerges at the upper interventricular septum, at the non-coronary aortic cusp's base. Due to the bundle of His (and its divisions) lies inside the ventricular septum, any procedure involving the ventricular septum puts it at risk for damage due to mechanical compression or stimulation of its conduction system <sup>[2]</sup>.

Complete heart block (CHB) is the term used to describe a post-interventional heart blockage which doesn't naturally restore to the pre-intervention rhythm (often within 8 days after the intervention) <sup>[3]</sup>. One of the riskiest adverse effects of surgical VSD closure or transcatheter device closure is thought to be CHB. CHB can be early or late; early CHB is defined as CHB that occurs within 14 days after cardiac intervention, whereas late CHB occurs after 14 days of cardiac intervention up to a year. So, follow up is mandatory after VSD closure <sup>[4]</sup>.

As the conduction tissue's course in varying kinds of CHD was determined, the probability of post-operative persistent CHB has reduced <sup>[5]</sup>. The likelihood of postoperative CHB were as high as 25% in older data from 1971. This probability has been decreased to 1-4% in the modern age because to improved surgical procedures and a better knowledge of the architecture of the conduction tissue in different CHD. Another research revealed a 0.7% chance of isolated VSD closure. <sup>[6]</sup>.

Treatment of CHB may require artificial pacemaker implantation, which may be temporary or permanent that requires replacement at least once every decade. Early management of postoperative or postintervention CHB by cardiac pacing decreases morbidity, mortality and hospital stay <sup>[6]</sup>.

The design and operation of pacemakers have been improved by remarkable technologies. Children now need more pacemaker treatment as a result of surgical repairs of heart abnormalities and their long-term effects. Many of the newer, physiologic pacemakers, which are permanent and can sustain healthy heart activity, are tiny enough to be placed in infants <sup>[7]</sup>.

Transvenous implantation often takes place on the side opposite the dominant hand. Whenever transvenous implantation is not an option, like after the Fontan procedure or whenever the superior vena cava is obstructed, epicardial implantation is done by a xyphoid method <sup>[8]</sup>.

The purpose of this research was to identify potential risk factors for CHB in children after VSD closure by surgical repair.

### **Patients and Methods:**

This retrospective work was performed on 126 pediatric individuals, with a history of VSD closure surgically, aged up to 18 years old, both sexes.

After receiving clearance from Tanta University's Ethical Committee, the research was carried out. An informed authorization in writing was obtained from all patients' parents or guardians. From September 2019 till September 2022.

Exclusion criteria were patients related to other types of complicated CHD, patients with minor associated lesions like interrupted inferior vena cava or left superior vena cava were included, patients with any type of cardiomyopathy, if they had any form of permanent

pacing before VSD closure and if they had history of hepatic or renal failure or any metabolic disease that may be associated with arrhythmia.

Participants were separated into a pair of groups:

Group 1 (Post-surgical CHB group): 42 patients (20 males and 22 females) with surgical closure with complete heart block.

Group 2 (Post-surgical non CHB group): 84 patients (46 males and 38 females) with surgical closure without complete heart block.

Every individual had been exposed to: Taking of history (Personal, oobstetric, developmental histories), medical records, heart block data (Timing, duration and type of heart block), clinical examination.

### **Echocardiographic evaluation**

It was performed for all included patients for post-procedure, presence of residual VSD, left ventricular dimensions, left ventricular function, and mean pulmonary artery pressure. An echocardiogram was performed for every patient repeatedly during follow-up.

Patients in Tanta University were evaluated by GE Vivid 7 Echocardiography ultrasound machine and S7, S5, S3 MHz probes according to the patient (GE medical system, Horton, Norway). Patients in Cairo University were examined by GE Vivid 6 Echocardiography ultrasound machine and S7, S3 MHz probes (GE Healthcare, USA). We followed the American society for Echocardiography recommendations in analysing echocardiographic data for all patients<sup>[9, 10]</sup>.

All patients underwent 2-dimensional echocardiographic examination, M-mode, colour Doppler ultrasound, continuous and pulsed tissue Doppler. 2D and colour Doppler echo in parasternal short, long axis, and apical four-chamber view was used for evaluation of any

residual shunt in the interventricular septum. The device was insitu for patients whom VSD was closed by device.

We evaluated the position of the endocardial lead of the pacemaker in the right ventricular apex with exclusion of tricuspid valve injury, function assessment or presence of thrombus. Chamber diameters were evaluated and correlated to the body surface areas, to determine if there is chamber dilatation according to the guidelines <sup>[11, 12]</sup>. The Left ventricular end diastolic diameter (LVEDD) was assessed using 2D echo and M-mode in standard parasternal long-axis view in late diastole. The left ventricular systolic function was assessed through FS%, using M-mode in parasternal long axis view, while Pulsed Doppler was used to measure the E/A ratio on the mitral valve, which represents the function of the left ventricular diastole.

The pulmonary artery pressures were assessed using constant wave Doppler on the pulmonary valve and tricuspid valve to measure the tricuspid and pulmonary regurgitant jets, then the diastolic (DPAP) and systolic (SPAP) pulmonary artery pressures were measured respectively, by use of the streamlined equation developed by Bernoulli ( $4(V)^2 + RA$  pressure), the mean pulmonary artery pressure was calculated (mean PA pressure =  $1/3(SPAP) + 2/3(DPAP)$  <sup>[13]</sup>).

We considered grading of pulmonary hypertension according to ESC/ERS criteria. Mild PAH = 25-40 mmHg, Moderate PAH = 41-55 mmHg, Severe PAH: > 55 mmHg <sup>[14]</sup>. We evaluated tricuspid valve morphology and flow, using 2D echo and colour Doppler in apical 4 chamber view. Using 2 D echo in parasternal and apical views, the pericardium was evaluated especially in the early follow-up (early 2 months post closure) to exclude pericardial effusion.

**Electrocardiographic evaluation and follow-up of the patients:**

A 12-lead surface Electrocardiogram had been performed for all participants. The 12-lead surface ECGs for the patients were evaluated for rate, rhythm, intervals, and hypertrophy.

**Twenty-four-hour (24h) ambulatory Holter monitoring:** Holter was required for 7 cases with late post-operative heart block. We evaluated the patients at Cairo University by the Holter device Microvit MT-101, and MT-200 Evaluation Software (Schiller AG, Baar, Switzerland). For the patients at Tanta University, they were evaluated by the Century Holter Analysis System C3000 software (Biomedical Systems, Louis, Belegium), the Holter device, and Biomedical Systems 300 (BMS 300). Three channels Holter was done for these patients (late post-operative heart block) and they were evaluated for rhythm, minimum, maximum and average heart rate, arrhythmias (supraventricular or ventricular), and atrioventricular (AV) block (presence of second degree (Mobitz 1,2 or CHB).

#### **Pacemaker therapy**

It was done for patients with CHB <sup>[15]</sup>.

#### **Temporary pacing**

Within the initial 7–10 days after surgery, temporary epicardial pacing (TEP) may be utilized to bridge the gap between postoperative heart blockade and either spontaneous conduction restoration or permanent pacemaker implantation. Ventricular and atrial pacing wires were routinely implanted in the operating room prior to chest closure, and TEP leads were often used following the cardiac surgery. Both the ventricular and atrial wires were positioned on the right ventricle and right atrium, respectively. The right femoral vein was most often utilized for TEP; however, the subclavian vein or internal jugular vein might also be employed. Fluoroscopy was used to position the temporary wire under guidance at the right ventricular apex.

#### **Permanent pacemaker implantation**

In post VSD surgical patient, only small patient size (<6 kg) represented many patients undergoing epicardial lead systems, to avoid placing transvenous leads in kids who are younger to protect the veins for potential future usage. Transvenous leads often have to be implanted in the pectoral area since there isn't enough subcutaneous tissue there to prevent issues like skin infection and erosion. Surgical procedures such as partial or complete sternotomies, sub-rectus, and thoracotomies, generator pocket placements such as retro-costal, sub-rectus, and sub-xyphoid, and various lead fixation techniques were used. Typically at the umbilicus level, the rectus abdominus muscle sheath contains the pacemaker generator pocket that has developed in the abdominal wall.

### **Follow-up and outcomes**

Follow-up and programming of device occurred by (Medtronic, Biotronic and ST-Jude medical) programmer. **the following pacemaker checks were permitted:** <sup>[15]</sup> Single-chamber pacemakers: two pacemaker checks throughout the first six months following placement; one check following that, once per year in hearts with structurally normal architecture; every six months in hearts with CHD; or if a pacemaker fails. Dual-chamber pacemakers: two pacemaker checks throughout the first six months following placement, followed by one check every six months or if there is a pacemaker issue.

### **Statistical analysis**

SPSS v26 (IBM Inc., Chicago, IL, USA) was used for the statistical evaluation. The unpaired Student's t-test was used for comparing quantitative data across both groups. The quantitative parameters were provided as mean and standard deviation (SD). The Fisher's exact test or the Chi-square test was used to examine qualitative parameters that were reported as frequency and percentage (%). To demonstrate the risk variables for the development of CHB,

multivariate logistic regression was used. Statistical significance was defined as a two-tailed P value < 0.05.

**Results:**

Weight at time of VSD closure was substantially decreased in CHB group contrasted to non-CHB group (P value <0.001). Regard other demographic data, past and medication history for pulmonary artery banding there were no substantial variation among both groups. Procedure time, ICU duration, and ward stay were substantially greater in the group of CHB than the group of non-CHB (P value<0.05). Table 1

UNDER PEER REVIEW

**Table 1: Comparison between CHB group and non- CHB group as regards the demographic, medication, operative data**

	Post-surgical CHB group (n= 42)	Post-surgical non CHB group (n=84)	P value
<b>Demographic data</b>			
<b>Age at closure (months)</b>	17.6 ± 8.57	18.3 ± 11.71	0.455
<b>Sex</b>	<b>Male</b>	20 (47.62%)	0.445
	<b>Female</b>	22 (52.38%)	
<b>Weight at closure (Kg)</b>	8.4 ± 1.89	11 ± 2.31	<b>&lt;0.001*</b>
<b>Weight Z score</b>	-1.9 ± 0.96	-1.6 ± 1.18	0.144
<b>Height (cm)</b>	77.5 ± 7.57	80 ± 18.09	0.402
<b>Height Z score</b>	-0.8 ± 1.08	-0.5 ± 0.72	0.085
<b>BSA (m<sup>2</sup>)</b>	0.44 ± 0.10	0.47 ± 0.13	0.078
<b>Down syndrome</b>	8 (19.05%)	12 (14.29%)	0.606
<b>Medications</b>			
<b>Pulmonary banding</b>	6 (14.28%)	12 (14.29%)	0.079
<b>Lasix</b>	4 (9.52%)	11 (13.1%)	0.114
<b>Lasix &amp; Capoten</b>	7 (16.67%)	11 (13.1%)	
<b>Lasix, Capoten &amp; Aldactone</b>	6 (14.28%)	18 (21.43%)	
<b>Lasix, Capoten &amp; Lanoxin</b>	9 (21.42%)	18 (21.43%)	
<b>Lasix, Capoten, Aldactone &amp; Lanoxin</b>	16 (38.1%)	26 (30.95%)	
<b>Operative data</b>			
<b>Procedure time (h)</b>	3.6 ± 0.67	3 ± 0.72	<b>&lt;0.001*</b>
<b>ICU duration (days)</b>	8.1 ± 3.9	5.5 ± 1.9	<b>&lt;0.001*</b>
<b>Ward stay (days)</b>	8.8 ± 4.24	7 ± 2.48	<b>0.003*</b>

Data are presented as mean ± SD or frequency (%). BSA: body surface area. ICU: intensive care unit. \* Statistically significant as P value <0.05.

Regarding the echocardiographic data, size of VSD, LVEDD before and after surgery, LVEDD Z score before and after surgery, FS% before and after surgery and mPAP after surgery were insubstantially various among the two groups. mPAP before surgery was substantially greater in post-surgical CHB group when contrasted to non-CHB group (P value <0.001). Peri-membranous and inlet type VSD were substantially greater in the group of CHB than the group of non-CHB (P value < 0.05). Table 2

**Table 2: Comparison between CHB group and non-CHB group as regard the echocardiographic data.**

		Post-surgical CHB group (n= 42)	Post-surgical non CHB group (n=84)	P value
<b>Type of VSD</b>	<b>Peri-membranous</b>	22 (52.38%)	28 (33.33%)	<b>0.002*</b>
	<b>Inlet</b>	13 (30.1%)	16 (19.05%)	
	<b>Outlet</b>	7 (16.67%)	18 (21.43%)	
	<b>Muscular</b>	0 (0%)	14 (16.67%)	
	<b>Supra cristal</b>	0 (0%)	8 (9.52%)	
<b>Size of VSD (mm)</b>		8.2 ± 2.2	7.7 ± 1.75	0.127
<b>LVEDD before (mm)</b>		29.7 ± 3.35	30.8 ± 3.85	0.107
<b>LVEDD Z score before</b>		1.9 ± 1.27	1.7 ± 1.23	0.299
<b>FS% before surgery</b>		32.4 ± 5.06	32.2 ± 4.3	0.813
<b>mPAP before surgery (mmHg)</b>		30.4 ± 5.23	25.4 ± 7.36	<b>&lt;0.001*</b>
<b>LVEDD after surgery (mm)</b>		29.1 ± 4.35	30.5 ± 4.28	0.092
<b>LVEDD Z score after surgery</b>		0.3 ± 1.19	0.7 ± 1.08	0.064
<b>FS% after surgery</b>		37.5 ± 4.69	36.2 ± 5.29	0.194
<b>mPAP after surgery (mmHg)</b>		21.4 ± 5.91	20.2 ± 5.93	0.122

Data are presented as frequency (%) or mean ± SD. VSD: Ventricular septal defect, mPAP: Mean pulmonary arterial pressure, FS: Fractional shortening, LVEDD: left ventricular end-diastolic dimension, \*significant as P value <0.05.

Average HR ranged from 48 – 66 bpm with  $56.1 \pm 7.97$ , minimum HR ranged from 30-42bpm with  $31.9 \pm 6.1$ , maximum HR ranged from 89 – 105 bpm with  $95.3 \pm 6.1$ . 2 cases (28.57%) of cases suffered from complete AV block, 5 cases (71.43%) suffered from 2<sup>nd</sup> degree Mobitz type 2 (2:1) AV block with intermittent CHB. Table 3

**Table 3: Holter data in late CHB group**

		Post-surgical late CHB group (n= 7)
<b>Holter (average HR) (bpm)</b>		56.1 ± 7.97
<b>Minimum HR (bpm)</b>		31.9 ± 6.1
<b>Maximum HR (bpm)</b>		95.3 ± 6.1
<b>Type of AV block</b>	<b>Complete</b>	2 (28.57%)
	<b>2nd degree</b>	5 (71.43%)
	<b>Mobitz type 2 (2:1) with intermittent CHB</b>	

Data are presented as frequency (%) or mean ± SD. HR: Heart rate. AV: Atrioventricular, HR: heart rate. CHB: Congenital heartbeat.

Regarding the CHB data, heart block occurred immediately in 35 (83.33%) cases, late in 7 cases (16.67%). Permanent heart block occurred in 31 cases (73.81%); transient heart block occurred in 11 cases (26.19%). Recovery to sinus rhythm in transient CHB cases occurred from 4–10 days. Temporary pacemaker was needed in 11 cases (26.19%), temporary then endocardial pacemaker occurred in 21cases (50%), epicardial pacemaker occurred in 3 cases

(7.14%), and endocardial pacemaker in 7 cases (16.67%). No complications occurred in 38 cases (90.48%), sepsis after one week occurred in 1 case (2.38%), wound infection and sepsis after one month occurred in 1 case (2.38%), tricuspid valve injury and TR occurred in 1 case (2.38%) and wound infection with skin erosion after 3 months occurred in 1 case (2.38%).

Table 4

**Table 4: CHB data of patients with CHB**

		<b>(n=42)</b>
<b>Timing of heart block</b>	<b>Immediately</b>	35 (83.33%)
	<b>After 2 months</b>	2 (4.76%)
	<b>After 6 months</b>	2 (4.76%)
	<b>After 1 year</b>	1(2.38%)
	<b>After 2 years</b>	2 (4.76%)
<b>Symptoms</b>	<b>Syncope, hypotension</b>	4 (9.52%)
	<b>Refusal of feeding, drowsiness</b>	1 (2.38%)
	<b>Cold extremities</b>	1 (2.38%)
<b>Type of heart block</b>	<b>Permanent</b>	31 (73.81%)
	<b>Transient</b>	11 (26.19%)
<b>Recovery in temporary cases (days)</b>		7 ± 3
<b>Pacemaker type</b>	<b>Temporary</b>	11 (26.19%)
	<b>Temporary then endocardial</b>	21 (50%)
	<b>Epicardial</b>	3 (7.14%)
	<b>Endocardial</b>	7 (16.67)
<b>Complications</b>	<b>No</b>	38 (90.48%)
	<b>Sepsis after one week</b>	1 (2.38%)
	<b>Wound infection, sepsis after one month</b>	1 (2.38%)
	<b>Tricuspid valve injury and TR</b>	1 (2.38%)
	<b>Wound infection with skin erosion after 3 months</b>	1 (2.38%)

Data are presented as frequency (%) or mean ± SD. CHB: complete heart block. TR: Tricuspid regurgitation.

Weight at closure, type of VSD, mPAP before surgery and procedure time were independent significant predictors for occurrence of complete heart block in the surgery group (P <0.05).

Table 5

**Table 5: Multivariate regression analysis for prediction of occurrence of CHB**

Variable	Coefficient	Std. Error	Wald	P
Age at closure	0.041	0.042	0.934	0.334
Sex	0.031	0.062	0.823	0.845
Weight at closure	-0.709	0.239	8.774	<b>0.003*</b>
Down syndrome	0.728	0.329	7.774	0.254
Size of VSD	0.392	0.231	6.748	0.123
Type of VSD	-0.491	0.179	7.548	<b>0.006*</b>
LVEDD before	0.204	0.056	8.432	0.775
FS% before	0.357	0.138	6.418	0.632
mPAP before	0.104	0.039	7.318	<b>0.007*</b>
Procedure time	1.087	0.392	7.692	<b>0.006*</b>

VSD: Ventricular septal defect, mPAP: Mean pulmonary arterial pressure, FS: Fractional shortening, LVEDD: left ventricular end-diastolic dimension\*: significant as P value < 0.05.

**Case:**

Male aged 3 years diagnosed with VSD at age of 2 months, down syndrome, on medication (Lasix 3mg/kg/day, Capoten 0.4 mg/kg/dose/8 hours, Aldactone 1mg/kg/day). Past history of open-heart surgery at age of 1 year, his weight =8 kg (-2 Z- score), height =72 cm (-1 Z- score), BSA=0.39 m<sup>2</sup> (Procedure duration was 3 hours, admitted in ICU for 4 days, word for 3 days .After 2 years, mother complained of: decrease activity, excessive sleeping and she sought medical advice.

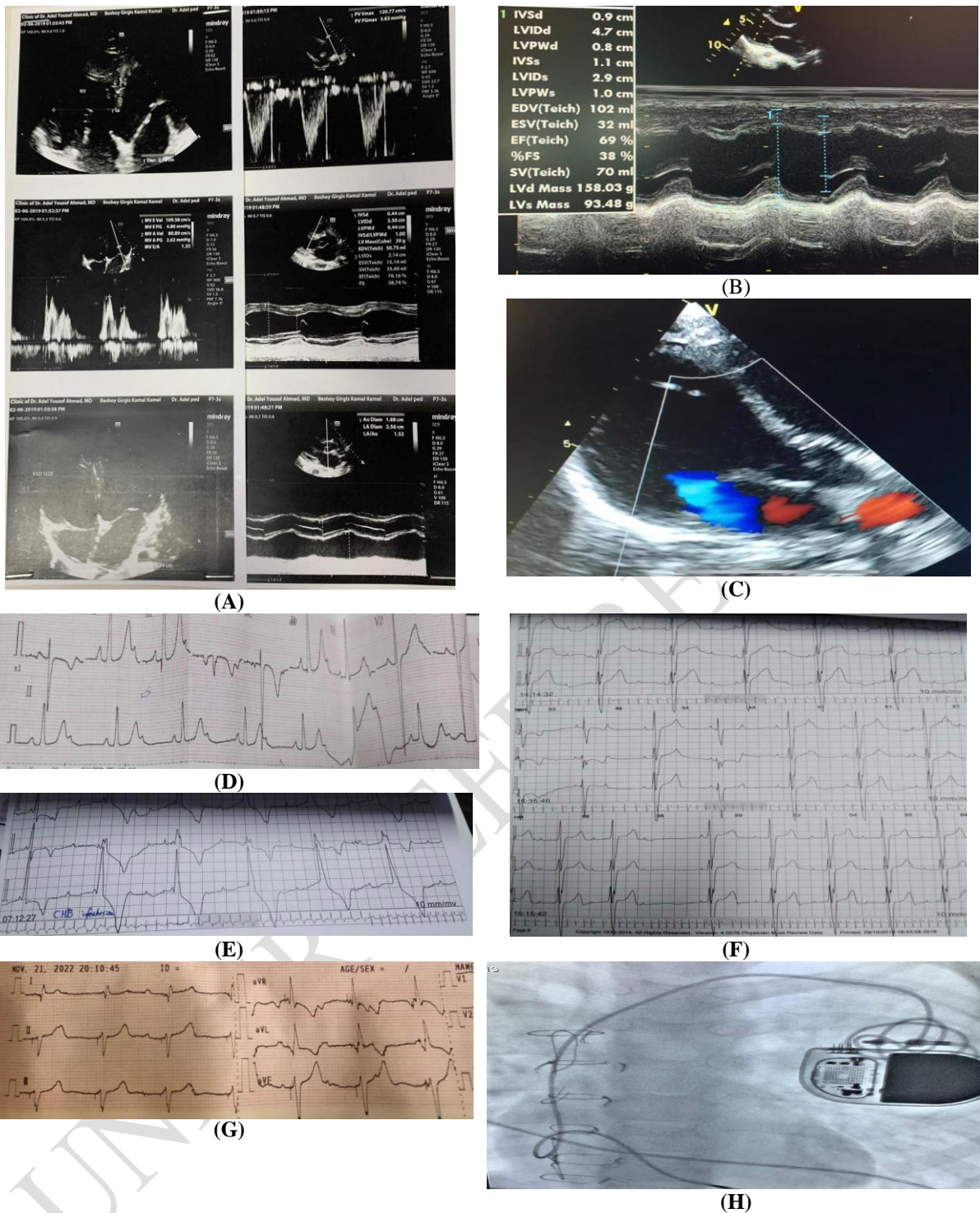
**HR:** was 50 b/m.

**ECG:** showed complete heart block with HR=66 b/m.

**Holter was done and showed:** heart block of a 2nd degree with occasional complete heart block with minimum HR =36, maximum HR=68, average HR =45bpm.

**ECHO:** before sugery showed: inlet VSD 9.9 mm, dilated left ventricle LVEDD=35mm (Z-score 3.6) with mean PAP=22mmHg.

**ECHO at presentation** after 2 years from surgery: Left ventricular dilatation, LVEDD=47mm, with preserved function, moderate mitral regurge, no residual flow across VSD patch. He was indicated for endocardial pacemaker therapy.



**Figure 1: (A) Echocardiography of inlet VSD before surgery, (B) M-mode Echocardiography showing LVEDD = 47 mm (dilated LV ) and (C) Echocardiography, parasternal long axis view, color Doppler, showing mitral regurgite at presentation. ECG and Holter at presentation (D) ECG showing 2:1 Mobitz type II heart block, (E) Holter ECG showing complete heart block infrahasian type and (F) Holter ECG showing second degree Mobitz type 2 with 2:1 block ,with complete heart block. After pacemaker (G) ECG showing paced ventricular rhythm by VVIR device and (H) Fluorography showing single chamber ventricular endocardial lead and pacemaker battery**

## Discussion

Recently, With the significant advancements in interventional methods and closure equipments, percutaneous transcatheter device VSD closure has shown encouraging outcomes as a substitute to traditional surgical repair<sup>[16]</sup>. Although many patients may benefit from surgical closure, there are certain drawbacks, such as sternotomy, the need for general anesthesia, and support of the circulation, which may increase hospital stays and recovery times.<sup>[17]</sup> Surgical closure carries a potential risk of CHB.

Regarding the demographic data for age and weight were matching with the previously published studies<sup>[17-19]</sup>, except for one study that reported lower age and weight at time of surgical VSD closure<sup>[20]</sup>. Also, it was noticed that patients who developed post-surgical CHB tended to have significantly lower body weight as compared with non-CHB group<sup>[17, 18, 20]</sup>.

Regarding the echocardiographic data: For the surgical group, most patients had peri membranous VSD. Post-surgical CHB was significantly higher in both peri-membranous and inlet types. There were no recorded patients with muscular VSD in the surgical CHB subgroup. These findings matched with the previous studies<sup>[17, 19, 21]</sup>. Of note, there was only one recorded case of CHB following muscular VSD surgical closure in the study of Azab et al.<sup>[1]</sup> which was explained by the difficulty of conclusive differentiation between peri membranous and muscular outlet VSD types on gross morphological examination. Moreover, while our largest recorded VSD size was 14 mm, a study of Zheng et al.<sup>[22]</sup> recorded surgical closure of VSDs up to 36 mm.

In the current study, it was noted that mean PAP before surgical repair was substantially greater in the surgical CHB subgroup, as contrasted with the non-CHB subgroup. The pre-operative mean PAP was shown to be an accurate indicator of post-surgical mortality, mainly due to higher risk of sudden cardiac death. However, no reports about its association with

increased incidence of post-surgical CHB were recorded as most of data were collected from only surviving patients <sup>[21]</sup>.

In the present study, patients who developed post-surgical CHB tended to have longer procedural time. It was also noted that hospital course- both intensive care unit (ICU) stays and ward stay - were significantly longer in patients who developed post-surgical CHB. Ibrahim et al. <sup>[23]</sup> additionally stated a similar substantial association between post-surgical CHB and extended cardiopulmonary bypass and aortic clamp times, with subsequent significantly longer hospital course for CHB patients. On the other hand, multiple studies suggested that despite having findings appear to support the literature with procedure time slightly longer in patients with CHB <sup>[18, 24]</sup>.

Regarding the development and outcomes of heart block: For the surgical group of our study, among the CHB subgroup (42 patients), approximately 85% of patients (35 children) developed CHB immediately during surgery, with the rest of patients experienced CHB over a period ranging between 2 months and up to 24 months. Additionally, around 75% of CHB patients (31 children) ended up with implantation of permanent pacemaker. Lin et al. <sup>[25]</sup> reported that most of the those who got post-operative permanent pacemaker had experienced early transient block in the perioperative period.

These findings suggest that even early and transient CHB is a risk factor for permanent pacemaker implantation. The slowly progressive sclero-fibrotic changes over the electrical conducting system of the heart, which is congenitally fragile, contribute to this late presenting heart block <sup>[26]</sup>. These results are like data from previous studies <sup>[19, 22, 25]</sup> however, the mean recorded period of delayed CHB was about 6 years post-operatively in a case series report of 16 cases <sup>[27]</sup>.

Independent predictors (risk factors) of heart block: For the surgical group in the current study, multivariate regression analysis for independent risk factors for post-surgical CHB

revealed that body weight, VSD type, preoperative mean pulmonary arterial pressure (mPAP) and procedure time were independent significant predictors of CHB. Also, Romer et al. <sup>[20]</sup> conducted a similar multivariate analysis which demonstrated matching results as regard procedure time, especially cardiopulmonary bypass time, but the study also added intraoperative extracorporeal membrane oxygenation (ECMO), and if a procedure with significant risks was carried out as other independent predictors of post-surgical CHB.

As could be expected, the type and location of VSD was an important risk factor of post-operative CHB, with many individuals with surgical heart block having inlet VSDs. These findings have been reported by most of the previously published studies <sup>[22, 23]</sup>. This most likely has to do with how close the AV node and the intake VSD's posterior-inferior margin are to one other.

Regarding VSD type, our data was consistent with almost all the previously published studies <sup>[28-30]</sup>. Device size as an independent predictor of postprocedural CHB was additionally verified by a similar multivariate logistic regression evaluation that was conducted by Jiang et al. <sup>[31]</sup>. However, the latter study also illustrated that type of the device, particularly the thin waist occlude, was a stand-alone risk factor for the development of postoperative heart block.

Pacemaker therapy: For the surgical group in our study, pacemaker therapy varied depending on the type and onset of post-surgical CHB. Transient CHB was managed by temporary pacing (11 children). Persistent CHB was managed by permanent pacemaker implantation either endocardial (28 patients) or epicardial (3 patients) and all our patients were managed by single chamber pacing mode (VVIR). Lin et al. <sup>[25]</sup> reported that most of the participants who got permanent pacemaker had experienced early transient block in the perioperative period.

Limitations: Small number of patients. Some of the data was collected retrospectively. The involved patients were heterogeneous as regard age at correction, body surface area weight,

and pre-existing comorbidities. For an improved evaluation of the late-onset CHB and the function of pacemaker treatment, a longer follow-up time may be necessary. a prospective, multi-center research with a bigger sample size and longer follow-up duration.

### **Conclusions:**

Low body weight at closure, large peri-membranous and inlet VSD, high mPAP before surgery, in addition to long operative duration were independent significant risk factors or predictors for occurrence of CHB after surgical VSD closure. Pacemaker therapy is the only beneficial therapy of post-operative CHB.

### **References:**

1. Azab S, El-Shahawy H, Samy A, Mahdy W. Permanent complete heart block following surgical closure of isolated ventricular septal defect. *Egypt J Chest Dis Tuberc.* 2013;62:529-33.
2. Li P, Zhao XX, Zheng X, Qin YW. Arrhythmias after transcatheter closure of perimembranous ventricular septal defects with a modified double-disk occluder: early and long-term results. *Heart Vessels.* 2012;27:405-10.
3. Shah SMA, Ullah I, Khan MG, Ullah N, Malik A, Khan RA. Frequency of complete heart block after surgical closure of perimembranous ventricular septal defect. *Postgrad Med J.* 2015;29:15-20.
4. Predescu D, Chaturvedi RR, Friedberg MK, Benson LN, Ozawa A, Lee KJ. Complete heart block associated with device closure of perimembranous ventricular septal defects. *J Thorac Cardiovasc Surg.* 2008;136:1223-8.
5. Edwin F, Aniteye E, Tettey M, Sereboe L, Kotei D, Tamatey M, et al. Permanent complete heart block following surgical correction of congenital heart disease. *Ghana Med J.* 2010;44:109-14.

6. Garcia RU, Safa R, Karpawich PP. Postoperative complete heart block among congenital heart disease patients: contributing risk factors, therapies and long-term sequelae in the current era. *Progress in Pediatric Cardiology*. 2018;49:66-70.
7. Kaszala K, Ellenbogen KA. Device sensing: sensors and algorithms for pacemakers and implantable cardioverter defibrillators. *Circulation*. 2010;122:1328-40.
8. Termosesov S, Kulbachinskaya E, Polyakova E, Khaspekov D, Grishin I, Bereznitskaya V, et al. Video-assisted thoracoscopic pacemaker lead placement in children with atrioventricular block. *Ann Pediatr Cardiol*. 2021;14:67-71.
9. Zhao C, Chen W, Qin J, Yang P, Xiang Z, Frangi AF, et al. IFT-Net: Interactive fusion transformer network for quantitative analysis of pediatric echocardiography. *Med Image Anal*. 2022;82:10-26.
10. Lopez L, Colan SD, Frommelt PC, Ensing GJ, Kendall K, Younoszai AK, et al. Recommendations for quantification methods during the performance of a pediatric echocardiogram: A report from the pediatric measurements writing group of the american society of echocardiography pediatric and congenital heart disease council. *J Am Soc Echocardiogr*. 2010;23:465-95.
11. Machino-Ohtsuka T, Seo Y, Ishizu T, Hamada-Harimura Y, Yamamoto M, Sato K, et al. Clinical utility of the 2016 ASE/EACVI recommendations for the evaluation of left ventricular diastolic function in the stratification of post-discharge prognosis in patients with acute heart failure. *Eur Heart J Cardiovasc Imaging*. 2019;20:1129-37.
12. Lang RM, Bierig M, Devereux RB, Flachskampf FA, Foster E, Pellikka PA, et al. Recommendations for chamber quantification: A report from the american society of echocardiography's guidelines and standards committee and the chamber quantification writing group, developed in conjunction with the european association of echocardiography, a branch of the european society of cardiology. *J Am Soc Echocardiogr*. 2005;18:1440-63.

13. Nagueh SF, Appleton CP, Gillebert TC, Marino PN, Oh JK, Smiseth OA, et al. Recommendations for the evaluation of left ventricular diastolic function by echocardiography. *Eur J Echocardiogr.* 2009;10:165-93.
14. Rudski LG, Lai WW, Afilalo J, Hua L, Handschumacher MD, Chandrasekaran K, et al. Guidelines for the echocardiographic assessment of the right heart in adults: A report from the american society of echocardiography endorsed by the european association of echocardiography, a registered branch of the european society of cardiology, and the canadian society of echocardiography. *J Am Soc Echocardiogr.* 2010;23:685-713.
15. Tracy CM, Epstein AE, Darbar D, DiMarco JP, Dunbar SB, Estes NAM, et al. 2012 ACCF/AHA/HRS focused update of the 2008 guidelines for device-based therapy of cardiac rhythm abnormalities. *Circulation.* 2012;126:1784-800.
16. Jiang D, Han B, Zhao L, Yi Y, Zhang J, Fan Y, et al. Transcatheter device closure of perimembranous and intracristal ventricular septal defects in children: Medium- and long-term results. *J Am Heart Assoc.* 2021;10:20-41.
17. Saurav A, Kaushik M, Mahesh Alla V, White MD, Satpathy R, Lanspa T, et al. Comparison of percutaneous device closure versus surgical closure of peri-membranous ventricular septal defects: A systematic review and meta-analysis. *Catheter Cardiovasc Interv.* 2015;86:1048-56.
18. Scully BB, Morales DL, Zafar F, McKenzie ED, Fraser CD, Jr., Heinle JS. Current expectations for surgical repair of isolated ventricular septal defects. *Ann Thorac Surg.* 2010;89:544-9.
19. Bergmann M, Germann CP, Nordmeyer J, Peters B, Berger F, Schubert S. Short- and long-term outcome after interventional vsd closure: A single-center experience in pediatric and adult patients. *Pediatr Cardiol.* 2021;42:78-88.

20. Romer AJ, Tabbutt S, Etheridge SP, Fischbach P, Ghanayem NS, Reddy VM, et al. Atrioventricular block after congenital heart surgery: Analysis from the Pediatric Cardiac Critical Care Consortium. *J Thorac Cardiovasc Surg.* 2019;157:1168-77.
21. Siehr SL, Hanley FL, Reddy VM, Miyake CY, Dubin AM. Incidence and risk factors of complete atrioventricular block after operative ventricular septal defect repair. *Congenit Heart Dis.* 2014;9:211-5.
22. Zheng Q, Zhao Z, Zuo J, Yang J, Wang H, Yu S, et al. A comparative study: Early results and complications of percutaneous and surgical closure of ventricular septal defect. *Cardiology.* 2009;114:238-43.
23. Ibrahim LA, Soliman MM, Gad Elkarim A, El Tantawy AE. Frequency and risk factors of early complete heart block post cardiac surgery in children: A multicenter prospective study. *Pediatric Sciences Journal.* 2023;3:44-9.
24. Sahu MK, Das A, Siddharth B, Talwar S, Singh SP, Abraham A, et al. Arrhythmias in children in early postoperative period after cardiac surgery. *World J Pediatr Congenit Heart Surg.* 2018;9:38-46.
25. Lin A, Mahle WT, Frias PA, Fischbach PS, Kogon BE, Kanter KR, et al. Early and delayed atrioventricular conduction block after routine surgery for congenital heart disease. *J Thorac Cardiovasc Surg.* 2010;140:158-60.
26. Altaweel H, Kabbani MS, Hijazi O, Hammadah HM, Al Ghamdi S. Late presenting complete heart block after surgical repair of ventricular septal defect. *Egypt Heart J.* 2018;70:455-9.
27. Laurens P, Gavelle P, Piwnica A, Farge C, Dubost C, Maurice P. [Severe postoperative heart blocks appearing late. 16 cases]. *Arch Mal Coeur Vaiss.* 1983;76:1132-9.

28. Walsh MA, Bialkowski J, Szkutnik M, Pawelec-Wojtalik M, Bobkowski W, Walsh KP. Atrioventricular block after transcatheter closure of perimembranous ventricular septal defects. *Heart*. 2006;92:1295-7.
29. Butera G, Massimo C, Mario C. Late complete atriovenous block after percutaneous closure of a perimembranous ventricular septal defect. *Catheter Cardiovasc Interv*. 2006;67:938-41.
30. Butera G, Carminati M, Chessa M, Piazza L, Micheletti A, Negura DG, et al. Transcatheter closure of perimembranous ventricular septal defects: early and long-term results. *J Am Coll Cardiol*. 2007;50:1189-95.
31. Jiang D, Zhang S, Zhang Y, Lv J, Yi Y, Wang J, et al. Predictors and long-term outcomes of heart block after transcatheter device closure of perimembranous ventricular septal defect. *Front Cardiovasc Med*. 2022;9:10-41.