

MULTIPLE CEREBRAL INFARCTS: A RARE AND DELAYED PRESENTATION OF HONEYBEE STING BITE

Abstract:

In emergencies, we encounter many local and allergic reactions associated with bee stings, but the venom of a bee sting can also cause neurovascular complications very rarely. We here discuss a case of a 53-year-old woman who was stung by a group of bees her on face and back and presented with swelling and itching of the face and 1 episode of Generalised Tonic Clonic Seizures type seizures followed by right upper limb and lower limb weakness 10 hours later. MRI brain revealed multiple acute bilateral frontal, parietal-occipital lobes, and basal ganglia infarcts.

Keywords: Bee sting, Generalised Tonic-clonic Seizures, MRI brain, Infarct.

Introduction:

Bees are the insects most likely to cause medical problems because they are potentially venomous. Although most stings cause minor problems such as local reactions, others can cause serious problems such as rhabdomyolysis, intravascular coagulation, cerebral hemorrhage, acute pulmonary edema, acute kidney failure, and even death [1, 2]. Bee stings are often associated with local reactions such as local erythema, edema, and self-limiting pain. It may be associated with systemic effects such as anaphylaxis, including hypotension and laryngeal edema. Bee stings are managed symptomatically. The first step is to remove the sting so that there is no exposure to the venom. Antihistamines, corticosteroids, and adrenaline are often given to treat local reactions as well as anaphylaxis. Patients recovering from anaphylaxis usually do not develop other symptoms. Rarely, patients may develop organ dysfunction such as acute kidney injury, rhabdomyolysis, cardiac dysfunction including heart block, Takotsubo cardiomyopathy. [3]

Case report:

A 53-year-old female, known epileptic since 7 years on the tab. phenytoin 100mg in the morning and 200mg at night, non-hypertensive, non-diabetic presented with a history of being stung by a massive attack of honey bees followed by swelling and itching of face and back [FIGURE 2], and one episode of Generalised Tonic Clonic type of seizures for which she was treated with antiepileptics, iv fluids [in view of hypotension (90/60mmHg)], corticosteroids and antihistamines at a local hospital. After 10 hours she presented at our emergency with weakness of the right upper limb and lower limb, insidious onset, and distal more than proximal weakness. The patient had no history of headache, loss of consciousness, blurring of vision, projectile vomiting, trauma, palpitations, or shortness of breath. On examination, the patient was conscious and coherent with stable vitals, with erythematous papules on the face and back. CNS examination showed Broca's aphasia, right UMN facial palsy [deviation of angle of mouth to left], right-sided hemiparesis, extensor right plantar [presence of Babinski sign] and flexor left plantar, no sensory and cerebellar involvement, and no other cranial nerve involvement was observed.

Investigations: The following investigations were performed.

Complete hemogram: Hb-12.3g/dl, TLC-9200cells/mm³, Platelet count- 2.2 lakhs/mm³. RFT: B. urea-21mg/dl, S. creatinine-0.7 mg/dl. LFT: Normal, Serum electrolytes: Normal, ECG: Normal sinus rhythm, Serum homocysteine levels: 15micromol/L, ANA: Negative, Lupus anticoagulant: Negative, 2D ECHO: No RWMA, Good LV systolic function, no vegetations or clots or pericardial effusion, LVEf-58%. Carotid Doppler revealed a floating thrombus in the right common carotid artery which may also be a source of thromboembolism and bee sting may be the inciting event. 2D-ECHO revealed no vegetation or clots or pericardial effusion. MRI brain: showed multiple T2, FLAIR hyperintense lesions with diffusion restriction in bilateral frontal, parietal-occipital lobes, and basal ganglia suggestive of acute infarcts – Embolic or Hypoxia related. [FIGURE 1]

Discussion:

Neurological, cardiovascular, renal, pulmonary, and ophthalmic symptoms might occur as a result of a bee sting. The neurological signs of a stroke following a bee sting can appear from 15 minutes up to 14 days after the sting. [2, 3] It is still unclear how a bee sting can cause a stroke. The underlying mechanism can be explained as 1) Anaphylaxis- or histamine-related hypotension may result in cerebral ischemia. 2) Vasoconstriction is caused by mediators produced after a bee sting. This scenario is also made worse by exogenous adrenaline. Additionally, brain ischemia and hypertension are caused by platelet aggregation. 3) Vasoactive and inflammatory mediators (histamine, thromboxane, leukotrienes, dopamine, noradrenaline, and others) are present in the actual bee venom. [4] Leukotrienes and thromboxane have both been demonstrated to cause cerebral infarction by causing vasoconstriction. [5,6]

According to Adrià Arboix et al., haematological conditions including anaemia and thrombocytosis can be unrecognised causes of stroke, however in case of our patient, this differential diagnosis has been ruled out because she has normal results from the haematological workup and the diagnosis of multiple cerebral infarcts due honey bee bite was concluded.[7] The patient was treated with antiplatelet (Tab. Aspirin 75mg once daily), antiepileptic (Tab. Phenytoin 100mg in the morning and 200mg at night), and anti-coagulant (Tab. Apixaban 2.5mg once daily) medications and showed gradual improvement. At discharge, the patient was able to walk with support with mild facial deviation and slurred speech.

Conclusion:

A stroke following a bee sting is very rare but it is still a possibility. In such cases of multiple bee stings, the patient often becomes unconscious and may not be able to provide a history. In these situations, a thorough physical examination would reveal insect bite marks, which would provide a diagnosis. A correct diagnosis can be made, and unnecessary testing to determine the cause of a stroke can be avoided with knowledge of this uncommon condition.

Ethical Approval:

As per international standard or university standard written ethical approval has been collected and preserved by the author(s).

Consent

As per international standard or university standard, patient(s) written consent has been collected and preserved by the author(s).

References:

1. Jain J, Banait S, Srivastava A, and Lodhe R. Stroke intracerebral multiple infarcts: Rare neurological presentation of honey bee bite. *Annals of Indian Academy of Neurology*. 2012;15(2):16
2. Gupta A. Acute Fatal Stroke Associated with Honeybee Sting. *Journal of neurology & neuromedicine*. 2019 Dec 1; 5 (1):18–21.
3. Haq T, Elavarasi A, Thahira T, Bineesh C, Kancharla L. Acute ischemic stroke due to multiple bee stings_A delayed complication. *Annals of Indian Academy of Neurology*. 2020; 23 (1):135–6.
4. Yang S, Wellington J, Chen J, Regenhardt RW, Chen AY, Li G, et al. Cerebral infarction following bee stings: Case report and literature review. *Translational Neuroscience*. 2022 Jan 1; 13 (1):163–71.
5. Murat G. “Stroke as a Very Rare Complication of Multiple Bee Sting: A Case Report.” *Archives in Neurology & Neuroscience*. 2020 Feb 26; 7 (2).
6. Balagopal K, Muraleedharan A, Koshy A, Jacob J. Cerebral infarction following a bee sting. *Indian Journal of Medical Specialities*. 2021;12(2)
7. Arboix A, Jiménez C, Massons J, Parra O, Besses C. Hematological disorders: a commonly unrecognized cause of acute stroke. *Expert Rev Hematol [Internet]*. 2016 [cited 2023 Jul 15]; 9 (9):891–901.

FIGURES AND LEGENDS:

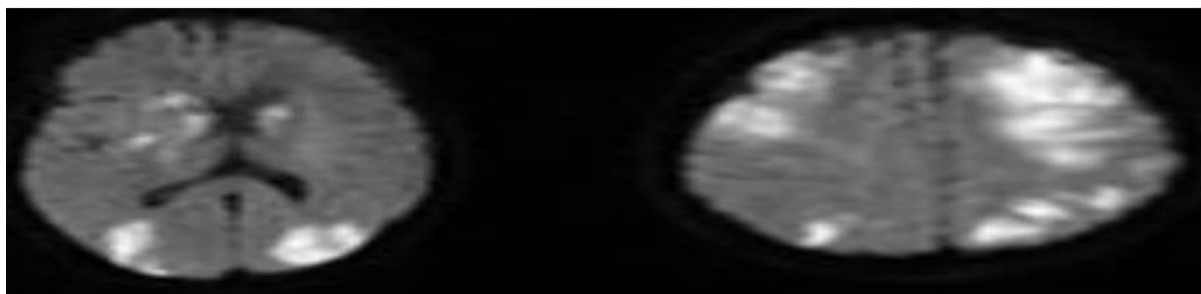


Figure1: MRI Brain showing multiple T2, FLAIR hyperintensities with diffusion restriction in bilateral fronto parieto-occipital lobes and basal ganglia suggestive of acute infarcts.

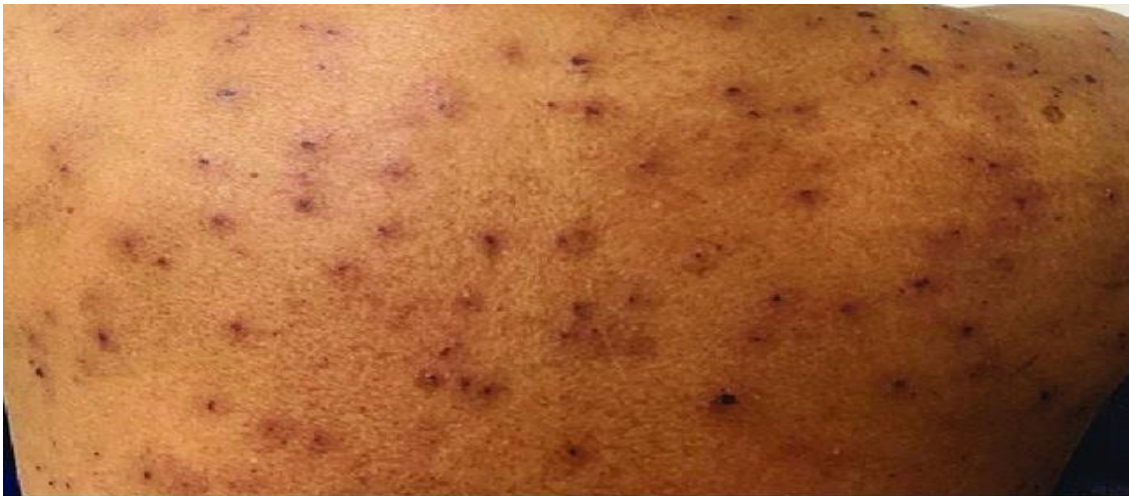

Figure 2: Multiple erythematous papules on the back.