

Review Article

Nutritional fish diseases in aquaculture: A human health hazard or mythical theory:

An Overview

ABSTRACT

To consume or not to consume farmed fish diagnosed with nutritional disorders within an aquaculture system is a question that resonates with fisheries and aquaculture experts worldwide. A nutritionally balanced diet stands as a fundamental necessity for human body growth, physical health, and cognitive development. Fish consumption is widely recognized as an excellent source of omega-3 fatty acids and essential amino acids for the human body. However, Nutritional diseases in fish result from a deficiency of essential nutrients in their diets. These diseases can also occur due to excessive amounts of certain nutrients in the feed, surpassing the fish's regular requirements. This review aims to explore the nutritional requirements of farmed fish species, the impact of nutritional deficiencies on human and public health, the causes of nutritional disorders, and viable therapies for managing these diseases in farmed fish. The data for this review article were collected from various secondary sources, including internationally reputable peer-reviewed articles, conference proceedings reports, internet searches, and more. The findings highlight the importance of providing aquaculture farmers with essential information on fish nutritional-related disease control, as nutritional diseases have been found to be detrimental not only to fish health but to some extent public health. Moreover, many farmed fish affected by nutritional disorders have entered the global market, raising questions about their impact on human health. Therefore, it is crucial for fish farmers to prioritize early diagnosis of nutritional fish diseases to ensure the safety of farmed fish in the market and maintain consumer confidence in farmed fish globally. The study recommends further research into the potentially lethal effects of different nutritional fish diseases, particularly when consumed in large quantities and to the environment especially when dead fish is discarded in the backwaters of an aquatic ecosystem.

Keywords: Nutritional Diseases; aflatoxin, mycotoxins, aquaculture, Health hazard.

1. Introduction

To consume or not to consume farmed fish diagnosed with nutritional disorders within an aquaculture system is a question that resonates with fisheries and aquaculture experts worldwide. A nutritionally balanced diet stands as a fundamental necessity for human body growth, physical health, and cognitive development. Fish consumption is widely recognized as an excellent source of omega-3 fatty acids and essential amino acids for the human body. With the decline in capture fisheries, a significant portion of the fish consumed today originates from aquaculture (FAO, 2022). Currently, aquaculture represents the fastest-growing agriculture-related industry globally. Throughout the past few decades, the aquaculture sector has transitioned from extensive to semi-intensive and, ultimately, to intensive culture systems (Opiyo et al., 2018).

Forecasts predict that the world's population will exceed 9 billion people by 2050 (Jennings et al., 2016; Syanya, 2018; Tacon & Metian, 2013). Consequently, there will be a 50% increase in the demand for fish as a protein source to sustain this growing population. However, diseases during the fish farming process have emerged as a significant challenge for aquaculture practitioners. These diseases hinder the development and sustainability of aquaculture by inflating production costs through fish mortality and the expenses associated with disease treatment (Alfred & Shaahu, 2020; Toranzo et al., 2005). Many of these diseases stem from deficiencies in essential nutrients. However, the crucial question remains: do these diseases have adverse effects on the health of consumers who eat farmed fish? The incidence of diseases in aquaculture farms, as reported in Tanzania, not only affects veterinary medicine and disease management but also poses risks to human health and environmental conservation (Mzula et al., 2021). In addition to concerns surrounding sustainability and production costs, the aquaculture industry is facing additional challenges due to the emergence of novel diseases such as the Tilapia Lake virus (Mugimba et al., 2018).

A disease is characterized as a state of disruption in which the normal physiological functions of various fish organs are altered, leading to chronic and persistent symptoms (Hernández et al., 2009). The rise in fish diseases within aquaculture is closely linked to the presence of various pathogenic microorganisms in water and the lack of essential nutritional elements in formulated fish feed. Similarly, when fish experience stress, including inadequate nutrition (Alfred & Shaahu, 2020), they become more susceptible to diseases.

Nutritional diseases in fish result from a deficiency of essential nutrients in their diets. These diseases can also occur due to excessive amounts of certain nutrients in the feed, surpassing the fish's regular requirements. Key elements for optimal fish growth and development include lipids, carbohydrates, proteins, vitamins, and mineral salts, among others (Ferraz De Arruda et al., 2006; Li et al., 2009; Makwinja & Geremew, 2020). Symptoms of nutritional diseases typically manifest immediately after replacing the old feed with new feed containing the required dietary components (Alfred & Shaahu, 2020). Common indicators of nutritional diseases include decreased fertility, slower growth rate, loss of appetite, increased susceptibility to diseases, impaired movement, and histopathological abnormalities. In severe cases, death may occur (Mzula et al., 2021).

The study conducted by Mzula et al. (2021) observed that the waste from fish feed used on farms has an immediate impact on the aquaculture system, leading to ecological cross-contamination. Uneaten fish feed and other metabolic waste contribute to the accumulation

of nutrients in the water, as reported in a study evaluating the use of taro leaves as a protein replacement in tilapia diets (Mathia & Fotedar, 2012).

These conditions impose stress on the growth of cultured fish, rendering them more susceptible to disease infections (Salin & Arome Ataguba, 2018). Diagnosing most nutritional diseases in fish can be challenging due to their intermittent nature, but effective management practices for fish feed quality can help prevent them. Bell et al. (2009) and Edwards (2015) both highlight the importance of nutritionally balanced fish feed and a healthy farming environment for long-term aquaculture production and appropriate health management of cultured fish species, which aids in preventing nutritional disorders in farmed fish.

This review aims to explore the nutritional requirements of farmed fish species, the impact of nutritional deficiencies on human and public health, the causes of nutritional disorders, and viable therapies for managing these diseases in farmed fish. Based on the findings, a recommendation will be provided regarding whether nutritionally disordered farmed fish is safe for human consumption or should be considered a health hazard.

2. Materials and Methods.

The data for this review article were collected from various secondary sources, including internationally reputable peer-reviewed articles, conference proceedings reports, internet searches, and more. The reviewed articles encompass the period from 1976 to 2023, focusing specifically on fish nutritional diseases. Additionally, literature information was obtained by visiting websites of fish disease diagnosis facilities, professional websites of fish disease experts, and aquaculture veterinary medicine shops. Careful attention was given to collecting and organizing all the secondary source materials in a sequential manner.

3. Review Findings

Fish nutritional management is crucial for achieving optimal growth rates and promoting the health of farmed fish. Nutritional disorders in fish can arise due to nutrient deficiencies, excessive nutrient intake, or an imbalanced diet (Izquierdo et al., 2015). Fish nutrition studies not only aim to determine the minimum nutritional requirements for normal growth but also investigate immune modulation and resistance to emerging infectious diseases. Significant research has been conducted to reduce the use of chemotherapeutic treatments and minimize financial losses associated with aquaculture-related diseases (Ayorinde et al., 1985).

Generally, nutritional fish diseases develop progressively as fish may store specific nutrients in their bodies to compensate for deficiencies. Once these stored nutrients are depleted, fish become weakened and susceptible to opportunistic microbes, leading to the development of chronic diseases. In fish farming, reduced growth and spawning are among the first indicators of insufficient nutrient absorption in fish (Désiré Adéyèmi et al., 2022; Yossa et al., 2021). Fingerlings and fry are particularly vulnerable, followed by broodstock (El-Sayed Ali et al., 2018). Chronic malnutrition can increase mortality in fish populations. Weakened fish are more prone to diseases and infections, such as fin rot and swollen bellies, as observed in Rohu (*Labeo rohita*) fingerlings (S. Saha et al., 2011).

Overfeeding fish with certain diets, such as excessive carbohydrates, can lead to fat accumulation in fish organs and significantly impair their physiological processes, resulting in obesity (Zhang et al., 2022). Nutritional disorders caused by imbalanced diets remain a global issue in farmed fish. Insufficient intake of dietary compounds such as proteins, amino acids, essential fatty acids, vitamins, and minerals can lead to severe diseases and nutritional risks (Hamid, 2021a; Hamid, 2021b). Therefore, proper feeding of fish with appropriately formulated diets is essential for growth, control of nutritional diseases, and

prevention of opportunistic bacterial, fungal, and viral infections. Nutritional deficiency conditions often present nonspecific symptoms (Bogard et al., 2015), creating favourable conditions for other pathogenic infections in fish, as observed in hybrid red tilapia (Muin & Taufek, 2022). Excessive use of certain nutrients in fish diets can result in nutrient loss and negatively impact water quality in the culture system, posing significant health risks to the entire fish population in a pond. Typically, symptoms of nutritional deficiencies in fish appear gradually and are challenging to identify during the early stages of fish growth (Bernoth, 2008). Similarly, the inclusion of vitamin premixes in fish diets is crucial. Fish experiencing vitamin insufficiency may exhibit reduced appetite, poor feed efficiency, and low body weight (Waagbø, 2010).

These indicators can provide fish farmers with additional information regarding vitamin insufficiency in fish diets. Similarly, mineral elements, including micro and macro elements, play critical roles in fish physiological activities such as osmoregulation, scale and skeleton development, and intermediate biochemistry, as stated by Antony Jesu Prabhu et al. (2016). Assessing fish mineral requirements can be challenging due to the trace amounts required for some minerals, while others are obtained in larger quantities from water and through the gills, as observed in Atlantic salmon (*Salmo salar*) (Prabhu et al., 2019). Therefore, the lack of minerals can result from dietary imbalances and the intricate interactions between nutritional elements, as noted by Hamid (2021c). Symptoms of mineral deficiency in fish include skeletal abnormalities, decreased resistance to infections, and anaemia, among others (Chong, 2022; Dadar et al., 2017).

Furthermore, trace elements such as zinc, copper, iron, and selenium are crucial for the functioning of metal enzymes in fish (Makwinja & Geremew, 2020). However, the potential harm of these defects and disorders in farmed fish to the end consumers of fish products requires further investigation. Currently, there is a lack of clear direction and studies in this area, indicating the need for more research. Additionally, the effects of trace elements on the immunological function of finfish species remain poorly understood. Iron, for example, is essential for both fish and microbes, as the ability of diseases to infect a host is also dependent on iron availability (Owatari et al., 2022). Microcytic anaemia, a type of iron deficiency, can occur in various farmed fish species (Kord et al., 2022; McMurtrie et al., 2022). Consequently, an iron deficiency in the fish diet renders the fish more vulnerable to infectious pathogens and increases the likelihood of disease outbreaks in the fish farm.

3.1. The prevalence and patterns of common nutritional diseases in aquaculture

Nutritional diseases in fish can arise due to deficiencies (undernutrition), excesses (overnutrition), or imbalances (malnutrition) in their diet. These disorders develop progressively as the fish's body reserves compensate for nutritional shortages to some extent. Disease symptoms only manifest when the availability of specific nutrients in the diet falls below a certain threshold. Conversely, an abundance of food can lead to the accumulation of excess fat in fish tissues and organs, significantly impairing their physiological processes (Izquierdo et al., 2015). As a result, various nutritional diseases and disorders have been reported among different farmed fish species in aquaculture, encompassing the ones described below but not limited to them.

3.1.1. Broken back syndrome (spinal kyphosis and lordosis)

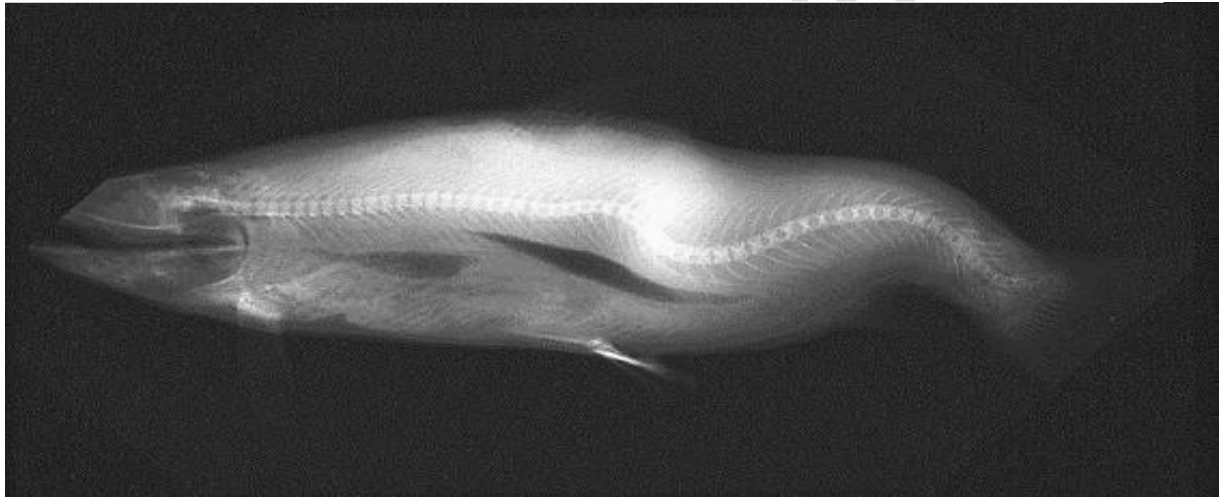
"Broken-back disease" in farmed fish is characterized by a bent backbone and is commonly associated with vitamin C deficiency. However, bacterial infections in salmon and trout can also lead to this disorder. Additionally, parasites like *Pleistophora hyphessobryconis*, which infect the skeletal muscles of neon tetras, angelfish, and other freshwater fish, can result in

complications associated with broken-back disease (Baker & Davies, 1997). Other factors, including parasitic infections, accidents, and dietary imbalances, can also cause bone and muscle abnormalities in farmed fish (Emre et al., 2008; Prabhu et al., 2019).

Nutritional imbalances due to vitamin deficiencies, such as a lack of vitamins C (ascorbic acid), E, D, and selenium, can contribute to these conditions (Rohani et al., 2023; Sarmiento et al., 2018). Broken Back Syndrome is a well-known nutritional disorder commonly observed in channel catfish and salmon in intensive aquaculture systems. This condition occurs in farmed fish when they are fed low-vitamin C diets for more than eight weeks, leading to metabolic dysfunction and organ failure (Foran et al., 2005; Silverstone & Hammell, 2002). Other authors, such as Brown & Robinson (1992) and Lock et al. (2010), have also reported structural and functional abnormalities in fish deficient in vitamin D and C.

Nutritional imbalances, particularly deficiencies in ascorbic acid (vitamin C), vitamin E, and selenium, are frequently associated with bone and muscle diseases (such as broken-back disease) in salmon farms and hatcheries (Silverstone & Hammell, 2002). Although other diseases and infections can cause this condition in farmed fish, it is rare. In commercial-scale salmon hatcheries, hatchery workers noticed an increased number of smolts with spinal malformations during the production cycle (*Figure 1*), as reported by Silverstone & Hammell (2002) in their study on salmon hatchery smolt production.

Figure1 Smolt salmon radiograph with Broken-back disease retrieved from (Silverstone & Hammell, 2002)



3.1.2. Lipidosis diseases.

This nutritional disorder is believed to be caused by the consumption of rancid, fatty fish feeds and improper storage of feeds used in aquaculture. Groupers, in particular, are highly susceptible to this condition, which is a common non-infectious nutritional disease in farmed fish species. The presence of diseased fish on a farm does not affect the health of the remaining individuals (Cole et al., 2009). A variation of this disease has been reported in cage-cultured grouper fish, such as *Epinephelus malabaricus*, in Indonesia, Thailand, and the Philippines (Lin & Shiau, 2007).

Lipidosis, also known as fatty liver disease, can be triggered by the consumption of rancid or poorly preserved food, especially fatty or low-quality trash fish. This condition affects growing fish the most (Walkley & Vanier, 2009). Affected fish exhibit a poor growth rate, sluggish movement, opaque eyes, minor abdominal distention, and a pale appearance of the liver (Dill et al., 2017).

Hepatic lipidosis, a common disease in farmed fish, can be caused by various factors, including malnutrition, a high proportion of carbohydrates in the diet, excessive lipid intake, and rancidity. Ascorbic acid, provided through their diet, is essential for fish. The main clinical signs of this nutritional disorder include poor growth rate, lethargic movement, pale appearance of the liver, opaque eyes, and abdominal distention (Dill et al., 2017; Hossain et al., 2018; Shefat, 2018).

3.1.3. Thiamine (Vitamin B1) deficiencies

Thiamine, also known as vitamin B1, is an essential water-soluble vitamin required by all living organisms. Its phosphorylated form, thiamine diphosphate, serves as a cofactor for several enzymes involved in cellular metabolism (Whitfield et al., 2018). Since fish obtain thiamine through their diet, inadequate supply can occur if the feeds they are given lack sufficient thiamine. Thiamine plays a crucial role in glucose metabolism, neurological function, digestion, and reproduction in fish (Harder et al., 2018). Thiaminase enzymes in the fish's body can lead to thiamine deficiency by breaking down thiamine molecules (Harder et al., 2018).

When farmed fish, such as tilapia (*Oreochromis niloticus*), are starved for an extended period, the activity of thiaminase enzymes increases, causing rapid thiamine breakdown and resulting in deficiency disorders (Hossain et al., 2018). Trash fish, often used as a fish meal in aquaculture, can contain enzymes that degrade thiamine, particularly in the sardine and anchovy fish families (Tacon & Metian, 2008). However, deficiency disorders do not occur when the fish meal is formulated using multiple species of trash fish, as opposed to a single species (Bijoy et al., 2018; Kari et al., 2022; J. Xu et al., 2022).

Clinically, thiamine deficiency in farmed fish presents with symptoms such as nervous system problems, pale body colour, anorexia, regurgitation of blood, erratic swimming, and physical wounds and haemorrhages on the body surface (Harder et al., 2018; Whitfield et al., 2018). Severe cases can lead to mass mortality, particularly when stocking densities are extremely high. Thiamine deficiency complex (TDC) was first documented in Pacific Coast salmonids in the USA, with Chinook salmon fry exhibiting swimming irregularities, lethargy, swollen belly, and increased early life-stage mortality (Heather, 2022). Figure 2: Evaluating Thiamine Deficiency in Chinook Salmon at the Fish Conservation Physiology Hatchery during fingerling production (Heather, 2022).

Figure 2. Showing lethargy, swollen belly, and increased early life-stage mortality due to Thiamine Deficiency in Chinook Salmon. Photo Plate retrieved from (Heather, 2022)



3.1.4. Obesity in fish

While malnutrition resulting from overfeeding in fish has been associated with metabolic and immunological diseases in humans, the phenomenon of overfeeding-induced obesity in fish aquaculture remains largely unknown. However, studies have demonstrated that feeding levels have an impact on the growth and nutrient deposition in rainbow trout (*Oncorhynchus mykiss*), leading to obesity in these fish species (Bureau et al., 2006). Obesity is a common health risk observed in both pond and aquarium-farmed fish, particularly in the widely cultured rainbow trout (*Oncorhynchus mykiss*), where it is primarily induced by feeding practices (Roh et al., 2020).

In fish such as zebrafish and blunt snout bream, overfeeding with high-fat diets has been linked to health issues, including fat accumulation in the liver. A fatty liver can be caused by

a high-fat diet or a deficiency of biotin or choline in the zebrafish's diet (Landgraf et al., 2017). Similarly, overfeeding blunt snout bream with a high-fat diet has been identified as a major cause of aberrant hepatic lipid secretion and associated diseases (Cao et al., 2019). When fish consume a fatty diet, they may become overweight or bloated, leading to obesity. Overfeeding young Nile tilapia (*Oreochromis niloticus*) has been observed to cause constipation, digestive disorders, and histological changes in the liver (Taddese et al., 2014).

To mitigate these issues in fish farming systems, it is important to reduce the frequency and amount of feed given to the fish or provide them with high-quality feeds containing less fat, depending on the species. Furthermore, research on rainbow trout has revealed that overfeeding negatively impacts fish health, with overfed individuals displaying enlarged livers and macrophages due to increased fat accumulation (Roh et al., 2020).

3.1.5. Nutritional myopathy

Nutritional myopathy is a condition associated with diets rich in rancid fat or polyunsaturated fatty acids and deficient in vitamin E. This condition can occur when cellular activities in the cell membrane are altered by causative agents such as statins (Galli & Iuliano, 2010). It is important to note that nutritional myopathy is not an infectious or contagious disease. In zebrafish, the condition has a significant impact, leading to degenerative myopathy and impaired swimming behaviour in fry and fingerlings (Lebold et al., 2013). Affected zebrafish exhibit darkening of body colour, emaciation, petechia around the operculum, and occasionally spinal cord malformation (Landgraf et al., 2017; Lebold et al., 2013).

In rainbow trout fingerlings (*Oncorhynchus mykiss*), this condition can cause low mortality initially, but widespread death can occur after a certain period, particularly when the bloodstock feed used is not properly adjusted (Bureau et al., 2006). Nutritional myopathy syndrome has also been associated with necrosis and degeneration of muscle fibres in calves-fed fish protein concentrate (Michel et al., 1972). Furthermore, the disease commonly occurs in cultured fish species such as yellowtail kingfish (*Seriola quinqueradiata*) (Le et al., 2014), red sea bream (*Pagrus major*), Japanese flounder (*Paralichthys olivaceus*) (Nguyen et al., 2002), rainbow trout (*Oncorhynchus mykiss*) (Bureau et al., 2006), common carp (*Cyprinus carpio*), and other notable cultured fish species that are fed diets with high levels of rancidity and lipids (Wang, Wang, Qin, Zhou, Geng, & Chen, 2016). Channel catfish and other catfish species, such as African catfish (*Clarias gariepinus*), are also prone to this disease. In European sea bass (*Dicentrarchus labrax*) and seabream, the condition is referred to as "yellow fat" disease (Gouveia & Davies, 1998) and is commonly observed in fish-fed rancid fish mince. Infected fish typically exhibit brown-coloured adipose tissue around the visceral organs (Wang Chen et al., 2016). Dark body colouration and brown-coloured livers are serious clinical signs of nutritional myopathy in farmed rainbow trout (Roh et al., 2020). Similarly, cultured puffers (*Fugu pardalis*) have been observed to develop ceroid deposits on hepatic cells when fed fish meal with high levels of rancidity (S. et al., 1981). Japanese Amberjack is also reported to exhibit nutritional myopathy when fed rancid feeds (Kobayashi, 2010). Fish affected by this condition may show clinical signs such as larger and irregular hepatic cells in the liver, but it is important to note that the disease is not transmissible to humans through fish consumption.

3.1.6 Avitaminosis and hyper-avitaminosis nutritional disorder

Vitamin deficiency in cultured fish, known as vitaminosis, occurs when certain vitamins are absent from the fish's diet. This condition is usually lethal, and insufficient vitamins can lead to non-specific growth retardation and increased susceptibility to diseases (Wang et al., 2016). The good news for pond fish farmers is that vitamin deficiency diseases are

uncommon in pond culture systems. However, when they do occur, they can impair immune function and lead to chronic diseases in nearly all cultured fish species in pond systems (Bell & Waagbø, 2008). During the early stages of fish culture, it is crucial to provide an optimal number of essential vitamins to boost fish immunity (Navia & Hunt, 1976).

According to Combs & McClung (2017), excessive intake of water-soluble vitamins can result in dangerous conditions known as hypervitaminosis under certain circumstances. However, under normal aquaculture conditions, such problems do not typically occur. Hypervitaminosis has been observed in Rainbow Trout fish under experimental conditions, with signs of toxicity (Watanabe et al., 1981). Similarly, based on the findings of Vir (2011), the accumulation of vitamin A in fish can cause hypervitaminosis and increase the incidence of craniofacial and spinal abnormalities. Vitamin D has been reported as an essential regulator of mineral ions in the homeostasis process of channel catfish (*Ictalurus punctatus*) (Brown & Robinson, 1992). Moreover, studies have shown that both vitamins A and D enhance the synthesis of vitamin K and D proteins in rainbow trout fish, indicating a strong correlation between their effects on fish cell activity and growth (Rider et al., 2023).

In Atlantic salmon (*Salmo salar*), vitamins C and E are responsible for activating vitamin K and D proteins. Therefore, incorporating these vitamins into the fish's diet can help control deficiency conditions associated with vitamin deficiencies in aquaculture. Similarly, chronic vitamin E insufficiency in zebrafish, as observed by Lebold et al. (2013), can exacerbate vitamin C deficiency, leading to degenerative myopathy and reduced swimming behaviour.

Furthermore, vitamin C has been reported to protect fish against vitamin E deprivation in Atlantic salmon (*Salmo salar*) (Hamre et al., 1997). This was demonstrated through data on growth, mortality, haematology, and lipid oxidation in the salmon's liver. A similar finding was reported by Sarmiento et al. (2018) regarding the insufficiency of vitamin C, which led to a significant decline in reproductive efficiency, egg quality, and larvae quality in Nile tilapia (*Oreochromis niloticus*) during breeding.

Additionally, based on the findings of Hamre & Lie (1995), there is a minimum requirement of vitamin E for farmed Atlantic salmon (*Salmo salar*) at the first feeding stage in order to improve the vitamin E concentration in the fish liver. However, it was noted that vitamin C had no effect on tissue levels of vitamin E. Nonetheless, vitamin C levels in the liver of Atlantic salmon were observed to increase in response to both vitamin treatments (Hamre et al., 1997).

3.1.6. Toxicosis nutritional disorder.

Toxins can enter the fish diet through various sources such as mycotoxins from feeds, pesticides, herbicides, and other agricultural pollutants, which can find their way into the fish feed (Cole et al., 2009). For example, mycotoxins produced by moulds on plant-related feed additives, including aflatoxin mycotoxin, have been observed to cause liver cancer in rainbow trout that were fed on toxic feeds (Colson et al., 2015).

Another form of toxicosis is bacterial toxicosis, which can be caused by toxins generated by microbiomes associated with fish feed pollution (Deng et al., 2014). These microbiological pathogens, as reported by Xu et al. (2021), can be effectively eliminated by properly processing fish feeds, particularly through heating under high temperatures, to kill fish pathogens, as demonstrated in the case of gift tilapia feeds.

Bacterial toxicosis is primarily caused by microbial toxins associated with fish feed spoilage. Good management practices should be followed to ensure that fish feeds are stored in cool, dry places. Hamre & Lie (1995) observed that feeding raw salmon offal to hatchery stocks

significantly resulted in mycobacteriosis, a type of fish tuberculosis, in Atlantic salmon (*Salmo salar*). The main source of infection, as stated by the authors, was effectively eliminated by replacing raw salmon offal with fish meals containing sterilized salmon visceral organs.

Although limited research has been conducted on the toxicity of toxicosis conditions in fish to human health, from my personal perspective, both toxicosis resulting from mycobacteriosis and mycotoxins may pose a health hazard to the end-user if allowed into the market.

3.1.7. Blindness-melanism syndrome.

Raymond (1987) originally identified this nutritional disorder as "Loss of Scales Syndrome" among *Ocyurus chrysurus* and *Lutjanus analis* fish species in India. The affected fish typically exhibit various clinical signs, including but not limited to loss of appetite, melanism, and drastic weight loss. According to Shefat (2018), some fish had difficulty identifying pellets, indicating total blindness. Ulcers on the fish's skin were frequently observed on the head, dorsal body parts, and fins. Additionally, keratitis was occasionally seen, and excessive fat deposition in the liver of the fish was reported. Similar symptoms were observed by Hamre et al. (1997), such as lack of septicemia and parasite parasitism, which are quite erratic in farmed Atlantic salmon (*Salmo salar*). These clinical signs are associated with dietary deficiencies, especially of vitamins C and E, as well as environmental conditions such as light and temperature variations.

3.1.8. Brown bowel syndrome:

The disease is also known as *Gastrointestinal ceroidosis* and is common among farmed marine and freshwater fish species such as common carp (*Cyprinus carpio*), tilapia, rainbow trout (*Oncorhynchus mykiss*), and turbot. According to Arnold et al. (2020) and Horn et al. (1990), the disease is caused by a deficiency of dietary vitamin E. Similarly, in humans, the disease is also associated with vitamin E deficiency but is a very rare condition that occurs in conjunction with malabsorption syndromes. Farmed salmon and turbot are the most affected fish species, as reported by Hamre et al. (1997) and Hamre & Lie (1995). Therefore, it is recommended that vitamin premixes used in fish feed formulations should contain a significant amount of vitamin E as a preventive measure against outbreaks of gastrointestinal ceroidosis in aquaculture rearing systems. The potential health concerns of this disease to humans warrant further research in this area.

3.1.9. Microcytic Homochronic anaemia.

It is caused by a deficiency of iron in the fish diet, which is common among all farmed species. Clinical signs of this condition include but are not limited to, hypoxia, reduced blood circulation, and impaired transport of red blood cells. As a result, the ability of haemoglobin to package oxygen is impaired, leading to hypoxia (Saha et al., 2022).

3.1.10. Granulomatous hypertyrosinemia

This condition was initially identified as a granulomatous syndrome in farmed turbot and is associated with a breakdown issue of tyrosine in the fish's body (Zheng et al., 2023). The most notable clinical signs include the presence of white, yellowish, or orange nodules, primarily observed on the kidney but occasionally occurring on the visceral organs of the fish. Navia & Hunt (1976) also reported the occurrence of subcutaneous white deposits

covering the cornea of the fish's eye. In certain cases, there may be cutaneous melanism, weight loss, and abdominal dropsy in certain fish species.

4. The impact of nutritional fish diseases on human health. From a personal perspective

The question of whether nutritional fish diseases and their implications for human health go beyond the scope of this study has been a significant concern for researchers in the field of fish nutrition. Limited research has been conducted to determine the actual risks associated with consuming fish affected by nutritional disorders. Despite the global increase in aquaculture production since 2018 (FAO, 2022), a significant portion of locally consumed fish comes from aquaculture, raising concerns about the use of vaccines and antibiotics. This topic has become a subject of debate among fisheries experts. The question of whether nutritional diseases in aquaculture can pose health risks to consumers and fish farmers remains unanswered.

Effective management of diseases in aquaculture systems is crucial for the sustainable development of aquaculture enterprises (Cole et al., 2009). Among the various diseases and disorders reported in the aquaculture sector, nutritional diseases and disorders pose significant public health and environmental hazards (Alfred et al., 2020; Hossain et al., 2018; Mzula et al., 2021). It is essential for all stakeholders in the aquaculture sector to establish clear surveillance plans to minimize cross-contamination and disease spread within the production system.

The detection of pathogens and the use of unlicensed veterinary medicines in aquaculture for disease treatment have raised concerns about product rejection in the international export market, impacting fish farmers in countries like India and China (Basavaraja, 2015; Hernández et al., 2009). This has resulted in substantial losses for fish farmers. Additionally, fish feed-derived waste has been found to directly influence the aquaculture environment, posing challenges for sustainable production and potential health risks for humans (Syanya et al., 2023b). The accumulation of fish additives, fish feces, and other metabolic wastes contributes to environmental pollution and poses health hazards (Cole et al., 2009; Munguti et al., 2014; Ottinger et al., 2016). These conditions not only cause stress and slow growth in farmed fish but also make them susceptible to opportunistic diseases that can be harmful to humans when consumed. Therefore, when formulating fish feeds, careful attention must be given to the levels of essential mineral elements and vitamins to mitigate these risks.

Excessive protein intake in fish diets can lead to increased protein excretion by farmed fish, resulting in elevated ammonia levels in the environment. This alteration in water chemistry poses significant health problems for fish farmers. Although protein accumulation may enhance the growth rate of farmed fish, the associated environmental hazards can be detrimental to fish farmers and their families (Mente et al., 2011; Ottinger et al., 2016). It is crucial to ensure that fish feeds administered in aquaculture systems have the appropriate crude protein composition to control emerging environmental-related issues that affect both the culture system and the human population.

Considering that the world population is predicted to exceed nine billion by 2050, with an increasing demand for fish feed, aquaculture is expected to play a vital role in meeting nutritional needs. Intensive aquaculture practices using commercial feeds will be necessary, which raises concerns about the health and environmental risks faced by personnel working in the aquaculture sector. It is important to acknowledge that the health and nutritional quality of fish are determined by the nutrient content of the supplemental feed, which directly impacts consumer nutrition requirements, food safety, and overall health conditions (Sealey et al., 1999).

Similarly, high levels of polyunsaturated fatty acids (PUFAs), such as EPA and DHA, are commonly added to fish feed as additives to enhance their nutritional value (Hearn et al., 1987). However, most customers are unaware of the decreasing levels of DHA and EPA in farmed fish species currently available in the market (Syanya et al., 2023b). Mukhopadhyay et al. (1996) reported decreased concentrations of EPA and DHA in samples of farmed Indian carp (*Catla catla*). Therefore, it is crucial to increase the levels of PUFA in fish feed to ensure human health concerns are addressed when consuming farmed fish.

While there is no clear report on the harmful nature of nutritional diseases such as granulomatous hypertyrosinemia and microcytic homochromatic anaemia, the clinical signs exhibited in affected fish make them unfit to meet the required quality and safety standards (Duarte et al., 2020). Regulations from organizations like the US FDA and the EU set safety requirements for fisheries and aquaculture products in the market. However, the question remains whether the consumption of fish with granulomatous hypertyrosinemia can be lethal to humans. Despite the presence of clinical signs, including the occurrence of white, yellowish, or orange nodules on the kidneys and other visceral organs of fish (Garrett et al., 1997), little research has been conducted to determine the safety of consuming such fish. More studies are needed to assess the potentially lethal effects of nutritional diseases on human health.

Toxicosis and nutritional disorders have been topics of debate not only in the agriculture industry but also in aquaculture. Toxins can enter the fish diet through sources such as mycotoxins from feeds, pesticides, herbicides, and other agricultural pollutants, which can find their way into fish feed (Cole et al., 2009; Syanya et al., 2023a). For example, mycotoxins produced by moulds on plant-related feed additives, including aflatoxin, have been observed to cause liver cancer in rainbow trout fed on contaminated feeds (Colson et al., 2015). Bacterial toxicosis, another form of toxicosis, can result from toxins produced by microbiomes associated with fish feed pollution (Deng et al., 2014). Aflatoxins and mycotoxins have been reported to cause death when consumed, particularly in cereals, raising concerns about the toxicity of fish feed and its cumulative effects on farmed fish and the environment. Aflatoxins are known to be harmful to humans.

Furthermore, avitaminosis and hyper-avitaminosis, two nutritional disorders, have been found to have no lethal effects on humans when fish affected by these disorders are properly cooked (Hossain et al., 2018). Vitamin deficiency can lead to non-specific growth retardation and increased vulnerability to diseases in cultured fish (Wang et al., 2016). However, in the international market, sick fish is considered unhealthy for human consumption, and no such fish should be sold due to public health concerns (Mzula et al., 2021). Similarly, while overfeeding-induced obesity in fish has been associated with metabolic and immunological diseases in humans, there is limited knowledge about the effect of consuming fish suffering from obesity as a nutritional disorder (Bureau et al., 2006). Obesity in fish is a common health risk for both pond and aquarium-farmed species, but no human health risks have been identified as barriers to consuming fish affected by this disorder. More research is needed to assess the safety of consuming fish affected by obesity and its impact on human health.

Equally, lipidosis is a nutritional disorder believed to be caused by rancid, fatty fish feeds and poor storage of feeds used in aquaculture (Syanya et al., 2023a). The major farmed fish affected by this condition are groupers. It is a prevalent, non-infectious nutritional disease in farmed fish species. The presence of diseased fish on a farm has no effect on healthy ones (Cole et al., 2009). However, frequent handling of rancid fish feeds can easily expose fish farmers to skin diseases that may be challenging to diagnose. Nevertheless, the consumption of fish suffering from lipidosis has never been linked to any health hazards (Syanya et al., 2023b). Since no research has been conducted on the potential effects of

consuming lipidosis-affected fish carcasses on human health, it is premature to make any assumptions. Therefore, we strongly recommend further research on the impact of lipidosis consumption on human health.

Another nutritional disorder is brown bowel syndrome, also known as gastrointestinal ceroidosis, which is common in farmed marine and freshwater fish such as common carp (*Cyprinus carpio*), tilapia, rainbow trout (*Oncorhynchus mykiss*), and turbot. This disease is caused by a deficiency of dietary vitamin E (Arnold et al., 2020; Horn et al., 1990). Similarly, in humans, the disease occurs as a rare condition associated with malabsorption syndromes and a lack of vitamin E. However, whether the same disease in farmed fish can be transmitted to humans through the consumption of affected fish remains an unexplored question, and it is considered a theoretical possibility in current research. Finally, mass mortality of fish due to nutritional diseases and disorders in intensive aquaculture systems can lead to environmental pollution and degradation when a large number of dead fish are disposed of in backwaters, estuaries, lakes, rivers, or oceans. The long-term pollution effects can pose a threat to human health. Therefore, it is essential to consider and address these issues when formulating fish diets.

5. Conclusion

Proper fish health management in aquaculture should be a critical area of concern for all fish farmers. It has become a fundamental requirement for achieving sustainable aquaculture production. However, many fish farmers, particularly in developing countries like Kenya, Uganda, Indonesia, Nepal, and Burundi, lack knowledge about fish diseases and how to effectively control fish health. Just like humans, the health of farmed fish in aquaculture systems should be a daily priority for fish farmers. Therefore, it is crucial to focus on disease prevalence and fish pathogens. Farmers should be provided with basic information on sound aquaculture management practices and disease control measures.

Nutritional diseases are often overlooked by the majority of fish farmers, even at the commercial level. They may not realize that nutritional disease prevention can be achieved through the use of well-formulated fish feeds that meet all the nutritional requirements for fish growth. Additionally, maintaining good water quality and implementing best management practices are essential to ensure that the fish stock remains healthy in the culture system. Fish farmers should regularly monitor water quality parameters, as poor water quality, inadequate diets, or a weakened immune system can allow potentially pathogenic microbes to cause diseases within the culture system.

Since fish species have varying nutritional dietary requirements, it is important to formulate the right nutritional diet based on the specific fish species being cultured. Fish feeds should contain the necessary nutrients to ensure opportunistic disease resistance. Furthermore, fish farmers should be familiar with early diagnosis techniques for nutritional fish disease disorders. This ensures that the harvested fish reaching the market does not raise concerns about the quality and safety of farmed fish products. Failure to diagnose nutritional disorders associated with poor feeds and diets can create doubts in the rapidly growing aquaculture industry.

6. Recommendations

Based on the findings of this review study, the following recommendations have been formulated:

1. Further research is needed to understand the potentially lethal effects of different nutritional fish diseases on human health, particularly when consumed in large quantities.

2. Fish farmers should ensure proper storage of their fish feed in a cool, dry place. This is important because *Aspergillus flavus* can grow on mouldy feedstuff and produce aflatoxins, which are harmful to fish and, to some extent, to humans.
3. To address vitamin-related nutritional deficiencies, fish farmers should consider adding vitamin C directly to the water in the culture system. This can serve as a supplementation method.
4. Fish farmers should use high-quality feed ingredients that are free from contamination. It is important to monitor blood fish meal formulations as they can supply high levels of iron, which may make the fish susceptible to common bacterial pathogens, rendering them unfit for consumption.
5. It is advisable for fish farmers to avoid feeding fish with fish trash from unknown sources. Such feed cannot provide a nutritionally balanced diet for the fish and may weaken their immune system, making them more vulnerable to pathogen infections.
6. Hygienic dry pellet feeds with appropriate vitamin and mineral inclusions should be used to enhance fish immunity.
7. Maintaining the correct stocking density is crucial for fish health. Fish farmers should ensure that the number of fish in the culture system is appropriate and does not lead to overcrowding.

By implementing these recommendations, fish farmers can improve the overall health and quality of their farmed fish, contributing to safer and more sustainable aquaculture practices.

7. REFERENCES

- Alfred, O., & Shaahu, A. (2020). *An Overview on Understanding the Basic Concept of Fish Diseases in Aquaculture*.
- Antony Jesu Prabhu, P., Schrama, J. W., & Kaushik, S. J. (2016). Mineral requirements of fish: A systematic review. *Reviews in Aquaculture*, 8(2), 172–219. <https://doi.org/10.1111/RAQ.12090>
- Arnold, C. A., Burke, A. P., Calomeni, E., Mayer, R. C., Rishi, A., Singhi, A. D., Stashek, K., Voltaggio, L., & Tondon, R. (2020). Brown Bowel Syndrome: A Multi-institutional Case Series. *American Journal of Surgical Pathology*, 44(6), 834–837. <https://doi.org/10.1097/PAS.0000000000001443>
- Ayorinde, F. O., Grissom, F. E., Afolabi, O. A., Oshuntogun, B. A., Adewusi, S. R., Fapojuwo, O. O., & Oke, O. L. (1985). Preliminary Nutritional and Chemical Evaluation of Raw Seeds from *Mucuna solanei*: An Underutilized Food Source. *Journal of Agricultural and Food Chemistry*, 33(1), 122–124. <https://doi.org/10.1021/JF00061A035>
- Baker, R. T. M., & Davies, S. J. (1997). Modulation of tissue cc-tocopherol in African catfish, *Clarias gariepinus* (Burchell), fed oxidized oils, and the compensatory effect of supplemental dietary vitamin E. *Aquaculture Nutrition*, 3(2), 91–97. <https://doi.org/10.1046/J.1365-2095.1997.00078.X>

- Basavaraja, N. (2015). Recent developments in Indian aquaculture. *Fish Chim*, 34(12), 24–28.
- Bell, J. G., & Waagbø, R. (2008). Safe and nutritious aquaculture produce: Benefits and risks of alternative sustainable aquafeeds. *Aquaculture in the Ecosystem*, 185–225. https://doi.org/10.1007/978-1-4020-6810-2_6
- Bell, M. B. V., Radford, A. N., Rose, R., Wade, H. M., & Ridley, A. R. (2009). The value of constant surveillance in a risky environment. *Proceedings of the Royal Society B: Biological Sciences*, 276(1669), 2997–3005. <https://doi.org/10.1098/RSPB.2009.0276>
- Bernoth, E. M. (2008). Aquaculture Biosecurity: The View and Approaches of the OIE (World Organisation for Animal Health) Regarding Prevention and Control of Aquatic Animal Diseases. *Aquaculture Biosecurity: Prevention, Control, and Eradication of Aquatic Animal Disease*, 3–8. <https://doi.org/10.1002/9780470376850.CH1>
- Bijoy, V. M., Sabu, S., & Harikrishnan, M. (2018). Fish meal replacement with squilla (*Oratosquilla nepa*, Latreille) silage in a practical diet for the juvenile giant freshwater prawn, *Macrobrachium rosenbergii* de man, 1879. *Aquaculture International*, 26(5), 1229–1245. <https://doi.org/10.1007/S10499-018-0280-0/TABLES/10>
- Bogard, J. R., Thilsted, S. H., Marks, G. C., Wahab, M. A., Hossain, M. A. R., Jakobsen, J., & Stangoulis, J. (2015). Nutrient composition of important fish species in Bangladesh and potential contribution to recommended nutrient intakes. *Journal of Food Composition and Analysis*, 42, 120–133. <https://doi.org/10.1016/J.JFCA.2015.03.002>
- Brown, P. B., & Robinson, E. H. (1992). Vitamin D studies with channel catfish (*Ictalurus punctatus*) reared in calcium-free water. *Comparative Biochemistry and Physiology -- Part A: Physiology*, 103(1), 213–219. [https://doi.org/10.1016/0300-9629\(92\)90265-R](https://doi.org/10.1016/0300-9629(92)90265-R)
- Bureau, D. P., Hua, K., & Cho, C. Y. (2006). Effect of feeding level on growth and nutrient deposition in rainbow trout (*Oncorhynchus mykiss* Walbaum) growing from 150 to 600 g. *Aquaculture Research*, 37(11), 1090–1098. <https://doi.org/10.1111/J.1365-2109.2006.01532.X>
- Cao, X. F., Dai, Y. J., Liu, M. Y., Yuan, X. Y., Wang, C. C., Huang, Y. Y., Liu, W. Bin, & Jiang, G. Z. (2019). High-fat diet induces aberrant hepatic lipid secretion in blunt snout bream by activating endoplasmic reticulum stress-associated IRE1/XBP1 pathway. *Biochimica et Biophysica Acta - Molecular and Cell Biology of Lipids*, 1864(3), 213–223. <https://doi.org/10.1016/J.BBALIP.2018.12.005>
- Chong, R. S.-M. (2022). Endocrine disruption in fish. *Aquaculture Pathophysiology*, 727–740. <https://doi.org/10.1016/B978-0-12-812211-2.00065-2>
- Cole, D. W., Cole, R., Gaydos, S. J., Gray, J., Hyland, G., Jacques, M. L., Powell-Dunford, N., Sawhney, C., & Au, W. W. (2009). Aquaculture: Environmental, toxicological, and health issues. *International Journal of Hygiene and Environmental Health*, 212(4), 369–377. <https://doi.org/10.1016/J.IJHEH.2008.08.003>
- Colson, V., Sadoul, B., Valotaire, C., Prunet, P., Gaumé, M., & Labbé, L. (2015). Welfare assessment of rainbow trout reared in a Recirculating Aquaculture System: Comparison with a Flow-Through System. *Aquaculture*, 436, 151–159. <https://doi.org/10.1016/J.AQUACULTURE.2014.10.047>
- Combs, G. F., & McClung, J. P. (2017). Vitamin Needs and Safety. *The Vitamins*, 79–106. <https://doi.org/10.1016/B978-0-12-802965-7.00005-8>

- Dadar, M., Dhama, K., Vakharia, V. N., Hoseinifar, S. H., Karthik, K., Tiwari, R., Khandia, R., Munjal, A., Salgado-Miranda, C., & Joshi, S. K. (2017). Advances in Aquaculture Vaccines Against Fish Pathogens: Global Status and Current Trends. *Reviews in Fisheries Science and Aquaculture*, 25(3), 184–217. <https://doi.org/10.1080/23308249.2016.1261277>
- Deng, J., Zhang, X., Long, X., Tao, L., Wang, Z., Niu, G., & Kang, B. (2014). Effects of dietary cholesterol supplementation on growth and cholesterol metabolism of rainbow trout (*Oncorhynchus mykiss*) fed diets with cottonseed meal or rapeseed meal. *Fish Physiology and Biochemistry*, 40(6), 1827–1838. <https://doi.org/10.1007/S10695-014-9971-2>
- Désiré Adéyèmi, A., Polycarpe Kayodé, A. P., Morelle Atcheon, I., Bienvenue Chabi, I., Rob Nout, M. J., & Linnemann, A. R. (2022). Performance of sustainable fish feeds in Benin for *Clarias gariepinus* (Burchell 1822). *Egyptian Journal of Aquatic Research*. <https://doi.org/10.1016/j.ejar.2022.09.002>
- Dill, J., Brown, C., Heym, K., & Camus, A. (2017). Lipoid liver disease, atherosclerosis and glomerular lipidosis in a Gulf flounder *Paralichthys albigutta* (Jordan & Gilbert 1882): a case report. *Journal of Fish Diseases*, 40(2), 273–278. <https://doi.org/10.1111/JFD.12486>
- Duarte, A. M., Silva, F., Pinto, F. R., Barroso, S., & Gil, M. M. (2020). Quality Assessment of Chilled and Frozen Fish—Mini Review. *Foods 2020*, Vol. 9, Page 1739, 9(12), 1739. <https://doi.org/10.3390/FOODS9121739>
- Edwards, P. (2015). Aquaculture environment interactions: Past, present and likely future trends. *Aquaculture*, 447, 2–14. <https://doi.org/10.1016/j.aquaculture.2015.02.001>
- El-Sayed Ali, T., El-Sayed, A. M., Eissa, M. A. R., & Hanafi, H. M. (2018). Effects of dietary Biogen and sodium butyrate on hematological parameters, immune response, and histological characteristics of Nile tilapia (*Oreochromis niloticus*) fingerlings. *Aquaculture International*, 26(1), 139–150. <https://doi.org/10.1007/S10499-017-0205-3>
- Emre, Y., Sevgili, H., & Şanlı, M. (2008). A preliminary study on the utilization of hazelnut meal as a substitute for fishmeal in the diets of European Sea bass *Dicentrarchus labrax*. *Aquac Res*, 39(3), 324–328. <https://doi.org/10.1111/j.1365-2109.2007.01881.x>
- FAO. (2022). *The state of world fisheries and Aquaculture, 2022, Towards Blue transformation*.
- Ferraz De Arruda, L., Borghesi, R., Brum, A., Regitano D'Arce, M., & Oetterer, M. (2006). Nutritional aspects of Nile Tilapia (*Oreochromis niloticus*) silage. *Cienc Tecnol Aliment Campinas*, 26(4), 749–753. <https://doi.org/10.1590/s0101-20612006000400006>
- Foran, J. A., Carpenter, D. O., Hamilton, M. C., Knuth, B. A., & Schwager, S. J. (2005). Risk-based consumption advice for farmed Atlantic and wild Pacific salmon contaminated with dioxins and dioxin-like compounds. *Environmental Health Perspectives*, 113(5), 552–556. <https://doi.org/10.1289/EHP.7626>
- Galli, F., & Iuliano, L. (2010). Do statins cause myopathy by lowering vitamin E levels? *Medical Hypotheses*, 74(4), 707–709. <https://doi.org/10.1016/j.mehy.2009.10.031>
- Garrett, E. S., Lima Dos Santos, C., & Jahncke, M. L. (1997). Public, Animal, and Environmental Health Implications of Aquaculture. *Emerging Infectious Diseases*, 3(4), 453–457. <https://doi.org/10.3201/EID0304.970406>

- Genschick, S., Mekkawy, W., Rossignoli, C., & Benzie, J. A. H. (2021). Growth performance of three strains of Nile tilapia (*Oreochromis niloticus*) on four different feeds in Western and Central Kenya. *Aquaculture Reports*, 20. <https://doi.org/10.1016/j.aqrep.2021.100701>
- Gouveia, A., & Davies, S. J. (1998). Preliminary nutritional evaluation of pea seal meal (*Pisum sativum*) for juvenile European sea bass (*Dicentrarchus labrax*). *Aquaculture*, 166(3–4), 311–320. [https://doi.org/10.1016/s0044-8486\(98\)00292-0](https://doi.org/10.1016/s0044-8486(98)00292-0)
- Hamid, N. K. A. (2021a). Sustainable Aquafeed: Alternative Ingredients Produced Locally as Nutrient Complementary in Minimizing the Use of Fishmeal. *Proceedings of the 2nd International Conference on Veterinary, Animal, and Environmental Sciences (ICVAES 2020)*, 12. <https://doi.org/10.2991/ABSR.K.210420.002>
- Hamid, N. K. A. (2021b). Sustainable Aquafeed: Alternative Ingredients Produced Locally as Nutrient Complementary in Minimizing the Use of Fishmeal. *Proceedings of the 2nd International Conference on Veterinary, Animal, and Environmental Sciences (ICVAES 2020)*, 12. <https://doi.org/10.2991/ABSR.K.210420.002>
- Hamid, N. K. A. (2021c). Sustainable Aquafeed: Alternative Ingredients Produced Locally as Nutrient Complementary in Minimizing the Use of Fishmeal. *Proceedings of the 2nd International Conference on Veterinary, Animal, and Environmental Sciences (ICVAES 2020)*, 12. <https://doi.org/10.2991/ABSR.K.210420.002>
- Hamre, K., & Lie. (1995). Minimum requirement of vitamin E for Atlantic salmon, *Salmo salar* L., at first feeding. *Aquaculture Research*, 26(3), 175–184. <https://doi.org/10.1111/J.1365-2109.1995.TB00900.X>
- Hamre, K., Waagbø, R., Berge, R. K., & Lie, Ø. (1997). Vitamins C and E interact in juvenile Atlantic salmon (*Salmo salar*, L.). *Free Radical Biology and Medicine*, 22(1–2), 137–149. [https://doi.org/10.1016/S0891-5849\(96\)00281-X](https://doi.org/10.1016/S0891-5849(96)00281-X)
- Harder, A. M., Ardren, W. R., Evans, A. N., Futia, M. H., Kraft, C. E., Marsden, J. E., Richter, C. A., Rinchar, J., Tillitt, D. E., & Christie, M. R. (2018). Thiamine deficiency in fishes: causes, consequences, and potential solutions. *Reviews in Fish Biology and Fisheries*, 28(4), 865–886. <https://doi.org/10.1007/S11160-018-9538-X>
- HEARN, T. L., SGOUTAS, S. A., HEARN, J. A., & SGOUTAS, D. S. (1987). Polyunsaturated Fatty Acids and Fat in Fish Flesh for Selecting Species for Health Benefits. *Journal of Food Science*, 52(5), 1209–1211. <https://doi.org/10.1111/J.1365-2621.1987.TB14045.X>
- Heather, B. (2022, March 7). *Evaluating the Effects of Thiamine Deficiency in Chinook Salmon* – Fish Conservation Physiology Lab. <https://fishconservationphysiologylab.faculty.ucdavis.edu/2022/03/07/evaluating-the-effects-of-thiamine-deficiency-in-chinook-salmon/>
- Hernández, E., Figueroa, J., & Iregui, C. (2009). Streptococcosis on a red tilapia, *Oreochromis* sp., farm: A case study. *Journal of Fish Diseases*, 32(3), 247–252. <https://doi.org/10.1111/J.1365-2761.2008.00981.X>
- Horn, T., Svendsen, L. B., & Nielsen, R. (1990). Brown-bowel syndrome: Review of the literature and presentation of cases. *Scandinavian Journal of Gastroenterology*, 25(1), 66–72. <https://doi.org/10.3109/00365529008999211>

- Hossain, S., Shefat, T., & Karim, M. A. (2018). Nutritional Diseases of Fish in Aquaculture and Their Management: A Review. *Acta Scientific Pharmaceutical Sciences*, 2, 2581–5423.
- Izquierdo, M. S., Turkmen, S., Montero, D., Zamorano, M. J., Afonso, J. M., Karalazos, V., & Fernández-Palacios, H. (2015). Nutritional programming through broodstock diets to improve utilization of very low fishmeal and fish oil diets in gilthead sea bream. *Aquaculture*, 449, 18–26. <https://doi.org/10.1016/j.aquaculture.2015.03.032>
- Jennings, S., Stentiford, G. D., Leocadio, A. M., Jeffery, K. R., Metcalfe, J. D., Katsiadaki, I., Auchterlonie, N. A., Mangi, S. C., Pinnegar, J. K., Ellis, T., Peeler, E. J., Luisetti, T., Baker-Austin, C., Brown, M., Catchpole, T. L., Clyne, F. J., Dye, S. R., Edmonds, N. J., Hyder, K., ... Verner-Jeffreys, D. W. (2016). Aquatic food security: insights into challenges and solutions from an analysis of interactions between fisheries, aquaculture, food safety, human health, fish and human welfare, economy and environment. *Fish and Fisheries*, 17(4), 893–938. <https://doi.org/10.1111/FAF.12152>
- Kari, Z. A., Kabir, M. A., Dawood, M. A. O., Razab, M. K. A. A., Ariff, N. S. N. A., Sarkar, T., Pati, S., Edinur, H. A., Mat, K., Ismail, T. A., & Wei, L. S. (2022). Effect of fish meal substitution with fermented soy pulp on growth performance, digestive enzyme, amino acid profile, and immune-related gene expression of African catfish (*Clarias gariepinus*). *Aquaculture*, 546. <https://doi.org/10.1016/j.aquaculture.2021.737418>
- Kobayashi, T. (2010). Histopathological Features of Cultured Japanese Amberjack *Seriola quinqueradiata* with Ascites Occurring in the Winter. *Journal of Toxicologic Pathology*, 23(3), 165. <https://doi.org/10.1293/TOX.23.165>
- Kord, M. I., Maulu, S., Srour, T. M., Omar, E. A., Farag, A. A., Nour, A. A. M., Hasimuna, O. J., Abdel-Tawwab, M., & Khalil, H. S. (2022). Impacts of water additives on water quality, production efficiency, intestinal morphology, gut microbiota, and immunological responses of Nile tilapia fingerlings under a zero-water-exchange system. *Aquaculture*, 547, 737503. <https://doi.org/10.1016/J.AQUACULTURE.2021.737503>
- Landgraf, K., Schuster, S., Meusel, A., Garten, A., Riemer, T., Schleinitz, D., Kiess, W., & Körner, A. (2017). Short-term overfeeding of zebrafish with normal or high-fat diet as a model for the development of metabolically healthy versus unhealthy obesity. *BMC Physiology*, 17(1), 1–10. <https://doi.org/10.1186/S12899-017-0031-X>
- Lebold, K. M., Löhr, C. V., Barton, C. L., Miller, G. W., Labut, E. M., Tanguay, R. L., & Traber, M. G. (2013). Chronic vitamin E deficiency promotes vitamin C deficiency in zebrafish leading to degenerative myopathy and impaired swimming behavior. *Comparative Biochemistry and Physiology Part C: Toxicology & Pharmacology*, 157(4), 382–389. <https://doi.org/10.1016/J.CBPC.2013.03.007>
- Le, K. T., Fotedar, R., & Partridge, G. (2014). Selenium and vitamin E interaction in the nutrition of yellowtail kingfish (*Seriola lalandi*): physiological and immune responses. *Aquaculture Nutrition*, 20(3), 303–313. <https://doi.org/10.1111/ANU.12079>
- Li, N., Wang, R., Zhang, J., Fu, Z., & Zhang, X. S. (2009). Developing a knowledge-based early warning system for fish disease/health via water quality management. *Expert Systems with Applications*, 36(3), 6500–6511. <https://doi.org/10.1016/J.ESWA.2008.07.065>

- Lock, E. J., Waagbø, R., Wendelaar Bonga, S., & Flik, G. (2010). The significance of vitamin D for fish: A review. *Aquaculture Nutrition*, 16(1), 100–116. <https://doi.org/10.1111/J.1365-2095.2009.00722.X>
- Makwinja, R., & Geremew, A. (2020). Roles and requirements of trace elements in tilapia nutrition: Review. *Egyptian Journal of Aquatic Research*, 46(3), 281–287. <https://doi.org/10.1016/j.ejar.2020.05.001>
- Mathia, W. M., & Fotedar, R. (2012). Evaluation of boiled taro leaves, *Colocasia esculenta* (L.) Schott, as a freshwater shrimp, *Caridina nilotica* Roux protein replacement, in diets of Nile tilapia, *Oreochromis niloticus* (Linnaeus). *Aquaculture*, 356–357, 302–309. <https://doi.org/10.1016/J.AQUACULTURE.2012.05.002>
- McMurtrie, J., Alathari, S., Chaput, D. L., Bass, D., Ghambi, C., Nagoli, J., Delamare-Deboutteville, J., Mohan, C. V., Cable, J., Temperton, B., & Tyler, C. R. (2022). Relationships between pond water and tilapia skin microbiomes in aquaculture ponds in Malawi. *Aquaculture*, 558. <https://doi.org/10.1016/J.AQUACULTURE.2022.738367>
- Mente, E., Karalazos, V., Karapanagiotidis, I. T., & Pita, C. (2011). Nutrition in organic aquaculture: An inquiry and a discourse. *Aquaculture Nutrition*, 17(4). <https://doi.org/10.1111/J.1365-2095.2010.00846.X>
- Michel, R. L., Makdani, D. D., Huber, J. T., & Sculthorpe, A. E. (1972). Nutritional Myopathy Due to Vitamin E Deficiency in Calves Fed Fish Protein Concentrate as the Sole Source of Protein. *Journal of Dairy Science*, 55(4), 498–506. [https://doi.org/10.3168/JDS.S0022-0302\(72\)85523-1](https://doi.org/10.3168/JDS.S0022-0302(72)85523-1)
- Mugimba, K. K., Chengula, A. A., Wamala, S., Mwega, E. D., Kasanga, C. J., Byarugaba, D. K., Mdegela, R. H., Tal, S., Bornstein, B., Dishon, A., Mutoloki, S., David, L., Evensen, & Munang'andu, H. M. (2018). Detection of tilapia lake virus (TiLV) infection by PCR in farmed and wild Nile tilapia (*Oreochromis niloticus*) from Lake Victoria. *Journal of Fish Diseases*, 41(8), 1181–1189. <https://doi.org/10.1111/JFD.12790>
- Muin, H., & Taufek, N. M. (2022). Evaluation of growth performance, feed efficiency and nutrient digestibility of red hybrid tilapia fed dietary inclusion of black soldier fly larvae (*Hermetia illucens*). *Aquaculture and Fisheries*. <https://doi.org/10.1016/j.aaf.2022.09.006>
- Mukhopadhyay, P. K., & Rout, S. K. (1996). Effects of different dietary lipids on growth and tissue fatty acid changes in fry of the carp *Catla catla* (Hamilton). *Aquaculture Research*, 27(8), 623–630. <https://doi.org/10.1111/J.1365-2109.1996.TB01295.X/ABSTRACT>
- Munguti, J. M., Kim, J. D., & Ogello, E. O. (2014). An overview of Kenyan aquaculture: Current status, challenges, and opportunities for future development. *Fisheries and Aquatic Sciences*, 17(1), 1–11. <https://doi.org/10.5657/FAS.2014.0001>
- Mzula, A., Wambura, P. N., Mdegela, R. H., & Shirima, G. M. (2021). Present status of aquaculture and the challenge of bacterial diseases in freshwater farmed fish in Tanzania; A call for sustainable strategies. *Aquaculture and Fisheries*, 6(3), 247–253. <https://doi.org/10.1016/J.AAF.2020.05.003>
- Navia, J. M., & Hunt, C. E. (1976). Nutrition, Nutritional Diseases, and Nutrition Research Applications. *The Biology of the Guinea Pig*, 235–267. <https://doi.org/10.1016/B978-0-12-730050-4.50022-3>

- Nguyen, H. T., Kanai, K., & Yoshikoshi, K. (2002). Ecological investigation of *Streptococcus iniae* in cultured Japanese flounder (*Paralichthys olivaceus*) using selective isolation procedures. *Aquaculture*, 205(1–2), 7–17. [https://doi.org/10.1016/S0044-8486\(01\)00667-6](https://doi.org/10.1016/S0044-8486(01)00667-6)
- Opiyo, M. A., Marijani, E., Muendo, P., Odede, R., Leschen, W., & Charo-Karisa, H. (2018). A review of aquaculture production and health management practices of farmed fish in Kenya. *International Journal of Veterinary Science and Medicine*, 6(2), 141–148. <https://doi.org/10.1016/J.IJVSM.2018.07.001>
- Ottinger, M., Clauss, K., & Kuenzer, C. (2016). Aquaculture: Relevance, distribution, impacts and spatial assessments - A review. *Ocean and Coastal Management*, 119, 244–266. <https://doi.org/10.1016/j.ocecoaman.2015.10.015>
- Owatari, M. S., Cardoso, L., Pereira, S. A., Pereira, U. de P., Tachibana, L., Martins, M. L., & Mouriño, J. L. P. (2022). Laboratory-controlled challenges of streptococcosis in Nile tilapia using the oral route (infected-feed) for infection. *Fish and Shellfish Immunology*, 120, 295–303. <https://doi.org/10.1016/j.fsi.2021.11.039>
- Prabhu, P. A. J., Lock, E. J., Hemre, G. I., Hamre, K., Espe, M., Olsvik, P. A., Silva, J., Hansen, A. C., Johansen, J., Sissener, N. H., & Waagbo, R. (2019). Recommendations for dietary level of micro-minerals and vitamin D3 to Atlantic salmon (*Salmo salar*) parr and post-smolt when fed low fish meal diets. *PeerJ*, 2019(5). <https://doi.org/10.7717/PEERJ.6996>
- Rana, S., Hasan, M. N., Bari, A. Al, Shimul, S. A., Ahmed, S. I., & Nahid, S. A. Al. (2022). Problems and prospects of fish farming in the Chattogram Hill Tracts of Bangladesh: Community-based aquaculture might be a right choice. *Aquaculture and Fisheries*. <https://doi.org/10.1016/J.AAF.2022.04.002>
- Rider, S., Verlhac-Trichet, V., Constant, D., Chenal, E., Etheve, S., Riond, B., Schmidt-Posthaus, H., & Schoop, R. (2023). Calcifediol is a safe and effective metabolite for raising vitamin D status and improving growth and feed conversion in rainbow trout. *Aquaculture*, 568, 739285. <https://doi.org/10.1016/J.AQUACULTURE.2023.739285>
- Rohani, M. F., Tarin, T., Hasan, J., Islam, S. M. M., & Shahjahan, M. (2023). Vitamin E supplementation in diet ameliorates growth of Nile tilapia by upgrading muscle health. *Saudi Journal of Biological Sciences*, 30(2). <https://doi.org/10.1016/j.sjbs.2023.103558>
- Roh, H. J., Park, J., Kim, A., Kim, N., Lee, Y., Kim, B. S., Vijayan, J., Lee, M. K., Park, C. II, & Kim, D. H. (2020). Overfeeding-Induced Obesity Could Cause Potential Immuno-Physiological Disorders in Rainbow Trout (*Oncorhynchus mykiss*). *Animals: An Open Access Journal from MDPI*, 10(9), 1–15. <https://doi.org/10.3390/ANI10091499>
- Saha, N., Koner, D., & Sharma, R. (2022). Environmental hypoxia: A threat to the gonadal development and reproduction in bony fishes. *Aquaculture and Fisheries*, 7(5), 572–582. <https://doi.org/10.1016/j.aaf.2022.02.002>
- Saha, S., Ray, A. K., Sümbülü, S., Ununun, Y., Bağırşagından, B., İki, İ. E., Türü, B., Sonrası, F., Rohu, Y., Rohita, L., Besinsel, D., & Değerlendirilmesi, K. (2011). Evaluation of Nutritive Value of Water Hyacinth (*Eichhornia crassipes*) Leaf Meal in Compound Diets for Rohu, *Labeo rohita* (Hamilton, 1822) Fingerlings after Fermentation with Two Bacterial Strains Isolated from Fish Gut. *Turkish Journal of Fisheries and Aquatic Sciences*, 11, 199–207. <https://doi.org/10.4194/trjfas.2011.0204>

- Salin, K. R., & Arome Ataguba, G. (2018). Aquaculture and the Environment: Towards Sustainability. *Sustainable Aquaculture*, 1–62. https://doi.org/10.1007/978-3-319-73257-2_1
- Sarmiento, N. L. A. F., Martins, E. F. F., Costa, D. C., Mattioli, C. C., da Costa Julio, G. S., Figueiredo, L. G., Luz, M. R., & Luz, R. K. (2018). Reproductive efficiency and egg and larvae quality of Nile tilapia fed different levels of vitamin C. *Aquaculture*, 482, 96–102. <https://doi.org/10.1016/j.aquaculture.2017.08.035>
- Sealey, W. M., & Gatlin, D. M. (1999). Overview of Nutritional Strategies Affecting Health of Marine Fish. *Journal of Applied Aquaculture*, 9(2), 11–26. https://doi.org/10.1300/J028V09N02_02
- Shefat, S. H. T. (2018). Nutritional Fish Disease and Public Health Concern. *Poultry, Fisheries & Wildlife Sciences*, 6(2), 1–4. <https://doi.org/10.4172/2375-446X.1000199>
- Silverstone, A. M., & Hammell, L. (2002). Spinal deformities in farmed Atlantic salmon. *The Canadian Veterinary Journal*, 43(10), 782. [/pmc/articles/PMC339614/](https://doi.org/10.1139/cv-2002-0102)
- S., K., T., M., M., E., & T., O. (1981). Studies on the nutritional myopathy syndrome in cultured fishes, 3: A prophylaxis effect of vitamin E on nutritional myopathy in cultured puffers [Fugu pardala]. *Fish Pathology*. <https://doi.org/10.3/JQUERY-UI.JS>
- Syanya, F. J. (2018). An Investigation on Causal Elements for Project Sustainability among Selected Nongovernmental Organizations in the Education Sector: A Case Of Nairobi County. *IOSR Journal Of Humanities And Social Science (IOSR-JHSS)*, 23(1), 63–105. <https://doi.org/10.9790/0837-23010263105>
- Syanya, F. J., Mathia, W. M., & Harikrishnan, M. (2023a). Current Status and Trend on the Adoption of Fish Feed Additives for Sustainable Tilapia Aquaculture Production: A Review. *Asian Journal of Fisheries and Aquatic Research*, 22(3), 10–25. <https://doi.org/10.9734/AJFAR/2023/V22I3571>
- Syanya, F. J., Mathia, W. M., & Harikrishnan, M. (2023b). Quality and Safety Concerns of Farmed Tilapia Fish during Freezing and Frozen Storage: Review. *Asian Food Science Journal*, 22(6), 40–58. <https://doi.org/10.9734/AFSJ/2023/V22I6641>
- Tacon, A. G. J., & Metian, M. (2008). Global overview on the use of fish meal and fish oil in industrially compounded aquafeeds. Trends and future prospects. *Aquaculture*, 285(1–4), 146–158. <https://doi.org/10.1016/j.aquaculture.2008.08.015>
- Tacon, A. G. J., & Metian, M. (2013). Fish Matters: Importance of Aquatic Foods in Human Nutrition and Global Food Supply. *Reviews in Fisheries Science*, 21(1), 22–38. <https://doi.org/10.1080/10641262.2012.753405>
- Taddese, F., Huh, M. D., Bai, S. C., & Vijverberg, J. (2014). Histological changes of liver in overfed young Nile tilapia. *Journal of Fisheries and Aquatic Science*, 9(2), 63–74. <https://doi.org/10.3923/JFAS.2014.63.74>
- Toranzo, A. E., Magariños, B., & Romalde, J. L. (2005). A review of the main bacterial fish diseases in mariculture systems. *Aquaculture*, 246(1–4), 37–61. <https://doi.org/10.1016/j.aquaculture.2005.01.002>
- Vir, S. C. (2011). Vitamin A deficiency: Prevention and Control. *Public Health Nutrition in Developing Countries: Two Volume Set*, 432–472. <https://doi.org/10.1533/9780857093905.432>

- Waagbø, R. (2010). Water-soluble vitamins in fish ontogeny. *Aquaculture Research*, 41(5), 733–744. <https://doi.org/10.1111/J.1365-2109.2009.02223.X>
- Walkley, S. U., & Vanier, M. T. (2009). Secondary lipid accumulation in lysosomal disease. *Biochimica et Biophysica Acta (BBA) - Molecular Cell Research*, 1793(4), 726–736. <https://doi.org/10.1016/J.BBAMCR.2008.11.014>
- Wang, K., Wang, E., Qin, Z., Zhou, Z., Geng, Y., & Chen, D. (2016). Effects of dietary vitamin E deficiency on systematic pathological changes and oxidative stress in fish. *Oncotarget*, 7(51), 83869. <https://doi.org/10.18632/ONCOTARGET.13729>
- Wang, K., Wang, E., Qin, Z., Zhou, Z., Geng, Y., Chen, D., Wang, K., Wang, E., Qin, Z., Zhou, Z., Geng, Y., & Chen, D. (2016). Effects of dietary vitamin E deficiency on systematic pathological changes and oxidative stress in fish. *Oncotarget*, 7(51), 83869–83879. <https://doi.org/10.18632/ONCOTARGET.13729>
- Watanabe, T., Takeuchi, T., Wada, M., & Uehara, R. (1981). The Relationship between Dietary Lipid Levels and α -Tocopherol Requirement of Rainbow Trout. *NIPPON SUISAN GAKKAISHI*, 47(11), 1463–1471. <https://doi.org/10.2331/SUISAN.47.1463>
- Whitfield, K. C., Bourassa, M. W., Adamolekun, B., Bergeron, G., Bettendorff, L., Brown, K. H., Cox, L., Fattal-Valevski, A., Fischer, P. R., Frank, E. L., Hiffler, L., Hlaing, L. M., Jefferds, M. E., Kapner, H., Kounnavong, S., Mousavi, M. P. S., Roth, D. E., Tsaloglou, M. N., Wieringa, F., & Combs, G. F. (2018). Thiamine deficiency disorders: diagnosis, prevalence, and a roadmap for global control programs. *Annals of the New York Academy of Sciences*, 1430(1), 3–43. <https://doi.org/10.1111/NYAS.13919>
- Xu, J., Sheng, Z., Chen, N., Xie, R., Zhang, H., & Li, S. (2022). Effect of dietary fish meal replacement with spray dried chicken plasma on growth, feed utilization and antioxidant capacity of largemouth bass (*Micropterus salmoides*). *Aquaculture Reports*, 24. <https://doi.org/10.1016/j.aqrep.2022.101112>
- Xu, W., Mawolo, P. Y., Gao, J., Chu, L., Wang, Y., Nie, Z., Song, L., Shao, N., Gao, J., Xu, P., & Xu, G. (2021). Effects of supplemental effective microorganisms in feed on the growth, immunity, and appetite regulation in juvenile GIFT tilapia. *Aquaculture Reports*, 19. <https://doi.org/10.1016/J.AQREP.2020.100577>
- Yossa, R., Greiling, A. M., Basiita, R. K., Sakala, M. E., Baumgartner, W. A., Taylor, A., & Gatlin, D. M. (2021). Replacing fishmeal with a single cell protein feedstuff in Nile tilapia *Oreochromis niloticus* diets. *Animal Feed Science and Technology*, 281. <https://doi.org/10.1016/J.ANIFEEDSCI.2021.115089>
- Zhang, W., Zhao, J., Ma, Y., Li, J., & Chen, X. (2022). The effective components of herbal medicines used for prevention and control of fish diseases. In *Fish and Shellfish Immunology* (Vol. 126, pp. 73–83). Academic Press. <https://doi.org/10.1016/j.fsi.2022.05.036>
- Zheng, J., Zhang, W., Dan, Z., Cao, X., Cui, K., Zhu, S., Zhuang, Y., Mai, K., & Ai, Q. (2023). Effects of fish meal replaced by methanotroph bacteria meal (*Methylococcus capsulatus*) on growth, body composition, antioxidant capacity, amino acids transporters and protein metabolism of turbot juveniles (*Scophthalmus maximus* L.). *Aquaculture*, 562. <https://doi.org/10.1016/J.AQUACULTURE.2022.738782>