

## **Incidence and management of cystic calculi in dogs in and around Meerut**

### **Abstract:**

A total of 54 animals of either sex with cystic calculi were prospectively studied. Most often the mature adult dogs aged between 3 to 10 years were affected and the juveniles (<1 year) were less commonly affected. Prevalence was maximal in extreme winter and summer. Cystic calculi were diagnosed either by radiography or ultrasonography. All the dogs were given urinary alkalizer and calculolytic drugs to dissolve the calculi and the dogs with urinary obstruction were treated surgically by cystostomy. Majority of the cases showed uneventful recovery.

**Keywords:** Cystic calculi, cystotomy, calculolytic drugs, dogs, incidence, Meerut.

### **Introduction:**

Cystic calculi (urinary bladder stones) are a common condition responsible for retention and obstruction of urine in dogs (Dvorska *et al.*, 2016). The formation of cystic calculi is generally associated with precipitation and crystal formation of a variety of minerals (Stiller *et al.*, 2014) though it is a multifactorial disease (Ackerman, 2016). The sequence of events that triggers stone formation is not fully understood. Less water and high dietary intake of minerals and protein in association with highly concentrated urine may contribute to increased saturation of salts in the urine (Parivar *et al.*, 1996). Disease conditions such as bacterial infections in the urinary tract can also increase urine salt concentration (Weese *et al.*, 2021). The understanding of incidence is important for the treatment and prevention of urinary stones in dogs. Surgery is the primary treatment of obstructive urolithiasis (Larson, 1996). Surgical procedure of cystostomy

together with medical dissolution of calculi is considered an effective technique for resolution of calculi in small animals (Ewoldt *et al.*, 2006). Animals with prolonged obstruction have high morbidity due to subsequent uremia. Surgical management of such patients should be done very cautiously. In this study incidence of cystic calculi, their diagnosis and surgical and medical management in 54 cases was reported.

### **Material and Methods:**

All the cases were treated and examined as per standard treatment and examination protocols so the ethical approval was not necessary for this study. A total of 54 dogs of either sex with complaint of dribbling of urine, urinary retention and urinary obstruction were prospectively studied (**Table.1**). These cases were presented to Veterinary Clinical Complex, College of Veterinary and Animal Sciences, SVPUA&T, Meerut from the adjoining areas between the years 2018-2021. Physical examination was done to check the status of the urinary bladder. Further, radiography or ultrasonography was performed to establish the diagnosis (**Fig.1 A and B**). All the animals with urinary obstruction were treated surgically by cystotomy technique and animals with dribbling of urine were treated by urinary alkalizer and calculolytic drugs.

After the confirmation of calculi in urinary bladder, all the animals were aseptically prepared for surgery and administered general anesthesia. The surgical interventions were done by keeping dogs in dorsal recumbency. Intravenous infusion of normal saline was maintained during surgery. An about 5-6 c.m. long mid line (in females) and right paramedian skin incision lateral to penis was given (in males). Penis along with incised skin was retracted to the left lateral side till the midline was visualized followed by routine laparotomy in caudal abdomen. The distended urinary bladder was located and exteriorized (**Fig. 2A**). The urine in the bladder was

removed by suction through a sterile syringe. Then an incision was given on the dorsal aspect of the urinary bladder to reach the lumen. The lumen was searched for calculi/concretions and then the calculi were removed (**Fig.2 B**) and the lumen of the urinary bladder was flushed with normal saline. A sterile polyethylene catheter was passed from urinary bladder through urethra to check the urethral patency. If, the urethra was found obstructed, urethrotomy was also performed to remove concretions/calculi. A sterile polyethylene catheter (infant feeding tube) was passed from external urethral orifice to urinary bladder. The external end of catheter was kept fixed with preputial skin by stay sutures. Cystotomy, urethrotomy and laparotomy wounds were closed, dressed and protected in routine manner.

Postoperatively, amoxicillin-sulbactam antibiotic combination (15 mg/kg, IM) for 5 days, analgesic meloxicam (0.2 mg/kg, IM) for 3-5 days and antacid pantoprazole (1 mg/kg, PO) for 5 days were administered. The urethral catheter was removed on 8-12 days and skin sutures were removed after healing of the wounds generally on 12<sup>th</sup> day.

In animals with dribbling of urine and diagnosed with very fine concretions in the urinary bladder, a sterile polyethylene catheter (infant feeding tube) was passed to urinary bladder from urethra to dislodge and push back any concretions. Catheter was secured to preputial skin and urinary flow was maintained. After this maneuver, all the affected animals were given urinary alkalizer disodium hydrogen citrate (Syp. Alkasol) and calculolytic drug Tab. Cystone till the cystic concretions not seen ultrasonographically and the catheter was removed accordingly.

## **Result and Discussion:**

Cases of cystic calculi were more prevalent in the extreme winter and summer. Mature adult dogs (3-10 years) 48% were most affected followed by young adult dogs (1-3 years) 28%

and juvenile dogs (<1 year) 11% were least affected followed by geriatric dogs (>10 years) 13% (**Fig. 3**). Anesthesia, cystotomy and urethrotomy procedures along with catheterization of urinary bladder and fixation of external end of catheter with preputial skin were achieved without difficulties. Majority of the dogs showed uneventful recovery except few minor incidences of infection and pus formation at surgical sites.

Cystic calculi are a common problem in dogs (Ling *et al.*, 1998) and seen mostly in extreme winter and summer (Singh *et al.*, 2011). This may be associated to less water intake and more water losses during winter and summer, respectively. Diagnosis of cystic calculi can be made either by radiography or ultrasonography. Sometimes, diagnosis of the cystic calculi by radiography becomes difficult, if they are radiolucent (Larson, 2009) or very fine. By ultrasonography, radiolucent and very fine calculi/concretions can be diagnosed easily as hyperechoic structures showing acoustic shadowing below them. Acoustic shadowing distal to floating calculi/concretions was not seen. Similar findings were also reported by Verma *et al.* (2006) and Dehmiwal *et al.* (2016). Surgery is the primary treatment for obstructive cystic calculi except very fine calculi/concretions which can be managed by urinary alkalizares and calculolytic drugs. Nutritional management may reduce the occurrence of calculi formation significantly in the dogs.

### **Conclusion:**

In this study, incidence of cystic calculi in dogs in and around Meerut was recorded. Such cases were managed by surgery and medicinal treatment effectively after diagnosing either by radiography or ultrasonography. Further, elaborative research is required on nutritional management to prevent the occurrence of the urolithiasis in dogs.

## References:

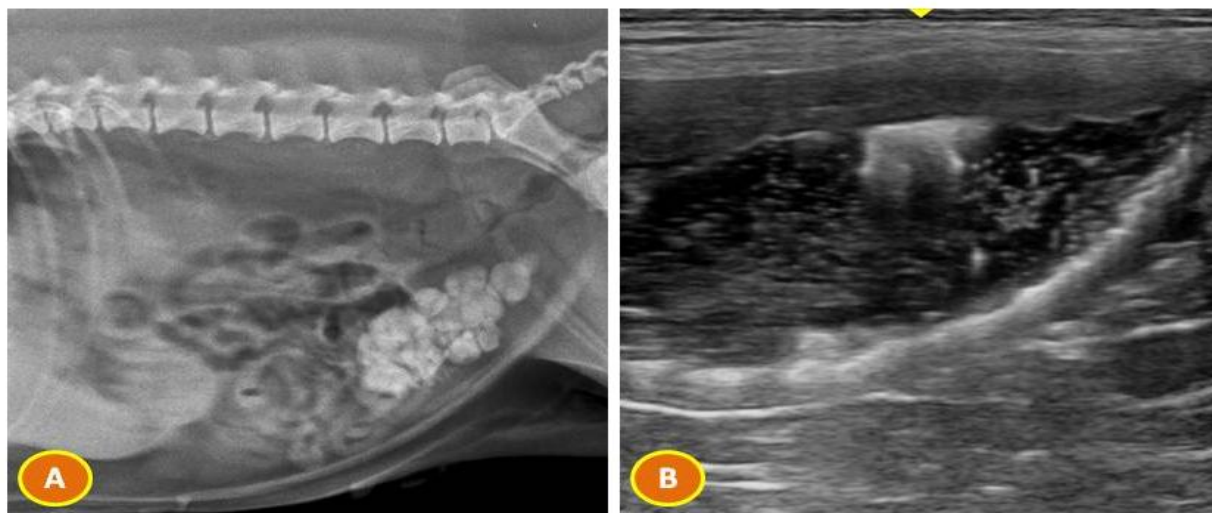- Ackerman, N., (2016). Nutritional management of canine urolithiasis. *The Veterinary Nurse*, 7(1), pp.12-17.
- Dehmiwal, D., Behl, S.M., Singh, P., Tayal, R., Pal, M., Saharan, S. and Chandolia, R.K., (2016). Diagnosis and surgical management of cystolith in dogs. *Haryana Vet*, 55(1), pp.103-105.
- Dvorska, J. and Saganuwan, S.A., 2015. A review on urolithiasis in dogs and cats. *Bulgarian Journal of Veterinary Medicine*, 18(1).
- Ewoldt JM, Anderson DE, Miesner MD, Saville WJ (2006). Short- and long-term outcome and factors predicting survival after surgical tube cystostomy for treatment of obstructive urolithiasis in small ruminants. *Veterinary Surgery*, 35: 417-422
- Larson BL (1996). Identifying, treating, and preventing bovine urolithiasis. *Veterinary Medicine* 91, 366-377.
- Larson, M.M. (2009). The Kidneys and Ureters. In: BSAVA Manual of Canine and Feline Abdominal Imaging. O'Brien, R. and Barr, F. (eds.). British Small Animal Veterinary Association, Gloucester.
- Ling, G.V., Ruby, A.L., Johnson, D.L., Thurmond, M. and Franti, C.E. (1998). Renal calculi in dogs and cats: prevalence, mineral type, breed, age and gender interrelationships (1981-93). *Internal Med*.12: 11-21.
- Parivar, F., Low, R.K. and Stoller, M.L., 1996. The influence of diet on urinary stone disease. *The Journal of urology*, 155(2), pp.432-440.

- Stiller, A.T., Lulich, J.P. and Furrow, E., 2014. Urethral plugs in dogs. *Journal of veterinary internal medicine*, 28(2), pp.324-330.
- Singh, T., Kinjavdekar, P., Aithal, H.P., Pawde, A.M., Pratap, K. and Mukherjee, R., (2011). Obstructive urolithiasis in domestic animals: A study on pattern of occurrence and etiology.
- Verma, P., Mohindroo, J., Singh, S.S. and Singh, C.B. (2006). Sonographic findings in affections of urinary system in dogs. *Indian J. Vet. Surg.* 27(2): 104-107.
- Weese, J.S., Blondeau, J., Boothe, D., Guardabassi, L.G., Gumleyg, N., Papichh, M., Jesseni, L.R., Lappinj, M., Rankin, S., Westropp, J.L. and Sykes, J. (2021). International Society for Companion Animal Infectious Diseases (ISCAID) guidelines for the diagnosis and management of bacterial urinary tract infections in dogs and cats. *Journal of Japanese Association of Veterinary Nephrology and Urology*, 13(1), pp.46-63.

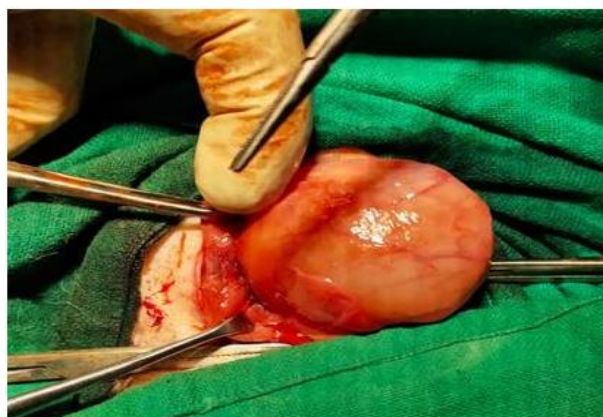**Table: 1. Incidence of cystic calculi as per the age groups.**

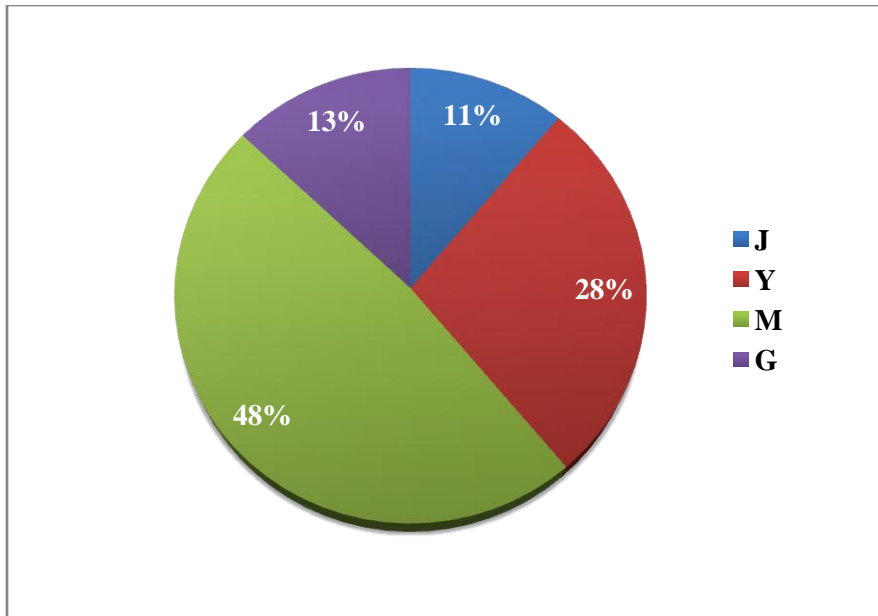
S.No.	Age group	Group code	Number of cases
1.	Juvenile (<1 year)	J	06
2.	Young adult (1-3 years)	Y	15
3.	Mature adult (3-10 years)	M	26
4.	Geriatric (>10 years)	G	07
<b>Total</b>			<b>54</b>

**Legends of the figures:**



**Figure: 1. Radiographic (A) and ultrasonographic (B) diagnosis of cystic calculi in dogs.**





**Figure: 3. Incidence of cystic calculi in different age groups.**

UNDER PEER REVIEW