

PAPULAR URTICARIA: Insights into non—IgE-mediated hypersensitivity reactions produced by stings of *Culex spp* and *Aedes spp* in patients with Intrinsic Atopic Dermatitis

Authors' contributions

This work was carried out in collaboration among all authors. The author CEO designed the study and wrote the protocol; the first draft of the manuscript and managed the literature searches. Author ESM extracts the studied allergens. Authors DGP, APMT, JLSS, GSB, and RPSL performed laboratory research. Author RAPGS performed cutaneous tests. All authors read and approved the final manuscript.

Article Information

Open Peer Review History:

This journal follows the Advanced Open Peer Review policy. Identity of the Reviewers, Editor(s) and additional Reviewers, peer review comments, different versions of the manuscript, comments of the editors, etc are available here:

Original Research Article

ABSTRACT

Aims: To evaluate the contribution of non—IgE-mediated hypersensitivity mechanisms in Papular Urticaria produced by *Aedes spp* and *Culex spp* bites in patients diagnosed with Intrinsic Atopic Dermatitis coming from an urban (not beachy) Brazilian region.

Study Design: To better understand the relationship between Papular Urticaria and Atopic Dermatitis, we revisit, through a retrospective chart review, the precipitins titrations and the *ex vivo* challenge tests against *Aedes spp* and *Culex spp* body extracts performed in patients with non—IgE-mediated Papular Urticaria who also were diagnosed with Intrinsic Atopic Dermatitis.

Place and Duration of Study: Instituto Alergoimuno de Americana – São Paulo – Brazil – between January 2018 and March 2023.

Methodology: We examined the medical charts of a population of 48 patients diagnosed with Intrinsic Atopic Dermatitis and non—IgE-mediated Papular Urticaria who were investigated through the research of precipitins and/or the Leukocyte Adherence Inhibition Test (LAIT) against *Aedes spp* and *Culex spp* body extracts. Cascade distribution charts were mounted with the range groups of Leukocyte Adherence Inhibition (LAI) results of *ex vivo Culex spp* and *Aedes spp* body extract challenges monitored by LAIT.

Results: The Cascade distribution charts showed a very wide distribution of results of LAIT performed with the *Culex spp*. However, most results (66.7%) were distributed above a 40% LAI, which suggests it may possess a good potential for the LAIT as a diagnostic indicator. However,

the Cascade distribution charts for the LAIT performed with *Aedes spp* showed 100% of the cases with an LAI above 40%, which suggests it may possess an excellent potential as a diagnostic indicator. There was only one case where the precipitins research was negative for both allergens. **Conclusion:** Our results support the fact that there is a strong relationship between non—IgE-mediated Papular Urticaria and Intrinsic Atopic Dermatitis, which probably share a common immune physiopathology.

Keywords: Aedes spp; Culex spp; Culicidae; allergy; intrinsic atopic dermatitis; hypersensitivity; immune complexes; mosquitoes; papular urticaria.

1. INTRODUCTION

Hypersensitivity reactions to arthropods are a common cause of allergic disease in the tropics [1]. Vertebrate reactions to arthropod bites can manifest in a variety of ways. Most individuals present a transient wheal and erythema, while others present persistent papular, vesicular, pustular, ulcerated, or even necrotic reactions that appear several hours after the biting [2]. These lesions may be due to mechanical trauma, secondary infections, naturally injurious substances, and/or the presence of harmless substances to which the host had previously developed a hypersensitivity reaction [3]. Papular Urticaria (PU) is the denomination attributed to persistent hypersensitivity reactions elicited by biting, stinging, or urticating arthropods [4]. This disease is produced by a delayed hypersensitivity reaction characterized by the presence of pruritic skin lesions such as papules (or wheals), vesicles, blisters, and scabs. This clinical presentation is sometimes called "*Prurigo Strophulus*", or simply "*Strophulus*" as it was first described in 1813 when Dermatology was primarily a descriptive science and there was no consensus about the causes of this condition [5-7]. Lesions originating from arthropod biting may resolve after some minutes or evolve into a chronic condition with secondary infections and scarring with hypo or hyperchromic pigmentation that may persist for years [8]. The delayed non—IgE-mediated immune reactions developed after the arthropods' salivary proteins are quite different from the IgE-mediated immediate reactions produced by the venom proteins inoculated by the Hymenoptera order, which are not produced to facilitate the acquirement of blood, but instead are more adequate to produce pain and inflammation for the defense of the hive or the anthill [9-11]. Hematophagous vectors usually have anticoagulants, platelet aggregation inhibitors, and vasodilators in their saliva [12]. This complex salivary protein mixture injected into the skin of the subject elicits a sequence of immune reactions. Each different immune reaction may be mounted against a different salivary antigen. In 1946 Mellanby proposed a four-stage evolution for the human's reactions to mosquito bites, according to the presence or absence of immediate and delayed reactions after the biting [13]. In most individuals, these reactions are self-limited, in others these reactions may persist through a sequence of hypersensitivity reactions that may be IgE-mediated and/or non—IgE-mediated, as suggested by the immune complexes present at the persistent lesions [14]. The first immune reaction produced by the host against the arthropod saliva is the classical inflammatory triple response of Lewis: pain, redness, and heat [15]. This autacoid-induced vasodilatation reaction usually disappears after a few minutes and may be inhibited by the use of antihistamines and steroids [16]. The subsequent severity and duration of the response are related to the further host's responses against the salivary or contacting proteins. The triple response of Lewis is the basis of the immediate reading skin-allergy tests. The diagnosis of the IgE-mediated reactions can also be inferred by the detection on the patient's serum, by ELISA or Immunoblot, of the free specific IgE able to link to natural or recombinant salivary proteins [17]. However, most patients do not show evidence of serum specific IgE at all. A Gell & Coombs type III hypersensitivity reaction mediated by immune complexes activated by the complement system is suggested by the presence of granular deposits of C1q, C3, and IgM in the dermal blood vessels with histological vasculitis [18]. Several biting arthropods were reported to present salivary agents liable for producing immune responses associated with PU, such as the cat flea (*Ctenocephalides felis*), the dog flea (*C. canis*), the rat flea (*Xenopsylla cheopis*), the human flea (*Pulex irritans*), the bedbug (*Cimex lectularius*), bush-mites (ticks and chiggers), rodent mites (*Ornithonyssus bacoti*), avian mites (*Germanicus gallinae*; *Ornithonyssus sylviarum*), and mosquitoes (*Culex spp*; *Aedes spp*; *Anopheles spp*), among others [19-26]. The most succeeded hematophagous synanthropic species from the *Culicidae* family (mosquitoes) developing in our tropical urban proximity belong to the genera *Aedes* and *Culex* [27]. Blood-feeding insects from the genera *Culex* and *Aedes* are endemic vectors in our region, which besides the transmission of infectious diseases, may develop hypersensitivity reactions in allergic patients, clinically manifested as

PU [28]. The literature describes an association of PU with Atopic Dermatitis (AD) and several allergic comorbidities [29, 30]. In our outpatient clinic, we are visited by several allergic patients with severe AD who also have mild or moderate PU; or, sometimes, allergic patients who have severe PU who also have mild or moderate AD. A few patients present severe AD and severe PU that mixed into an overlapping disease, usually infected by bacteria, that turns into a difficult control condition. The severity of these diseases varies over time. At a given moment, the AD can be more uncomfortable for the patient than the PU, at other times, the PU is more troublesome than the AD. Usually, it seems that one condition aggravates the other, mainly when delayed or non—IgE-mediated hypersensitivity mechanisms are at play [31, 32]. To extrapolate the influence of the IgE-mediated reactions, we focused our attention only on patients with no evidence of increased Total IgE and undetectable specific IgE against every tested allergen, including the mosquitoes' extracts. This might be the equivalent of the diagnosis of the "intrinsic" atopic conditions when the hypersensitivity reactions are not due to the presence of IgE [33, 34]. So, our diagnosis of Intrinsic Atopic Dermatitis (IAD) does not refer to an absence of an eliciting allergen, but to the absence of the Gell & Coombs Type I hypersensitivity mechanism [35]. To explore these hypersensitivity mechanisms which present in common the absence of the influence of the IgE, we select this setting of patients with both diagnoses of IAD and PU. To study this interrelationship, we conducted a retrospective chart review of patients that were diagnosed with these two conditions at our outpatient facility to get insights into their conjoint physiopathology.

2. MATERIALS AND METHODS

2.1 Subjects

After receiving Institutional Review Board approval, from the Instituto Alergoimuno de Americana (Brazil), we proceed with a chart review of a population of 7,035 allergic patients, from which 48 (0.68%) fulfilled the criteria for the diagnosis of non—IgE-mediated PU and IAD. This was a very diversified cohort with 33 females; mean age 26.5 years; SD 22.5 years; range 1 to 73 years; mode = 1 year (appeared 5 times); geometric mean = 13.5 years.

2.2 Antigen Extraction

Whole-body extracts of *Culex spp* and *Aedes spp* were prepared by crushing and grinding whole-body parts of frozen mosquitoes, after which allergen extraction was performed in PBS buffer (pH 7.4) for 24 hours and centrifuged at 8,820 g for 30 min. The supernatant was collected and served for the subsequent procedures [36].

2.3 *In vivo* Investigation: Skin Scrape Test

All patients were submitted to immediate reading allergic skin tests, by the Skin Scrape Test, as previously reported [37]. Shortly, to scrape the skin, we used the bevel of a sterilized and disposable 18-G 1½ (1.20 x 40) hypodermic needle (standard bevel) whit movements repeated until the health care professional observed a thin homogeneous desquamation or slight hyperemia. The allergen solutions are applied after scraping; the allergen solution remained on the skin to allow absorption until the final reading is made at 15 minutes. At this time, the wheal's longest diameter (WLD) was assessed. We perform a negative control to draw the cut-offs for positive and negative tests. A wheal reaction was defined as positive if the WLD was ≥ 3 mm 15 minutes after the application of the allergen extracts and after the subtraction of each patient's reaction to the negative control.

2.4 *Ex vivo* Investigation: Leukocyte Adherence Inhibition Test

Some patients were submitted to the *ex vivo* challenge tests monitored by the Leukocyte Adherence Inhibition Test (LAIT), against total body extracts of *Aedes spp* and *Culex spp* to evaluate Gell & Coombs type II and type III hypersensitivity reactions. The LAIT was performed as previously described [38]. Shortly, each donor's fresh plasma was divided into two parts and used in paralleled *ex vivo* challenging tests with *Culex spp* or *Aedes spp* body extract and the unchallenged plasma assay. The plasma with high leukocyte content (buffy coat) was collected from the heparinized tube after one hour of sedimentation at 37 °C and aliquots of 100 μ L were distributed into Eppendorf tubes kept under agitation for 30 minutes (200 rpm at 37 °C) with (or without, as used as control) antigen

extract (10 μ L of a solution with 1mg/mL and pH 7.5). After incubation, the plasma was allocated into a standard Neubauer hemocytometer counting chamber with a plain, non-metallic glass surface and left to stand for 2 hours at 37 °C in the humidified atmosphere of the covered water bath to allow leukocytes to adhere to the glass. Next, leukocytes were counted, the coverslip was removed, and the chamber was washed by immersion in a beaker with PBS at 37 °C. A drop of PBS was added to the hemocytometer's chamber and a clean coverslip was placed over it. The remaining cells were counted in the same squares as previously examined. The percentage of Leukocyte Adherence (LA) of each assay was estimated as: (the number of leukocytes observed on the hemocytometry chamber after washing divided by the number of leukocytes observed on the hemocytometry chamber before washing) and multiplied by 100 (%). The Leukocyte Adherence Ratio (LAR) was estimated based on the ratio between the LA from the antigen-specific challenged groups and the LA from the unchallenged control group: $LAR = LA \text{ of the challenged sample} / LA \text{ of unchallenged control sample}$; multiplied by 100 (%). To further calculate the Leukocyte Adherence Inhibition (LAI) the LAR was subtracted from 100 (%).

2.5 *In vitro* Investigation: Titration of tube precipitins

Five patients were submitted to the titration of tube precipitins, according to the suspected allergens identified by anamnesis. The tube precipitin titration was performed as previously described [39]. Shortly, the patient's blood was collected in a clot-activator collecting tube. After serum separation, the tube was centrifugated at 2,000 rpm for 10 minutes. The allergen extracts were allocated in sets of eleven glass tubes at progressive duplicated serum dilutions. The progressive dilutions were combined with the 15 μ L of the antigen (1 mg/mL) with 250 μ L of the patient's serum, progressively diluted into physiological saline solution (NaCl 0,9%) in the dilution ratios of 1:1; 1:2; 1:4; 1:8; 1:16; 1:32; 1:64; 1:128; 1:256 and 1:512. The first tube was a blank control done just with the serum to observe occasional spontaneous precipitation (cryoglobulins). After 24 hours, the tubes were examined by one of us, and the titers (the highest dilution factor that yields a positive reading) were recorded.

3. RESULTS

3.1 Allergic skin tests

The patients were selected by the absence of immediate response to the cutaneous allergic skin tests performed with a panel of common allergens, including insects, foods, and respiratory allergens.

3.2 Total and specific IgE

The patients were selected by detection of the total IgE inside the normal ranges provided by the reference laboratory and undetectable levels of specific IgE against a panel of common allergens, including insects, foods, and respiratory allergens performed by ImmunoCAP[®].

3.3 Immunoassay Results

As a retrospective survey, there was no research protocol, therefore we report the incidental immune investigation as registered in the medical charts.

The most investigated *ex vivo* challenge was performed via the TIAL against *Culex spp.* There were 39 tests in which results varied from 0% Leukocyte Adherence Inhibition (LAI) to 100% LAI. See Figure 1.

The *ex vivo* challenge was also performed via the TIAL against *Aedes spp.* There were 18 tests in which results varied from 43% Leukocyte Adherence Inhibition (LAI) to 100% LAI. See Figure 2.

The Cascade distribution charts showed a very wide distribution of results, mainly for the LAIT performed with the *Culex spp.* However, most results (66.7%) were distributed above a 40% LAI, which suggests it may possess a good potential for the LAIT as a diagnostic indicator. However, the

Cascade distribution charts for the LAIT performed with *Aedes spp* showed 100% of the cases with an LAI above 40%, which suggests it may possess an excellent potential as a diagnostic indicator.

The most intensively investigated case was a 34 years-old woman whose TIAL was 92% LAI for *Culex spp* and 85% LAI for *Aedes spp*. The precipitins research was negative for both allergens.

There were also two female patients (35 and 39 years old) investigated with precipitins for *Culex spp* whose results were both positive for 1:32.

There was a female patient (26 years old) investigated with precipitins for *Culex spp* (positive for 1:8) and for *Aedes spp* (positive for 1:32).

There was a male patient (7 years old) investigated with precipitins for *Culex spp* (positive for 1:128) and for *Aedes spp* (positive for 1:256).

There was a male patient (1-year-old) investigated with precipitins for *Culex spp* (positive for 1:512) and for *Aedes spp* (positive for 1:8).

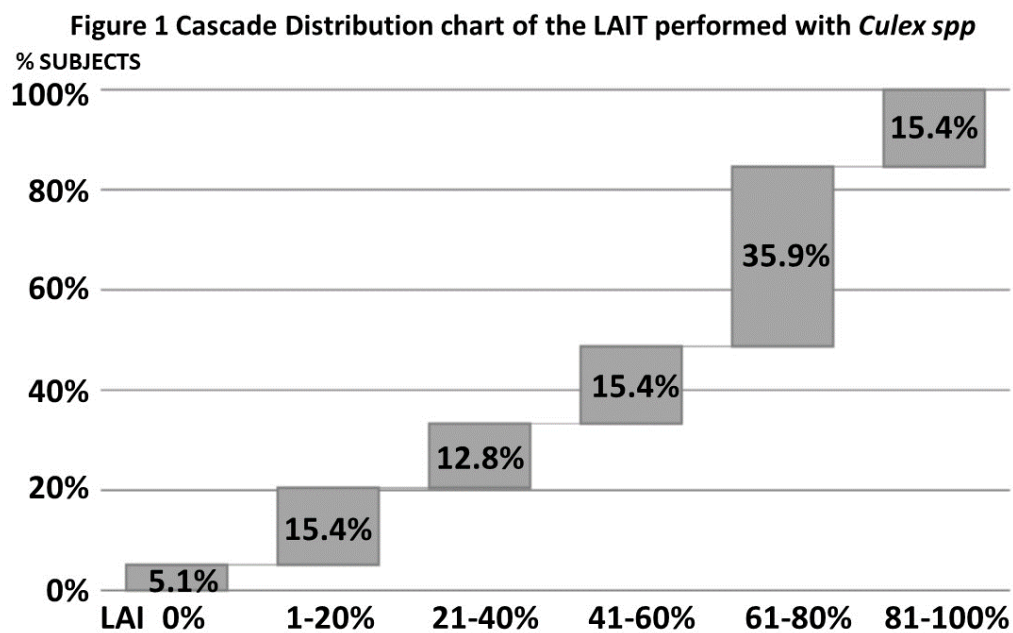


Fig. 1. Cascade distribution chart of the range groups of Leukocyte Adherence Inhibition (x-axis) results (%) of ex vivo *Culex spp* body extract challenges monitored by Leukocyte Adherence Inhibition Tests, according to the respective percentage of results over 39 tests (y-axis) performed on patients with non-IgE-mediated Papular Urticaria and Intrinsic Atopic Dermatitis.

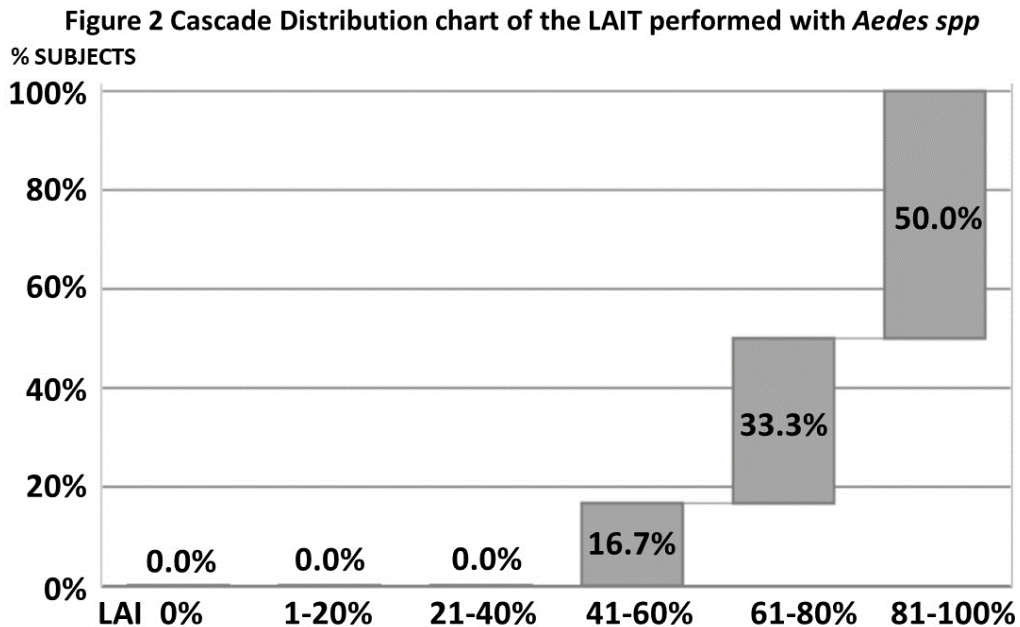


Fig. 2. Cascade distribution chart of the range groups of Leukocyte Adherence Inhibition (x-axis) results (%) of ex vivo *Aedes spp* body extract challenges monitored by Leukocyte Adherence Inhibition Tests, according to the respective percentage of results over 18 tests (y-axis) performed on patients with non—IgE-mediated Papular Urticaria and Intrinsic Atopic Dermatitis.

4. DISCUSSION

The non—IgE-mediated hypersensitivities diseases are a diagnostic challenge to clinicians. Practically every IgE-mediated hypersensitivity reaction has a non—IgE-mediated counterpart that sometimes presents very similar symptoms, almost indistinguishable from the IgE-mediated diagnosed condition [31]. Probably, this is because hardly a hypersensitivity reaction is purely IgE-mediated. The IgE elicits an immediate response, mainly by the release of histamine, a rapidly metabolized autacoid, that after stimulating the histamine receptors is soon degraded by the histaminases. However, IgE-dependent mast cell degranulation releases not only histamine but several other autacoids responsible for the late-phase reactions, such as prostaglandins and leukotrienes, responsible for the persistent symptoms [32]. What experience has shown us is that the IgE-mediated response is not needed for the appearance of the delayed response, which is then called a non—IgE-mediated hypersensitivity reaction [40]. For a long time, the medical community cultivated the “IgE paradigm” that limited the perception of a hypersensitivity reaction to the presence of IgE. Nowadays most physicians have been liberated from this limiting idea but are yet limited by the poverty of resources to perform the etiologic diagnosis of the non—IgE-mediated hypersensitivity reaction. PU is a clinical pathological presentation of a Gell & Coombs type III hypersensitivity reaction mediated by immune complexes, subsequent activation of the Complement System, and the production of anaphylatoxins [41]. The demonstration of the inhibition of the leukocyte adherence by the causative allergen also suggests a Gell & Coombs type II hypersensitivity reaction. The evolution of PU lesions is very similar to the clinical presentation of Intrinsic Atopic Dermatitis that was also diagnosed in our patients. The PU reactions also may produce cutaneous lesions very similar to the Urticarial Vasculitis (UV), another Gell and Coombs type III reaction classified as a “vasculitidis” i.e., a disease produced by vascular or peri-vascular inflammation (vasculitis) [42]. Patients with UV present indurated wheals with a duration greater than 24 hours, palpable purpura, and hyperpigmentation left behind, sometimes indistinguishable from the PU lesions [43]. These three conditions (UV, IAD, and PU) are clinically very similar and constitute a differential diagnosis among themselves. Probably they share a common physiopathology that may be suspected using laboratory tools such as the research of precipitins or ex vivo challenge tests performed with the help of the LAIT. Our results show that there is a potential

for the employ of *ex vivo* tests such as the LAIT and *in vitro* tests such as the research of serum precipitins against the Culicidae allergens in the suspicion of Papular Urticaria, mainly in patients with IAD.

5. CONCLUSION

Our preliminary results suggest that there is a big field to be exploited in larger cohorts to prove a relationship between Intrinsic Atopic Dermatitis and Papular Urticaria; as well as the employment of the research of precipitins and the Leukocyte Adherence Inhibition Test to demonstrate a non—IgE-mediated immune mechanism responsible for them.

CONSENT

It is not applicable.

ETHICAL APPROVALS

As per international standards written ethical approval has been collected and preserved by the authors.

ACKNOWLEDGEMENTS

This work was funded by the Instituto Alergoimuno de Americana.

COMPETING INTERESTS

The authors have declared that no competing interests exist.

REFERENCES

- [1] L. Caraballo, J. Zakzuk, B.W. Lee, N. Acevedo, J.Y. Soh, M. Sánchez-Borges, E. Hossny, E. García, N. Rosario, I. Ansotegui, L. Puerta, J. Sánchez, V. Cardona, Particularities of allergy in the Tropics, *World Allergy Organ J*, 9 (2016) 20.
- [2] R.M. Gordon, Reactions produced by arthropods directly injurious to the skin of man, *Br Med J*, 2 (1950) 316-318.
- [3] B. Heilesen, Studies on mosquito bites, *Acta Allergol*, 2 (1949) 245-267.
- [4] J.G. Demain, Papular urticaria and things that bite in the night, *Current Allergy and Asthma Reports*, 3 (2003) 291-303.
- [5] E.A. Kouotou, U. Nguena Feungue, A. Engolo Fandio, D.N. Tounouga, E.C. Ndjitoyap Ndam, Prurigo strophulus: Epidemiological, clinical aspects and environmental factors among children in Yaoundé, Cameroon (Sub-Saharan Africa), *Skin health and disease*, 1 (2021) e38.
- [6] L. Stingeni, K. Hansel, G. Casciola, L. Bianchi, M. Tramontana, R. Marietti, S. Zampetti, F. Napoli, G. Miñón Llera, F. Biancolini, R. Romani, M. Sevarika, P. Masini, Human ectoparasitosis by mites of the genus *Pyemotes* Amerling 1861 (Acarina: Pyemotidae), *Italian journal of dermatology and venereology*, 158 (2023) 4-14.
- [7] B. T., *A practical synopsis of cutaneous disease.*, Longman, Hirst, Rees, Orme and Brown, London, 1813.
- [8] C.J. Steen, P.A. Carbonaro, R.A. Schwartz, Arthropods in dermatology, *J Am Acad Dermatol*, 50 (2004) 819-842, quiz 842-814.

- [9] M.L. Bazon, L.G.R. Fernandes, I.O.S. Assugeni, L.M. Pinto, P.U. Simioni, R.L. Zollner, M.R.B. Braga, Biological and Inflammatory Effects of Antigen 5 from *Polybia paulista* (Hymenoptera, Vespidae) Venom in Mouse Intraperitoneal Macrophages, *Toxins* (Basel), 13 (2021).
- [10] D.M. Abram, L.G.R. Fernandes, A. Perez-Riverol, M. Regina Brochetto-Braga, R.L. Zollner, Cross-Reactive Carbohydrate Determinant in *Apis mellifera*, *Solenopsis invicta* and *Polybia paulista* Venoms: Identification of Allergic Sensitization and Cross-Reactivity, *Toxins* (Basel), 12 (2020).
- [11] D.L. Justo Jacomini, S.M. Gomes Moreira, F.D. Campos Pereira, L. Zollner Rde, M.R. Brochetto Braga, Reactivity of IgE to the allergen hyaluronidase from *Polybia paulista* (Hymenoptera, Vespidae) venom, *Toxicon*, 82 (2014) 104-111.
- [12] J.M.C. Ribeiro, B. Arcà, Chapter 2 From Sialomes to the Sialoverse: An Insight into Salivary Potions of Blood-Feeding Insects, *Advances in Insect Physiology*, Academic Press. 2009, pp. 59-118.
- [13] K. Mellanby, Man's reaction to mosquito bites, *Nature*, 158 (1946) 554.
- [14] J.O. Alexander, Papular urticaria and immune complexes, *J Am Acad Dermatol*, 12 (1985) 374-375.
- [15] T. Lewis, R.T. Grant, Vascular reactions of the skin to injury Part II The liberation of a histamine-like substance in injured skin, the underlying cause of factitious urticaria and of wheals produced by burning, and observations upon the nervous control of certain skin reactions, *Heart*, 11 (1924) 209-265.
- [16] J.M. Ribeiro, I.M. Francischetti, Role of arthropod saliva in blood feeding: sialome and post-sialome perspectives, *Annual review of entomology*, 48 (2003) 73-88.
- [17] Li, A.N. Beckett, F.E.R. Simons, C. Li, T. Zhang, Z. Peng, A new 67 kDa recombinant *Aedes aegypti* salivary allergen rAed a 4 in the diagnosis of mosquito allergy, *Journal of Allergy and Clinical Immunology*, 115 (2005) S100.
- [18] M.C.Y. Heng, S.G. Kloss, G.C. Haberfelde, Pathogenesis of papular urticaria, *Journal of the American Academy of Dermatology*, 10 (1984) 1030-1034.
- [19] S. Cheikhrouhou, S. Trabelsi, D. Aloui, M. Bouchekoua, S. Khaled, Avian mite bites acquired from pigeons: Report of three cases and review of the literature, *Tunis Med*, 98 (2020) 241-245.
- [20] S. Lu, L. Tirloni, M.B. Oliveira, C.F. Bosio, G.A. Nardone, Y. Zhang, B.J. Hinnebusch, J.M. Ribeiro, J.F. Andersen, Identification of a substrate-like cleavage-resistant thrombin inhibitor from the saliva of the flea *Xenopsylla cheopis*, *J Biol Chem*, 297 (2021) 101322.
- [21] L. Rodrigues Moreira Guerra, G. Caldas D'Ávila Pessoa, P. Horta Andrade, L. Medeiros da Costa, L. Diotaiuti, L. Barbosa Koerich, M.R. Viana Sant'Anna, R.N. Araujo, N.F. Gontijo, M. Horácio Pereira, Bedbug salivation patterns during hematophagy in the skin of a mammalian host, *Journal of insect physiology*, 131 (2021) 104235.
- [22] C.M. Teixeira, T.M.d. Oliveira, A. Soriano-Araújo, L.d.C. Rezende, P.R.d. Oliveira, L.M. Cunha, N.R.d.S. Martins, *Ornithonyssus sylviarum* parasitism among poultry farm workers in Minas Gerais state, Brazil, *Ciência Rural*, 50 (2020).
- [23] A.M. Lozano, J.F. López, J. Zakzuk, E. García, Papular urticaria: A review of causal agents in Colombia, *Biomedica*, 36 (2016) 632-645.
- [24] L.B. Smith, E. Duge, P.C. Valenzuela-León, S. Brooks, I. Martin-Martin, H. Ackerman, E. Calvo, Novel salivary antihemostatic activities of long-form D7 proteins from the malaria vector *Anopheles gambiae* facilitate hematophagy, *Journal of Biological Chemistry*, 298 (2022) 101971.
- [25] R. Howard, I.J. Frieden, Papular Urticaria in Children, 13 (1996) 246-249.
- [26] J. Theis, M.M. Lavoipierre, R. LaPerriere, H. Kroese, Tropical Rat Mite Dermatitis: Report of Six Cases and Review of Other Mite Infestations, *Archives of Dermatology*, 117 (1981) 341-343.
- [27] F.D. Carvalho, L.A. Moreira, Why is *Aedes aegypti* Linnaeus so Successful as a Species?, *Neotropical entomology*, 46 (2017) 243-255.

- [28] R.S. Fernandes, O. O'Connor, M.I.L. Bersot, D. Girault, M.R. Dokunengo, N. Pocquet, M. Dupont-Rouzeyrol, R. Lourenço-de-Oliveira, Vector Competence of *Aedes aegypti*, *Aedes albopictus* and *Culex quinquefasciatus* from Brazil and New Caledonia for Three Zika Virus Lineages, 9 (2020) 575.
- [29] A.S. Stibich, R.A. Schwartz, Papular urticaria, *Cutis*, 68 (2001) 89-91.
- [30] M.H. Celiksoy, A.H. Ozmen, E. Topal, Prevalence of atopic diseases in children with papular urticaria, *Allergol Immunopathol (Madr)*, 49 (2021) 62-67.
- [31] A. Cianferoni, Non-IgE-mediated anaphylaxis, *J Allergy Clin Immunol*, 147 (2021) 1123-1131.
- [32] G.J. Gleich, The late phase of the immunoglobulin E-mediated reaction: a link between anaphylaxis and common allergic disease? *J Allergy Clin Immunol*, 70 (1982) 160-169.
- [33] C.E. Olivier, D.G. Pinto, A.P.M. Teixeira, J.L.S. Santana, R.A.P.G.S. Santos, R.P.S. Lima, E.S. Monteiro, Evaluating Non-IgE-Mediated Allergens' Immunoreactivity in Patients Formerly Classified as "Intrinsic" Asthmatics with Help of the Leukocyte Adherence Inhibition Test, *European Journal of Clinical Medicine*, 4 (2023) 1-7.
- [34] C.E. Olivier, D.G. Pinto, A.P.M. Teixeira, J.L.S. Santana, R.A.P.G.S. Santos, R.P.S. Lima, E.S. Monteiro, Evaluating Non-IgE-mediated Allergens' Immunoreactivity in Patients with "Intrinsic" Persistent Rhinitis with Help of the Leukocyte Adherence Inhibition Test, *European Journal of Medical and Health Sciences*, 5 (2023) 17-22.
- [35] C.E. Olivier, D.G. Pinto, A.P.M. Teixeira, J.L.S. Santana, R.A.P.G.S. Santos, R.P.S. Lima, Intrinsic Atopic Dermatitis: Titration of Precipitins in the Screening of Food Allergens for Prescription of Elimination Diets and Desensitization Strategies, *Eur J Clin Med*, 2 (2021) 1-9.
- [36] S. Wongkamchai, P. Khongtak, S. Leemingsawat, N. Komalamisra, N. Junsong, K. Kulthanan, W. Wisuthsarewong, J.J. Boitano, Comparative identification of protein profiles and major allergens of saliva, salivary gland and whole body extracts of mosquito species in Thailand, *Asian Pac J Allergy Immunol*, 28 (2010) 162-169.
- [37] C.E. Olivier, D.G.P. Argentão, R.A.P.G. Santos, M.D. Silva, R.P.S. Lima, R.L. Zollner, Skin scrape test: an inexpensive and painless skin test for recognition of immediate hypersensitivity in children and adults, *The Open Allergy Journal*, 6 (2013) 9-17.
- [38] C.E. Olivier, R.P.d.S. Lima, D.G. Pinto, R.A.P.G.d. Santos, The Plasma Preincubation with Papain Before the Assay Suggests that a Gell and Coombs Type II Reaction is Been Demonstrated by the Leukocyte Adherence Inhibition Test., *Biomedical Journal of Scientific & Technical Research*, 36 (2021) 28647 - 28655.
- [39] C.E. Olivier, D.G. Pinto, R.P.d.S. Lima, A.P.M. Teixeira, J.L.S. Santana, Self-imposed food restriction and oral food challenges are correlated with precipitin's accuracy in the diagnosis of non-IgE-mediated food-related adulthood acute episodes of urticaria, *Journal of Allergy & Therapy.*, 12 (2021) 1-8.
- [40] A. Cianferoni, Non-IgE Mediated Food Allergy, *Curr Pediatr Rev*, 16 (2020) 95-105.
- [41] P.G.H. Gell, R.R.A. Coombs, Classification of Allergic Reactions Responsible for Clinical Hypersensitivity and Disease., in: P.G.H. Gell, R.R.A. Coombs (Eds.) *Clinical Aspects of Immunology*, Blackwell Scientific Publications, Oxford, 1968, pp. 575-596.
- [42] C.E. Olivier, D.G. Pinto, A.P.M. Teixeira, J.L.S. Santana, R.A.P.G. Santos, R.P.S. Lima, E.S. Monteiro, Far Beyond the IgE: Insights into the Clinical Profile of Allergic Patients with Selective IgE Deficiency, Urticarial Vasculitis, Allergic Pharyngitis, and Perennial Allergic Conjunctivitis. , 7(1), 35-45, *Asian Journal of Immunology*, 7 (2023) 35-45.
- [43] J.S.S. Lee, T.H. Loh, S.C. Seow, S.H. Tan, Prolonged urticaria with purpura: The spectrum of clinical and histopathologic features in a prospective series of 22 patients exhibiting the clinical features of urticarial vasculitis, *J Am Acad Dermatol*, 56 (2007) 994-1005.