

Case study

Papillary microcarcinoma of thyroid with tuberculosis: an exceptional association

Abstract:

Tuberculosis (TB) is an infectious disease with pulmonary and extrapulmonary locations. Tuberculosis of the Thyroid gland is rare and patients generally don't show any symptoms. The association of tuberculosis and papillary thyroid carcinoma (PTC) is exceptional. As far as the authors know, less than ten cases have ever been reported in the English literature. The diagnosis was made on histopathological examination and treatment is surgical.

The aim of this work is to present a very rare association observed in a 53-years-old patient treated in the ENT tertiary referral center of Casablanca, Morocco for a thyroid nodule suspect of malignancy. The final histopathological examination found a papillary microcarcinoma of thyroid associated with tuberculosis.

Keywords: papillary microcarcinoma, tuberculosis, thyroid

Introduction:

Tuberculosis (TB) is an infectious disease considered as big threat for public health¹. The World Health Organization reported that in 2020 worldwide 16/10.000 individuals were known to be infected with Mycobacterium tuberculosis and 19% of deaths were associated with tuberculosis¹s. It can be divided into pulmonary and extrapulmonary TB. Extrapulmonary TB comprises 20% of all TB cases and occurs in a variety of organs². The thyroid gland tuberculosis is a rare entity, that should be known by medical practitioners^{2,3}.

Thyroid cancer is a common type of cancer and represents 1% of all cancers⁴. In Morocco, thyroid cancer is the third cause of female cancer. Papillary thyroid cancer (PTC) is the most encountered and accounts for 80-85% of well-differentiated thyroid cancers⁴.

The existence of both tuberculosis and thyroid cancer in the same location is exceptional. Very few cases have been reported in literature.

Case presentation:

This case is about a 53-years-old female, with no personal or familiar history of tuberculosis or thyroid cancer, was admitted to the ENT Head and neck surgery department of the Academic hospital of Casablanca in February 2021 for a 2 years history of an enlargement of the left thyroid lobe. The clinical examination found a thyroid mobile, soft and not painful with the presence of a small nodule on the left lobe measuring less than 1cm

B-mode ultrasound examination revealed number of nodules in the bilateral lobe of the thyroid gland and one nodule on the anterior side of the left lobe showing irregular shape and margin, hypoechoic, score 5

of TIRADS 2017 with high risk of malignancy (26-87% of malignancy). Biology was normal with no inflammatory signs. Thyroid function tests were normal. Fine needle aspiration cytology (FNAC) was not performed before surgery. The chest X-ray was normal and other extrapulmonary TBs were excluded.

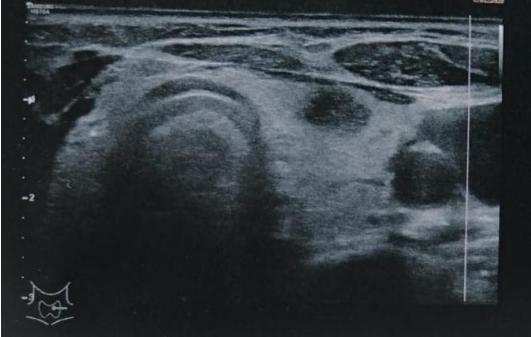


Figure 1. B-mode ultrasonography showing thyroid hypoechoic nodule of the left lobe

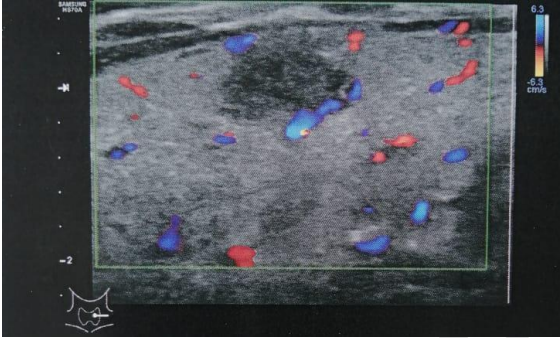


Figure 2. Doppler mode showing peripheral vascularization of the nodule

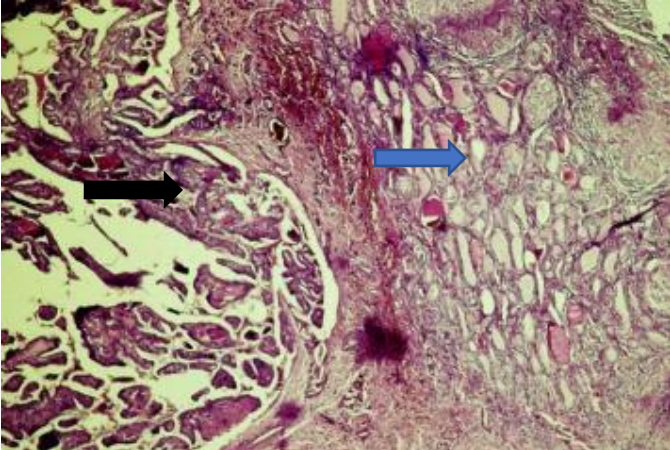


Figure 3. microscopic view showing the association within the thyroid

- parenchyma of papillary carcinoma
- granulomatous process with caseous necrosis (Hex10)

The patient underwent total thyroidectomy. Macroscopic examination showed necrotic tissue within the most suspect nodule. Final Histological examination showed within the most suspect nodule, an epithelioid and gigantocellular granulomatous process with caseous necrosis of the thyroid associated with an 8mm papillary microcarcinoma variant vesicular. Investigations did not find any other extrapulmonary Tuberculosis location.

The patient received a six-month antituberculosis regimen: 2RHZE/4RH (R :Rifampicin 10 mg/ kg/ j, H :Isoniazid 5 mg/ kg/ j, Z :Pyrazinamid 20-30 mg/ kg/j), and a permanent substitution with L-thyroxin with satisfying evolution. No sign of recurrency was found during the follow-up.

Discussion:

Thyroid gland tuberculosis is a rare disease with a frequency of 0.1-0.4% in histologically diagnosed thyroid specimens². In Asian countries, such as India with high prevalence of tuberculosis, the incidence of thyroid tuberculosis remains low (0.6-1.15%)³. This can be due to its good oxygenation and bacteriostatic nature of thyroid hormones, explaining the rarity of this location^{3,5}. Clinically, there are mainly no evident symptoms as encountered in goiter⁶. Most of thyroid tuberculosis cases are diagnosed based on the post-operative histopathological examination.

The association of thyroid tuberculosis and thyroid carcinoma is extremely rare. To date, very few cases have been described in literature. Meng and al. reported a case of Papillary thyroid cancer coexisting with thyroid tuberculosis and implicated the possible role of mycobacterial infections in the tumorigenesis of PTC³. Mycobacterial infections establish chronic and persistent inflammation. Previous studies have reported that mycobacterial cell wall components are capable of inducing DNA damage through the production of nitric oxide and reactive oxygen species. This DNA damage has been implicated in inflammation-related carcinogenesis^{3,5,7}. Hizawa and al. who also reported a case of a young woman with miliary pulmonary tuberculosis, suggested the same hypothesis⁸. Most of studies reported cases of patients with thyroid dysfunction as hypothyroidism.

Allan and al. who described the case of an old lady with previous medullary thyroid carcinoma treated by total thyroidectomy alone, and developed a tuberculous abscess of the thyroid bed seven years after, might suggest that the coexistence of thyroid tuberculosis and papillary carcinoma is a coincidence⁹.

FNAC is not always required for the diagnosis. El kohen and al. reported the case of a young patient, in whom the totalization for papillary microcarcinoma found after partial thyroidectomy revealed an associated tuberculous thyroiditis. FNAC could have made them missed the papillary carcinoma associated to the tuberculosis^{7,10}. Some authors suggest the possibility of diagnostic confirmation by polymerase chain reaction (PCR) after culturing glandular cell homogenate or pus issuing from a fistulous orifice⁷.

The tuberculosis treatment is medical and consists of the combination of powerful anti-tuberculous drugs according to the regimen: 2RHZ/4RH. Surgical treatment helps the drainage of abscess collections, allowing diagnosis and increasing the effectiveness of medical treatment⁷. A substitution with L-thyroxin is required after the total thyroidectomy.

Most of Patients evolve well under this treatment. No sign of recurrency or complication have been notified.

Conclusion :

The association with Papillary microcarcinoma of thyroid with tuberculosis is exception. The clinical presentation of this association is variable and thyroid dysfunction is generally found. The treatment is medical and surgical with a good prognosis. We report this case so the physicians, biologists must be aware of this possible association.

References :

1. TB profile. Accessed July 17, 2021.
https://worldhealthorg.shinyapps.io/tb_profiles/?_inputs_&lan=%22EN%22&entity_type=%22group%22&group_code=%22global%22
2. Bulbuloglu E, Ciralik H, Okur E, Ozdemir G, Ezberci F, Cetinkaya A. Tuberculosis of the thyroid gland: review of the literature. *World J Surg*. 2006;30(2):149-155. doi:10.1007/s00268-005-0139-1
3. Meng L, Hu S, Huang L, Xu C. Papillary thyroid cancer coexisting with thyroid tuberculosis: A case report. *Oncol Lett*. 2014;7(5):1563-1565. doi:10.3892/ol.2014.1901
4. Kaabouch M, El Mzibri M. Thyroid Cancer: State of Art of in Morocco. *Journal of Thyroid Disorders & Therapy*. 2016;05. doi:10.4172/2167-7948.1000197
5. Falagas ME, Kouranos VD, Athanassa Z, Kopterides P. Tuberculosis and malignancy. *QJM*. 2010;103(7):461-487. doi:10.1093/qjmed/hcq068
6. Oudidi A, Cherkaoui A, Zaki Z, Hachimi H, Alami MN. Tuberculose thyroïdienne. *Annales d'Otolaryngologie et de Chirurgie Cervico-faciale*. 2005;122:150-153. doi:10.1016/S0003-438X(05)82341-2
7. Errami N, Benjellounb A, Hemmaouia B, Nadoura K, Benariba F. Association of tuberculous thyroiditis and papillary carcinoma of the thyroid: a rare coincidence. *Pan Afr Med J*. 2014;19:118. doi:10.11604/pamj.2014.19.118.4805
8. Hizawa K, Okamura K, Sato K, et al. Tuberculous thyroiditis and miliary tuberculosis manifested postpartum in a patient with thyroid carcinoma. *Endocrinol Jpn*. 1990;37(4):571-576. doi:10.1507/endocrj1954.37.571
9. Allan R, O'Flynn W, Clarke SE. Tuberculosis of the thyroid bed presenting as recurrent medullary thyroid carcinoma. *Tubercle*. 1990;71(4):301-302. doi:10.1016/0041-3879(90)90046-b
10. el Kohen A, Essakalli L, Amarti A, Benchekroun L, Jazouli N, Kzadri M. [Thyroid tuberculosis associated with papillary microcarcinoma of the thyroid gland: a case report]. *Rev Laryngol Otol Rhinol (Bord)*. 2001;122(3):205-208.