

## Case report

# **A RARE CASE OF MISPLACED COPPER - T IN APPENDIX ALONG WITH APPENDICITIS**

### **ABSTRACT**

Uterine perforation is one of the serious complications associated with use of intrauterine contraceptive devices (IUD). Perforation can occur during insertion or later. Delayed onset of symptoms is mostly due to chronic inflammatory reaction of copper-containing IUD. Presenting a 28 year old with pain over right iliac fossa since 6 months with misplaced copper t which had penetrated into the tip of appendix. Appendectomy was done and copper T was retrieved. The impacted copper t had caused local inflammatory changes leading to appendicitis. Patients with IUD should be alerted about the possibility of its migration. Regular self examination for "missing threads" is useful in the early detection of migration of the IUD. The treatment of a migrated IUD is surgical, either laparoscopy or laparotomy. Withdrawal of the migrated IUD is advisable even if its migration has not given rise to any clinical symptoms.

**KEYWORDS:** IUCD, Appendicitis, migration, perforation.

### **INTRODUCTION**

"Because of the ease of availability, and low cost intrauterine contraceptive device (IUCD) is the second most common used contraceptive Worldwide".[1] "One of the reasons for discontinuation rates of 20-40% is the fear of complications such as excessive bleeding, pain, infection, uterine perforation, and spontaneous expulsion".[2,3] "However, it has a potential health risk and is often silent".[4] "Intrauterine contraceptive device (IUD) has been widely used since 1965" [5]. "Perforation of the uterus by an IUD is a rare and serious complication, occurring in 1/350 to 1/2 500 insertions" [6]. "Perforation by IUD can involve several neighbouring organs such as the bladder, and particularly the intestinal tract resulting frequently in serious complications which require intensive treatment including intestinal surgery. Perforation can occur during insertion or later. Perforation occurring at the time of insertion correlates directly with the skill of the clinician. Delayed onset of symptoms is mostly due to chronic inflammatory reaction of copper-containing IUD. Health workers need to be aware of this complication and should take necessary precautions while inserting Copper T and be able to provide prompt diagnosis and treatment in the case of

missing IUCD so as to prevent chances of migration of IUD and prevent bowel and bladder perforation”.[7]

**CASE REPORT** - Presenting a young 28 year old female presented with the complaint of pain over the right iliac fossa for 6 months.  
No additional symptoms. Her LMP was 31/05/2022 with past menstrual history being a regular(every 28-30 days) cycle, with moderate flow lasting for 3-5 days not associated with pain.  
She is a P2L2 patient with previous both full term normal vaginal delivery with 8 years of married life.No other significant past, personal and family history was noted. General condition of the patient was good and the vital parameters were normal.Abdomen was soft with tenderness over the right iliac fossa. On Per vaginal examination the uterus was retroverted, retroflexed, normal sized uterus,bilateral fornices free and non tender. On per speculum examination, IUCD thread was not seen.

**MANAGEMENT:** Basic blood investigations were done.

Cbc- Hb- 9.9 gm%,  
Tlc - 5900 cell/cumm,  
Dlc- 66/25/4/5  
platelet - 2.23 lac/cumm

RBS - 111mg%

RFT -S.Creat -0.5 mg%

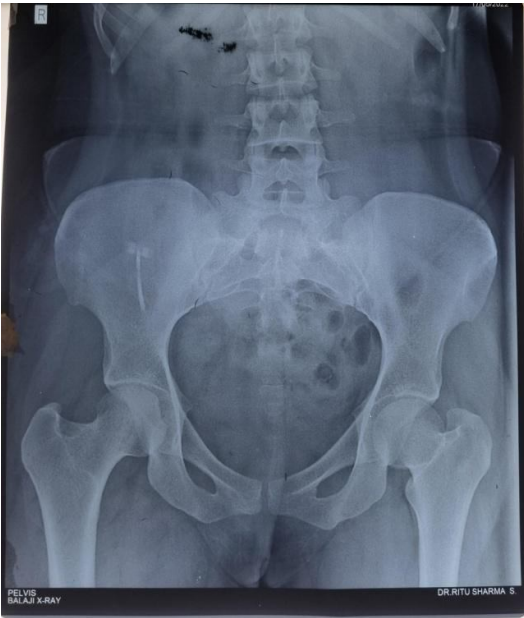LFT - SGPT - 16 IU/L,  
SGOT - 23 IU/L,  
S.bilirubin - 0.6 mg/dl

Blood group - O positive

Chest X Ray and ECG are within normal limits.

Ultrasonography suggested Linear echogenic strand like foreign body object is noted in the right iliac fossa which is causing local inflammatory changes in the form of surrounding fat stranding. The foreign body is within close proximity to the appendix, maximum diameter measures 2.5mm. Further evaluation with clinical correlation is recommended. X-ray of the pelvis was done (Figure 1) and showed the Copper T to be in the right iliac fossa

Figure 1: X-ray report showing Copper T in right iliac fossa



The preoperative process was carried out and the patient was posted for an exploratory laparotomy. Uterus and both adnexa normal. However, by a palpatory method over the appendix, the vertical lines of IUCD could be felt. The IUCD was located in the abdominal cavity behind the ileocecal junction and its tip had penetrated the tip of the appendix. The whole area was edematous and covered with omentum. No fecalith impaction in the appendix was found.

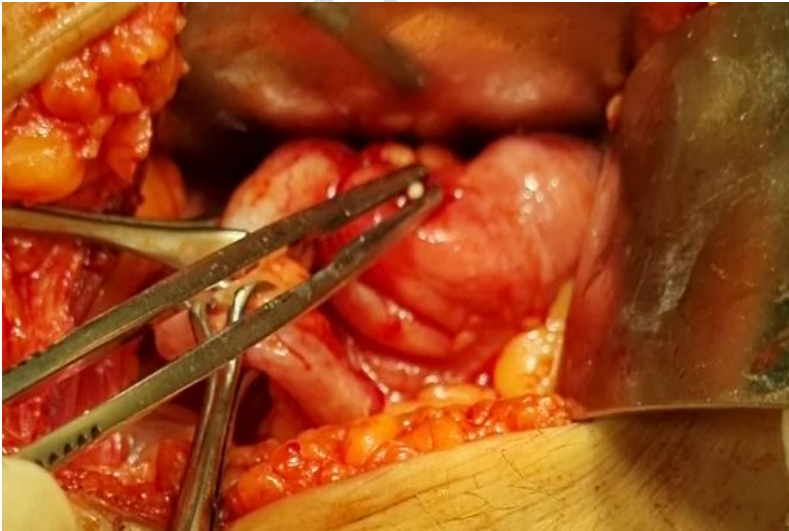

Figure 2 Exploratory laparotomy

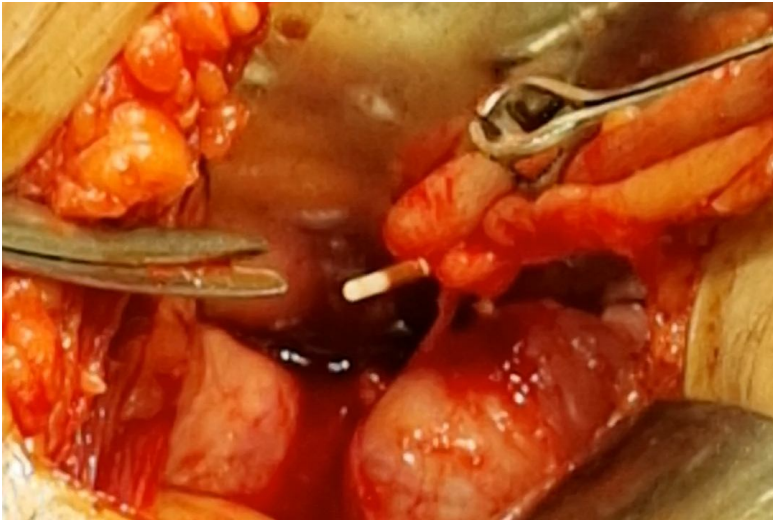


Figure 3 Copper T visibly penetrated into the appendix

Appendix was found to be inflamed and an appendectomy was done. Bowels were checked for injury and hemostasis achieved. The patient recovered uneventfully. Haemorrhagic fluid was present at the tip of the appendix.

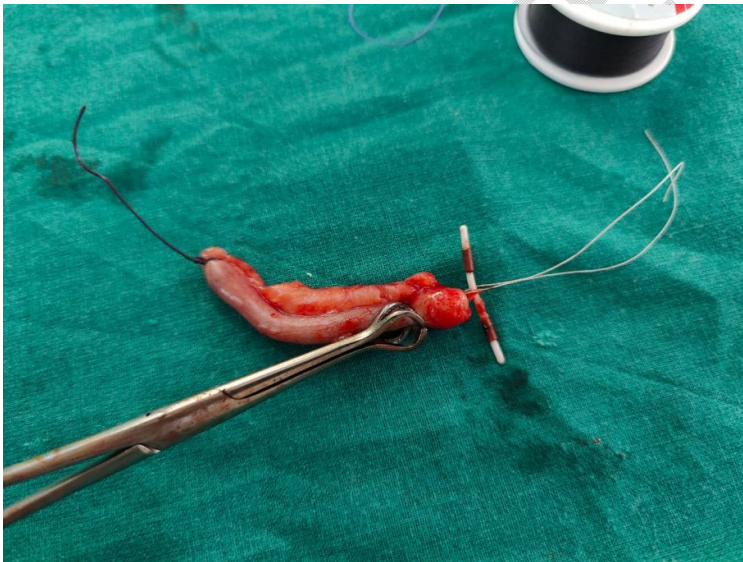

Figure 4 : Retrieved copper T penetrated into the appendix

Post operative TPR BP I/P O/P, AG, BPV was monitored. Patient was given hydration, antibiotic and analgesic cover. The patient was discharged on day 4 of surgery. The retrieved copper T and the appendix was sent for histopathology. The section showed focal ulcerated mucosa with few hyperplastic lymphoid follicles in the mucosa. Few scattered

neutrophils seen in the submucosa. Blood vessels were congested. Foreign body granulomas were not seen. Malignancy was not seen.

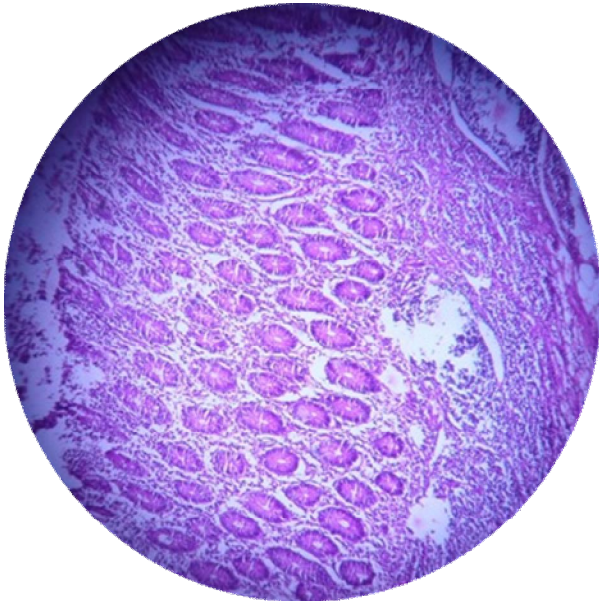


Figure 5: Ulcerated mucosa with few hyperplastic lymphoid follicles in the mucosa

### **DISCUSSION AND CONCLUSION:**

The impacted copper t had caused local inflammatory changes leading to appendicitis.

“IUD is generally a safe modality for long-term contraception. Associated complications are bleeding, infection, ectopic pregnancy and uterine perforation. Uterine perforation is one of the most serious but uncommon complications associated with an IUD with an incidence of one in 1,000 insertions. Perforation may be complete, with the device totally in the abdominal cavity, or partial, with the device to varying degrees within the uterine wall. The mechanism of perforation is thought to be the insertion procedure or chronic inflammatory reaction with gradual erosion through the uterine wall” [5]. “The incidence is influenced by several factors including the timing of insertion, parity, previous abortions, type of IUD inserted, experience of the operator and position of the uterus. Most of the perforations take place at the time of insertion. Delayed onset of symptoms supports secondary migration” [5].

Causes include faulty technique, inappropriate timing of insertion, soft uterine wall, wrong measurement of uterocervical length. Secondary uterine perforation is silent and occurs due to slow migration of Copper T through the uterus with the concurrent bowel peristalsis, spontaneous uterine contractions, bladder contractions. Migrated IUD may not be discovered

until it is found missing or the patient becomes pregnant. Sometimes they may present with pain in the abdomen or urinary disturbances. Post-insertion women should have follow-up visits as recommended. First, visit should be at the first menstrual period or after 1-month, whichever is earlier. Subsequently after 3 months. Thereafter, once a year for the exclusion of infection, abnormal bleeding, the proper position of Copper T. An IUD user should be instructed to contact health care provider in case of: (a) IUCD threads cannot be felt, (b) she or her partner can feel the lower end of IUCD, (c) persistent abdominal pain, fever, dyspareunia, unusual vaginal discharge, (d) when she misses periods. Regular self examination for “missing threads” is useful in the early detection of migration of the IUD. “A plain radiograph of the abdomen is usually the initial examination of choice to verify the presence of the IUD in the pelvis. Once found, an ultrasound examination has to be done to determine the location of the IUD relative to the uterus. The treatment of a migrated IUD is surgical, either laparoscopy or laparotomy. Withdrawal of the migrated IUD is advisable even if its migration has not given rise to any clinical symptoms and can avoid further complications like bowel perforation, bladder perforation, or fistula formation” [8].

There have been similar reported cases in the past; one was with Lippe’s loop[9] and four cases had perforation due to Copper 7[10]. These cases are reported in '70's and early'80's when Cu7 and Lippe’s loop were the only available IUD's. However cases reported later than that were with CuT200, MLCu375 etc. “In all the cases reported, there was a lot of inflammation and adhesion surrounding the appendix, thought to be due to copper present in IUD. However inflammation was also seen in a case where perforation was due to non-medicated IUD, Lippe’s loop, and a lot of dissection had to be carried out for performing the appendicectomy” [9].

All the cases mentioned in literature, including our present one were managed either by laparotomy or laparoscopy followed by laparotomy due to extensive inflammation and adhesions except one, where Coelho et al[11](2003) was able to “manage it by laparoscopy alone; in spite of the presence of inflammation and adhesion. This may be due to more expertise of the surgeons in laparoscopy”.

## **CONSENT**

As per international standard or university standard, patients’ written consent has been collected and preserved by the author(s).

## **Ethical Approval**

As per international standard or university standard guideline participant consent and ethical approval has been collected and preserved by the authors.

## **REFERENCES:**

1. Farouk K, uddin Afridi Z, Farooq MA, Qureshi IA. Urological complications of intrauterine contraceptive device. *Journal of Postgraduate Medical Institute*. 2007;21(4).
2. Bhatnagars MI. A Field Study of IUCD Acceptors in the State of UP. New Delhi: National Institute of Health and Family Welfare. 1988.
3. Schaap B. IUD ACCEPTANCE IN RURAL MADHYA-PRADESH-RESULTS OF AN ACCEPTORS INTERVIEW. *Journal of Family Welfare*. 1993 Mar 1;39(1):52-5.
4. Heinberg EM, McCoy TW, Pasic R. The perforated intrauterine device: endoscopic retrieval. *JSL: Journal of the Society of Laparoendoscopic Surgeons*. 2008 Jan;12(1):97.
5. Zakin D, Stern WZ, Rosenblatt R. Complete and partial uterine perforation and embedding following insertion of intrauterine devices. I. Classification, complications, mechanism, incidence, and missing string. *Obstet Gynecol Surv*. 1981;36:335–353.
6. Ohana E, Sheiner E, Leron E, Mazor M. Appendix perforation by an intrauterine contraceptive device. *Eur J Obstet Gynecol Reprod Biol*. 2000;88:129–131.
7. Thomalla JV. Perforation of urinary bladder by intrauterine device. *Urology*. 1986 Mar 1;27(3):260-4.
8. Berman MC, Cohen HL. *Diagnostic Medical Sonography*. Lippincott; 1997. *Obstetrics and gynaecology: A guide to clinical practice*; pp. 569–571
9. Goldman JA, Peleg D, Feldberg D, Dicker D, Samuel N. IUD appendicitis. *European Journal of Obstetrics & Gynecology*. 1983 Jul 1;15(3):181-3.
10. Singhal SR, Marwah DS, Paul A, Singhal SK. Missed intra uterine device: a rare indication for appendicectomy-case report with review of literature. *East and Central African Journal of Surgery*. 2010;15(2):156-8.
11. Coelho JC, Gonçalves CG, Graf CM. Laparoscopic treatment of peri-appendicitis caused by intrauterine contraceptive device. *Arquivos de Gastroenterologia*. 2003 Jan 1;40(1):45-6.