

# Vanishing Bile Duct Syndrome case report and mini-review of this rare disease.

---

## ABSTRACT

**Aim:** Vanishing bile duct syndrome (VBDS) is a rare condition that affects the liver and bile ducts. It is characterized by the progressive destruction or loss of bile ducts in the liver. The causes of vanishing bile duct syndrome are not fully understood, but it can occur as a result of a variety of factors, including infections, autoimmune disorders, certain medications, and genetic conditions.

**Presentation:** we report a case of VBDS after a treatment with Bortezumid and Linelomide. We explain the pathophysiology and the actual knowledge of the treatment.

**Conclusion:** Plasmapheresis not to seems indicated "only because there are not improvement with immunosuppressive treatment" and support that the use of plasmapheresis in isolated VBDS is limited.

**Key words:** DILI, Drug induce liver injury, VBDS, vanishing bile duct syndrome, multiple myeloma

## 1. INTRODUCTION

Vanishing bile duct syndrome (VBDS) is a rare condition that affects the liver and bile ducts. It is characterized by the progressive destruction or loss of bile ducts in the liver, which can lead to a buildup of toxic substances in the liver, jaundice, itching, and other symptoms. It can lead to liver damage and cirrhosis [1]. The causes of vanishing bile duct syndrome are not fully understood, but it can occur as a result of a variety of factors, including infections, autoimmune disorders, certain medications, and genetic conditions. Treatment depends on the underlying cause, but may include medications to reduce inflammation, immune system suppression, and liver transplantation in severe cases [2].

## 2. CASE REPORT

A patient of 75 years old with a medical past of hypertension, diabetes, hyperlipidemia, smoking, chronic Renal failure, and recent diagnosis of Multiple Myeloma, was hospitalized due to increased liver enzymes and jaundice. About two months ago, he was diagnosed with multiple myeloma and started treatment with Bortezumid, Linelomide and dexamethasone. He also received a prophylactic treatment with acyclovir and trimethoprim/sulfamethoxazole. On his admission to our department raised suspicion of jaundice due to drug treatment for myeloma and/or treatment with paracetamol for pain management. Drug treatment for myeloma was stopped and acetylcystein treatment was started according to the protocol.

In the DILI differential drugs Bortezumid, Linelomide and trimethoprim/sulfamethoxazole or their combination can cause into significant disorders. According to the recommendations of the hepatologist, comprehensive tests were taken for infectious and autoimmune diseases without finding any abnormalities. In a joint discussion including the hematologist and the hepatologist, drug treatment with steroids and ursodeoxycholic acid (UDCA) was started and antibiotic coverage was added.

The Abdominal CT showed a shrunken gallbladder. No space-consuming process was demonstrated. Multiple lytic lesions in the skeleton without change. A known pathological fracture in the D10 body without change.

The MRCP was without new significant finding, but the biopsy (FIG 1) revealed a parenchyma intrahepatic with bile pigment in the hepatocytes. There was a mild chronic inflammatory infiltration without plasma cells in the portal tracts. In addition, in some portal tracts there was a lack of visible bile ducts (immunostaining for CK7 was done), suitable for VBDS. There were no myeloma cells, negative amyloid staining, no signs of obstruction, negative for CMV.

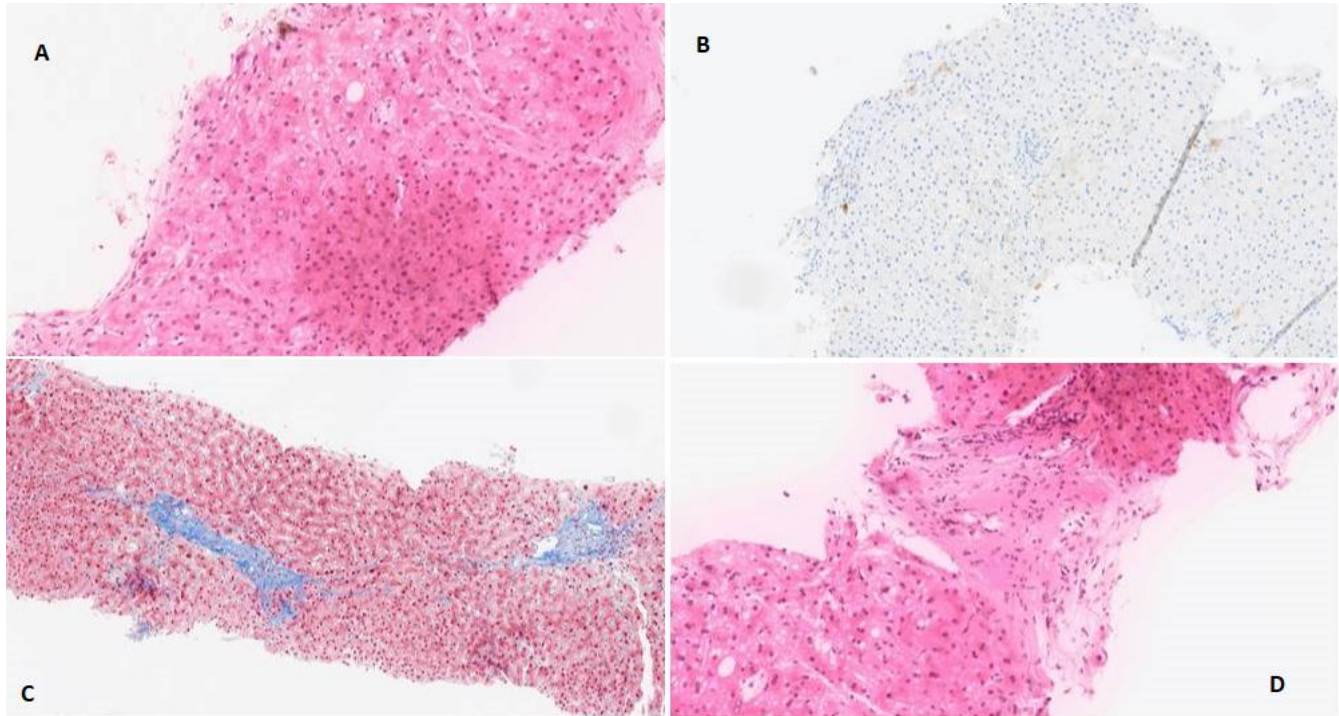


FIG 1. A and D : H and D Staining ; no clear bile duct seen. B. CK7 staining ; no clear bile duct seen. C. Trichrome staining ; Fibrosis (blue)

The patient's condition did not improve under treatment with steroids and UDCA. In a joint discussion including the hematologist and the hepatologist, it was decided to begin plasmapheresis to try to improve bilirubin level (FIG 2) and patient condition. After plasmapheresis, the patient was released in with a little improve of his condition. During the 4 months after his release from the hospital, patient was hospitalized again several times because complications of liver insufficiency and finally died because a septic shock.

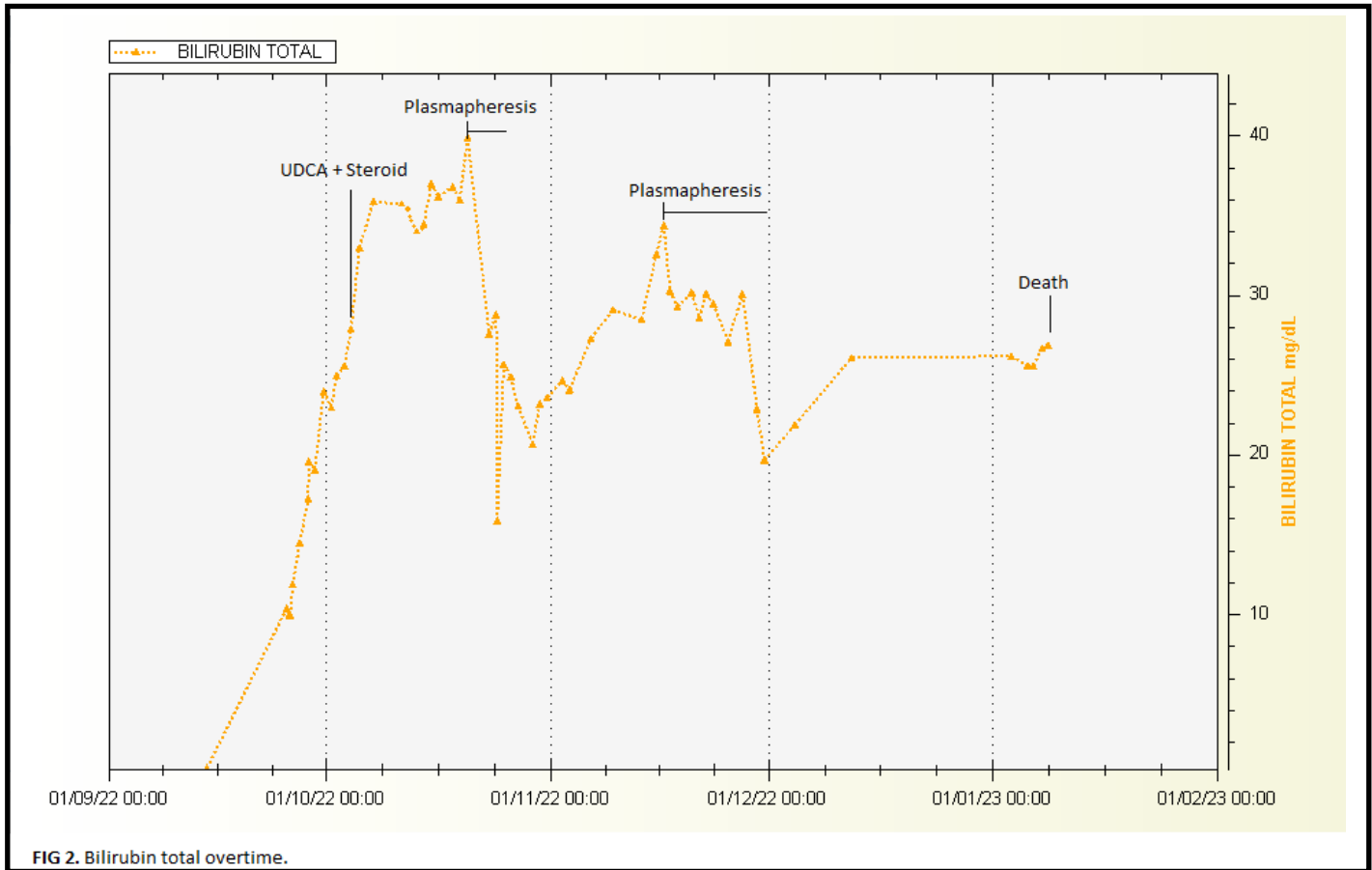


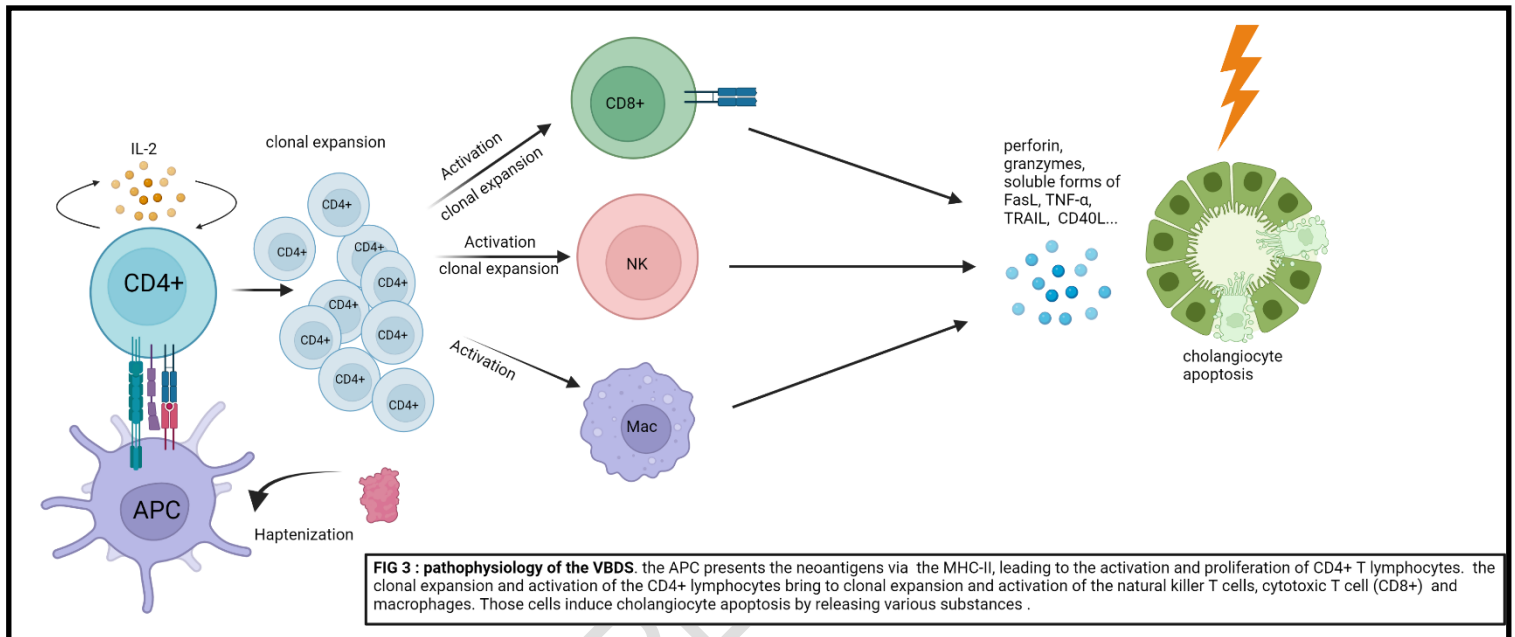
FIG 2. Bilirubin total overtime.

### 3. DISCUSSION

DILI is a significant contributor to acute liver failure. It presents a major challenge for drug development and safety. DILI is typically caused by unexpected reactions or idiosyncratic metabolic responses to medication, but the exact mechanism is not well understood. Due to the lack of specific signs, symptoms, and tests, diagnosing DILI can be challenging and often requires ruling out other possible causes [3].

The pathophysiology of vanishing bile duct syndrome (FIG 3) involves the progressive destruction or loss of the bile ducts in the liver, leading to a range of symptoms and complications. The exact mechanisms that cause this condition are not fully understood, but it is thought to be a result of an immune-mediated attack on the bile ducts or other factors that damage the cells that make up the ducts. In some cases, vanishing bile duct syndrome may be triggered by infections. Other possible causes include autoimmune disorders, and genetic conditions that affect the bile ducts. This can result in a range of symptoms, including jaundice, itching, abdominal pain, and fatigue. As the condition progresses, the patient may develop a liver insufficiency causing complications such as portal hypertension, ascites and hepatic encephalopathy. The process starts with the drug or its reactive metabolites binding covalently with cellular proteins, creating a neoantigen recognized as foreign by the adaptive immune system. These neoantigens are processed and presented by antigen-presenting cells via MHC-II molecules, leading to the activation and proliferation of CD4+ T lymphocytes that produce and release IL-2. The CD4+ T cells further induce the clonal expansion and/or activation of cytotoxic T lymphocytes, natural killer T cells, and

macrophages. These cells induce cholangiocyte apoptosis by releasing various substances such as perforin, granzymes, and soluble forms of FasL, TNF- $\alpha$ , TRAIL, and CD40L. The binding of these substances to their receptors in target cells causes cholangiocyte apoptosis, facilitated by cholangiocyte expression of MHC-I and adhesion molecules such as ICAM-1. The death of cholangiocytes leads to the release of danger-associated molecular patterns molecules (DAMPs), which activate the innate immunity. Toll-like receptors located in cholangiocytes, NK cells, and granulocytes recognize these DAMPs, leading to the release of inflammatory/proapoptotic mediators that induce apoptosis in intact cholangiocytes [4].



A study compared 26 cases with bile duct loss to 337 cases without it on liver biopsy. The two groups had similar age, sex, and race, but those with bile duct loss were more likely to have jaundice and a cholestatic pattern of liver enzyme elevations. They were also more likely to have rash and fever than the control group. In general, the bile duct loss group had higher peak of bilirubin and Alkaline Phosphatase levels, but lower initial and peak of ALT levels. It is important to note that those with bile duct loss had higher mortality rates and chronicity rates compared to those without, especially among patients followed for at least 6 months. They also compared the 26 cases with bile duct loss to a group of control subjects with R values  $\leq 8$  who also underwent liver biopsies. These control subjects had similar clinical features and types of liver injury to those in the study cohort. However, those with bile duct loss had higher levels of serum alkaline phosphatase, total bilirubin, a significantly higher INR at baseline, and a much greater risk of chronicity and poor outcomes [5].

Treatment for vanishing bile duct syndrome depends on the underlying cause and severity of the condition, and may involve medications to reduce inflammation or suppress the immune system, as well as liver transplantation in severe cases. Due to the rarity and unpredictability of drug-induced ductopenia, there are no established treatments or clinical trials to evaluate their efficacy. The main recommended treatment is to immediately discontinue the causative drug and prevent re-exposure. If the drug is discontinued before massive bile duct loss has occurred, the bile duct injury may reverse spontaneously in most cases, with cholestasis subsiding after several months to years.

For patients who do not promptly recover after withdrawal, treatment is highly advised. However, the mechanisms of drug-induced ductopenia are often uncertain, making it difficult to develop specific treatments for each case. Treatment is typically focused on supportive care and controlling symptoms for chronic cholestatic manifestations, such as pruritus, fat-soluble vitamin/mineral deficiencies, and cirrhosis complicated by portal hypertension. Endoscopic therapy may be helpful in selected cases, particularly those with relapsing episodes of cholangitis. Current therapeutic strategies for ductopenia are limited to anticholestatic drugs like UDCA, which aim to protect cholangiocytes from apoptotic death induced by bile salts and inflammatory cytokines associated with the inflammatory process, immunosuppressive and anti-inflammatory agents for cases with a known or suspected immune-mediated action mechanism, liver transplantation for cases with cirrhosis and end-stage liver disease that are unresponsive to medical therapy, and treatment of pruritus when necessary. Unfortunately, there is currently no treatment to stimulate biliary regrowth after bile duct loss, which reduces the chances of treatment success. In cases of drug-induced ductopenia, the use of immunosuppressive therapy is generally not supported, as corticosteroids have been found to be mostly ineffective [4]. Moreover, immunosuppressive treatment can themselves cause VBDS [6]. However, if ductopenia is associated with drug-induced hypersensitivity reactions, including allergic reactions with rash, facial swelling, lymphadenopathy, and eosinophilia, or more severe reactions such as Stevens-Johnson syndrome, toxic epidermal necrolysis, erythema multiforme, or hemophagocytic lymphohistiocytosis, immunosuppressive agents may be used as part of the therapeutic strategy. Corticosteroids are the most commonly used immunosuppressive agents, either alone or in combination with other drugs such as mycophenolate mofetil, tacrolimus, and cyclosporine A, when the patient is unresponsive to corticosteroids. Other drugs, such as infliximab and plasmapheresis, have also been successfully used for immunologically mediated diseases [4].

Considering the severe case of the patient, he was treated with dexamethasone to try to improve his condition even though the support is weak. The patient received also UDCA as advised in the literature. But the treatment was not responding, there was no clinical improvement and the bilirubin continued to rise. Because of the critical condition of the patient, treatment with plasmapheresis was used, even though its use in patients with isolated VBDS is limited [7].

#### **4. CONCLUSION**

Vanishing bile duct syndrome is a rare condition that affects the liver and bile ducts. It is characterized by the progressive destruction or loss of bile ducts that can be caused by drugs. Levels of serum Alkaline phosphatase, total bilirubin, and INR are risk factors for chronicity and likelihood of poor outcomes like in our patient. The pathophysiology of this condition remains unclear and there is a lack of guidelines for treatment. This case supports that plasmapheresis is not indicated only because there is no improvement with immunosuppressive treatment and supports that the use of plasmapheresis in isolated VBDS is limited. Studies are needed to better understand all aspects of the disease and to provide therapeutic guidelines.

#### **REFERENCES**

1. Greca RD, Cunha-Silva M, Costa LBE, Costa JGF, Mazo DFC, Seva-Pereira T, Nascimento MMC, Pereira IE, Oliveira FC, Faria GAS, Neto FLP, Almeida JRS. Vanishing bile duct syndrome related to DILI and Hodgkin lymphoma overlap: A rare and severe case. *Ann Hepatol.* 2020 Jan-Feb;19(1):107-112. doi: 10.1016/j.aohep.2019.06.010. Epub 2019 Aug 19. PMID: 31537508.

2.LiverTox: Clinical and Research Information on Drug-Induced Liver Injury [Internet]. Bethesda (MD): National Institute of Diabetes and Digestive and Kidney Diseases; 2012-. Vanishing Bile Duct Syndrome. [Updated 2019 Dec 11]. Available from: <https://www.ncbi.nlm.nih.gov/books/NBK548715/>

3.Suk KT, Kim DJ. Drug-induced liver injury: present and future. *Clin Mol Hepatol*. 2012 Sep;18(3):249-57. doi: 10.3350/cmh.2012.18.3.249. Epub 2012 Sep 25. PMID: 23091804; PMCID: PMC3467427.

4.Bessone F, Hernández N, Tanno M, Roma MG. Drug-Induced Vanishing Bile Duct Syndrome: From Pathogenesis to Diagnosis and Therapeutics. *Semin Liver Dis*. 2021 Aug;41(3):331-348. doi: 10.1055/s-0041-1729972. Epub 2021 Jun 15. Erratum in: *Semin Liver Dis*. 2021 Jun 29;: PMID: 34130334.

5.Bonkovsky HL, Kleiner DE, Gu J, Odin JA, Russo MW, Navarro VM, Fontana RJ, Ghabril MS, Barnhart H, Hoofnagle JH; U.S. Drug Induced Liver Injury Network Investigators. Clinical presentations and outcomes of bile duct loss caused by drugs and herbal and dietary supplements. *Hepatology*. 2017 Apr;65(4):1267-1277. doi: 10.1002/hep.28967. Epub 2017 Feb 7. PMID: 27981596; PMCID: PMC5360519.

6.Eiswerth M J, Heckroth M A, Ismail A, et al. (February 05, 2022) Infliximab-Induced Vanishing Bile Duct Syndrome. *Cureus* 14(2): e21940. doi:10.7759/cureus.21940

7.White JC, Appleman S. Infliximab/Plasmapheresis in vanishing bile duct syndrome secondary to toxic epidermal necrolysis. *Pediatrics*. 2014 Oct;134(4):e1194-8. doi: 10.1542/peds.2013-2239. Epub 2014 Sep 22. PMID: 25246624; PMCID: PMC4535040.