

Morphometric Assessment of Bi-Caudate Index Using Computerized Tomographic Scan From Sokoto North-Western Nigeria

ABSTRACT

Aim: To determine the bi-caudate index (BCI) of Nigerians using computerized tomography from Sokoto North-Western Nigeria.

Study design: Retrospective cross-sectional

Place and duration of study: Department of Anatomy UsmanuDanfodiyo University Sokoto and Department of Radiology UsmanuDanfodiyo University Teaching Hospital Sokoto, between January, 2020 and January, 2022.

Methodology: CT scans of 186 apparently healthy normal individuals of age group 1 to 70 years were taken and the subjects were categorized into age intervals of 10 years; males and females taken separately. The linear measurements of caudate and brain were taken directly from the screen. The Bi Caudate Index were calculated. The mean values in each group were compared with age and sex, using appropriate statistical tests.

Results: The least BCI in male was 6.0mm and was seen in the age group 1-10 years while in female the least BCI was 5.0mm, seen in the age group 1-10. The largest BCI in male was 21mm, observed in the age group 61-70years, while the largest BCI in female 19.0mm, seen in the age group 61-70years.

Conclusion: Bi Caudate Index shows positive correlation with age.

Key words: Morphometry, bi-caudate, index, CT scan, Nigerians

1. INTRODUCTION

The need to study complete abnormal anatomies such as asymmetry causes interest for three-dimensional computed tomography (3D CT) to have risen over the last two decades.¹ With Three dimensional computed tomography, contours and surfaces are rendered in fine detail.² There are several methods for measuring the brain, nuclei and brain ventricular sizes, which are applied as a means of evaluate brain atrophy during the normal aging process and diseases.²

The digital CT scan machines currently in use also allow direct visualization of ventricles in cross sectional images and direct real time measurement of various dimensions of the ventricular system thus assisting in understanding the normal anatomy of the brain and its nuclei.³ Morphometric analyses of caudate nuclei and cerebral ventricular system is essential for evaluating changes due to ageing, growth and various intrinsic and extrinsic pathologies.⁴

The study of shape and size of brain nuclei has become a focus of interest in studies of some neuropsychiatric diseases like schizophrenia and Alzheimer's disease.^{5,6,7} Knowledge of anatomy of cerebral ventricular system is important for endoscopic neurosurgery.⁸

The caudate nuclei are grey matters that are situated deep in both the cerebral hemispheres. It consists of a head, body and tail.⁹

The values of Bi- Caudate Index (BCI) varied between 0.08 and 0.23 with a mean value of 0.15 ± 0.03 .¹⁰ In a study done by the (BCI) was reported to be between 0.06 and 0.12.¹¹ The bi-caudate index was considered to be abnormal if >0.17 and a definite enlargement if >0.20 , and his values were between 0.06 and 0.19 with a mean value of 0.11 ± 0.03 .¹²

2. MATERIALS AND METHODS

This is a retrospective study of 178 normal brain CT scans of subjects from the Radiology Department of the UsmanuDanfodiyo University Teaching Hospital, whose ages ranged from 1 to 70 year. The CT scan images were retrieved from the hospital database. This study was conducted using CT images done between Jan 2020 and Jan 2022. The CT scans were done with NEUSOFT C 3000 Spiral CT machine Dual Slide Helical CT Scanner, (2005) model at 5mm slice thickness.

The images were viewed on the computer aided Digital Imaging and Communication in Medicine (DICOM) viewer using the RadiAnt Version 4.2 software. Measurements were taken to the nearest 0.1 millimeters.

The Bi Caudate indices were calculated from the linear measures taken at the level of **intreventricular** foramen as shown in fig 1; The Bi Caudate indices were obtained by measuring the distance between the far lateral borders of the head of caudate at its mid-point at the level of interventricular foramen divided by the intracranial distance between the inner skull table at the same level in axial plane.

Inclusion Criteria: The Participants were from Nigeria, they are aged between 1 and 70 years and the brain CT scans were described as normal by a radiologist with respect to: a) Normal cerebral ventricular size, form, shape and periventricular translucency, b) brain parenchyma appears normal with no evidence of space occupying lesions and c) perfect positioning of the patient. With the Passage of the lowest tomographic section through a line 15–20 degrees to and 1cm above the cantho-meatal line which represent the base of the skull.

Exclusion Criterion: The brain CT scans with these features were excluded from the study Evidence of space occupying lesions, cerebral hemorrhage, Previous brain trauma, seizures disorders, intellectual deterioration, alcoholism and dementia, asymmetry of the lateral ventricles, all brain CT scans with poor quality of the scan images.

Statistical analysis was done using Sigmastat 2.0 for windows San Rafael CA. Statsoft (1995). Data are presented in tables and charts, and expressed as means and standard deviation. Differences in ventricular parameters with respect to sex were examined using Student's t test. One-way analysis of variance was used to analyze for variations across age groups and any significant correlation for the indices with the age using scatter diagram $P < 0.05$ was considered as statistically significant.

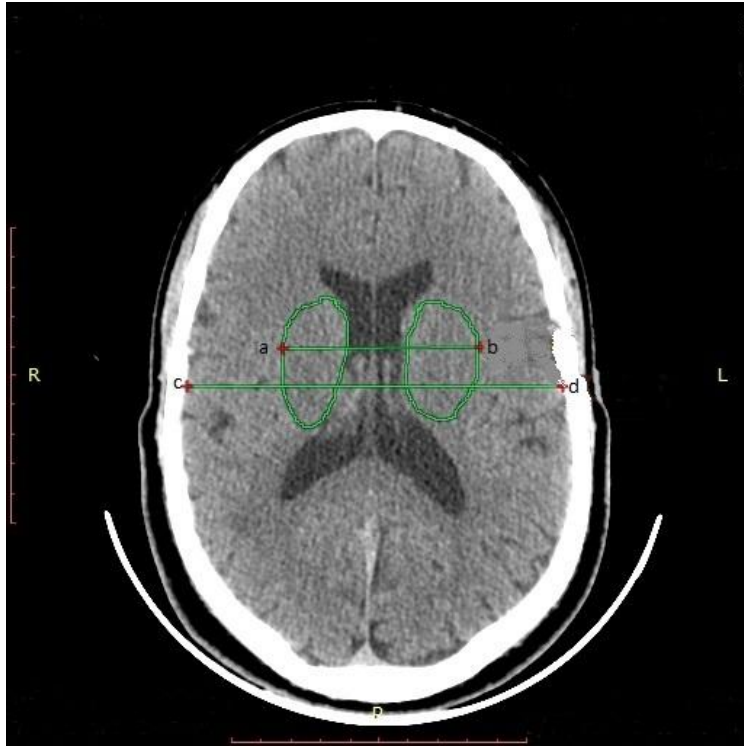


Figure 1: A CT image showing measurement Bi-caudate index (BCI); determined by measuring the lateral borders of head of caudate (a-b) and intracranial distance of the inner skull tables (c-d) at the same level.

3. RESULTS AND DISCUSSION

3.1 MEAN AND SD OF BI- CAUDATE INDEX (BCI) IN RELATION TO AGE AND SEX

There is a gradual increase in the Bi- Caudate Index BCI from 2-4years up to 70years in both males and female. The BCI in males are generally larger than those of the females across all the age groups; but the differences are not statistically significant ($p > 0.05$). The least BCI in male is 0.06cm and was seen in the age group 2-4 years while in female the least BCI is 0.05cm and was seen in the age group 5-10. The greatest BCI in male is 0.21cm and was observed in the age group 61-70years, while greatest BCI in female is 0.19cm and was seen in the age group 61-70years.

Table 1: Mean and SD of Bi- Caudate Index (BCI) in Relation to Age and Sex

Age	Mean±SD Male	Female	Minimum		Maximum		P Value
			Male	Female	Male	Female	
1-10 (N=22)	0.09 ±2.02	0.08±2.42	0.06	0.05	0.13	0.12	.127
11-20 (N=26)	0.10 ±1.32	0.08±1.31	0.08	0.07	0.14	0.13	.634
21-30 (N=27)	0.11±1.321	0.09±1.142	0.09	0.09	0.15	0.13	.723
31-40 (N=28)	0.12±2.02	0.10±2.35	0.10	0.09	0.17	0.15	.671
41-50 (N=24)	0.13 ±3.42	0.11±2.71	0.09	0.08	0.18	0.16	.067
51-60 (N=25)	0.14 ±2.42	0.13±2.67	0.11	0.10	0.19	0.17	.091
61-70 (N=16)	0.15 ±2.67	0.14±2.92	0.11	0.10	0.21	0.19	.752

N= number, SD=Standard deviation

There was no statistical significant difference between sexes and same age groups as $p > 0.05$

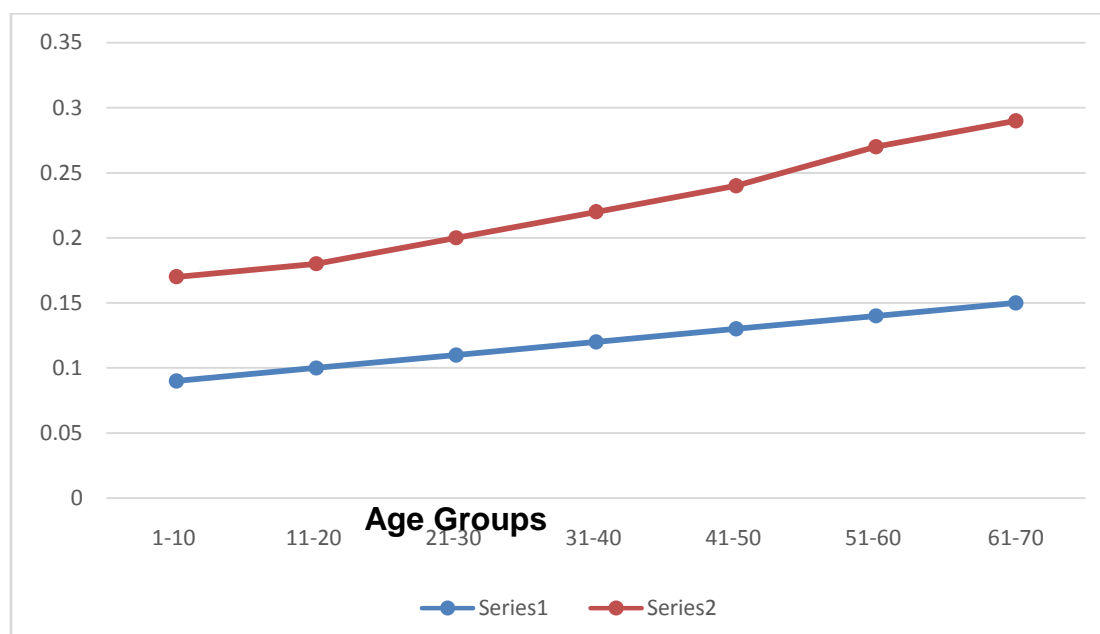


Figure 2: Graphical Representation of Bi-caudate index of the Different Age Group in Male and Female.

3.2 DISCUSSION

As the human brain ages, characteristic structural changes occur that are considered to be normal and are expected. Thus the thorough knowledge of the age related normal changes that occur in the brain is required before any abnormal findings are analyzed.¹⁴

Bi-caudate index (BCI) was found to be more sensitive in showing the age changes than other linear ratios.⁴ In this study we observed a gradual increase in the bi-caudate index from 1 year up to 70 years in both males and females. The BCI in males is generally larger than those of the females across all the age groups; but the differences are not statistically significant. The BCI varies from 6mm to 21mm in males and 5mm to 19mm in females. Similar findings were reported by Hahn and Rim who noted the values of BCI to vary between 8mm and 23mm with a mean value of 0.15 ± 0.03 .¹⁰ Ambili in a study among Indians reported Bi Caudate Index to vary from 0.06cm to 0.20cm, with a mean value of 0.12.¹³ However, the Bi Caudate Index in their study showed a statistically significant positive correlation with age which is different from our study in which there was no statistically significant correlation with age between males and females. Pelicci, considered the ratio to be abnormal if >0.17 and a definite enlargement if >0.20 , and his values were between 0.06cm and 0.19cm with a mean value of 0.11 ± 0.03 .¹³ In a study the Bi Caudate Index reported was between 0.06cm and 0.12cm.¹¹ Ambili reported a range of 0.06cm to 0.20cm with a mean value of 0.12 ± 0.02 .¹³ These findings corroborate with the finding in the current study.

Whereas the age-related decline in gray matter volume is relatively linear from younger age to adulthood, the corresponding decline in white matter tends to be nonlinear, with a plateau in middle-age and additional decline, beyond that of gray matter, in late adulthood.¹⁵

4. CONCLUSION

Base line data was provided in our environment with respect to bi-caudate index which can be used in assessing age-related decline in gray matter volume in relation to sex and to objectively judge ventricular

dilatation by Radiologist, Neurologist, Neuro-surgeons and Psychiatrist to help in proper management of patient

REFERENCE REFERENCES

- 1- Vandersloten, E., Bertrand, P.G., Vaillant, M.C., Laugier, J.. Area of lateral ventricles on cranial ultrasonography in preterm infants: reference range. *Archive Disease Child* 2008; 65: 1029-1032.
- 2- Gomeri, J.M., Steiner, I. and Melamed, E.. The assessment of changes in brain volume using combined linear measurement: A CT study. *Neuroradiology*. 1984; 26, 21-24.
- 3- Jacoby, R.J., Levy, R., Dawson, J.M. Computed tomography in the elderly. The normal population. *British Journal of Psychiatry* 1980;1;136, (3): 249-55.
- 4- LeMay, M. Radiologic changes of the aging brain and skull. *American journal of roentgenology*1984; 143: 383-89.
- 5- McCarley, R.W., Shenton, M.E., O'Donnell, B.F., Faux, S.F., Kikinis, R., Nestor, P.G. and Jolesz, F.A. Auditory P300 abnormalities and left posterior superior temporal gyrus volume reduction in schizophrenia. *Archives of General Psychiatry* 1993; 1, 50(3): 190-7.
- 6- Ashtari, M., Zito, J.L., Gold, B.I., Lieberman, J.A., Borenstein, M.T. and Herman, P.G. Computerized volume measurement of brain structure. *Investigative Radiology* 1990; 1;25(7):798-805.
- 7- Gallia, G.L., Rigamonti, D. and Williams, M.A. The diagnosis and treatment of idiopathic normal pressure hydrocephalus. *Nature Clinical Practice Neurology* 2006; 1;2, (7): 375-81.
- 8- Duffner, F., Schiffbauer, H., Glemser, D., Skalej, M. and Freudenstein, D. Anatomy of the cerebral ventricular system for endoscopic neurosurgery: a magnetic resonance study. *Surgical Radiological Anatomy* 1990; 12, (2): 135-41.
- 9- Williams, P.L., Bannister, H., Berry, M.M., Collins, P., Dyson, M., Dssek, J.E. and Fergusson, M.W. *Gray's Anatomy*. 38th edition, Churchill Livingstone. London 1999; Pp123-126, 486-490, 1205-1206.
- 10- Hahn, F.J., Rim. K. Frontal ventricular dimensions on normal computed tomography. *American Journal of Roentgenology* 1976;26, (3): 593-596.
- 11- Wilk, R., Kluczevska, E., Syc, B. Normative values for selected linear indices of the intracranial fluid spaces based on CT images of the head in children. *Poland Journal of Radiology* 2011; 76, (3): 16-25.
- 12- Pelicci, L.J., Bedrick, A.D. and Cruse, R.P. Frontal ventricular dimensions of brain in infants and children. *Archives Neurology* 1979;36, (13): 852-853.
- 13- Ambili, P. Ct measurements of two cerebroventricular indices and their relation with age. *Journal of Evidence Based Medicine Health* 2017; 4(6): 303-306.
- 14- Brij, R.S., Ujwal, G., Amit, A., Anilkumar, R.Y., Sunita, B. Ventricles of brain: a morphometric study by computerized tomography. *International Journal of Medicine and Research Health Science* 2014; (2): 381-387.
- 15- Marner, L., Nyengaard, J.R., Tang, Y. and Pakkenberg, B. Marked loss of myelinated nerve fibers in the human brain with age. *Journal of Comparative Neurology* 2003; 462: 144–52.