

Evisceration Of Bowel: Sequelae Of High Velocity Injury

Abstract

Bowel evisceration is an uncommon finding after blunt abdominal trauma, therefore it warrants prompt action and urgent intervention in form of emergency laparotomy.

We report a young male who sustained multiple abdominal injuries due to a high impact mechanism resulting in bowel evisceration and underwent emergency laparotomy.

Case report: In a high speed motorcycle accident a 18 year old male sustained a direct blunt injury to his abdomen which resulted in a perforation of the stomach, transection of colon, multiple mesenteric injuries and B/L pneumothorax. The abdominal wall split transversely extruding intact bowel. After resuscitation according to ATLS guidelines, patient was taken for emergency laparotomy. After 20 days in Intensive Care Unit and surgical ward, patient was discharged in a satisfactory condition.

Conclusion: High velocity blunt trauma to abdomen results in high mortality and morbidity. Blunt trauma resulting in evisceration requires prompt intervention, and the approach is tailored according to the magnitude of injury.

Keywords: blunt trauma abdomen, damage control surgery, exploratory laparotomy, bowel perforation, pneumothorax, gastrectomy

Introduction

“Traumatic injury is the leading cause of emergency department admissions disability and death. Motor vehicle accident is one of the significant causes of injury related death across the world” [8,11].

“Moreover in trauma patients, abdomen is the third most common injured region. Abdominal organ evisceration is uncommon to be encountered particularly after blunt trauma” [11]

Case report

An eighteen year old Indian male, a victim of a high speed motorcycle accident, lost control of vehicle and rammed into another vehicle following which a blunt object hit him in stomach resulting in the below mentioned injuries (Figure 1a and 1b). He was not wearing any personal protective gear.

He was brought to trauma centre of JNMCH. At the time of presentation his vitals were as follows: PR-112/min, BP-96/60 mm of hg, RR 22/min sPO2 96% on room air with severe bowel evisceration. (Figure a and 1b). He was resuscitated immediately according to ATLS guidelines.

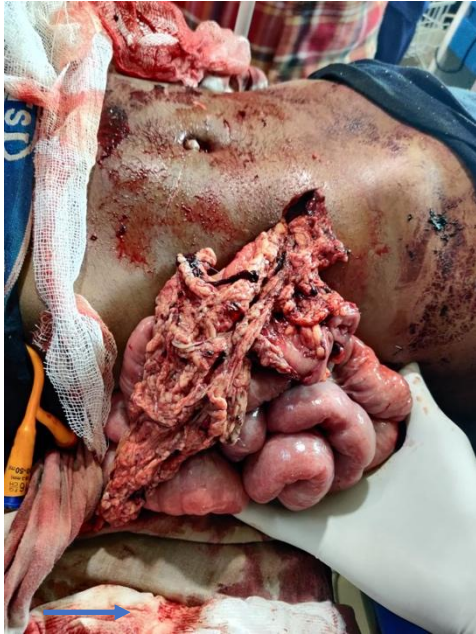

Figure 1a

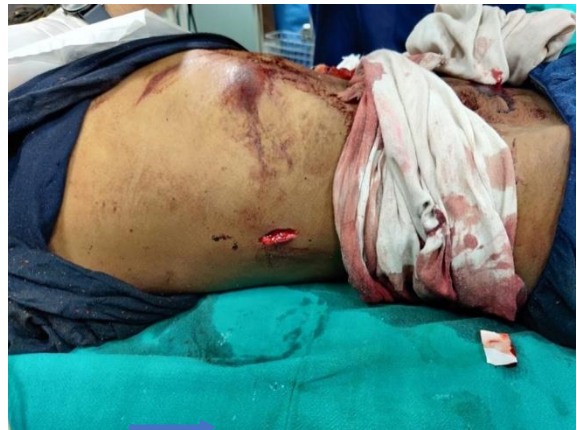

Figure 1b

Fig 1(a,b) : Morphology of severe bowel evisceration

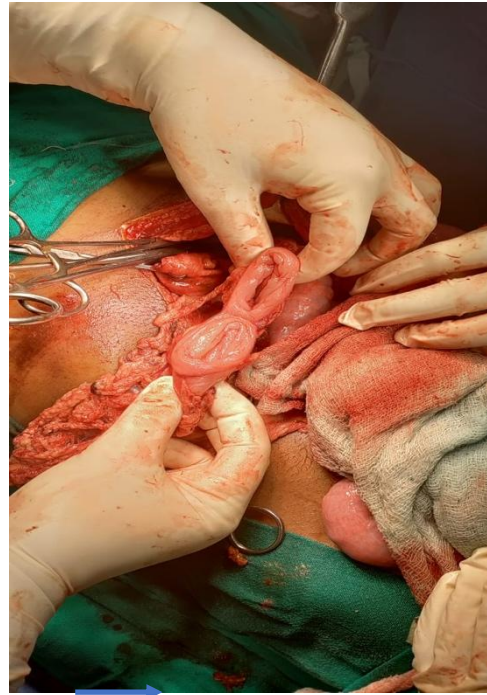
After resuscitation, patient was immediately taken to emergency surgery OT for exploratory laparotomy as a damage control surgery after primary survey.

Upon exploration following findings were seen (Figure 2a and 2b):

- Stomach was perforated at greater curvature with Ryle's tube in situ.
- Transverse colon was transected.
- Multiple mesenteric injuries.
- Multiple injuries over parietal abdominal wall.
- All solid organs were normal.

Above findings were managed by:

- Perforation at stomach was closed primarily by polyglactin suture and omental patch repair.
- Transected transverse colon was closed primarily with polyglactin suture.
- A loop ileostomy was made at 1.5 feet proximal to ICJ



- Mesenteric injuries were primarily repaired with absorbable suture.
- Parietal abdominal wall injuries were closed with polyglactin suture.

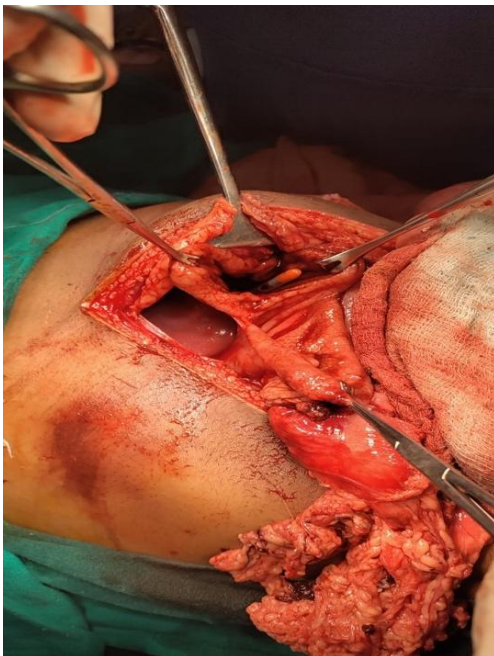


Figure 2a

Figure 2b

Fig (2a,b): Exploratory laparotomy as a damage control surgery

The abdomen was closed primarily and the patient was extubated and shifted to X-ray.

Chest X-ray was done which revealed B/L pneumothorax (Figure 3), for which B/L intercostal chest tube was inserted in Intensive Care Unit.

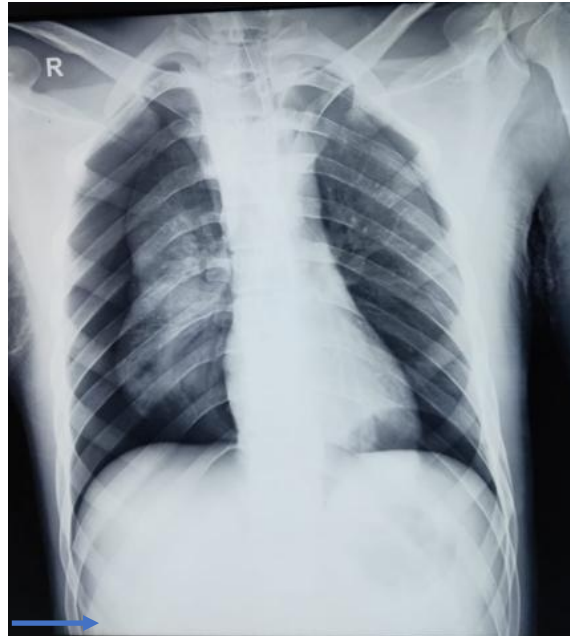

Figure 3: Chest Xray showed B/L pneumothorax

Patient was kept in surgical HDU for 12 days. Aggressive chest physiotherapy was done and chest tube was removed on Post-op day 6. Wound was healthy with no discharge. Patient was ambulated from Post-op day 2. Stoma was functional on Post-op day 4. Patient was kept nil per oral for 8 days after which oral sips were started gradually. Ryle's tube was removed and drains were removed subsequently. Patient was discharged in satisfactory condition.

Currently the patient is on regular outpatient follow-up and maintaining satisfactory condition with resolution of his injuries and functional ileostomy.

Discussion

Bowel evisceration is thought to occur from a simultaneous surge in abdominal pressure and presence of shearing forces. Viability of the eviscerated organ is to be assessed. The evisceration of organs was as follows (number of patients): Small bowel in 27 (40.9%), stomach in 2 (3%), colon in 1 (1.5%), small bowel and stomach in 2 (3%), and small bowel and colon in 3 (4.5%).

Small and large bowel injuries commonly occur following blunt trauma injury to abdomen, although less common than solid organ injury. Incidence of gastric

perforation following blunt trauma to abdomen is unusual presentation and usually results following a high speed injury to abdominal wall resulting in abdominal wall dehiscence. Site and location of the injury, time of the last meal and seat belt use are some of the factors influencing the gastric injury.

The surgical management in small or single lesions is comprised of debriding the wound and simple suturing. Partial gastrectomy might be indicated in cases with extensive damage to the stomach.

“Duodenal injury is extremely rare to be found after blunt abdominal trauma accounting for only 0.2%. Moreover, duodenal injury range from intramural hematoma to a complete duodenal transection and devascularization.

Management ranges from primary closure to resection and anastomosis, which is the method used in most cases where there is extensive damage” [11].

The serosal tear is considered the most common colonic injury in blunt abdominal trauma.

Emergency laparotomy should be done in evisceration of both omentum and organ, and in suspected cases of peritonitis.

Conclusion

Patients with severe injury mechanism have high mortality and morbidity rates.

Evisceration injuries require prompt, expeditious and timely intervention with damage control procedures. Throughout the course of therapy, till recovery and rehabilitation, a multidisciplinary team approach is required.

Ethical Approval:

As per international standard or university standard written ethical approval has been collected and preserved by the author(s).

Consent

Written informed consent was obtained from the patient for publication of this case report and accompanying images.

References

- 1) El-Menyar A., Parchani A., Peralta R., Zarour A., Al-Thani H., Al-Hassani A. Frequency, causes and pattern of abdominal trauma: a 4-year

descriptive analysis. *J. Emerg. Trauma Shock.* 2015;8(4):193. [PMC free article] [PubMed] [Google Scholar]

- 2) O'Rourke MC, Landis R, Burns B. Blunt Abdominal Trauma. [Updated 2023 Feb 15]. In: StatPearls [Internet]. Treasure Island (FL): StatPearls Publishing; 2023 Jan-. Available from: <https://www.ncbi.nlm.nih.gov/books/NBK431087/>
- 3) Cawich S, Islam S, Harnarayan P, Young-Pong C: Abdominal wall disruption with evisceration after blunt trauma. *BMJ Case Rep.* 2014, 2014:10.1136/bcr-2014-203646
- 4) O. Matsevych, M. Koto, S. Motilall, N. Kumar, The role of laparoscopy in management of stable patients with penetrating abdominal trauma and organ evisceration, *J. Trauma Acute Care Surg.* 81 (2) (2016) 307–311
- 5) Matsevych Y, Koto MZ, Motilall SR, Kumar N. The role of laparoscopy in management of stable patients with penetrating abdominal trauma and organ evisceration. *Journal of Trauma and Acute Care Surgery.* 2016 Aug 1;81(2):307-11.
- 6) R.A. Agha, M.R. Borrelli, R. Farwana, K. Koshy, A. Fowler, D.P. Orgill, For the SCARE Group, The SCARE 2018 statement: updating consensus surgical CAse REport (SCARE) guidelines, *Int. J. Surg.* 60 (2018) 132–136.
- 7) C. Ull, S. Bensch, T. Schildhauer, J. Swol, Blunt pancreatic injury in major trauma: decision-making between nonoperative and operative treatment, *Case Rep. Surg.* 2018 (2018) 1–5.
- 8) Guillen B, Cassaro S. StatPearls [Internet]. StatPearls Publishing; Treasure Island (FL): Jul 12, 2022. Traumatic Open Abdomen. [PubMed]
- 9) Tomic I, Dragas M, Vasin D, Loncar Z, Fatic N, Davidovic L. Seat-Belt Abdominal Aortic Injury-Treatment Modalities. *Ann Vasc Surg.* 2018 Nov;53:270.e13-270.e16. [PubMed]
- 10) Essola B, Batamag JBB, Engbang JP, Djomo D, Ngaroua E, et al. Blunt abdominal trauma with duodenal dissection: A case report. *Arch Case Rep.* 2021; 5: 023-026. 10.29328/journal.acr.1001051
- 11) Arwa H. Ibrahim, Adel J. Osman, Mosab A. Alarfaj, Case report: Evisceration of abdomen after blunt trauma, *International Journal of Surgery Case Reports*, Volume 72, 2020, Pages 207-211, ISSN 2210-2612, <https://doi.org/10.1016/j.ijscr.2020.05.037>.

