

# Coronavirus disease2019 – Dengue Fever Coinfection : A Case Report

## Abstract

A lot of coronavirus disease 2019 (COVID-19) related deaths were reported in Yemen (about what risk factors contributing to this excess death ?*This phrase appears to be hanging. – please delete*) Hodeidah governorate at Western part of Yemen and other governorates in Yemen are exposed to COVID-19 pandemic in addition to other current chronic diseases problems and endemic of vector – borne diseases namely malaria and dengue. The aim of this case report is to explore more data about COVID-19 – dengue fever coinfection related deaths in Hodeidah, Yemen. (*With... Delete*) Both infections are causes of high mortality rates. The case reported here shows a 25 -year-old male with major symptoms of, cough , hypoxia , fever (38 °C), difficult in breathing , and bleeding from nose and oxygen saturation (O<sup>2</sup>) of 70 % , respiratory rate (RR) of 30 ipm, blood pressure of 120/ 80 mmHg, and heart rate (HR) of 120 bpm”. The patient was diagnosed with bilateral ground glasses opacity based x – ray with leukocytosis ,lymphopenia , neutrophilia , and thrombocytopenia. The level blood sugar was normal , increase in liver enzyme was observed. Mild increase in serum creatinine, CRP high reactivity with positive COVID -19 and hemorrhagic dengue fever were observed . The patient (*was... delete*) died within two hours in triage. In conclusion , the co-infections with other infection like dengue is of high concern and this is the first reported case of COVID -19 and dengue coinfection presented as stroke and highlights the complex context of diagnostic and therapeutic management in tropical settings such as Hodeidah, Yemen.

**Keywords :** COVID – 19 , Dengue , Co- infection, Hodeidah , Yemen

## Introduction

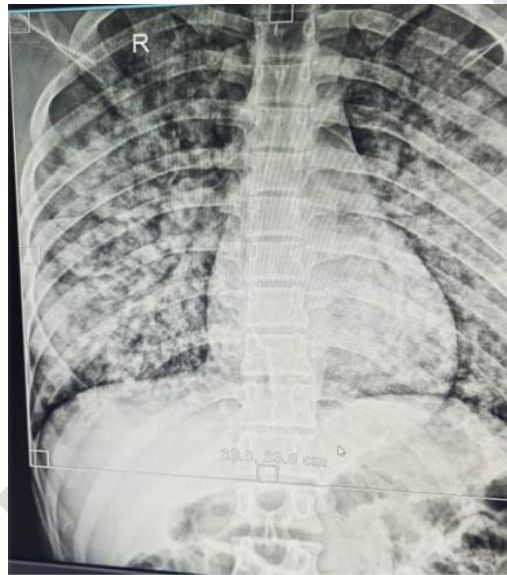
Coronavirus disease 2019 (COVID-19) is a respiratory disease caused by a single-stranded positive sense RNA virus that was first isolated in December 2019 after it emerged in Wuhan, China [1,2]. In Yemen, the first case was registered on April 10,

2020 in Hadhramout [3], with further cases later identified in other parts of the country as the disease spread. Hodeidah governorate lies in the western part of Yemen, and other governorates in Yemen, have been exposed to the COVID-19 pandemic, adding to the ongoing chronic challenges in the region. Hodeidah is facing a complex spectrum of determinants of health, including poverty, illiteracy, food insecurity, malnutrition and multiple epidemics as well as humanitarian crises resulting from the armed war that has been ongoing since 2015. At the time of writing, no research has been conducted to document the COVID-19 pandemic in Hodeidah, especially related to morbidity and mortality. Several other notable disease outbreaks included malaria, dengue fever [4 -6], chikungunya [7], west – Nile virus [8], cholera [9], diphtheria [10 -11] and measles [12 -13] were reported in Hodeidah, Yemen. 49 /505 cases (severe and critical) were confirmed based on RT – PCR [14,15]. Al Kamarany et al (?year) reported 68.05 % of Hodeidah people exposed to COVID-19 infection based on immunological method [16]. Previous study reported a high prevalence of malaria – dengue co-infection in Hodeidah, Yemen as the first time (37 %). These due to a high density of vectors in this region and endemic areas for malaria and dengue [4]. Therefore, the aim of this case report is to explore more data about COVID-19 – dengue fever coinfection related death in Hodeidah, Yemen.

### **Case Presentation**

The patient was received and assessed clinically in triage unit of COVID – 19, isolation department, Center of Tropical Medicine and Infectious Diseases (CTMID), AL-Thawrah Public Hospital Authority, Hodeidah, Yemen. A 25 -year-old male, cough , hypoxia , fever (38 °C) , difficult in breathing , and bleeding from nose as major of symptoms with oxygen saturation (O<sub>2</sub>) of 70 % , respiratory rate (RR) of 30 ipm, blood pressure of 120/ 80 mmHg, and heart rate (HR) of 120 bpm” .Chest – radiography , complete blood count , C – reactive protein (CRP) , nasopharyngeal swab and dengue assay were carried out . The patient was diagnosed with bilateral ground glasses opacity with leukocytosis (26000 Cell/mm<sup>2</sup>) , lymphopenia (6 % ) , neutrophilia (90 % ) , thrombocytopenia (141 x 10<sup>3</sup> /L) , and a hemogram noted hematocrit 47%. The blood sugar level was normal (131 mg/dl) , increase in liver enzyme (51 IU of GPT and 157 IU of GOT) was observed. Mild increase in serum creatinine (1.6 mg/dl). On the other mean , increase the neutrophil \ lymphocyte ratio (15 % ) with CRP was high reactivity with positive COVID -19 and hemorrhagic

dengue fever . The patient(was... delete) died within two hours in triage. In conclusion, Covid-19co-infections with malaria and viral infections like dengue is of high concern.This is the first reported case of COVID -19 and dengue coinfection presented as stroke and it highlights the complex context of diagnostic and therapeutic management in tropical settings such as Hodeidah, Yemen.



**Figure 1.** Chest X-ray shows peripheral and lower opacities “Bilateral pleural effusion with % of the lungs are

ray shows peripheral of both lungs asymmetric - no about more than 50 involved.

**Table 1.** Results of haematological parameters

Parameters	Values	Normal values (17,18)
RBC ( $\times 10^9/L$ )	5.5	3500-5000
Hb (g/dl)	16.5	12-15
PCV (%)	45.3	35-45
WBC ( $\times 10^9/l$ )	26200	$3.5 \pm 7.5$
Neutrophil (%)	90	40-75
Lymphocyte (%)	6	20-45
Monocyte (%)	2	2-10
Eosinophil (%)	2	1-6
Basophil (%)	0	0-1
Platelets ( $\times 10^3/ul$ )	161	150-450

**Table 2.** Results of biochemical parameters

Parameters	Values	Normal values
Random Blood Sugar mg/dl	131	140-180

ALT IU/L	51	17-63
AST IU/L	157	0-37
Serum creatinine mg/dl	1.6	0.1 -1.2
Blood urea mg/dl	43	5-20
Na+ mmol/L	143	135-146
K+ mmol/L	5.0	3.5-5
CRP	43	Up to 6

## Discussion

The study focused on epidemiological and clinical features of COVID -19 – dengue fever coinfection in Hodeidah, Yemen. (Delete) While the COVID-19 pandemic takes the world by storm, dengue-endemic regions risk developing a co-epidemic in COVID-19/dengue coinfection. Several cases were emerged in different countries. In Philippines It was reported that a 38-year-old male patient with high-grade fever, presented with complaints of nausea, joint, and muscle aches, all characteristic symptoms of COVID-19 and dengue but was not severe, although the tests confirmed the infections to be “moderate to severe” and showed steady and rapid recovery (19). Previous studies in Latin America reported that coinfection with SARS-CoV-2 and dengue virus is associated with worse outcomes with significant morbidity and mortality. (The delete) Similar clinical and laboratory features of each infection are a challenge in accurately diagnosing and treating cases. Establishing an early diagnosis could be the answer to reducing the estimated significant burden of these conditions (20). Two cases were reported in Maldives , Case 1 was a 39-year old Asian male, presented on day 6 of dengue infection with warning signs. Case 2 was a 38-year old Asian male, was admitted on day 5 of illness with symptoms of acute respiratory infection. Evaluation of progressive leukopenia and thrombocytopenia showed positive dengue serology (21). Study identified two pregnancies with dengue and COVID-19 co-infection; one ended with premature rupture of membrane and intrauterine growth restriction fetus, while the other one ended with maternal mortality and intrauterine fetal death. COVID-19 and dengue co-infection had worse outcomes regarding mortality rates, ICU admission, and prolonged hospital stay. Thus, wise-decision management approaches should be adequately offered to these patients to enhance their outcomes. Establishing an early diagnosis might be the answer to reducing the estimated significant burden of these conditions (22). COVID-19 and dengue co-infection was associated with severe disease and fatal outcomes. The correct diagnosis and treatment of co-infection poses

a substantial challenge due to the overlapping clinical and laboratory parameters. Therefore, confirmative diagnostic tests are necessary for accurate and timely diagnosis and patient management (23). Finally, Old age and co-morbidity with non-communicable diseases may be contributing factors to excess deaths among SARS-CoV-2 patients. Co-infections with other infections like dengue is of high concern in Hodeidah, Yemen (24,25).

### **Conclusion**

The co-infections with other infection like dengue is of high concern and this is the first reported case of COVID -19 and dengue coinfection presented as stroke and highlights the complex context of diagnostic and therapeutic management in tropical settings such as Hodeidah, Yemen and may be contributing factor to excess deaths.

### **CONSENT**

As per international standards or university standards, Participants' written consent has been collected and preserved in Medical File. The raw data are secured in CTMES – HU and CTMID, Hodeidah, Yemen.

### **ETHICAL APPROVAL**

The studies involving human participants were reviewed and approved by the Ethics Committee of CTMES – HU, Hodeidah, Yemen.

### **References**

1. Lai CC, Shih TP, Ko WC, Tang HJ, Hsueh PR. Severe acute respiratory syndrome coronavirus 2 (SARS-CoV-2) and coronavirus disease-2019 (COVID-19): The epidemic and the challenges. *Int J Antimicrob Agents*. 2020 Mar;55(3):105924. doi: 10.1016/j.ijantimicag.2020.105924. Epub 2020 Feb 17. PMID: 32081636; PMCID: PMC7127800.
2. Gundlapally J, Kumar A, Kashyap A, Saxena AK, Sanyal A. In Search of Novel Coronavirus 19 Therapeutic Targets. *Helix*. 2020;10:02: DOI: 10.29042/2020-10-2-01-08
3. Novel Coronavirus COVID-19". Yemen Supreme National Emergency Committee for Covid-19. Retrieved 9 December; 2020.
4. Al-Areeqi, A., Alghalibi, S., Yusuf, Q., Al-Masrafi, I., & Al-Kamarany, M. A. Epidemiological Characteristic of Malaria Coinfected with Dengue Fever in

- Hodeidah, Yemen. International Journal of TROPICAL DISEASE & Health, 2020 February ; 40(3), 1–10. <https://doi.org/10.9734/ijtdh/2019/v40i330230>
5. Alahdal, M., Al-Shabi, J., Ogaili, M., Abdullah, Q. Y., Alghalibi, S., Jumaan, A. O., & AL-Kamarany, M. A. Detection of Dengue Fever Virus Serotype – 4 by using One-Step Real-Time RT-PCR in Hodeidah, Yemen. Microbiology Research Journal International, 2016 May ; 14(6), 1–7. <https://doi.org/10.9734/BMRJ/2016/24380>
  6. Abdullah QY, Ogaili M, Alahdal M, AL-Kamarany MA. Dengue Fever Infection in Hodeidah, Yemen: risk factors and socioeconomic indicators. British Biomedical Bulletin. 2015;3(1):058-065. Google Scholar
  7. Malik MR, Mnzava A, Mohareb E, Zayed A, Al Kohlani A, Thabet AA, El Bushra H. Chikungunya outbreak in Al-Hudaydah, Yemen, 2011: epidemiological characterization and key lessons learned for early detection and control. J Epidemiol Glob Health. 2014 Sep;4(3):203-11. doi: 10.1016/j.jegh.2014.01.004. Epub 2014 ... Too old) Mar 15. PMID: 25107656; PMCID: PMC7333817.
  8. Yusuf, Q., Al-Masrafi, I., Al-Mahbashi, A., Al-Areeqi, A., Al-Kamarany, M. A., & Khan, A. S. (2019). First Evidence of West Nile Virus in Hodeidah, Yemen: Clinical and Epidemiological Characteristics. International Journal of TROPICAL DISEASE & Health, 38(4), 1-9. <https://doi.org/10.9734/ijtdh/2019/v38i430190>  
<https://journalijtdh.com/index.php/IJTDH/article/view/30190>
  9. Al Sheebani S., Al-Kamarany M. A., Ghouth A. B., Kamal A., Alaq M. Acute renal failure induced by cholera: outbreak of Hodeidah, Yemen, 2017. European Journal of Pharmaceutical and Medical Research. 2018 July ;5(8):188–192
  10. Bin Ghouth, A., AL–Kamarany, M., Suhail, K., El-Absy, E., Abdulkarim, T., Majam, M., Khabaz, Y., Faqeeh, W., Al-Mahwety, W., Abu Talib, W., Al-Dhahwi, A., Hijam, M., Al-Ahdal, M., Muamer, H., & Bokhamy, S. Community Awareness about Diphtheria Prevention and Control in Hodeidah, Yemen 2018. International Journal of TROPICAL DISEASE & Health, 2018 May; 30(3), 1-7. <https://doi.org/10.9734/IJTDH/2018/40750>  
<https://journalijtdh.com/index.php/IJTDH/article/view/20743>

11. Mohammed Amood AL-Kamarany and Ahmed Majam . Monitoring Efficacy of Benzyl penicillin in Diphtheria Treatment based on Validated Hematological Analyzer in Hodeidah Outbreak , Yemen . *European Journal of Pharmaceutical and Medical Research* . 6 (4) 52 – 57 , 2019
12. How to Cite :Abdo M. S., AL Kamarany A.M., Suhail K.A., Majam A.S., (2022). Vaccination based Measles Outbreak Model with Fractional Dynamics, *Abhath Journal of Basic and Applied Sciences*, 1(2), 40-50.
13. Majam A, Mulhee N and AL Kamarany Amood A, (2023). Measles Virus Infection Among Vaccinated and Unvaccinated Children in Hodeidah, Yemen , Workshop about Quality , Safety and Efficacy of Vaccines , 19 – 20 March , Page 15
14. AL-Kamarany, M. A., Suhail, K. A., Majam, A. S., Abdulabari Alabsi, E., Hamoud Dowbalah, M., & Mohammed Zohairy, A. (2021). Epidemiological and Clinical Features of COVID-19 in Hodeidah, Yemen. *International Journal of TROPICAL DISEASE & Health*, 42(21), 28–40. <https://doi.org/10.9734/ijtdh/2021/v42i2130550>
15. Suhail, F. A., & Al Kamarany, M. A. Radiological Features of COVID-19 Patients in Hodeidah, Yemen. *Asian Journal of Research in Infectious Diseases*. 2021 December; 8(4), 117-127. <https://doi.org/10.9734/ajrid/2021/v8i430256>
16. Al-Kamarany, M. A., & Abdulkarim , T. (2023). Immunological Features of COVID-19 in Hodeidah, Yemen. *Asian Journal of Immunology*, 6(1), 76–84. Retrieved from <https://journalaji.com/index.php/AJI/article/view/97>
17. Al-Sheibani, S., Osman Taha, S., Balkam, F., Dhflash, A., & Amood Al-Kamarany, M. (2018). Validation Hematological Analyzer for Assay of Erythrogram in Hodeidah City, Yemen. *Asian Hematology Research Journal*, 1(1), 1-8. Retrieved from <https://journalahrj.com/index.php/AHRJ/article/view/13188>
18. AL Kamarany Amood M. Validation of Neutrophils - Lymphocytes Ratio for Monitoring of Therapeutic Efficacy of COVID -19 in Hodeidah , Yemen. *The second conference for laboratory medicine* . 20 – 23 Mar 2021, 43-44.
19. Prapty CNBS, Ahmed N, Araf Y, Yang Z, Zhai J, Hosen MJ, Zheng C. Coinfection of COVID-19 and Dengue: A Case Report. *Front Med*

- (Lausanne). 2022 Jul 27;9:872627. doi: 10.3389/fmed.2022.872627. PMID: 35991668; PMCID: PMC9386617.
20. León-Figueroa DA, Abanto-Urbano S, Olarte-Durand M, Nuñez-Lupaca JN, Barboza JJ, Bonilla-Aldana DK, Yrene-Cubas RA, Rodriguez-Morales AJ. COVID-19 and dengue coinfection in Latin America: A systematic review. *New Microbes New Infect.* 2022 Nov-Dec;49:101041. doi: 10.1016/j.nmni.2022.101041. Epub 2022 Oct 28. PMID: 36320316; PMCID: PMC9613782.
  21. Hilmy AI, Dey RK, Imad HA, Yoosuf AA, Nazeem A, Latheef AA. Coronavirus disease 2019 and dengue: two case reports. *J Med Case Rep.* 2021 Mar 26;15(1):171. doi: 10.1186/s13256-021-02707-7. PMID: 33771221; PMCID: PMC7995386.
  22. El-Qushayri AE, Kamel AMA, Reda A, Ghozy S. Does dengue and COVID-19 co-infection have worse outcomes? A systematic review of current evidence. *Rev Med Virol.* 2022 Sep;32(5):e2339. doi: 10.1002/rmv.2339. Epub 2022 Feb 25. PMID: 35213764; PMCID: PMC9111070.
  23. Tsheten T, Clements ACA, Gray DJ, Adhikary RK, Wangdi K. Clinical features and outcomes of COVID-19 and dengue co-infection: a systematic review. *BMC Infect Dis.* 2021 Aug 2;21(1):729. doi: 10.1186/s12879-021-06409-9. PMID: 34340682; PMCID: PMC8327042.
  24. AL Kamarany, M. A., Al-Masrafi, I., Ghouth, A. B., Suhail, K., Majam, A., Zuhairy, A., & Alabsi, E. (2023). Outbreak Investigation: First Ten COVID – 19 Infection Related Deaths in Hodeidah, Yemen. *Asian Journal of Research in Infectious Diseases*, 13(3), 19–27. <https://doi.org/10.9734/ajrid/2023/v13i3268>
  25. Majam A and AL KamaranyAmoodM , COVID -19 and Dengue Coinfection, Predication for Increasing the Mortality Rate: Case Report. The First Scientific Annual Conference of AL Thawara Public General Authority 2021