

Case study

A Sacrococcygeal Teratoma: Third Lower Extremity

Abstract

Teratomas develop most frequently in the sacrococcygeum and are often diagnosed by simple observation. Most sacrococcygeal teratomas are benign, and evident in the newborn. Surgery is the primary, usually curative treatment. In this report, an unusual form of sacrococcygeal teratoma which had morphology of lower extremity is presented.

Key Words : Sacrococcygeal teratoma, lower extremity, newborn.

Introduction

Teratoma is a tumor caused by pluripotent cells and occurs in the midline or on both sides of the body(1). Teratomas are rare (found in approximately one of every 35.000 live births) midline congenital tumors which develop most frequently in the sacrococcygeum (2,3,4). More common in girls than boys (5).This tumors are neoplasms composed of the tissue elements foreign to the organ or anatomic site of origin, which typically contain tissue elements of tridermal lineage, ectoderm, endoderm and mesoderm (6). With this case report, we wanted to evaluate sacrococcygeal teratoma in the light of literature.

Case Report

A three – day – old baby girl was referred to our hospital due to a sacrococcygeal mass which looks to a lower extremity (Fig. 1)

3300 gram baby was born to a 30 year old women at term following an uncomplicated pregnancy whose two other sons were healthy. No history of drug or medication, illnesses, trauma and irradiation during pregnancy was obtained. Routine laboratory tests were normal. Serum alpha fetoprotein (AFP) was higher normal and chorio embryonic antigen (CEA) was normal. Lateral X-ray film and CT scan of the mass revealed looks like to morphology (primitive two femur, short tibia and fibula bones) of a lower extremity (Fig. 2a and 2b)

Sagittal T1W MR image showed no relation between the mass and underlying organs including medulla spinalis. In addition to , fat and vasculer intensities was present in the mass. (Fig 3).

At operation 150 gram measuring 10x6x5 cm , sacrococcygeal mass did not demonstrate any invasion in to the underlying organs including medulla spinalis and was totally excised along with the coccyx. Postoperative period was not complicated. The mass was completely covered with skin and on crosscut sections immatur bones, cartilage and mature muscle tissues were detected.

Discussion

The sacrococcygeum is most frequent site for teratoma development. These tumors may be extrapelvic, extrapelvic / intrapelvic or intrapelvic (primarily presacral). Associated observable abnormalities of the spine are infrequent. Sacrococcygeal teratomas can become evident at any age, although the majority are noted at birth or soon after. Those tumors found after the first few months of life are not obvious masses or they are asymptomatic. They are usually readily diagnosed at birth, although the nature of the mass extend is not always obvious. Females are affected four times more often than males, but affected males are more likely to have malignant tumors (4,5).

Most of the teratomas can be diagnosed prenatally by ultrasound. CT , MRI , IVP and colon graphies may be useful to determine the relation between the tumoral mass and intrapelvic organs. The low-attenuation fatty components can be seen by CT and MRI which are diagnostic.

Mature or immature teratomas arises in any of the body, and are usually related to midline structures. In earlier times, teratomas were attributed to sexual abuse, and abnormal insemination (7). Matur teratomas are generally benign, and immature ones are generally malign (8) In sacrococcygeal teratomas, malignancy incidence is 7-10 % under 2 –month-old age; after this age the incidence increases to 48-67 %. Distant metastases mostly to pulmonary and bone tissues, have been reported in 5 per cent of the malignant teratomas (9).

The mass size does not appear to correlate with malignant content, although because larger lesions are more difficult to remove surgically the morbidity and mortality are higher. The literature suggests malignant transformation probably occurs. Therefore, delay in the treatment of these tumors should be avoided. The tumor may not manifest itself for long periods when it is completely presacral.

Cystic lesions, or solid lesions with calcifications, are more often benign than malignant; tumor invasiveness (gastrointestinal tract or genitourinary penetration) suggests malignancy. The tumors develops embryologically from multipotential cells which migrate caudally and come to lie within the coccyx (7). Tumor recurrence indicates incomplete removal of all tumor elements (or the coccyx), and suggests malignant transformation. Optimal treatment of sacrococcygeal teratomas (benign and malignant) is en block removal of the tumor along with the coccyx since recurrence is high when coccyx is not removed. The cure rate is excellent if the tumor is

completely excised, as in our case (5,8). Therefore neither chemotherapy nor radioteraphy were considered. In this case report, we evaluated the clinical presentation of sacrococcygeal teratomas and the management of the disease.

Figures

Figure 1. Macroscopic view of the sacrococcygeal mass

Figures 2a and 2b. Lateral plain film (2a) and CT scan of the mass (2b) showing primitive bone structures which looks like to lower extremity.

Figure 3. Post enhanced sagittal T1W (TR/TE:500/15 ms) MR image demonstrated fatty components and vascular structures.

References

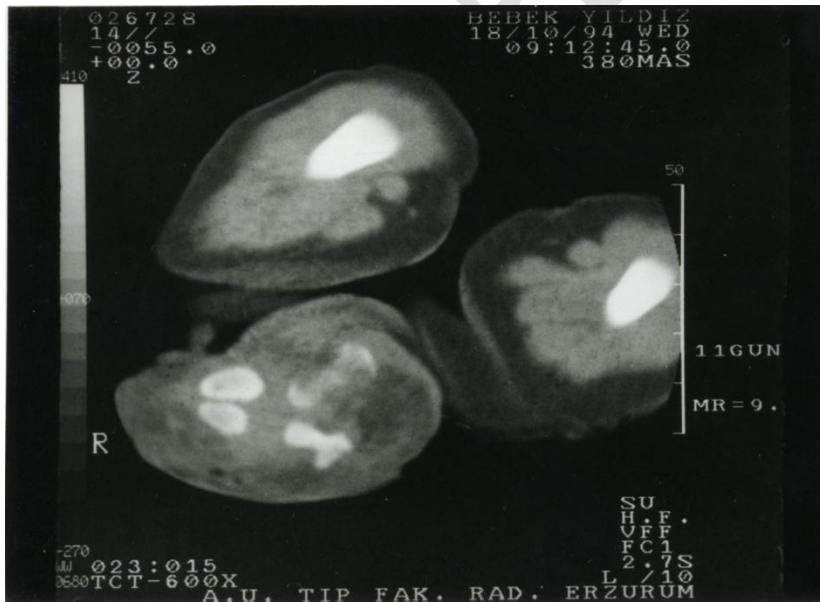
- Liu JL, Sun PL. Rectal mature [HYPERLINK](https://pubmed.ncbi.nlm.nih.gov/36158485/)
["https://pubmed.ncbi.nlm.nih.gov/36158485/"](https://pubmed.ncbi.nlm.nih.gov/36158485/) [HYPERLINK](https://pubmed.ncbi.nlm.nih.gov/36158485/)
["https://pubmed.ncbi.nlm.nih.gov/36158485/"](https://pubmed.ncbi.nlm.nih.gov/36158485/) [HYPERLINK](https://pubmed.ncbi.nlm.nih.gov/36158485/)
["https://pubmed.ncbi.nlm.nih.gov/36158485/"](https://pubmed.ncbi.nlm.nih.gov/36158485/) [HYPERLINK](https://pubmed.ncbi.nlm.nih.gov/36158485/)
["https://pubmed.ncbi.nlm.nih.gov/36158485/"](https://pubmed.ncbi.nlm.nih.gov/36158485/) [HYPERLINK](https://pubmed.ncbi.nlm.nih.gov/36158485/)
["https://pubmed.ncbi.nlm.nih.gov/36158485/"](https://pubmed.ncbi.nlm.nih.gov/36158485/): A case report. World J Clin Cases. 2022 Aug 6;10(22):7883-7889. doi: 10.12998/wjcc.v10.i22.7883.
- Salim A, Raitio A, Losty PD. Long-term functional outcomes of sacrococcygeal [HYPERLINK](https://pubmed.ncbi.nlm.nih.gov/36127201/)
["https://pubmed.ncbi.nlm.nih.gov/36127201/"](https://pubmed.ncbi.nlm.nih.gov/36127201/) [HYPERLINK](https://pubmed.ncbi.nlm.nih.gov/36127201/)
["https://pubmed.ncbi.nlm.nih.gov/36127201/"](https://pubmed.ncbi.nlm.nih.gov/36127201/) [HYPERLINK](https://pubmed.ncbi.nlm.nih.gov/36127201/)
["https://pubmed.ncbi.nlm.nih.gov/36127201/"](https://pubmed.ncbi.nlm.nih.gov/36127201/) [HYPERLINK](https://pubmed.ncbi.nlm.nih.gov/36127201/)
["https://pubmed.ncbi.nlm.nih.gov/36127201/"](https://pubmed.ncbi.nlm.nih.gov/36127201/) [HYPERLINK](https://pubmed.ncbi.nlm.nih.gov/36127201/)
["https://pubmed.ncbi.nlm.nih.gov/36127201/"](https://pubmed.ncbi.nlm.nih.gov/36127201/) - A systematic review of published studies exploring 'real world' outcomes. Eur J Surg Oncol. 2022 Sep 7:S0748-7983(22)00653-9. doi: 10.1016/j.ejso.2022.09.002.
- Marcu ML, Bacalbaşa N, Candrea E, Stănică CD, Massawi T, Chirilov A, Neacşu A, Pacu I. Fetal sacrococcygeal immature teratoma - report of two cases and review of the

literature. Rom J Morphol Embryol. 2022 Jan-Mar;63(1):203-207. doi: 10.47162/RJME.63.1.22.

- Backer D, Erpicum P, Philippe P, Demarche M, Otte JB, Schwagten K, et al. Sacrococcygeal teratoma: Results of a retrospective multicentric study in Belgium and Luxembourg. *Eur J Pediatr Surg.* 2001;11:182–185.
- Keslar PJ, Buck JL, Suarez ES. Germ cell tumours of the sacrococcygeal region: radiologic-pathologic correlation. *Radiographics.* 1994;14:607–620
- Tapper D, Lack EE (1983) ; Teratomas in infancy and childhood. *Ann. Surgery* 198 : 398.
- Gatcombe HG, Assikis V, Kooby D, Johnstone PA. Primary retroperitoneal teratomas: a review of the literature. *J Surg Oncol.* 2004;86:107–113.
- Jordan RB, Gauderer MV (1988) Cervical teratomas : An analysis. Literature review and proposed classification. *J. Pediatr Surg.* 23 : 583.
- Schey WL, Shkolnik A, White H (1977) ; Clinical and radiographic considerations of sacrococcygeal teratomas : An analysis of 26 new cases and review of the literature. *Radiology* 125 : 189.

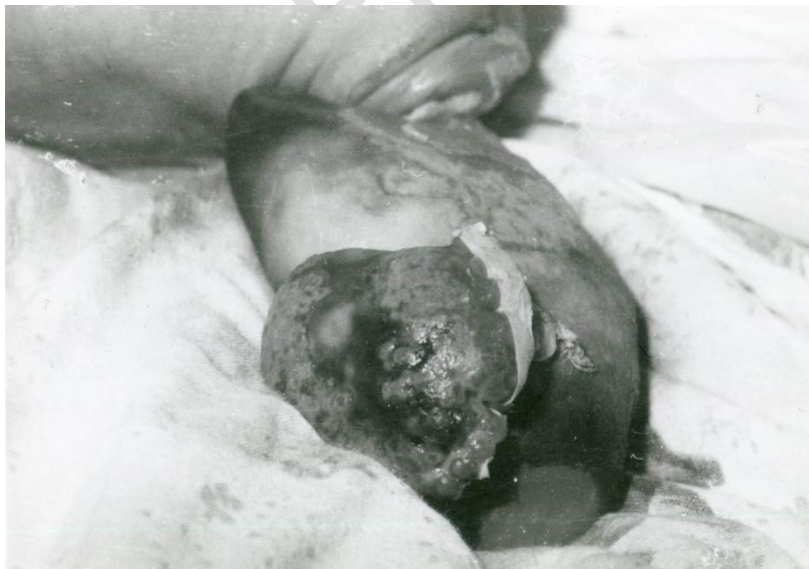

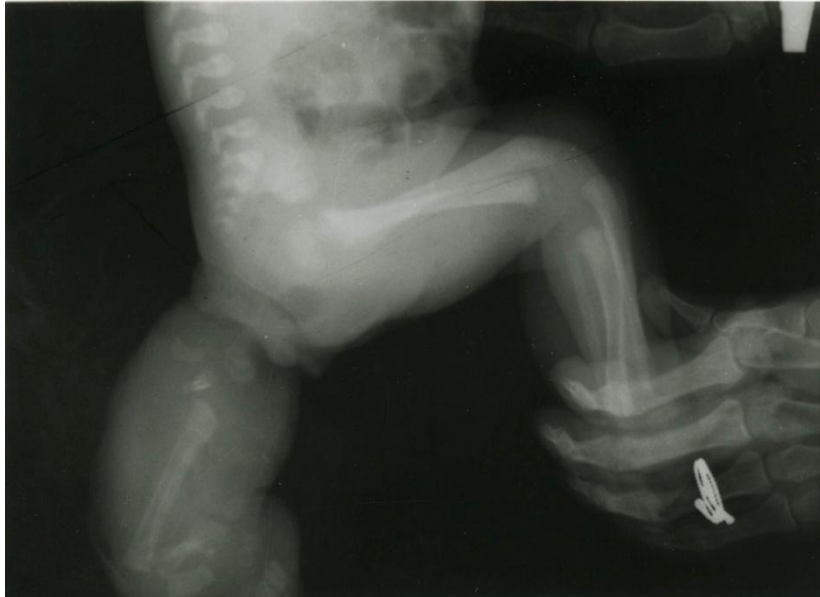Figure 1. Macroscopic view of the sacrococcygeal mass



Figures 2a and 2b. Lateral plain film (2a) and CT scan of the mass (2b) showing primitive bone structures which looks like to lower extremity.

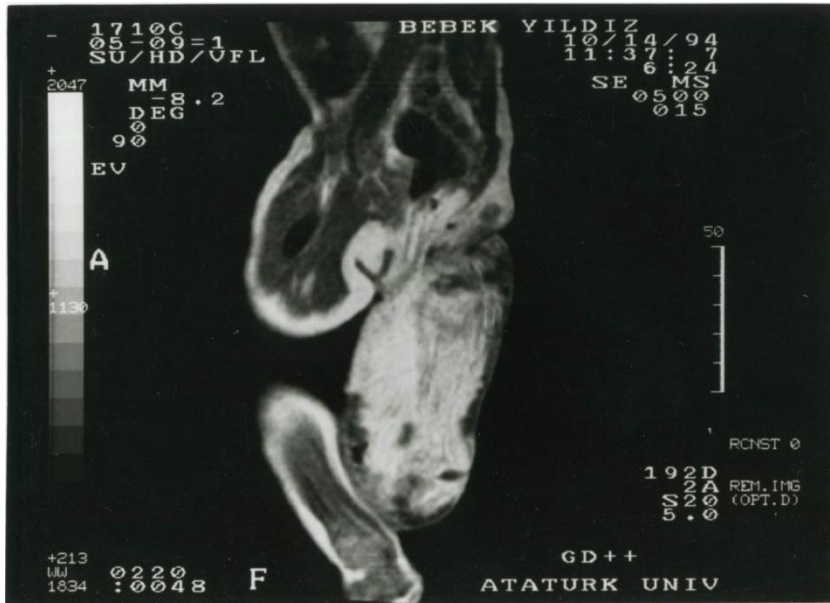


Figure 3. Post enhanced sagittal T1W (TR/TE:500/15 ms) MR image demonstrated fatty components and vascular structures.