

# Hemiagenesis of Right Hemithyroid with Left Lobe Multinodular Goitre

---

## ABSTRACT

**Aims:** To present the case of a patient with an uncommon congenital abnormality and discuss its consequence and management.

**Presentation of Case:** We present the case of a 62 year old female patient with no thyroid function abnormalities and no previous neck surgery who was sent to our outpatient clinic for a left sided neck mass with associated discomfort. An ultrasound revealed a left sided multinodular goitre and the absence of the right lobe. A TC scan confirmed these findings. A fine needle aspiration cytology excluded malignancy. A total thyroidectomy was performed and the patient prescribed levothyroxine. There were no intraoperative or postoperative interferences and the patient remains asymptomatic four years later.

**Discussion:** Thyroid gland hemiagenesis is a rare congenital disorder consisting in the absence of a thyroid lobe. Left lobe agenesis is the most frequent and females are more commonly affected. Despite this, thyroid-stimulating hormone and free T3 levels are higher than in individuals without this condition and higher risk of thyroid disease has been suggested.

**Conclusion:** Thyroid gland hemiagenesis is rare. Patients are usually asymptomatic and the condition is found incidentally during screening tests or exams driven by other pathology. Its existence should be recognized for patients to be well studied and treated.

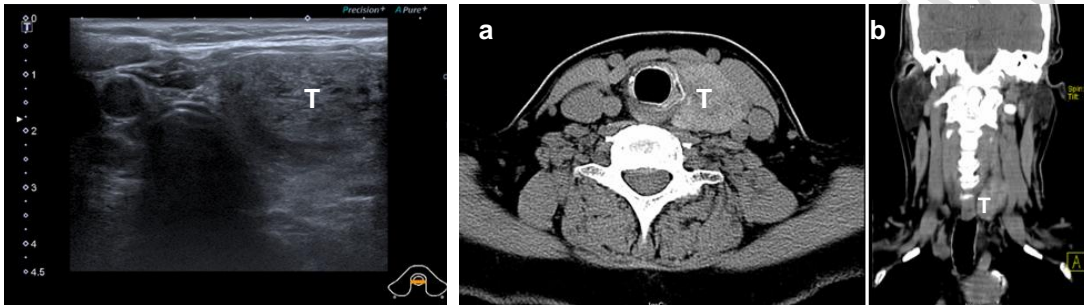
*Keywords: Thyroid hemiagenesis, Multinodular goitre, Left lobe multinodular goitre, Thyroid congenital abnormality*

## 1. INTRODUCTION

Thyroid gland hemiagenesis and consequent inexistence of one of the thyroid lobes is a rare congenital disorder with an estimated prevalence from 0,05% to 0,5% and occurring more frequently in females with an estimated 7:1 ratio [1, 2]. Although mainly sporadic, familial clustering has been described [3]. Left lobe hemiagenesis is the most frequent one, occurring in up to 87% of the cases with absence of the isthmus in 40 to 50%). Patients with this condition are usually asymptomatic but can develop thyroid pathology and, despite being euthyroid, have commonly levels of thyroid-stimulating hormone (TSH) and free T3 (fT3) higher than individuals with a normally developed gland [2]. In this case report we present a patient with agenesis of the right lobe of the thyroid gland and a multinodular goitre of the existing left lobe. The aim of this case report is to increase awareness of this pathology and its' clinical implications, such as higher risk of associated thyroid pathology.

## 2. PRESENTATION OF CASE

We present the case of a 62 year old female patient, with history of appendectomy and hyperlipidaemia, medicated with a statin, with no previous history of neck surgery or thyroid function abnormalities. She was referred to General Surgery outpatient clinic for a left neck mass. An ultrasound of the neck revealed absence of the right thyroid lobe with a 13mm adenopathy on the right side of the neck and a multinodular goitre on the left lobe (figure 1). The left thyroid lobe presented with about 80mm of longitudinal axis, which is clearly above the normal dimensions, and multiple nodules, some coalescing, with a maximum with of 14 and 21mm and no suspicious characteristics. A computed tomography (CT) scan of the neck was performed (figure 2), to clarify the anatomy, that confirmed the inexistence of a right thyroid lobe and revealed a left lobe insinuating into the upper mediastinum.



**Figs. 1 and 2. Neck ultrasound and CT (a – axial, b – coronal) showing presence of only the left thyroid lobe (T)**

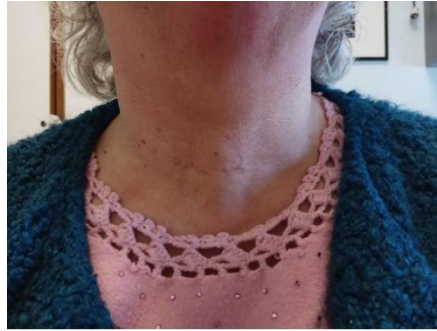A fine needle aspiration cytology was performed to the bigger nodule and the adenopathy that showed a colloid nodule and normal lymph node tissue, respectively. A total thyroidectomy was proposed to the patient, with its' risks and benefits being explained, and she accepted the procedure.

A total thyroidectomy was performed and intraoperatively an isolated left thyroid lobe with the macroscopic appearance of a multinodular goitre was found (figure 3) and the absence of right thyroid lobule and isthmus was confirmed. The right paratracheal space was intact. The surgical procedure went unremarkably with a normal identification of the other anatomical structures, without any unexpected findings or interurrences. The histological examination of the specimen was consistent with a multinodular goitre with colloid nodules.



**Fig. 3. Total thyroidectomy surgical specimen after conservation in formaldehyde**

The patient was prescribed levothyroxine and control and stability of thyroid function were rapidly reached, she was very satisfied with the final cosmetic result (figure 4) and remains asymptomatic after four years.



**Fig. 4. Six months postoperative surgical scar.**

### **3. DISCUSSION**

Being a rare finding, thyroid hemiagenesis pathogenesis and clinical significance remain uncertain with some studies affirming that there is increased susceptibility to develop additional thyroid pathologies. Generally asymptomatic, the diagnosis is commonly incidentally during screening or other pathology related imaging examinations [1, 4]. Ultrasound of the neck can confirm or exclude the suspicion as well as diagnose other thyroid pathology. A study with 65 patients with THA suggested that thyroid hyperplasia and goitre result from long-term elevation of serum TSH with chronic overstimulation [5].

Previous neck surgery should be excluded, specifically hemithyroidectomy, as neck scars are not always obvious and it can lead to a similar image in computed tomography and ultrasound. Imaging examinations that can confirm the diagnosis, besides the ultrasound, are the CT, MRI and scintigraphy [4, 6]. Excluding vascular congenital abnormalities is relevant for surgical planning as unilateral absence of superior and inferior thyroid artery and right sided aortic arch are described as being associated to thyroid hemiagenesis [2, 7].

As patients with hemiagenesis of a thyroid lobe can develop any thyroid pathology, apparently having a bigger risk than the normal population, they should be managed as every patient with thyroid disease [5]. Our patient had a neck mass with discomfort associated, already entering the upper mediastinum, so thyroidectomy was considered the correct treatment to be offered.

### **4. CONCLUSION**

Thyroid hemiagenesis is rare, generally being asymptomatic. The thyroid gland is constituted by its' normal tissue and can develop its' usual pathologies. Alterations in thyroid function can as well be present or not. Preoperative recognition of the condition is important for surgery planning but, , when surgery is needed, there seems to be no association with surgical technical challenges or outcomes different than normal.

## CONSENT

Authors declare that 'written informed consent was obtained from the patient for publication of this case report and accompanying images. A copy of the written consent is available for review by the Editorial office/Chief Editor/Editorial Board members of this journal.

## ETHICAL APPROVAL

Authors declare that 'written informed consent was obtained from the patient and strict protection of privacy standards were followed.

## REFERENCES

1. Szczepanek-Parulska E, Zybek-Kocik A, Wartofsky L, Ruchala M. Thyroid Hemiagenesis: Incidence, Clinical Significance, and Genetic Background. *J Clin Endocrinol Metab* 2017;102:3124-3137

DOI: 10.1210/jc.2017-00784

2. Ruchala M, Szczepanek E, Szaflarski W, Moczko J, Czarnywojtek A, Pietz L et al. Increased risk of thyroid pathology in patients with thyroid hemiagenesis: results of a large cohort case-control study. *Eur J Endocrinol*. 2010;162:153-160.

DOI: 10.1530/EJE-09-0590

3. Castanet M, Leenhardt L, Léger J, Simon-Carré A, Lyonnet S, Pelet A et al. Thyroid Hemiagenesis Is a Rare Variant of Thyroid Dysgenesis with a Familial Component but without Pax8 Mutations in a Cohort of 22 Cases. *Pediatric Research* 2005;57(6):908-913

DOI: 10.1203/01.PDR.0000161409.04177.36

4. Kaeser M, Haun D, Perillat M, Kttner N. Thyroid Hemiagenesis: A Sonographic Diagnosis. *J Medical Ultrasound*. 2012;20:228-231

DOI: 10.1016/j.jmu.2012.10.001

5. Szczepanek-Parulska E, Zybek-Kocik A, Wolinski K, Czarnocka B, Ruchala M. Does TSH trigger the anti-thyroid autoimmune processes? Observation on a large cohort of naive patients with thyroid hemiagenesis. *Arch Immunol Ther Exp (Warsz)*. 2016; 64:331–338

DOI:10.1007/s00005-016-0393-y

6. Lesi O, Thapar A, Appaiah N, Iqbal M, Kumar S, Maharaj D et al. Thyroid Hemiagenesis: Narrative Review and Clinical Implications. *Cureus*. 2022;14: e22401

DOI: 10.7759/cureus.22401

7. Khaladkar S, Garg S, Sherawat P, Kamal A. Thyroid hemiagenesis with isthmic agenesis: A case report with review of the literature. *Med J DY Patil Univ* 2015;8:559-562

DOI: 10.4103/0975-2870.160815

UNDER PEER REVIEW