

Case study

UNVEILING THE RARITY: A COMPREHENSIVE REPORT ON CEMENTOBLASTOMA

Abstract

Background: Cementoblastoma is a rare odontogenic neoplasm characterized by the proliferation of cellular cementum around the roots of teeth. Accurate diagnosis is crucial for effective management of this condition.

Objective: This article presents a case report of a 15-year-old male patient with cementoblastoma, initially misdiagnosed as an infectious process.

Methods: The clinical, radiographic, and histological features of cementoblastoma are described in detail, emphasizing the importance of comprehensive evaluation. The case highlights the typical presentation of cementoblastoma, including tender swelling and radiographic findings of a well-defined radiopaque mass attached to the tooth root. Histopathological examination confirmed the diagnosis, revealing the characteristic features of cementoblastoma. Surgical excision and extraction of the associated tooth were performed, leading to successful resolution of the lesion.

Results: The article emphasizes the significance of accurate diagnosis and appropriate treatment, as well as the need for interdisciplinary collaboration in managing cementoblastoma.

Conclusion: By enhancing our understanding of this rare odontogenic neoplasm, this case report contributes to the existing literature and promotes improved patient care.

Key words- Cementum; cementoblastoma; molar; radiopaque

Introduction

Cementoblastoma is a rare type of tumor that originates from the mesenchymal cells associated with the roots of teeth. It is considered an odontogenic neoplasm because it arises from the tissues involved in tooth development. Cementoblastomas are relatively uncommon, accounting for less than 5% of all odontogenic tumors. It predominantly occurs in the permanent dentition, typically in the second and third decades of life. Mandibular premolars or molars are commonly affected by this neoplasm. Clinically, cementoblastomas present as a well-defined rounded mass that is firmly attached to the root of the affected tooth. The lesion may cause localized pain, swelling, and expansion of the jaw. However, the symptoms can vary, and in some cases, the lesion may be asymptomatic and discovered incidentally during routine dental examinations. Histologically, the lesion is characterized by the exuberant proliferation of cellular cementum surrounding the roots of the implicated tooth/teeth [1-3]. In this report; we present a clinical case of cementoblastoma in a 15-year-old male, initially misdiagnosed as an infectious process due to its clinical resemblance.

Case report

A fifteen-year-old boy presented to the outpatient department with a chief complaint of a tender swelling in the left lower back tooth region that had been present for one month. The swelling had gradually increased in size over time. The patient was in good general health, and no facial asymmetry was observed during the extraoral examination. On intraoral examination, a firm to bony hard swelling measuring approximately 2 cm x 1.5 cm was noted in the left mandibular posterior tooth region. The swelling was associated with the permanent mandibular left first molar, causing expansion of the buccal cortical plate and slight obliteration of the buccal vestibule. The overlying mucosa appeared normal, and all associated teeth were immobile and symptom-free.

An orthopantomogram (OPG) revealed a well-defined radiopaque lesion measuring 2 cm x 1.5 cm, which was found to be associated with the roots of the left mandibular permanent first molar. The radiopaque area was surrounded by a radiolucent line (Fig 1). A provisional diagnosis of odontoma was considered, with cementoblastoma as a differential diagnosis. The patient was counselled, and it was decided to proceed with excision of the mass along with extraction of the associated tooth. The excision was

planned under general anaesthesia, and the tumor mass was surgically removed after raising a mucoperiosteal flap. Bony expansion was observed over the roots of tooth 36 in the posterior mandible. The mass was well delineated from the surrounding healthy bone and could easily be removed along with the extraction of tooth 36. Primary closure was performed, and the healing was uneventful.

Histopathological examination was performed on the specimen, which consisted of a greyish-white mass attached to the tooth, measuring approximately 2.0 cm in diameter (Fig 2A). The entire tissue was decalcified using the acid decalcification method, as a single specimen. Buccopalatal slices of the decalcified tumor mass disclosed a yellowish white solid globular tumor mass located in the apical portion and fused to the roots of the molar tooth (Fig 2B). The decalcified sections three micron thin haematoxylin and eosin sections revealed the tumor mass to be attached to the apical and lateral portion of both the tooth. It was composed of globules of dense cellular cementum with prominent basophilic resting and reversal lines, along with associated plump eosinophilic cementoblasts, cementoclasts, and vascular immature fibrous tissue. Centre of the tumors mass showed cemental agglomerate with cementocytes in lacunae. The lesion was fused to the root of the tooth, while the remaining structures of the tooth, such as dentinal tubules, vascular pulpal tissue, and cementum, appeared unremarkable (Fig 3).

The final diagnosis was given as a benign mesenchymal odontogenic tumor, favouring cementoblastoma. The patient is currently under follow-up and asymptomatic.

Discussion

Benign cementoblastoma is a rare neoplasm of the jaws. It is defined by the 5th edition of **World Health Organization (WHO 2023)** as a benign odontogenic neoplasm that forms a rounded mass of cementum on the root of a tooth [1, 4]. Cementoblastomas are classified as genuine neoplasms arising from cementum or cementum-like tissue formed by cementoblasts on the root of a tooth. Benign cementoblastomas are predominantly found in association with a single erupted permanent tooth and rarely occur in relation to the primary dentition [2, 5-6]. First recognized by Dewey in 1927, cementoblastoma exhibits a higher prevalence among young male adults under 30 years of age, constituting less than 1-6.2% of all odontogenic tumors. There is no significant sex predilection observed. The size of these lesions varies between 0.5 cm

and 5.5 cm. Pain and swelling are the most common findings in patients. Radiographically, a radiopaque mass is usually adhered to the apices of the tooth roots [2, 7-8].

The case being discussed entails a detailed clinical presentation of a 15-year-old male patient who sought medical attention due to the presence of a tender swelling in the posterior region of the left mandible. Specifically, the observed lesion was localized to the mandibular permanent first molar, which is in accordance with existing literature on similar cases.

Radiographic examination of the patient revealed a distinctive and well-defined radiopaque mass. Notably, surrounding the mass, there was a thin radiolucent rim that delineated its borders. Importantly, the mass appeared to be firmly attached to the radicular portion of the affected tooth, further emphasizing its relationship to the mandibular permanent first molar.

These clinical and radiographic findings align with the characteristics commonly associated with cementoblastoma, a benign neoplasm of the cementum. Cementoblastomas typically manifest as localized masses attached to the roots of affected teeth. The presence of tenderness and swelling reported by the patient also corresponds with the documented symptoms commonly associated with this condition [8-9].

By providing this comprehensive description of the clinical and radiographic features observed in the current case, we contribute to the existing body of knowledge on cementoblastoma, aiding in its recognition and accurate diagnosis.

The developmental progression of cementoblastoma can be divided into three stages: the periapical osteolysis stage, the cementoblastic stage, and the maturation and calcification stage [3].

Histologically, the observed lesion exhibits histomorphological similarities to an osteoblastoma. The majority of the lesion consists of a dense cellular cementum mass, which bears resemblance to bone tissue. Within this mass, prominent reversal lines can often be observed, indicative of the dynamic remodeling process. Importantly, the mass is fused with the resorbed surface of the tooth root, further highlighting its association with the affected area. Peripherally, the lesion displays finger-like trabeculae composed of newly formed matrix. These radiating trabeculae are often accompanied by plump cementoblasts and cementoclasts, as well as vascular

immature fibrous tissue [1-3,9]. The microscopic characteristics observed in this case are consistent and in line with previous literature reports on similar cases.

Given its similarity to other entities, particularly osteoblastoma, careful differentiation is essential to avoid misdiagnosis and ensure appropriate management. Complete surgical excision, along with extraction of the involved tooth, is the preferred treatment approach, leading to a low risk of recurrence when performed meticulously. In contrast, incomplete removal or attempted preservation of the tooth often results in a higher likelihood of recurrence [3].

Due to the unlimited growth potential observed in benign cementoblastomas, the optimal treatment approach involves complete surgical excision of the lesion, along with the extraction of any associated teeth, even in cases where the pulp may remain vital. When the mass is completely removed, the likelihood of recurrence is rare. However, in situations where the excision is incomplete, recurrence is commonly observed [1-2].

In cases where cementoblastoma affects multiple teeth, it demonstrates a higher growth potential. Nevertheless, no instances of recurrence have been reported thus far. Notably, the removal of the associated tooth and thorough curettage typically prevents recurrence. Conversely, incomplete removal or attempts to preserve the affected tooth are often followed by recurrence.

By emphasizing the importance of complete surgical excision and tooth extraction in treating benign cementoblastoma, the risk of recurrence can be minimized. These insights contribute to the existing academic knowledge, aiding in the development of effective treatment strategies [5, 9].

Conclusion

In conclusion, cementoblastoma, although rare, necessitates meticulous diagnostic precision to ensure optimal management strategies. Thorough clinical evaluation, complemented by meticulous radiographic and histological assessments, remains paramount in distinguishing cementoblastoma from other related pathologies. Surgical excision coupled with the extraction of associated teeth represents the preferred treatment modality, mitigating the risk of recurrence. Vigilant postoperative monitoring is advised to ensure long-term therapeutic success and expedite the identification of potential complications or recurrent manifestations. Effective interdisciplinary collaboration among clinicians, radiologists, and pathologists is

indispensable for accurate recognition and proficient management of this infrequent odontogenic neoplasm.

Acknowledgements

I would acknowledge all my co-authors and staff for their valuable contribution.

No source of funding.

Competing Interests – No competing interests to be declared

Authors' Contributions

Dr. Garima Rawat – Concept, manuscript designing compilation

Dr. Hema Malini Aiyer – proof reading

Dr. Ashish garg - Surgeon

UNDER PEER REVIEW

Figure legends

Fig 1 Radiograph showing well defined radio-opacity surrounded by radiolucent line involving the left mandibular first molar.

Fig 2A Gross examination showing hard tissue bit of bony hard mass surrounding the tooth.

Fig 2B Decalcified sliced sections showing tumor mass attached to the roots of permanent molar.

Fig 3 Photomicrograph showing tumor mass attached to the apical portion of tooth (HE 40X). Arrow heads (blue) delineating the junction between the tooth and the cemental mass.

Fig 4 Photomicrograph showing tumor mass composed of numerous basophilic reversal lines (black arrow head). (HE 400X).

UNDER PEER REVIEW

References

1. Odell et al. IARC/ WHO classification of tumors online. 5th edition
2. Aadithya B Urs, Hanspal Singh, Garima Rawat, Sujata Mohanty, Sujoy Ghosh. Cementoblastoma Solely Involving Maxillary Primary Teeth- A Rare Presentation. *Journal of Clinical Pediatric Dentistry*. 2016;40(2):147-151.
3. Revathi S., Ramesh V., Balamurali P.D., Oza N. Benign cementoblastoma: A case report. *Int J Med Res Health Sci*. 2016;5(3):73-76.
4. Subramani V, Narasimhan M, Ramalingam S, Anandan S, Ranganathan S. Revisiting Cementoblastoma with a Rare Case Presentation. *Case Reports in Pathology*. 2017;2017:1-3.
5. Slootweg PJ, Muller H. Cementoblastoma: a review of the literature and report of a case. *J Oral Pathol*. 1982;11(6):459-66.
6. Huber AR, Folk GS. Cementoblastoma. *Head Neck Pathol*. 2009;3(2):133-5. doi: 10.1007/s12105-008-0099-5. Epub 2008.
7. Kaur S, Kaur T, Dhawan A, et al. Benign Cementoblastoma: Revisiting Rare Tumor of Mandible. *AMEI's Curr Trends Diagn Treat* 2019;3(2):86–89.
8. Cavalcante RC, Petinati MFP, de Oliveira ER, Bergamaschi IP, Rebelatto NLB, Klüppel L, Scariot R, da Costa DJ. Benign Cementoblastoma Associated with an Impacted Third Molar inside Maxillary Sinus. *Case Rep Surg*. 2018;2018:7148479. doi: 10.1155/2018/7148479.
9. D'Orto B, Busa A, Scavella G, Moreschi C, Capparè P, Vinci R. Treatment options in cementoblastoma. *J Osseointegr* 2020;12(2):172-176.

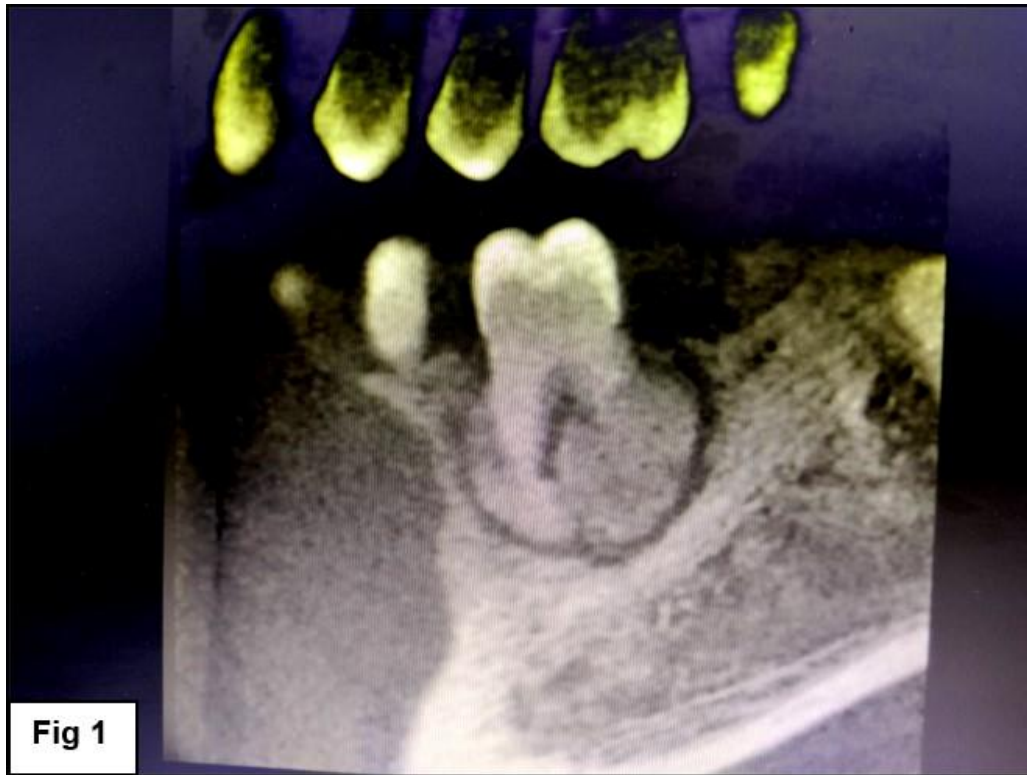


Figure 1 : Radiograph showing well defined radio-opacity surrounded by radiolucent line involving the left mandibular first molar.

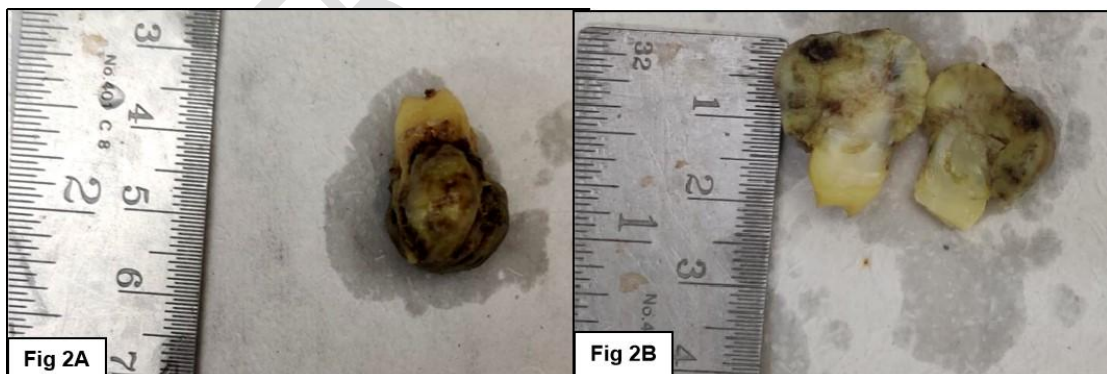

Figure 2:

Fig 2A Gross examination showing hard tissue bit of bony hard mass surrounding the tooth.

Fig 2B Decalcified sliced sections showing tumor mass attached to the roots of permanent molar.




Figure 3: Photomicrograph showing tumor mass attached to the apical portion of tooth (HE 40X). Arrow heads (blue) delineating the junction between the tooth and the cemental mass.

UNDER REVIEW

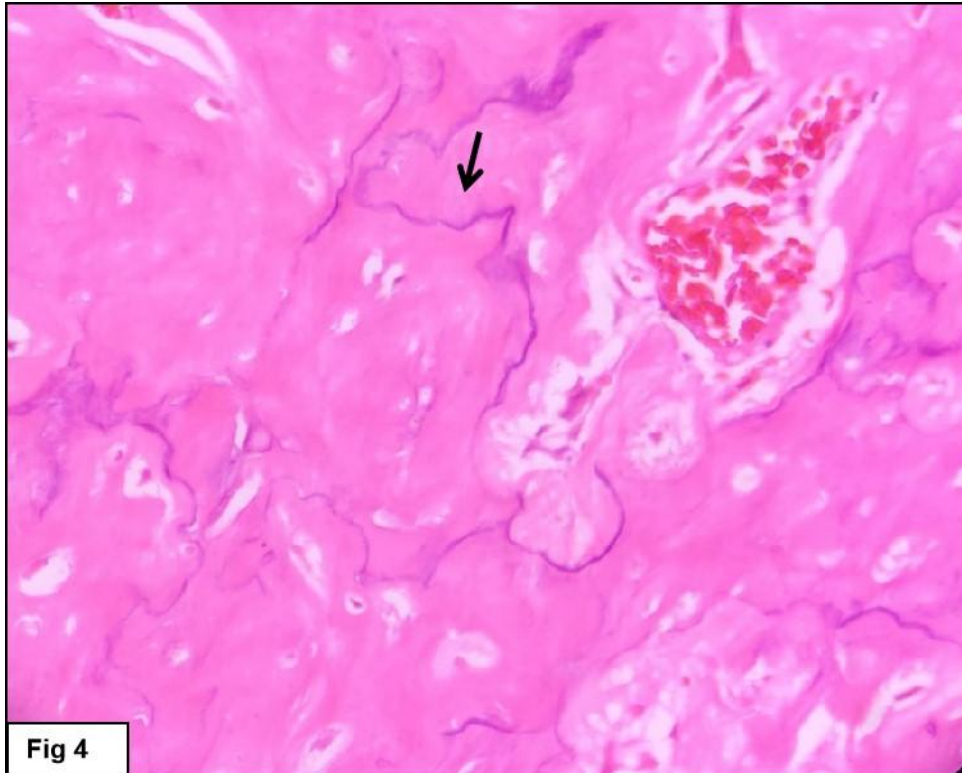


Fig 4

Figure 4: Photomicrograph showing tumor mass composed of numerous basophilic reversal lines (black arrow head). (HE 400X).

UNDER PEER REVIEW