

Case study

Post-traumatic Mesenteric Pseudocyst Due to Bicycle Handlebar Injury

Abstract

Mesenteric Pseudocyst is a cystic mass in the abdomen. ~~They are caused either due to trauma or infection.~~ True mesenteric cysts are lined by epithelium while ~~Pseudocyst pseudocysts~~ are not. Mesenteric ~~Pseudocyst pseudocysts~~ are very rare. Only 29 case reports were retrieved via the Medline/PubMed search engine. Incidental diagnosis of mesenteric Pseudocyst is during abdominal imaging or laparotomy. ~~The term mesenteric Pseudocyst was first used by Ros et al in 1987.~~

Comment [Er1]: This sentence is plagiarized from: https://en.wikipedia.org/wiki/Mesenteric_pseudocyst

We report an extremely rare case of ~~post traumatic post-traumatic~~ mesenteric Pseudocyst in a 10-year-old girl. There was ~~a~~ history of ~~fall falling~~ from the bicycle and causing ~~a~~ handlebar blunt abdominal injury to the abdomen. After 5-6 months, she was presented with acute intestinal obstruction, due to volvulus of small bowel. ~~Patient The patient~~ was managed by open explorative laparotomy, and we did total segmental resection of the ileum along with ~~post traumatic post-traumatic~~ mesenteric Pseudocyst and ~~also~~ ileo-ileal anastomosis.

~~Key words~~Keywords

Blunt abdominal trauma, bicycle handlebar injury, Traumatic mesenteric cyst

Introduction

Mesenteric ~~Pseudocyst pseudocysts~~ are rare abdominal tumours that can arise from mesenteric tissue. ~~The term mesenteric Pseudocyst was first used by Ros et al in 1987.~~ They are typically benign, ~~fluid filled fluid-filled cyst cysts~~ that can cause abdominal pain, vomiting, and very rarely acute intestinal obstruction. The diagnosis of Mesenteric Pseudocyst can be challenging and usually diagnosed during abdominal imaging or laparotomy. The Pseudocyst by definition ~~is~~ lacks of ~~the~~ true epithelial wall. [1,2,4,8]

Mesenteric Pseudocyst are rare intra-abdominal lesions. Trauma and infection have been ~~the~~ possible cause, by means of blunt abdominal trauma, followed by Mesenteric haematoma ~~gets getting~~ absorbed and cystic degeneration and formation of a cystic mass in the mesentery. Surgical removal has been achieved by means of open surgery, laparoscopy, and robotic surgery. Total surgical excision of a traumatic mesenteric Pseudocyst along with ~~a~~ segmental ileal loop and ileo-ileal anastomosis is the gold standard treatment. [1,2,3]

The aim of this ~~case study~~ was to report a rare case of post traumatic Mesenteric Pseudocyst following blunt abdominal trauma due to bicycle handlebar injury in a 10 years old girl.

Case Reports

A 10 ~~years' years~~ girl was admitted to our centre in ~~1997~~, with ~~complains complaints~~ of severe abdominal, pain distension of ~~the abdomen~~, and vomiting ~~of for~~ 2 days' duration. After detailed counselling with parents, they have narrated the history of ~~fall falling~~ from the bicycle 5-6 months back. While going to school, the handlebar of the bicycle ~~causing caused the~~ blunt abdominal injury. After 5-6 months she presented with acute intestinal obstruction. On ultrasonography, ~~the~~ abdomen showed a cystic mass in ~~the~~ ileal mesentery with dilated bowel loops. ~~Plain A plain~~ abdominal x-ray showed multiple air-fluid levels suggestive of acute intestinal obstruction. ~~Her all All~~ laboratory investigation was normal. Open explorative laparotomy ~~was~~ performed, after exploration, she had ~~ac~~

Comment [Er2]: This study was done in the year 1997, 26 years back. What was the reason that it is being reported after 26 years in 2023?

cystic Multilocular mass in the small bowel mesentery of size 15x12x10centimetres and weight 2.5 kilograms.

Multilocular-The multilocular haemorrhagic cystic mass was causing torsion of the small bowel and volvulus followed by acute intestinal obstruction. This big Multilocular haemorrhagic cyst developed due to bicycle handlebar trauma to the mesentery and formed a big haematoma in between two peritoneal leaves of small bowel mesentery, due to laceration of mesenteric small vessels forming a post-traumatic post-traumatic mesenteric Pseudocyst. A big-size mMultilocular Mesenteric Pseudocyst created a torsion of the small bowel followed by acute intestinal obstruction. Such type of case we have noticed for the first time in my surgical carrier. We performed total segmental excision of the ileal segment along with Mesenteric Pseudocyst and ileo-ileal anastomosis.

Postoperative recovery was uneventful and the patient was discharged on the 8th postoperative day. The Pathological report revealed a Mesenteric Cyst-wallcontaining chronic inflammation, a large amount of haemorrhagic fluid with fibrous tissue, andan absence of epithelium, which was suggestive of a Pseudocyst. (Figure 1,2,3,4)

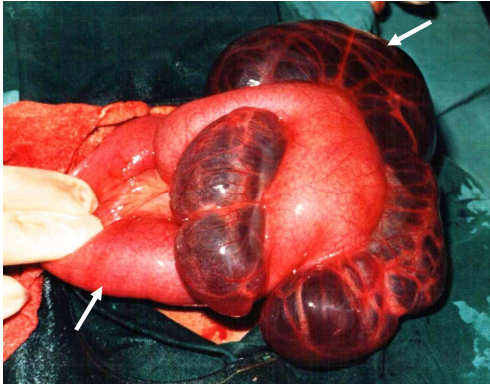


Fig-1 Intraoperative photographs Showing volvulus of small bowel due to post traumatic Pseudocyst

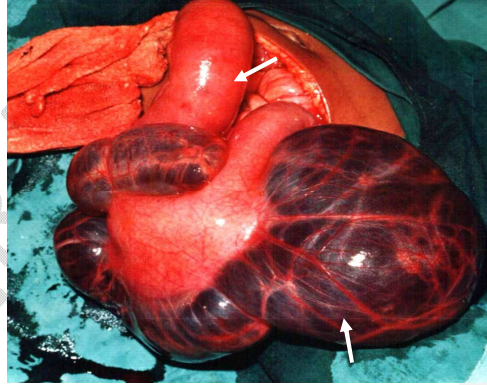


Fig-2 Intraoperative photographs Showing volvulus of small bowel and acute intestinal obstruction

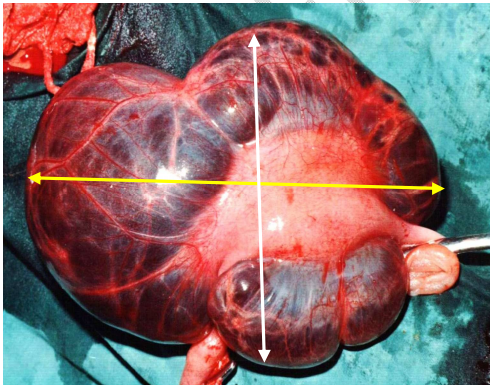


Fig-3 Intraoperative photographs Showing Giant Multiloculated Post Traumatic Pseudocyst of size 15x12 cm

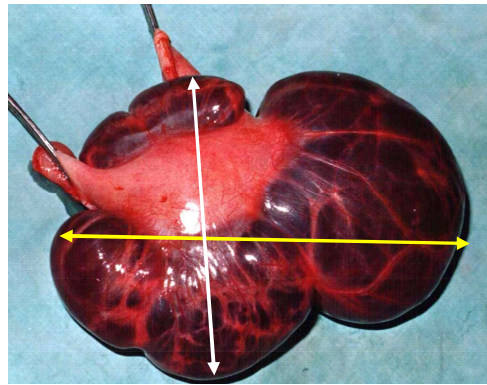


Fig-4 Intraoperative photographs Showing Total Excision of post traumatic Pseudocyst weight -2.5 kg

Discussion

A mesenteric cyst is a rare type of abdominal cyst. These cysts can be classified as true cysts or ~~Pseudocyst pseudocysts~~ based on their histological features. True cysts are ~~line-lined~~ by epithelium while ~~Pseudocyst Pseudocysts~~ are not. ~~The A~~ cyst size ~~of~~ more than 10 cm is called ~~a~~ giant Pseudocyst. Histopathological classification by De-Perrotand colleagues proposed ~~in teinto~~ six groups as follows. [1,2,3,8]

1. Cyst of lymphatic origin
2. Cyst of mesothelial origin
3. Cysts of enteric origin
4. Cysts of urogenital origin
5. Mature cystic Teratoma
6. Pseudocyst (Traumatic/Infective)

Mesenteric ~~Pseudocyst pseudocysts are~~ arise from trauma and inflammation. Mesenteric ~~Pseudocyst pseudocysts are a~~ relatively rare condition. ~~The diagnosis of Mesenteric Pseudocyst in is~~ challenging, as they are asymptomatic and reported incidentally and imaging ~~studystudies~~. Most of ~~the~~ Mesenteric Pseudocyst are asymptomatic and may be discovered incidentally during ~~diagnosis~~ ~~diagnostic~~ imaging or surgery. Abdominal symptoms caused by cysts such as abdominal pain 55-82%, palpable abdominal lumps 44-61%, and abdominal distension 17-61% may be observed. Very rarely trauma, infection, perforation volvulus or bowel obstruction may have developed and present as an acute abdomen. The symptoms are reported incidentally ~~on in~~ imaging ~~studystudies~~. The symptoms are abdominal pain, vomiting, and bowel obstruction. Complete surgical excision ~~in is~~ the gold standard treatment for Pseudocyst however laparoscopic excision or robotic excision is the preferred surgical approach. [1,2,4,8]

In our ~~casescase~~, for the first time reported that, there was ~~as a~~ history of bicycle handlebar injury due to ~~a~~ fall, after 5-6~~month-months~~ of blunt abdominal trauma in a 10 ~~years'-years~~ girl ~~who~~ developed the Mesenteric Pseudocyst. She developed a well-defined hematoma in the mesentery of ~~the~~ small bowel, due to ~~a~~ laceration of ~~the~~ mesenteric vessel forming a mesenteric hematoma, which ~~get gets~~ absorbed and degenerated forming a cystic haemorrhagic fluid mass. ~~Size The size of~~ ~~the~~ Pseudocyst was 15x12x10~~centimetres~~ and weight 2.5 ~~kilograms~~ in the mesentery and ~~the~~ cyst was containing bloody or haemorrhage fluid. Their large size and weight can result in ~~to~~ axial torsion and volvulus causing acute intestinal obstruction.

We performed total surgical excision of the Mesenteric Pseudocyst with segmental bowel resection and ileo-ileal anastomosis.

Conclusion

The definitive treatment of Post Traumatic Mesenteric Pseudocyst is open explorative laparotomy, total surgical excision of the Mesenteric Pseudocyst with segmental bowel resection and anastomosis. The prognosis is good, if the cyst is completely removed.

Reference

1. KlaudiaGjinoska, OgnenKostovski, Andrej Nikolovski, Daniela BajdevskaDukoska, AgronAlimi, SvetozarAntovic. Mesenteric Pseudocyst Following Blunt Abdominal Trauma: Report of a Case and Review of Literature. Journal of Surgery and Research. 5 (2022): 563-568.

Comment [Er3]: This sentence is plagiarized from: <https://www.cureus.com/articles/156829-intact-excision-of-a-mesenteric-pseudocyst#!>

2. Park SE, Jeon TJ, Park JY. Mesenteric pseudocyst of the transverse colon: unusual presentation of more common pathology. *BMJ Case Rep.* 2014 Oct 15;2014:bcr2013202682. doi: 10.1136/bcr-2013-202682. PMID: 25320250; PMCID: PMC4202056
3. Bhullar JS, Orfanou P. The disappearing abdominal mass: mesenteric pseudocyst. *JSL.* 2014 Apr-Jun;18(2):319-22. doi: 10.4293/108680813X13753907290991. PMID: 24960500; PMCID: PMC4035647
4. EvangelosFalidas, Stavros Mathioulakis, Konstantinos Vlachos, EmmanouilPavlakis, Georgios Anyfantakis, ConstantinosVillias, Traumatic mesenteric cyst after blunt abdominal trauma, *International Journal of Surgery Case Reports*, <https://doi.org/10.1016/j.ijscr.2011.03.006>
5. Beatrice D'Orazio, Bonventre Sebastiano, Martorana Guido, Cudia Bianca, Sciumé Carmelo, Gaetano Di Vita, Geraci Girolamo, Small Bowel Mesenteric Pseudocysts: Report of a Case and Review of the Literature *Surgical Case Reports*, <http://dx.doi.org/10.31487/j.SCR.2020.09.13>
6. Takumi Yamabuki; Masato Suzuoki; Tsuzuku Murakami; Laparoscopic Resection of a Jejunal Mesenteric Pseudocyst, *Case Rep Gastroenterol* (2018) 11 (3): 526–530. <https://doi.org/10.1159/000479313>
7. Klaudia Gjinoska, Ognjen Kostovski, Andrej Nikolovski, Daniela Bajdevska Dukoska, Agron Alimi, Svetozar Antovic. Mesenteric Pseudocyst Following Blunt Abdominal Trauma: Report of a Case And Review of Literature. *Journal of Surgery and Research.* 5 (2022): 563-568.
8. Jacqueline Oxenberg, "Giant Intraperitoneal Multiloculated Pseudocyst in a Male", *Case Reports in Surgery*, vol. 2016, Article ID 4974509, 5 pages, 2016. <https://doi.org/10.1155/2016/4974509>
9. Uysal M. An unusual cause of acute abdomen in children: Mesenteric pseudocyst in the ileum. *Ortadogu Tip Derg* 2020; 12(2): 275-278. <https://doi.org/10.21601/ortadogutipdergisi.752193>
10. Çizginer S, Tatlı S, Snyder EL, Goldberg JE, Silverman SG. CT And MR Imaging Features of a Non-Pancreatic Pseudocyst of the Mesentery. *Eur J Gen Med.* 2009;6(1):49-51. (doi: 10.29333/ejgm/82637)