

CASE REPORT

EOSINOPHILIC ASCITES AS A RARE MANIFESTATION OF EOSINOPHILIC GASTROENTERITIS

ABSTRACT:

Eosinophilic gastroenteritis is a rare gastrointestinal (GI) disorder characterized by nonspecific GI symptoms, peripheral eosinophilia, and eosinophilic infiltration of the intestinal wall. The disorder is classified into mucosal, muscular, and sub-serosal types, depending on the clinical picture and the depth of eosinophilic infiltration within the GI wall. Sub-serosal disease, which is complicated by ascites, usually results in the most severe clinical form of eosinophilic gastroenteritis and requires early corticosteroid therapy. In such cases, a favorable outcome can be achieved after a short course of corticosteroids. We report a similar case of a 47 years old male presenting with progressive abdominal distention with pedal oedema, who on investigations was found to be having eosinophilic and low SAAG ascites, patient was worked up further with upper and lower GI endoscopies and mucoal biopsies, Cross-sectional imaging, Bone marrow examination and finally diagnosed to be having eosinophilic ascites secondary to EGIDs. He was started on steroids in a tapering dose with Six Food Elimination Diet (SFED) and showed remarkable improvement. Patient is off steroids now and well maintained and is planned to continue now on SFED with slow re-introduction of foods.

Key words: Eosinophilic ascites, eosinophilic gastroenteritis, gastrointestinal disorder

INTRODUCTION

Eosinophilic Gastroenteritis (EGED) represents a member of a family of diseases collectively referred to as eosinophilic gastrointestinal (GI) disorders (EGIDs) that includes eosinophilic esophagitis, gastritis, enteritis, and colitis. EGED is a rare disease characterized by focal or diffuse eosinophilic infiltration of the GI tract, especially the stomach and duodenum. It has vague, nonspecific symptoms, including nausea, vomiting, abdominal pain, diarrhea, weight loss, ascites, and malabsorption.¹ There is no single diagnostic test or procedure that would point directly to the diagnosis, and there are no strict or uniform diagnostic criteria.² Despite its rarity, eosinophilic gastroenteritis needs to be recognized by the clinician because this treatable disease can masquerade as irritable bowel syndrome. Patient with serosal variant of EGED present with eosniophilic ascites. Mucosal biopsies can be negative in upto 10 % of the cases.^{3 4 5} Radiographic picture has no characteristic appearance.⁶ Treatment is by food elimination, commonly Six Food elimination diet (SFED), oral glucocorticosteroids is given for patient who present with the obstructive symptoms and eosinophilic ascites.

CASE PRESENTATION

A 47 year old man with a history of bronchial asthma presented with acute onset,

gradually progressive abdominal distension for 1 month not associated with pedal edema, shortness of breath/cough or periorbital puffiness. He had generalized body weakness and constipation (passage of stool once in 3 days). Patient was a non addict, and had no similar complaints in past. On clinical examination, general examination was normal. On systemic examination he had hepatomegaly 6 cm below Right coastal margin, positive shifting dullness test. Respiratory system examination revealed monophonic rhonchi, rest CVS and CNS examination was normal. On investigation, haemogram showed Hb – 14.1 gm %, leukocytosis of 16900 cells/mm³, differentials being N 22%/L25%/E 49%, with an Absolute eosinophilic count of 8281 / mm³, Platelets were 2.68 L /mm³(Figure 1). He was found to have low serum ascites albumin gradient (serum albumin 4.1 mg/dl, ascitic fluid albumin 3.21 mg/dl) with eosinophilic predominance (total cell 5673/mm³, neutrophils 02%, lymphocytes 03%, eosinophils 90%) with adenosine deaminase of 18 IU. Serum IgE was >2500 IU/ml (Biological reference <100 IU/ml). Renal and Liver function tests were within normal limit. Stool test for ova and parasites was negative, and serology for hepatitis-B and hepatitis-C were non-reactive. Ultrasonography of the abdomen and pelvis showed mild ascites. 2D echocardiography revealed no abnormality. Upper GI Endoscopy revealed edematous mucosa of gastric antrum and body and Colonoscopy showed a normal study. Biopsies from gastric, duodenal ileal, and colonic specimen were suggestive of non specific gastritis, duodenitis, ileitis and colitis respectively. No specific mention about eosinophilic infiltration or predominance was made. Contrast-enhanced computed tomography (CECT) of the abdomen showed a diffuse circumferential wall thickening with post contrast enhancement in the multiple small bowel loops in the peritoneal cavity and associated intense peritoneal fat stranding (Figure 2 & 3). Bone marrow examination (from Sternum) showed myeloid hyperplasia with remarkably increased eosinophilic precursors and mature eosinophils (44%)(Figure 4). The patient was started on oral steroids, tablet Prednisolone 1 mg/kg to be tapered over 8 weeks, considering the diagnosis of eosinophilic ascites secondary to EGED, and was explained about SFED. The patient was followed up after 4 weeks, he has significant relief of symptoms, abdominal complaints and ascites resolved totally. Haemogram showed Hb of 14.8 g%, TLC 9100 /mm³, DLC N51%/L31%/E15%, Platelets of 3.5 L/mm³. Ultrasound of abdomen revealed no ascites. The patient is now doing well and is to be tapered off from steroids and to be maintained on Six food elimination diet and will be followed up.

DISCUSSION

Eosinophilic gastrointestinal disorder, which includes eosinophilic esophagitis, eosinophilic gastroenteritis, and eosinophilic colitis, is a rare group of heterogeneous diseases characterised by eosinophilic infiltration of gastrointestinal tract mucosa with subsequent inflammation and no apparent eosinophilic cause (e.g., drug reactions, parasitic infections, and malignancy).⁷ In 3/4 of the cases, it is significantly linked to atopic disease and an allergy-related family history.⁸ Male adults in their third to fifth decades are more likely to have EGID.⁹ Eosinophils spend a brief time in peripheral circulation after maturing in the bone marrow and going through selective expansion. From there, they are trafficked to specific tissues like the gastrointestinal tract where they interact with endothelium to produce different types of inflammation with the aid of IL5, chemokines (eotaxin), platelet-activating factor, and cysteinyl leukotriene C4.⁹

EGID can be of three subtypes: mucosal variety (most common 70%), presenting with

diarrhea, melena, and iron deficiency anemia, protein-losing enteropathy; muscularis variety (20%) manifests as intestinal obstruction; and the least common, serosal variety (10%), shows peripheral eosinophilia and ascites.⁹ The diagnostic challenge about ~~subserosal~~ serosal EGID is a rarity, nonspecific clinical presentation, non-diagnostic endoscopy since the ~~biopsysample~~ is mostly taken from the mucosa.

The presence of gastrointestinal symptoms, the absence of parasitic or extraintestinal manifestations, a biopsy of the gastrointestinal tract showing eosinophilic infiltration, or radiological findings indicative of the disease like presence of ascites, ~~such as~~ peripheral eosinophilia ~~or eosinophilic ascites~~, are all required for diagnosis. The differential diagnosis of Eosinophilic ascites (EA) often leads to confusion and in inability to exclude its multitude of causes in many patients. Eosinophilic Ascite should be kept in mind as a cause of unexplained ascites associated with gastrointestinal symptoms. The differential diagnosis include parasitic infestations (Strongyloides Stercoralis, Toxocara Canis), spontaneous bacterial peritonitis, abdominal tuberculosis, rupture of hydatid cyst, peritoneal dialysis, chronic pancreatitis, vasculitis (Churg-Strauss syndrome), hypereosinophilic syndrome, malignancy (ovarian cancer, Hodgkin lymphoma, peritoneal carcinomatosis) and Crohn's disease

Treatment consists of elimination or elemental diet, oral steroids prednisolone 1mg/kg/day.¹⁰ Alternative second-line medications include mast cell stabilisers (sodium cromoglycate, ketotifen), leukotriene receptor antagonist (montelukast), an anti-IgE monoclonal antibody (omalizumab), anti-IL 5 monoclonal antibody (mepolizumab). In 80% of instances, full symptom ~~relieftakes~~ place within a week, and within two weeks, the eosinophil count returns to normal. There is less possibility of recurrence, but if it does, short-term steroids work well. Immunosuppressants such as azathioprine, cyclosporine and other steroid sparing therapies can be used in steroid-resistant patients.¹¹ In summary, EGE is a rare entity and it should be kept in mind in patients of unexplained ascites. Absence of malignancy, presence of ascitic fluid eosinophilia and a dramatic response to treatment with steroids confirm indirectly the diagnosis of EGED and Eosinophilic Ascites, as was observed in this patient.

CONCLUSION

Owing to the relatively nonspecific symptoms, this diagnosis should be considered in patients with ascites of unclear etiology, nonspecific bowel thickening by imaging studies and otherwise, negative workup for parasitic infection and malignancy. Absence of distinctive upper or lower gastrointestinal endoscopic biopsy findings does not rule out the presence of the disease in cases of eosinophilic ascites when there is abdominal discomfort, ascites, and peripheral ~~hypereosinophilia~~. Excellent outcomes are achieved ~~withearly~~ diagnosis, prompt diagnosis, and oral steroid treatment.

IMAGES

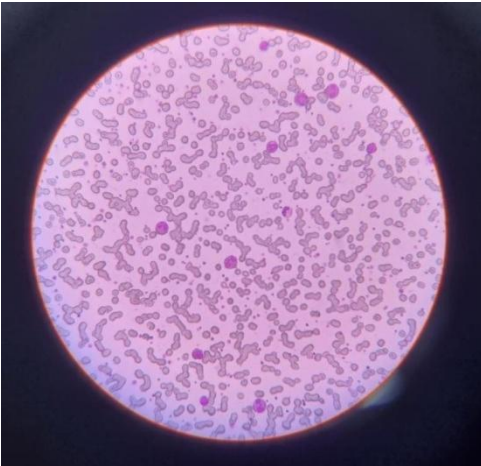


Figure 1 Peripheral blood smear showing peripheral eosinophilia.

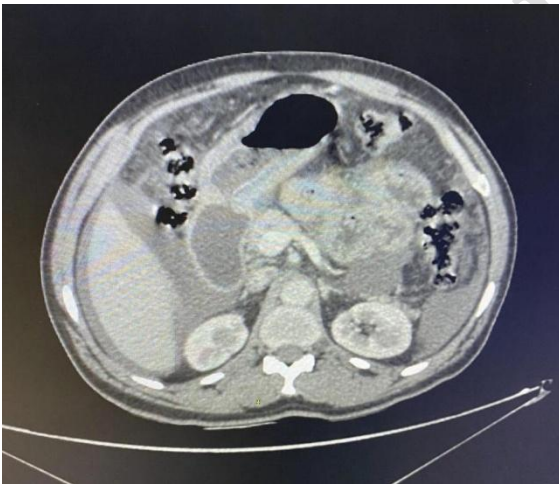


Figure 2 CECT W/A showing presence of ascites and small bowel loop thickening.

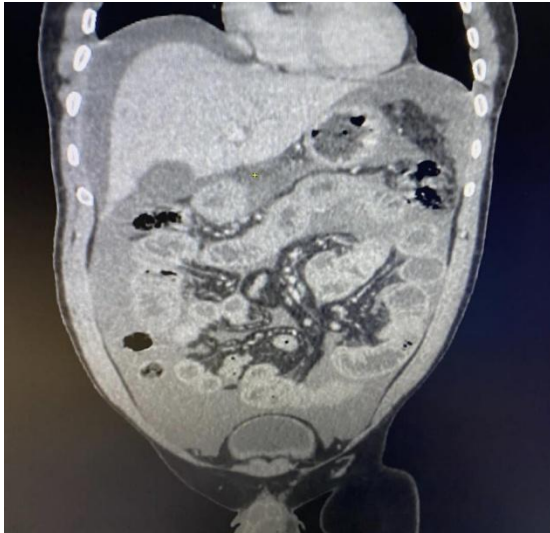


Figure 3 CECT W/A saggital section showing ascites and small bowel lop thickening.

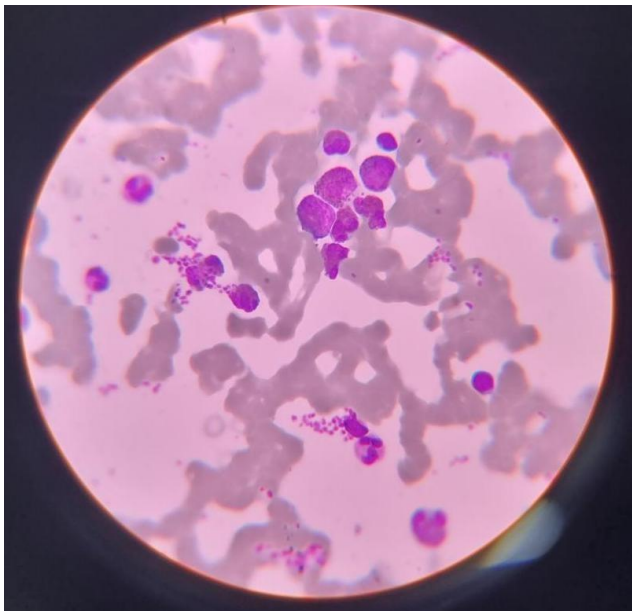


Figure 4 Bone Marrow examination showing myeloid hyperplasia with eosinophilic predominance.

CONSENT

All authors declare that written informed consent was obtained from the patient for publication of this case report and accompanying images. A copy of the written consent is available for review by the Editorial office/Chief Editor/Editorial Board members of this journal.

ETHICAL APPROVAL

No ethical approval was required for this manuscript.

REFERENCES

-
1. Baek MS, Mok YM, Han WC, Kim YS. A patient with eosinophilic gastroenteritis presenting with acute pancreatitis and ascites. *Gut Liver* 2014;8:224-7
 2. Cuko L, Bilaj F, Bega B, Barbullushi A, Resuli B. Eosinophilic ascites, as a rare presentation of eosinophilic gastroenteritis. *Hippokratia* 2014;18:275-7.
 3. Talley N, Shorter R, Phillips S, Zinsmeister A. "Eosinophilic gastroenteritis: a clinicopathological study of patients with disease of the mucosa, muscle layer, and subserosal tissues". *Gut* 1990;31:54-58.
 4. Klein N, Hargrove R, Slesinger M, Jeffries G. "Eosinophilic gastroenteritis". *Medicine Baltimore* 1970;49:299-319.
 5. Katz A, Goldman H, Grand R. "Gastric mucosal biopsy in eosinophilic (allergic) gastroenteritis". *Gastroenterology* 1977;73(4Pt1):705-709.
 6. Wiesner W, Kocher T, Heim M, Bongartz G. CT findings in eosinophilic enterocolitis with predominantly serosal and muscular bowel wall infiltration. *JBR-BTR* 2002;85:4-6.
 7. Rothenberg ME: [Eosinophilic gastrointestinal disorders \(EGID\)](#). *J Allergy Clin Immunol.* 2004,113:11-28. [10.1016/j.jaci.2003.10](#)
 8. AR: [Eosinophilic gastroenteritis: a clinicopathological study of patients with disease of the mucosa, muscle layer, and subserosal tissues](#). *Gut.* 1990, 31:54-58. [10.1136/gut.31.1.54](#)
 9. Jarry J, Peycru T, Shekher M: [A rare cause of ascites](#). *Gastroenterology.* 2011, 140:1149. [10.1053/j.gastro.2010.05.095](#)
 10. Kelly KJ: [Eosinophilic gastroenteritis](#). *J PediatrGastroenterol Nutr.* 2000, 30:28-35. [10.1097/00005176-200001001-00005](#)
 11. Antonini F, Saltarelli P, Frieri G, Latella G: [Education and Imaging: gastrointestinal: eosinophilic ascites](#). *J Gastroenterol Hepatol.* 2012, 27:1759. [10.1111/j.1440-1746.2012.07254.x](#)