

Case report

Chylolymphatic Mesenteric Cysts Presenting with Acute Intestinal Obstruction: 3 Case Reports

Abstract

A Chylolymphatic cyst, as the name suggests, is a cyst that contains both chyle and lymph, usually presents within the mesentery lined with a thin endothelium or mesothelium. The incidence is between 1:100,000 to 1:250,000ⁱⁿ hospital admissions. Chylolymphatic cysts are rare intra-abdominal tumours, may occur in the mesentery of the gastrointestinal tract from the duodenum to the rectum. 25% of the mesenteric cyst occur in children up to 10 year of age and constitute 7.3% to 9.5% of all abdominal cysts.

Herein, we report 3 cases of Chylolymphatic mesenteric cysts in paediatric age group of 6-10 years and all are symptomatic. All three cases presented with acute intestinal obstruction due to volvulus or twist of multilocular cysts and treated by explorative laparotomy, segmental bowel resection along with the excision of the mesenteric cystic mass and end to end anastomosis of the small bowel.

Keywords

Acute intestinal obstruction, Chylolymphatic cysts, Mesenteric cyst.

Introduction

Chylolymphatic mesenteric cysts are rare entities, lined by flat endothelium, containing, chylous and serous milky white fluid. They are single or multiple, unilocular or multilocular cyst and usually located in the root of mesentery of the terminal ileum.

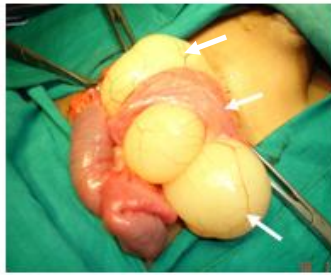
They are found 60% in the mesentery of small bowel, 24% are located in the mesentery of the large bowel and 14.5% were retroperitoneal. The most accepted theory by Gross, that it is the result of benign proliferation of ectopic lymphatics in the mesentery that lack communication with the lymphatic system. Clinically Chylolymphatic cysts may present as an asymptomatic abdominal mass, incidental findings during laparotomy or rarely present with volvulus and acute intestinal obstruction. Surgical excision of the cyst remains the mainstay for the treatment with an excellent result in 20% to 60% of the cases. Bowel resection and end to end anastomosis is needed. [1,2,3,4]

Case presentation

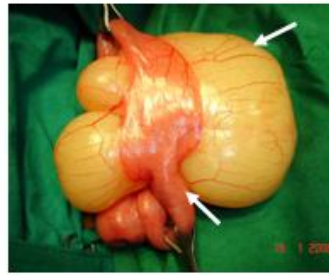Case Report 1

A 6 years old boy was admitted in our centre on 16/01/2008, with complains of severe pain in abdomen, distension of abdomen and vomiting since 2 days. On clinical examination of a child, he was having abdominal distension, palpable abdominal mass and little tenderness all over the abdomen. His plain x-ray abdomen showed multiple air-fluid levels and on ultrasonography of abdomen showed multiloculated cystic lesion in the mesentery of small bowel and dilated small bowel loops which was suggestive of acute intestinal obstruction.

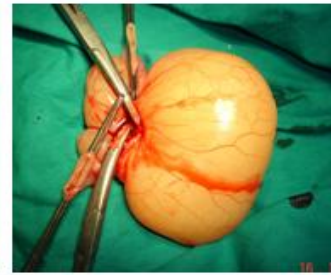We performed explorative laparotomy through mid-line incision. After exploration, we found a large multilocular cystic mass, yellowish white in colour in the terminal ileal mesentery, causing acute intestinal obstruction. Resection of the involved ileal segment(15cm) along with multiple cysts was done with ileo-ileal anastomosis in two layers. Gross examination revealed a large multicystic mass in the mesentery. Post-operative recovery was uneventful and boy was discharged on 8th postoperative day and no recurrence was noted during follow up for 10 years. Histopathology study revealed multilocular cysts lined with endothelium and cysts were filled with chylous and lymph fluid, which confirms the Chylolymphatic cyst. [Figure 1,2,3]



Case 1, Fig-1- Intra operative photographs Showing Chylolymphatic cyst of mesentery



Case 1, Fig-2, Multi-loculated Chylolymphatic cyst of size 5x10 cm

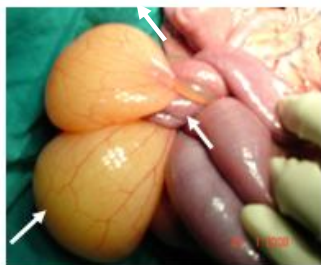

Case 1, Fig-3, Excised specimen of Chylolymphatic cyst

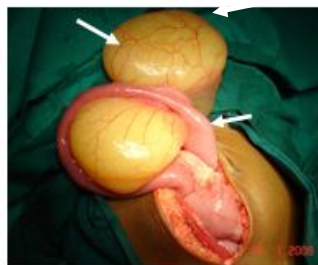Case Report 2

A 6 years old girl was admitted in our centre on 23/01/2008, with complains of pain in abdomen, distension of abdomen and vomiting for last 2 days. On clinical examination of girl was having abdominal distension, palpable abdominal lump and tenderness all over the abdomen. All laboratory investigation was normal. Her plain x-ray abdomen showed multiple air-fluid levels and abdominal ultrasonography showed multiloculated cystic lesion in the small bowel segment and dilated small bowel loop and all findings were suggestive of acute intestinal obstruction.

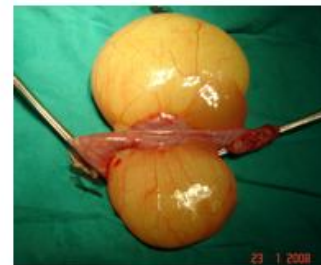Midline explorative laparotomy was performed, after opening the abdomen to our surprise, we saw a big segment of small bowel having multiple cystic mass in the mesentery, resulted in to volvulus of small bowel causing acute intestinal obstruction. There was 200 cc haemorrhagic fluid in the abdomen. Untwisting of volvulus was done and there was no gangrene of small bowel. A ileal segment of 12-15 cm length was having multiple cysts of yellowish white colour, filled with chylous & lymph. Cysts were 5-10 cm in size located in the mesentery. Resection of the involved segment of ileum along with multiple cysts was done with ileo-ileal anastomosis. Post-operative recovery was uneventful and girl discharged home on 8th post-operative day. Histopathology revealed a multiple Chylolymphatic mesenteric cysts. [Figure 1,2,3]



Case 2, Fig-1- Intra operative photographs Showing Volvulus of small bowel Due to Chylolymphatic cyst



Case 2, Fig-1- Intra operative photographs Showing untwisting of volvulus



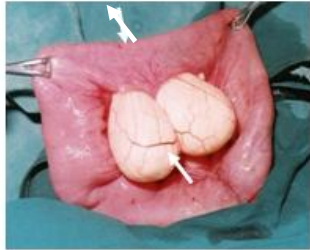
Case 2, Fig-3, Excised specimen of Chylolymphatic cyst

Case Report 3

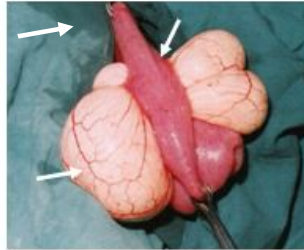
A 8 years old girl was admitted in our centre in the year 1995, with complains of severe abdominal pain, distension of abdomen, vomiting and constipation since last 2 days. On clinical

examination she was having abdominal distension and palpable abdominal lump. Here abdominal x-ray showed multiple air-fluid levels suggestive of acute intestinal obstruction.

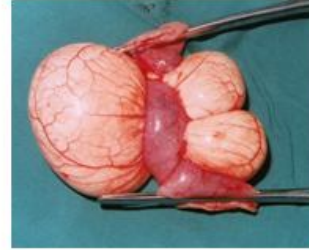
We performed explorative laparotomy, showed a multiloculated segment of ileum causing small bowel obstruction. A ileal segment of 15 cm was involved with multiple white egg coloured cysts in the mesentery and 200 cc of haemorrhagic fluid aspirated through the abdominal cavity. So resection of the involved segment along with multiple cyst and end to end anastomosis done with hand sewn in two layers. Post-operative recovery was good and girl discharged on 8th postoperative day. Histopathological report showed the Chylolymphatic mesenteric cyst, cysts containing chylous & lymph and lined by endothelium. [Figure 1,2,3]



Case 3, Fig-1- Intra operative photographs Showing Milky white color of Chylolymphatic cyst



Case 3, Fig-2- Intra operative photographs Chylolymphatic cyst of size 5x10 cm



Case 2, Fig-3, Excised specimen of Chylolymphatic cyst

Discussion

Chylous cysts are variants of mesenteric cysts and constitute 7.3% to 9.5% of all abdominal cysts. There are very few cases of paediatric Chylolymphatic cyst reported in the literature. Mesenteric cysts are classified in to four groups based on etiology.

1. Embryonic or developmental. 2. Traumatic or acquired. 3. Neoplastic 4. Infective or degenerative

Histopathological classification by de parrot et al in 2000 proposed following classification.

1. Lymphatic origin - Simple cyst and lymphatic cyst Chylolymphatic
2. Mesothelial origin - Simple, benign and malignant cystic mesothelium
3. Enteric origin- Enteric duplication cysts
4. Urogenital origin
5. Mature cystic teratoma or dermoid cysts
6. Pseudocysts- Infection or traumatic cysts. [1,2,3,4]

In 1942 van Rokitansky first reported the case of chylous mesenteric cyst and in 1880, Tillaux achieved the first successful surgical excision of a cystic mass in the mesentery. Mesenteric cyst are most commonly solitary and multilocuated, containing chylous, serous or haemorrhagic fluid. [2,5,6]

Clinically mesenteric cysts may present as an asymptomatic abdominal mass or incidental findings during laparotomy or it may present acute intestinal obstruction and volvulus. Ultrasonography and CT abdomen are the investigation of choice. Mesenteric cysts may vary in size from 4 cm to 30 cm. Chylolymphatic cyst of size more than 10 cm are considered as giant Chylolymphatic cyst. [1,2]

Complete surgical excision of the affected ileal segment along with mesenteric cystic mass and ileo-ileal anastomosis with an excellent result. 20-60 % of the cases bowel resection and anastomosis in needed along with excision of the mesenteric cyst. The recurrence following complete excision of the mesenteric cyst in very rare. [2,3]

The different surgical approaches used are marsupialization, sclerotherapy, drainage, enucleation, percutaneous aspiration and excision of the cyst with or without resection of the involved gut. All our patients underwent exploratory laparotomy and complete excision of the involved gut. [3,4,6]

Conclusion

Chylolymphatic cysts are very rare and treatment of which involves excision of cyst with or without resection of small bowel which is the gold standard offering complete cure to the patients.

Ethical Approval:

As per international standard or university standard written ethical approval has been collected and preserved by the author(s).

Consent

As per international standard or university standard, patient(s) written consent has been collected and preserved by the author(s).

References

1. Pithawa AK, Bansal AS, Kochar SP, Mesenteric cyst: A rare intra-abdominal tumour, *Med J Armed Forces India*. 2014 Jan;70(1):79-82. doi: 10.1016/j.mjafi.2012.06.010. Epub 2012 Oct 23. PMID: 24936122; PMCID: PMC4054796.
2. Kazi Md Noor-ul Ferdous, S M Mahmud, Sadia Sultan, Ferdousi Akter, Nusrat Jahan Mona, Mesenteric Cysts in Children: Review of 55 Cases, *Annals of International Medical and Dental Research* March- April 2023 DOI: 10.53339/aimdr.2023.9.2.16
3. Priya K. Pai, Hallbera Gudmundsdottir, Nathan C. Hull, Paul G. Thacker, Denise B. Klinkner, Chylolymphatic mesenteric cyst with midgut volvulus in an adolescent: a peculiar presentation, *Radiology Case Reports*, ISSN 1930-0433, <https://doi.org/10.1016/j.radcr.2021.10.066>.
4. Ahmed M. Gafar, Mohamed Y. Batikhe. Surgical management for mesenteric cysts in pediatric patients: a single centre experience. *Int Surg J*, DOI: <http://dx.doi.org/10.18203/2349-2902.isj20181027>
5. Ghritlaharey RK, More S. Chylolymphatic Cyst of Mesentery of Terminal Ileum, *J Clin Diagn Res*. 2014 Nov;8(11):ND05-7. doi: 10.7860/JCDR/2014/9748.5121. Epub 2014 Nov 20. PMID: 25584262; PMCID: PMC4290281.
6. Rattan KN, Nair VJ, Pathak M, Kumar S. Pediatric chylolymphatic mesenteric cyst - a separate entity from cystic lymphangioma: a case series. *J Med Case Rep*. 2009 Nov 9;3:111. Doi: 10.1186/1752-1947-3-111. PMID: 19946589; PMCID: PMC2783052.
7. Paramythiotis, D., Bangeas, P., Karakatsanis, A. et al. Ideal treatment strategy for chylous mesenteric cyst: a case report. *J Med Case Reports* 12, 317 (2018). <https://doi.org/10.1186/s13256-018-1716>
8. Sehrawat, Roopali MD, Bansal, Nalini, Kour, Harshita, Sinha, Anand MS, MCh†. A Giant Pediatric Chylolymphatic Cyst: An Extremely Rare Entity. *JPGN Reports* 4(1):p e274, February 2023. | DOI: 10.1097/PG9.0000000000000274

9. Shyamendra Pratap Sharma, Sarita Chowdhary, Pranay Panigrahi, Management of Mesenteric Cysts in Pediatric Population: Five-year Experience in Tertiary Care Center, DOI <https://doi.org/10.1055/s-0040-1718611> ISSN 0379-038X

UNDER PEER REVIEW