

Cephalometric Assessment of The Brain Ventricular System Index Using Computerised Tomography in Sokoto North-Western Nigeria

ABSTRACT

Aim: To determine the normal brain ventricular system index of Nigerians using computerized tomography in Sokoto North-Western Nigeria.

Study design: Retrospective cross-sectional

Place and Duration of Study: Department of Anatomy Usmanu Danfodiyo University Sokoto and Department of Radiology Usmanu Danfodiyo University Teaching Hospital Sokoto, between January, 2020 and January, 2022.

Methodology: One hundred and seventy-eight normal brain CT scans of subjects from the Radiology Department, whose ages ranged from 1 to 70 years, were recruited for this study.

The Bi-frontal and Bi-occipital indices were calculated as ratios of measured distances of the frontal and occipital horns of the lateral ventricles and the transverse intracranial diameter, at the same level, respectively. The brain ventricular system index was then determined by a ratio of the Bi-frontal index and Bi-occipital index.

Results: The largest brain ventricular system indexes were 7.83cm and 7.68cm in males and females respectively and these were observed between the age of 2-4years for both sexes. While, the smallest brain ventricular system indexes were 7.47cm in males and 7.29cm in females, which were observed in age group 61-70years for both sexes.

Conclusion: This study was conducted to determine the Ventricular Brain System Index and its relation with sex and age in our environment.

Key words: brain, ventricular, system index, ct scan, Nigerians.

1. INTRODUCTION

"The advent of brain computerized tomography (CT) has afforded a generally safe and non-invasive means of examining the interior of the head, including evaluation of ventricular size".^{1,2} "Measurement of ventricular dimensions were initially made on Polaroid pictures. But currently direct measurements are now possible on the soft copies of the CT scans".² "The digital CT scan machines currently in use also allow real time measurement of various dimensions of the ventricular system thus enhancing the understanding of its anatomy".²

"Various work reported that modern computerized tomography allows easy and safe noninvasive study of the ventricular system, without complications".^{3,4,5}

Measurement of dimensions of the ventricular system of the brain (Cephalometry) has revealed variations in the size of the brain ventricular system index with certain parameters such as age and sex.⁶ This therefore placed high premium on the accuracy in the technique and equipment used in obtaining a good CT of the brain, from which this measurement could be made.⁶

“Women were found to have smaller brains and lateral ventricles than men 89.3mm and 90.7mm respectively, even when the difference in height is taken into account”.⁷ “This difference was in proportion to the smaller size of the female cerebral hemispheres”.⁷ “There are variations in the human brain, conditioned by differences in age, sex, and body mass index (BMI) and these differences all have significant effects on ventricular sizes and brain ventricular system index”.⁸ The ventricles are enlarged in epilepsy and depression respectively.^{9,10}

“Morphometric analysis of cerebral ventricular system indexes are essential for evaluating changes due to ageing, growth, and the various intrinsic and extrinsic pathologies”.⁴ “The study of shape and size of ventricular system has become the main focus of interest in studies of some neuropsychiatric diseases like schizophrenia and Alzheimer’s disease and chronic alcoholism”.^{11, 12, 13}

“Linear measurements on axial CT scans provide clinicians and surgeons’ opportunity to ascertain differential diagnoses of neuropsychiatric disorders, outcomes of clinical and surgical interventions, geriatric changes and deleterious effects of drugs”.¹³

2. MATERIALS AND METHODS

This is a retrospective study of 178 normal brain CT scans of subjects from the Radiology Department of the Usmanu Danfodiyo University Teaching Hospital, whose ages ranged from 1 to 70 year. The CT scan images were retrieved from the hospital database backed up storage discs in the CT library. This study was conducted between Jan 2020 and Jan 2022, following an ethical approval granted by the institutional ethical committee. Images were taken with a NEUSOFT C 3000 Spiral CT machine Dual Slide Helical CT Scanner, (2005) model at 5mm slice thickness.

Poor quality of the scan images, and those with evidence of space occupying lesions, cerebral hemorrhage, previous brain trauma, and asymmetric of lateral ventricles were excluded from the study. The images were viewed on the computer aided Digital Imaging and Communication in Medicine (DICOM) viewer using the RadiAnt Version 4.2 software. Measurements were taken to the nearest 0.1 millimeters.

The Bi-Frontal Index (BFI) was determined by the ratio of the measured distance between the lateral borders of the frontal horns and the transverse intracranial diameter (see fig 1) at the same level. Similarly, the Bi-Occipital Index (BOI) was determined by the ratio of the measured distance between the most lateral borders of the occipital horns and the transverse intracranial diameter at the same level (see fig 1). Consequently, the Brain Ventricular System Index (BVSI) was determined by the ratio of the BFI and BOI.

Statistical analysis was done using Sigmastat 2.0 for windows San Rafael CA. Statsoft (1995). Data were presented in tables and charts, and expressed as means and standard deviation. Differences in ventricular parameters with respect to sex were examined using Student's t test. One-way analysis of variance was used to analyze for variations across age groups. $P < 0.05$ was considered as statistically significant.

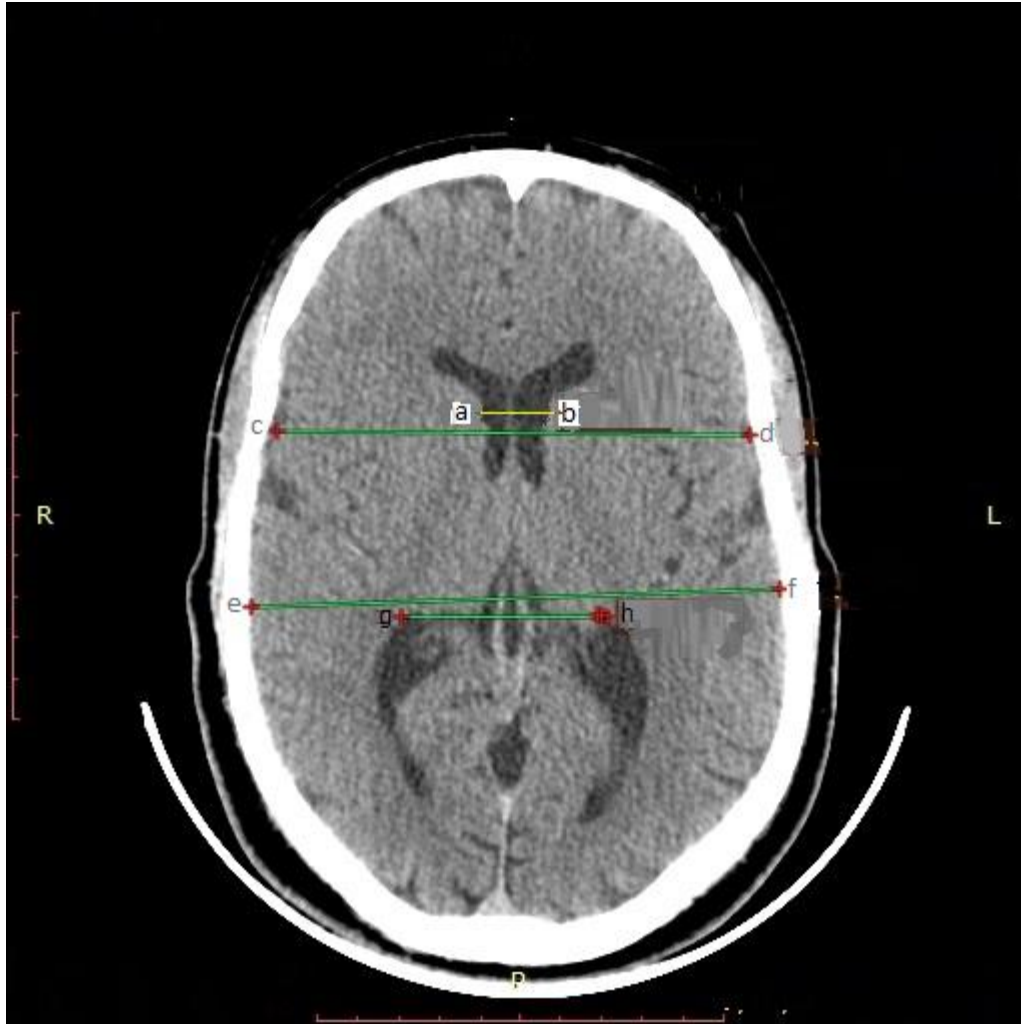

Figure 1: A CT showing measurement Bi-Frontal Index (BFI); determined by the ratio of the measured distance between the lateral borders of the frontal horns (a-b) and the transverse intracranial diameter (c-d) at the same level. Similarly, the Bi-Occipital Index (BOI) was determined by the ratio of the measured distance between the most lateral borders of the occipital horns (g-h) and the transverse intracranial diameter at the same level (e-f).

3. RESULTS AND DISCUSSION

3.1 RESULTS

The brain ventricular system index was observed to be generally larger in male than in females. In the males there was gradual decrease of brain ventricular system index observed from age 1-10years to age 11-20years. There is slight increase in the 4th decade, thereafter; there is continuous decline up to the 7th decade. In female a gradual decrease of brain ventricular system index was observed from age 1-10years. Thereafter, it continues to increase until the 4th decade, after which a gradual decline in brain ventricular system index was seen. The largest brain ventricular system index was 7.83cm and 7.68cm in males and females respectively, which were observed in the age group 1-10years for both sexes. While, the smallest brain ventricular system index was 7.47cm in males and 7.29cm in females, which were observed in age group 61-70years for both sexes.

Table 1: Brain –Ventricular System Index (BVS I) of the Different Age Group Males

AG`E	AHL	MICD	BFI	OHL	MICD	BOI	BVS I
1-10 (N=32)	25.78	123.3	0.20	4.96	134.1	0.04	5.00
11-20 (N=26)	26.56	124.9	0.21	5.69	119.4	0.05	4.20
21-30 (N=27)	26.92	136.6	0.20	5.86	139.7	0.06	3.33
31-40 (N=28)	25.67	117.5	0.22	6.94	113.3	0.06	3.66
41-50 (N=24)	30.96	123.8	0.25	7.87	101.5	0.08	3.13
51-60 (N=25)	33.71	120.9	0.27	7.94	114.2	0.07	3.89
61-70 (N=16)	37.02	132.7	0.28	8.64	132.1	0.06	4.66

N= Number, AHL=Anterior horn length, MICD= mid-intracranial distance. BFI=Bi-frontal index, OHL=Occipital horn length, BOI=Bi-occipital index, BVS I= brain ventricular index

Table 2: Brain –Ventricular System Index (BVS I) of the Different Age Groups Females

AGE	AHL	MICD	BFI	OHL	MICD	BOI	BVS I
1-10 (N=32)	25.35	120.4	0.21	4.93	127.1	0.04	5.25
11-20 (N=26)	26.21	119.8	0.22	5.67	125.1	0.05	4.40
21-30 (N=27)	26.37	133.4	0.20	5.77	137.7	0.04	5.00
31-40 (N=28)	25.44	114.2	0.22	6.75	124.3	0.05	4.40
41-50 (N=24)	30.4	119.9	0.25	7.72	124.1	0.06	4.16
51-60 (N=25)	33.71	113.5	0.30	7.87	123.1	0.06	5.00
61-70 (N=16)	36.62	130.3	0.28	8.43	138.1	0.06	4.66

N= Number, AHL=Anterior horn length, MICD= mid-intracranial distance. BFI=Bi-frontal index, OHL=Occipital horn length, BOI=Bi-occipital index, BVS I= brain ventricular index

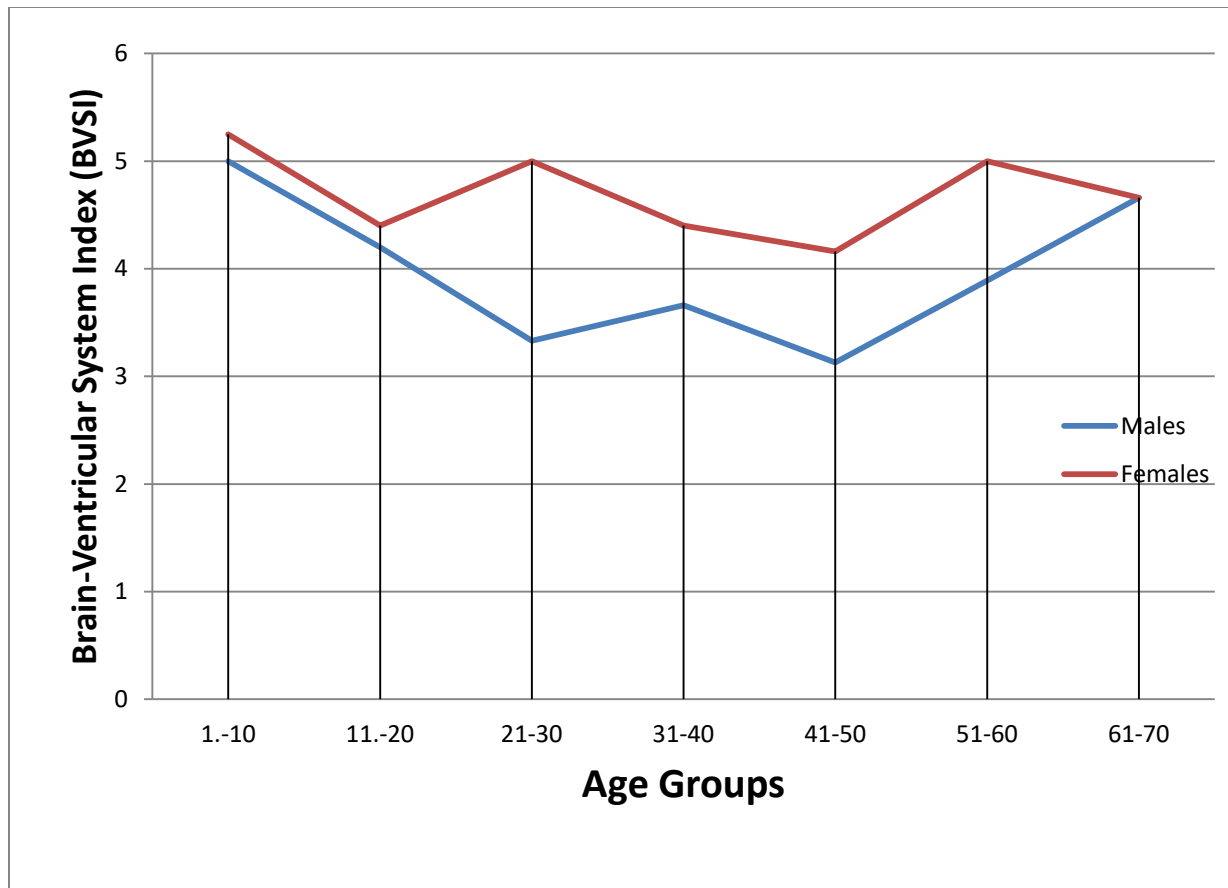


Figure 2: Graphical Representation of Brain –Ventricular System Index (BVSI) of the Different Age Group in Males and Females

3.2 DISCUSSION

Age-related changes in brain structure result from a complex interplay among various neurobiological processes, which may contribute to more complex trajectories than what can be described by simple linear or quadratic models.¹⁵

In this study the brain ventricular system index was observed to be generally larger in male than in females. This could be explained by the fact that, males have heavier and bigger skull than females.¹⁶ The capacity of skull in males is 10% more compared to that of female skull and also brain size.¹⁶

In both sexes there were gradual decrease of brain ventricular system index observed from age 1-10years to age 11-20years. We observed a slight increase in the brain ventricular system index in the 4th decade in both males and females. Thereafter, there is continuous decline in the brain ventricular system index up to the 7th decade both males and females. Ambili in their study reported brain ventricular system index to vary from 3.6cm to 8.1cm.¹⁷ which is similar to the finding in the current study although unlike in our study they did not observed an increase in the brain ventricular system index in the 4th decade. The reason for this discrepancy at the 4th decade is not very clear. Wilk in their study reported slightly lower value (2.3cm to 6.1 cm) than those observed in our study this differences could be explained by the large sample size used in their study.¹⁸ Whereas the age-related decline in gray matter volume is relatively

linear from younger adulthood, the corresponding decline in white matter tends to be nonlinear, with a plateau in middle-age and additional decline, beyond that of gray matter, in late adulthood.¹⁹

Morphometric analysis of cerebral ventricular system is essential for evaluating changes due to ageing, growth, and the various intrinsic and extrinsic pathologies.¹⁹ In this study, we observed changes in the brain ventricular ratio with age mainly as a result of increase in size of the ventricles with advancing age. Similar findings were observed by Hamidu et al from Zaria who reported enlargement of ventricles as the most common abnormality that is frequently present in a number of neurologic and psychiatric disorders in both children and adults²⁰. With MRI being part of the newer imaging techniques, CT remains the most widely affordable and available tool for the assessment of brain ventricles²¹.

4. CONCLUSION

This study has determined the Brain Ventricular System Index and its correlation with age and sexes in our environment. This could serve as a baseline data for further study.

Ethical approval

This study was conducted following an ethical approval granted by the institutional ethical committee.

REFERENCE

- 1- Gawler, J, Du Boulay, G.H, Bull, J.W, Marshall, J. Computerized tomography (the EMI Scanner): A comparison with pneumoencephalography and ventriculography. *Journal of Neurology, Neurosurgery & Psychiatry* 1976; 39: 203-11.
- 2- Gallia, G.L, Rigamonti D, Williams M.A. The diagnosis and treatment of idiopathic normal pressure hydrocephalus. *Nature Clinical Practice Neurology* 2006; 2(7): 375-81.
- 3- Roberts, M.A. and Caird, F.I. Computerised tomography and intellectual impairment in the elderly. *Journal of neurology, neurosurgery, and psychiatry* 1976; 39: 986-89
- 4- LeMay, M. Radiologic changes of the aging brain and skull. *American journal of roentgenology* 1984; 143: 383-89.
- 5- Lee, S.H. and Krishna, C.G. CT and MRI. McGraw-Hill 1987; New York
- 6- Haaga, J.R. Lanzieri, C.F. and Gilkenson, R.C. "CT and MRI imaging of the whole Body" fourth edition volume 1, chapter 4, Mosby, Inc. Philadelphia, USA, P. 1994; 88-123 and 351.
- 7- Skullerud, K. Variations in the size of the human brain. Influence of age, sex, body length, body mass index, alcoholism, Alzheimer changes, and cerebral atherosclerosis. *Acta Neurology* 1985; 102:1-94.
- 8- Gyldensted, C. and Kosteljanet M. Measurements of the normal ventricular system with computer tomography of the brain. A preliminary studies on 44 adults. *Neuroradiology* 1976;10: 205-213.
- 9- McRae, D. Radiology in epilepsy. Handbook of clinical neurology New York: Elsevier 1974; 553-63.
- 10- Scott, M.L., Golden, C.J., Ruedrich, S.C. and Bishop, R.J. Ventricular enlargement in major depression. *Psychiatry Research* 1983; 8:91-93.
- 11- McCarley, R.W., Shenton, M.E., O'Donnell, B.F., Faux, S.F., Kikinis, R., Nestor, P.G. and Jolesz, F.A. Auditory P300 abnormalities and left posterior superior temporal gyrus volume reduction in schizophrenia. *Archives of General Psychiatry* 1993; 1, 50(3): 190-7.
- 12- Ashtari, M., Zito, J.L., Gold, B.I., Lieberman, J.A., Borenstein, M.T. and Herman, P.G. Computerized volume measurement of brain structure. *Investigative Radiology* 1990; 1;25(7):798-805.

- 13- Rohlfing, T., Sullivan, E.V. and Pfefferbaum, A. Deformation-based brain morphometry to track the course of alcoholism: Differences between intrasubject and inter-subject analysis. *Psychiatry Research Neuroimaging* 2006; 31;146(2):157-70.
- 14- Ferrari, M.L., Kimura, L., Nita, L.M. and Elkis, H. Structural brain abnormalities in early-onset schizophrenia. *Archives of Neuropsychiatry* 2006; 64,(3): 741-746.
- 15- Last, R.J and Tompsett D.H. Casts of the cerebral ventricles. *British Journal of Surgery* 1953; 40: 525-543.
- 16- Williams, P.L., Bannister, L.H., Berry, M.M., Collins, P., Dyson, M. and Dussek, J.E. . The Anatomical basis of Medicine and Surgery, 38th Ed. Edinburgh: Elsevier Churchill Livingstone 1995; Page 1205-9.
- 17- Ambili, P. Ct measurements of two cerebroventricular indices and their relation with age. *Journal of Evidence Based Medicine Health* 2017; 4(6): 303-306.
- 18- Wilk, R., Kluczevska, E., Syc, B. Normative values for selected linear indices of the intracranial fluid spaces based on CT images of the head in children. *Poland Journal of Radiology* 2011; 76, (3): 16-25.
- 19- Marnier, L., Nyengaard, J.R., Tang, Y. and Pakkenberg, B. Marked loss of myelinated nerve fibers in the human brain with age. *Journal of Comparative Neurology* 2003; 462: 144–52.
- 20- Hamidu, A.U., Olarinoye-Akorede, S.A., Ekott, D.S., Danborn, B., Mahmud, M.R., Balogun, M.S. Computerized tomographic study of normal Evans index in adult Nigerians. *Journal of neurosciences in rural practice*. 2015 Jan;6(1):55.
- 21- Patnaik, P, Singh, V, and Singh, S, Singh, D. Lateral Ventricle Ratios Correlated to diameters of cerebrum - a study on CT scans of head. *Journal of Anatomical Sciences (JAS)* (2014;22(2):5-11