

Original Research Article

**HISTOPATHOLOGICAL ANALYSIS OF HEXAVALENT CHROMIUM
TOXICITY TO OVARY AND TESTIS OF FRESHWATER FOOD FISH,
CHANNA PUNCTATUS (BLOCH. 1793)**

Abstract

A major issue nowadays is aquatic contamination by heavy metals like Chromium as a result of industrial, agricultural and domestic activities and cause threat to the aquatic ecosystem. This study's objective was to evaluate the toxicological effects of chromium (VI) in freshwater food fish, *Channa punctatus*. For the experiment, a medium-sized fish (10 ± 2 cm, 30 ± 5 g) was collected from local aquatic habitat and acclimatised in a lab under controlled conditions. There were one control and three exposed groups having different sublethal concentrations of chromium ($LC_{50/5} = 15.378$ mg/l, $LC_{50/10} = 7.689$ mg/l, and $LC_{50/20} = 3.844$ mg/l). Fish sacrificed to create slides after the desired duration. Compared to control, fish exposed to different sublethal concentrations showed substantial alterations in their gonads. The highest adverse effects were seen in the ovary and testes in group 4 ($LC_{50/5}$) compared to the lower in group 2 ($LC_{50/20}$) in contrast to the control (group 1), Large intrafollicular gaps and nuclear membrane rupture in stage IInd oocytes were seen in the ovary, whereas intralobular edoema, disruption of the germinal epithelium, and severe vacuolization were recorded in the testes. According to the findings of the current research, chromium (VI) has a negative impact on fish reproductive tissue and disturbs ecological balances.

Keywords: Chromium, Ovary, Testes, Histopathology, *Channa punctatus*

Introduction

These days, pollution is a big worry that affects not only the environment (roads, trash, and industrial sectors) but also the water supply. The majority of heavy metals that cause toxicity in aquatic systems are regarded as important aquatic pollutants. Chromium is a heavy metal that is regarded as a serious contaminant. Chromium poisoning poses a serious threat to aquatic environments, especially when it manifests as Chromium (VI), a hexavalent metal.

The water we need to survive is becoming more dangerous every day as a result of human activity. Chromium is a naturally occurring metal that may be found in a variety of environmental sources, such as wastewater and industrial waste. Fish are especially susceptible to the harmful effects of Chromium (VI) because they are directly exposed to it via their food and water sources. Because it is so poisonous, Chromium (VI) may seriously harm fish populations. When fish are exposed to high quantities of Chromium (VI), it may enter their bodies via the gills and cause systemic poisoning by affecting the digestive, circulatory, and reproductive systems (Tumolo et al., 2020).

For monitoring environmental contamination, particularly the presence of Chromium (VI), fish are useful bioindicators. Fish may gradually collect the harmful metal in their tissues after being exposed to Chromium (VI) in their natural environment. As Chromium (VI) is present in aquatic food sources, this buildup happens as a result of both direct water exposure and dietary intake. Fish are impacted by Chromium (VI) in several ways (Taslina et al., 2022). It may harm the gonads, reducing their capacity for gametogenesis and general fitness. Furthermore, Chromium (VI) may build up over time in fish tissues, resulting in chronic exposure and bioaccumulation throughout the food chain. Fish exposed to high concentrations of Cr (VI) may show a variety of symptoms, including changed behaviour, slowed growth rates, and aberrant reproductive pattern (Ciacci et al., 2012). Additionally, it may have an impact on immunological function, making fish more susceptible to illnesses and infections. Additionally, it has been discovered that Chromium (VI) has genotoxic effects that induce DNA damage and mutations in fish populations.

Reduced GSI, fecundity, hatching rate, fertilisation success, abnormal shape of reproductive organs, and finally overall reproductive success have all been reported as reproductive compromises in response to a variety of heavy metals (ForouharVajargah et al., 2020; Gárriz et al., 2017; Gupta et al., n.d.; Yan et al., 2020). Chromium VI exposure may interfere with fish's natural reproductive processes. It could impact how hormones are regulated, influencing the development of gametes (eggs and sperm) and fertility. Reduced reproductive success and population reduction may result from this. It decreased spawning success as well (Delbes et al., 2022). The toxicity may impact the quality and viability of gametes, resulting in reduced rates of fertilisation and lower rates of offspring hatching or survival. High levels of chromium VI may result in morphological and histological abnormalities in fish gonads when there are gonad abnormalities. This may include modifications to the gonads' size, shape, and organisation, as well as changes to the way reproductive cells grow

and are structured. By interfering with the endocrine system, which controls several physiological functions, including reproduction, exposure to chromium may also lead to endocrine disruption. Endocrine signalling disruption may cause hormonal abnormalities, which can impair the healthy operation of fish reproductive systems. Few, if any, generalised or comprehensive patterns of these responses are known, despite the damaging effects of numerous heavy metals on fish physiology and reproductive function (Bhat et al., 2023).

Materials and methods

Test chemical in this experiment

The test chemical was the substance CrO_3 (>98%). The purified chromium (VI) oxide analytical grade, produced by Merck Specialities, Private Limited (Shiv Sagar Estate 'A'), Mumbai, was utilised. The fish were prepared to be exposed to the three distinct concentrations.

Test Specimen

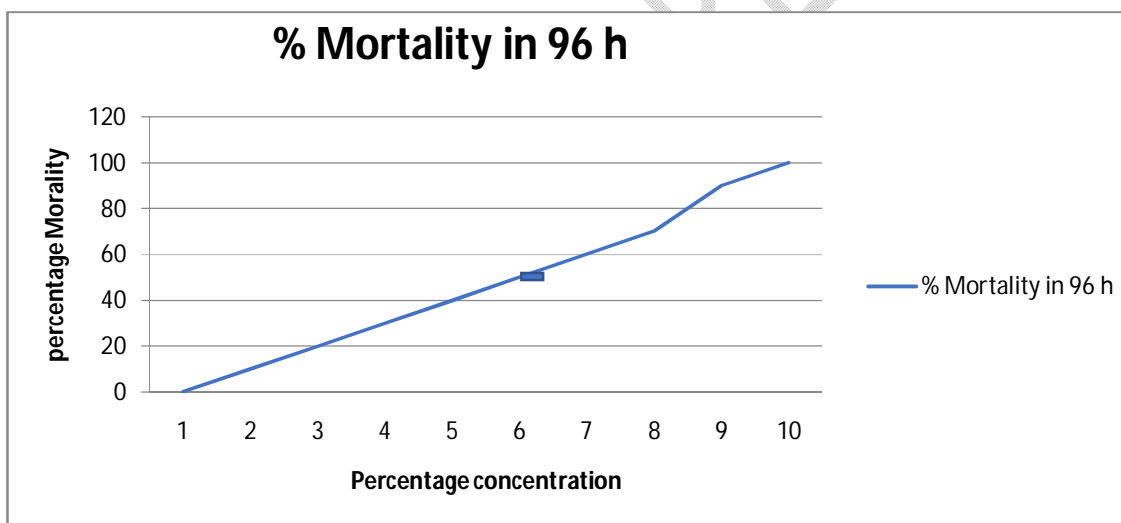
For the experimental test, *Channa punctatus*, a freshwater food fish of length (10 ± 2 cm) and weight (30 ± 5 g), was selected from the local fish market in Lucknow, India, and procured with the assistance of fishermen. It is used for the experiment since it is readily available and inexpensive. For the purpose of the experimental setup, fish were maintained in aquariums. In four tanks with four sublethal amounts, fish were added. To get rid of any skin infections, fish were adequately cleansed with tap water and treated with a 0.01% KMnO_4 solution. Before beginning the experiment, the fish spent 10 days getting used to the lab environment. Commercial dry pellets were used to continually feed fish (Tokyo fish food; Beijing, China). Fish were subjected to various concentrations of varying grades.

Experimental Set-up

Chromium trioxide (CrO_3) LC_{50} 96-hour value was determined in step one of the experiment, and three distinct sublethal CrO_3 concentrations ($\text{LC}_{50}/5 = 15.378$ mg/l, $\text{LC}_{50}/10 = 7.689$ mg/l, and $\text{LC}_{50}/20 = 3.844$ mg/l) along with a control were included in step two. The whole experiment was planned to last 28 days. All of the chosen parameters were evaluated seven, fourteen, twenty-one, and twenty-eight days afterwards.

LC_{50} value determination for 96 hours

Various sets of experiments were developed to provide the raw data needed to determine the LC_{50} for the test chemical, chromium trioxide, after 96 hours. At least 10 concentrations were gathered in a logarithmic ratio, with 10 fish exposed to each dosage in glass tanks. Fish fatalities were discovered after 24, 48, 72, and 96 hours, and the cadaver was then taken out of the tank. The requisite "Trimmed Spearman Karber" programme was loaded into a Core i3 computer with the raw data thus created for each concentration and chemical, and the LC_{50} values for 96 hours of exposure along with their 95% upper and lower confidence limits were acquired. As a result of data analysis using the necessary software for the "Trimmed Spearman-Karber Method" (H Lee P K et al., 1957), graphical data were produced, demonstrating that 50% mortality was achieved at a concentration of 6 percent (82 mg/l). On exposure to CrO_3 for 96 hours, the 95% confidence limit was attained ($LC_{50} = 76.8$ mg/l). The results showed that the lower confidence limit was 68.24 and the upper confidence limit was 85.52.



Graph 1. Determination of LC_{50} chromium trioxide (CrO_3) by "Trimmed Spearman-Karbers Method"

Statistical Analysis

The mean and standard deviation (SD) of the observed data were used to express them. A Probit analysis was used to get the chromium LC_{50} 96-h value. A one-way ANOVA was used to analyse the data, and then a post hoc test was used to determine if there were any statistically significant differences between treatment and control values. At a significance

level of ($p > 0.05$), statistical analysis was carried out using **SPSS version 26.0** for Windows (SPSS Inc., Chicago, Illinois, USA).

Histology and slide preparation

Fish were first captured for the purpose of making slides, then they were anaesthetised after that they were sacrificed so that the organs could be collected. For histological investigation, gonad slices were taken from the middle of the ovary on a monthly basis. After being washed under running water, the samples were dehydrated using ethanol concentrations of 50%, 70%, 90%, and 100% in progressive order. Using the modified gonad maturity scale created by Arockiaraj et al., n.d., the ovarian phases of *Channa punctatus* were identified. Fish treated to sublethal levels of **Chromium (VI)** across a variety of exposure times showed significant testis histological changes. The seminiferous tubules in testicles are often of different sizes and forms, and each tubule has a distinct, thin fibrous wall that is lost following spaying. In the form of a decrease in the quantity of and condensation of RZ, the testes of *Channa punctatus* demonstrated extremely noticeable alterations to sublethal concentrations of chromium. Sokal and others, Fish inhibition and testicular dysfunction have been seen, and these phenomena are linked to the direct cytotoxic effects of heavy metal and the disturbance of endocrine function. The findings of this research show that chromium in water may change the histology of the testes in the fish *Channa punctatus*.

Results and Discussion

Figure 2 displays the testis and ovary histological sections from the reference location. To start, the ideal testicular structure consists of two long, paired organs that are linked to the dorsal body wall. The histology of fish ovaries exposed for exposure periods of 7, 14, 21, and 28 days to sublethal concentrations of chromium (VI) ($LC_{50}/5$, $LC_{50}/10$, $LC_{50}/20$) that are low, medium, and higher concentrations of each of their concentrations alone (synergistic effects) showed a variety of histopathological findings. The damage percentage of the ovary is observed to be at its highest at higher concentrations of chromium, or $LC_{50}/5$ concentration, after 28 days after exposure, as compared to the control, whose variations in damage percentage ranged from 18.58 ± 0.62 to 1.57 ± 0.33 . The lowest infection rate occurred after exposure to **Chromium (VI)** for 7 days, or 7.37 ± 0.62 . However, compared to all the data for the group that had been exposed to toxins, the control case damage percentage was the lowest. Oocytes in the control *Channa punctatus* ovary's section are normal (Fig. 2). Ovarian

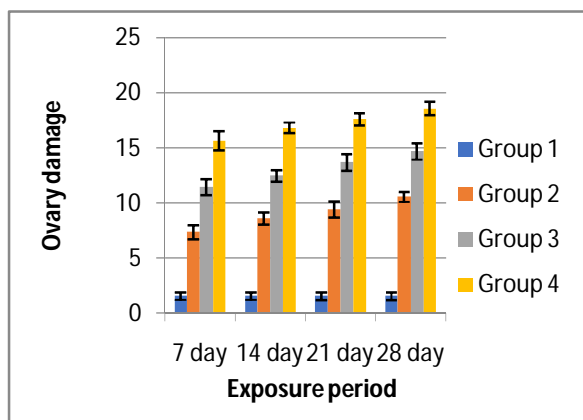
section of *Channa punctatus* exposed to LC₅₀/10 for 14 days, demonstrating vacuolization with yolk vehicles placed near the ovum's perimeter. When the exposure level was intermediate, the outcome was moderate. Compared to the control, the gonads index was substantially lower (Table 1). In contrast to the control fish's homogeneous expansion into the ovaries (Fig. 1), the heavy metal group's growth was chronically exposed (Fig. 2). All stages of oocytes from the preliminary phase ovaries, non-yolky stage 1 oocytes, and ovary and testicles from stages 1, 2, and 3 all had smaller diameters. In comparison to the control fish, fewer oocytes were found in the exposed fish.

Testicles exhibit an inflammatory reaction after Chromium (VI) exposure. Table 1 shows a little disturbance in seminiferous tubules. The majority of the testicular injury was discovered after 24 days of exposure to a higher concentration of CrO₃, which was 27.61 ± 0.65 , compared to a control concentration of 1.45 ± 0.55 . Compared to control, there were larger changes in the damage percentage. A 7-day exposure to Chromium (VI) was determined to cause the least amount of harm, which was 9.12 ± 0.43 and 2.22 ± 0.33 for controls. When testis cells are damaged histologically, the amount of vacuolization in the tubular epithelium grows as the experiment goes on. After exposure for 7 days, the testis had an inflammatory reaction, and compared to the control group, there was a small disturbance in the seminiferous tubules. Vacuolization, fluid-filled seminiferous tubules, immature spermatogonia, and a general inflammatory response were seen after 14 days of exposure. When compared to control groups, there are fewer primary and secondary spermatocytes that are readily identifiable at this stage. The main spermatocyte count is significantly reduced after 28 days of exposure, and spermatogenic cells condense with inflammation, contraction, and vacuolization of tubules. Each fish that has been treated has inflammation-producing cells in its testicular tissue. In addition to severe vacuolization and an inflammatory reaction, epithelial deformation is also extremely noticeable.

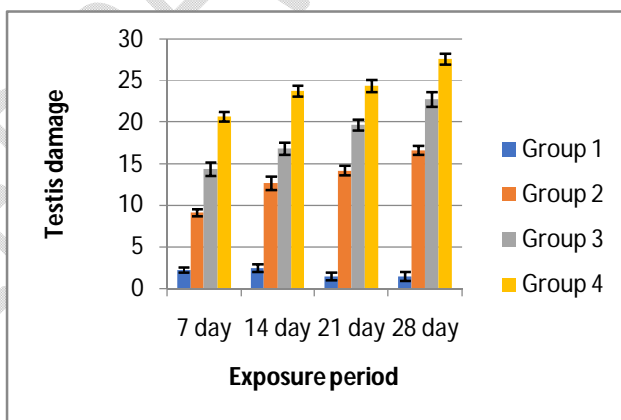
The histology of the testis and ovary was significantly altered in fish exposed to sublethal concentrations of Chromium (VI) during a range of exposure times. The seminiferous tubules in testicles often come in a variety of sizes and forms, and each one has a distinct tin fibre wall that cannot be seen after spawning. In the current investigation, sublethal exposure to chromium resulted in the severe loss of germinal components in the testis of *Channa punctatus*. Similar to the ovary, the subchronic Cr (VI) treatment group showed evidence of oocyte vitellogenic growth suppression by having a larger proportion of previtellogenic oocytes than the control groups. Overall, it has a more harmful impact on *Channa punctatus*' ovary and testicles (Mishra & Mohanty, 2008).

Table 1. Histological damage in Ovary and Testis of *Channa punctatus*.

Tissue	Exposure level	7 days	14 days	21 days	28 days
Ovary	Group 1 (Control)	1.58±0.33	1.59±0.34	1.57±0.33	1.57±0.33
	Group 2 (3.84mg/l)	7.37±0.62	8.63±0.55	9.42±0.72	10.58±0.46
	Group 3 (7.68 mg/l)	11.45±0.72	12.48±0.53	13.68±0.74	14.68±0.73
	Group 4 (15.37mg/l)	15.66±0.89	16.82±0.49	17.62±0.55	18.58±0.62
Testis	Group1 (Control)	2.22±0.33	2.44 ±0.45	1.48±0.46	1.45±0.55
	Group2 (3.84mg/l)	9.12±0.43	12.66±0.82	14.18±0.50.8	16.63±0.53
	Group3 (7.68 mg/l)	14.36±0.82	16.48±0.73	19.67±0.63	22.75±0.89
	Group4 (15.37mg/l)	20.68±0.58	23.72±0.65	24.34±0.73	27.61±0.65



Graph 2 showing histological damage in ovary



Graph 3 showing histological damage in testis

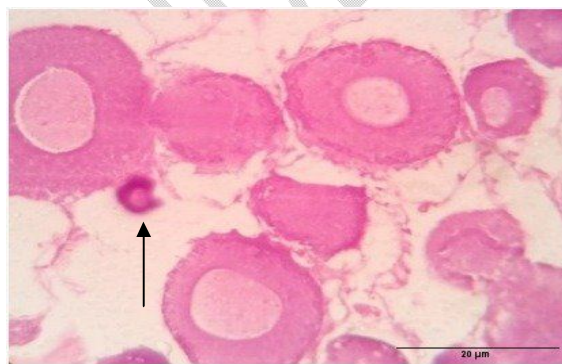


Fig.1 Control group ovary tissue

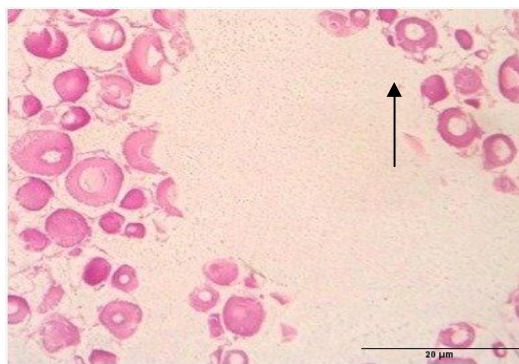


Fig.2 Exposed group ovary tissue

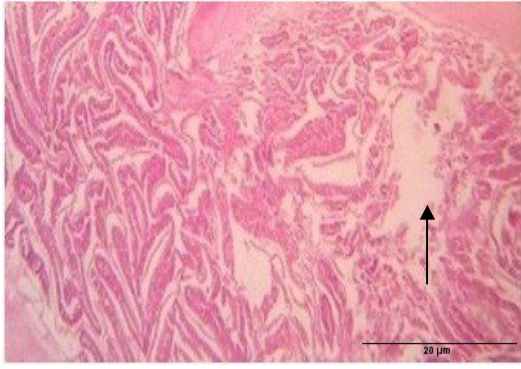


Fig 3. Control group testis

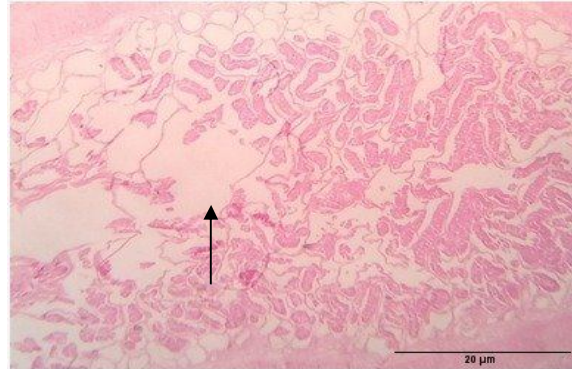


Fig.4. Exposed group testis

The histology of the testis and ovary was significantly altered in fish exposed to sublethal concentrations of Cr (VI) during a range of exposure times. The seminiferous tubules in testicles often come in a variety of sizes and forms, and each one has a distinct tin fibre wall that cannot be seen after spawning (Johnson & Radhakrishnan, 2016). After sub-lethal exposure to chromium in the current investigation, substantial loss of germinal components in the testis of *Channa punctatus* was observed. Similar to the ovary, the subchronic Cr (VI) treatment group showed a larger proportion of previtellogenic oocytes compared to the control groups, indicating that the vitellogenic growth of the oocytes had been inhibited. According to (Mishra & Mohanty, 2008) it had a greater overall harmful impact on *Channa punctatus* ovary and testicles. Sections of testis of the fish in the control and groups had numerous seminiferous lobules h intact and distinct lobular walls and interstitial tissue. The lobules contained germ cells, primarily spermatogonia, although few other stages were also seen (Basak et al., 2016; Belsare, 1966). Moreover, chromium (VI) at the highest dose induced a considerable decrease in hCG-induced germ cell proliferation. Although hypertrophy of interstitial tissue was observed with the highest dose of chromium, 11-KT production was not significantly affected. In teleost, 11-KT is synthesized by interstitial Leydig cells in testis, which leads to induction of spermatogenesis (Miura & Miura, 2001).

Conclusion

The environment is going to be seriously threatened by aquatic pollution. This experiment demonstrates a clear relationship between chromium VI content and survival. The toxicity of chromium was dramatically impacted by even a little pH shift. Monitoring the amount of Cr content in industrial effluents is necessary (Velma et al., 2009). The results of the current

research, which described the harmful effects of hexavalent chromium on a teleost fish named *Channapunctatus* ovary and testis, also imply that the overall toxic effects occur at various organ locations. According to (Mishra & Mohanty, 2008), fish populations in hexavalent chromium-contaminated waterways may be in danger from long-term exposure to this heavy metal due to the reduced proportion of damage to vitellogenic oocytes in chronically exposed fish. Chromium poisoning in fish has important ecological ramifications. Fish are essential parts of aquatic food webs, and their extinction may cause havoc with the environment as a whole. Additionally, consuming fish polluted with high amounts of Chromium (VI) might be harmful to human health (Aslam & Yousafzai, 2017). Proper monitoring and management of industrial discharges are essential to reducing the effects of chromium toxicity on fish. Chromium (VI) contamination should be reduced at the source, and wastewater treatment facilities should use efficient chromium removal techniques (Prasad et al., 2021). Additionally, supporting good waste management practises and increasing public knowledge of the dangers of chromium poisoning will help save fish and preserve the health of aquatic habitats.

References

- Arockiaraj, A. J., Haniffa, M. A., Seetharaman, S., & Singh, S. (n.d.). *CYCLIC CHANGES IN GONADAL MATURATION AND HISTOLOGICAL OBSERVATIONS OF THREATENED FRESHWATER CATFISH "NARIKELIRU" MYSTUS MONTANUS (JERDON, 1849) ACTA ICHTHYOLOGICA ET PISCATORIA (2004) 34 (2): 253-266.*
- Aslam, S., & Yousafzai, A. M. (2017). Chromium toxicity in fish: A review article. ~ 1483 ~ *Journal of Entomology and Zoology Studies*, 5(3), 1483–1488.
- Basak, R., Roy, A., & Rai, U. (2016). Seasonality of reproduction in male spotted murrel *Channa punctatus*: correlation of environmental variables and plasma sex steroids with histological changes in testis. *Fish Physiology and Biochemistry*, 42, 1249–1258.
- Belsare, D. K. (1966). Development of the gonads in *Channa punctatus* Bloch (Osteichthyes: Channidae). *Journal of Morphology*, 119(4), 467–475.
- Bhat, R. A., Bakhshalizadeh, S., Guerrero, M. C., Kesbiç, O. S., & Fazio, F. (2023). Toxic effect of heavy metals on ovarian deformities, apoptotic changes, oxidative stress, and steroid hormones in rainbow trout. *Journal of Trace Elements in Medicine and Biology*, 75. <https://doi.org/10.1016/j.jtemb.2022.127106>

- Ciacci, C., Barmo, C., Gallo, G., Maisano, M., Cappello, T., D'Agata, A., Leonzio, C., Mauceri, A., Fasulo, S., & Canesi, L. (2012). Effects of sublethal, environmentally relevant concentrations of hexavalent chromium in the gills of *Mytilus galloprovincialis*. *Aquatic Toxicology*, *120–121*, 109–118. <https://doi.org/10.1016/j.aquatox.2012.04.015>
- Delbes, G., Blázquez, M., Fernandino, J. I., Grigorova, P., Hales, B. F., Metcalfe, C., Navarro-Martín, L., Parent, L., Robaire, B., Rwigemera, A., Van Der Kraak, G., Wade, M., & Marlatt, V. (2022). Effects of endocrine disrupting chemicals on gonad development: Mechanistic insights from fish and mammals. *Environmental Research*, *204*. <https://doi.org/10.1016/j.envres.2021.112040>
- ForouharVajargah, M., MohamadiYalsuyi, A., Sattari, M., Prokić, M. D., & Faggio, C. (2020). Effects of Copper Oxide Nanoparticles (CuO-NPs) on Parturition Time, Survival Rate and Reproductive Success of Guppy Fish, *Poecilia reticulata*. *Journal of Cluster Science*, *31(2)*, 499–506. <https://doi.org/10.1007/s10876-019-01664-y>
- Gárriz, Á., del Fresno, P. S., & Miranda, L. A. (2017). Exposure to E2 and EE2 environmental concentrations affect different components of the Brain-Pituitary-Gonadal axis in pejerrey fish (*Odontesthes bonariensis*). *Ecotoxicology and Environmental Safety*, *144*, 45–53. <https://doi.org/10.1016/j.ecoenv.2017.06.002>
- Gupta, S., Saha, J., Hazra, S., & Ghosh, R. (n.d.). *Short-term Impact of Chromium on Erythrocytic Profiles of Channa punctata (Bloch, 1793)*. www.worldscientificnews.com
- H Lee P K, S. R., Hamilton, M. A., Russo, R. C., & Thurston, R. V. (1957). Quantitative Analysis of Coagulation Processes in Aqueous Systems: An Application of the Coulter Counter Technique. In *J. Sanit. Eng. Div., Am. Soc. Civ. Eng.* (Vol. 12, Issue 3). Dow Chemical Co.
- Johnson, C., & Radhakrishnan, M. V. (2016). Histopathological Analysis of Chromium Toxicity to Testis of the Catfish *Clarias batrachus* (Linn.). *IOSR Journal of Environmental Science*, *10(1)*, 1–04. <https://doi.org/10.9790/2402-10110104>
- Mishra, A. K., & Mohanty, B. (2008). Histopathological effects of hexavalent chromium in the ovary of a fresh water fish, *Channa punctatus* (Bloch). *Bulletin of Environmental Contamination and Toxicology*, *80(6)*, 507–511. <https://doi.org/10.1007/s00128-008-9406-9>
- Miura, T., & Miura, C. (2001). Japanese eel: A model for analysis of spermatogenesis. In *Zoological Science* (Vol. 18, Issue 8, pp. 1055–1063). <https://doi.org/10.2108/zsj.18.1055>

- Prasad, S., Yadav, K. K., Kumar, S., Gupta, N., Cabral-Pinto, M. M. S., Rezania, S., Radwan, N., & Alam, J. (2021). Chromium contamination and effect on environmental health and its remediation: A sustainable approaches. In *Journal of Environmental Management* (Vol. 285). Academic Press. <https://doi.org/10.1016/j.jenvman.2021.112174>
- Taslina, K., Al-Emran, M., Rahman, M. S., Hasan, J., Ferdous, Z., Rohani, M. F., & Shahjahan, M. (2022). Impacts of heavy metals on early development, growth and reproduction of fish – A review. In *Toxicology Reports* (Vol. 9, pp. 858–868). Elsevier Inc. <https://doi.org/10.1016/j.toxrep.2022.04.013>
- Tumolo, M., Ancona, V., De Paola, D., Losacco, D., Campanale, C., Massarelli, C., & Uricchio, V. F. (2020). Chromium pollution in European water, sources, health risk, and remediation strategies: An overview. In *International Journal of Environmental Research and Public Health* (Vol. 17, Issue 15, pp. 1–25). MDPI AG. <https://doi.org/10.3390/ijerph17155438>
- Velma, V., Vutukuru, S. S., & Tchounwou, P. B. (2009). Ecotoxicology of Hexavalent Chromium in Freshwater Fish: A Critical Review. In *REVIEWS ON ENVIRONMENTAL HEALTH* (Vol. 24, Issue 2).
- Yan, W., Hamid, N., Deng, S., Jia, P. P., & Pei, D. S. (2020). Individual and combined toxicogenetic effects of microplastics and heavy metals (Cd, Pb, and Zn) perturb gut microbiota homeostasis and gonadal development in marine medaka (*Oryzias melastigma*). *Journal of Hazardous Materials*, 397. <https://doi.org/10.1016/j.jhazmat.2020.122795>