

Soft Tissue Reconstruction for Pre-Prosthetic Site Development - A Case Report

ABSTRACT

Introduction: In restorative dentistry aesthetic is the prime factor during reconstruction of maxillary anterior region in young adults. Therefore loss of upper anterior teeth in that region needs special attention to patients as well as dentists. The aim of this case report was to restore normal gingival contour around fixed prosthesis in maxillary anterior region by using subepithelial connective tissue graft (SCTG) in a 16 years old male patient.

Presentation of case: A 16 years old boy presented with chief complaint of missing three upper anterior teeth causing esthetic and speech problems. Combined periodontal surgery and Endodontic and prosthetic treatment were provided.

Discussion: Several studies reported that mild to moderate ridge defect can be corrected by using sub epithelial connective tissue graft (SCTG). The present case depicts how minor correction of soft tissue defect using SCTG in relation to fixed prosthesis improves emergence profile in aesthetic region.

Conclusion: The use of soft tissue for small ridge defect restoration is a simple and cost-effective procedure.

Keywords: Aesthetic problems, Sub epithelial connective tissue Graft (SCTG), Ridge augmentation, Fixed prosthesis

1. INTRODUCTION

Reconstructive plastic surgery allows the hard and soft tissues of the alveolar ridge to be restored to their almost previous dimensions and gives the restorative dentist the opportunity to provide patients with fixed prostheses that are truly aesthetic and that will improve Dento-facial harmony [1]

Allen classifies residual alveolar ridge defects in:

Class A: A loss of the apical-coronal dimension;

Class B: A loss of the buccolingual dimension;

Class C: A loss of the apical-coronal and buccolingual dimension.

It also introduces the concept of severity, assessing defects of less than 3 mm as mild, 3 to 6 mm as moderate and those greater than 6 mm as severe [2].

Augmentations of the residual alveolar ridge with bone grafts or connective tissue grafts show a significant result in maintaining the thickness of the residual ridge and level of gingival tissue. [3] Excessive horizontal or facial resorption of residual alveolar ridge affects

the ability of the dentist to make an ovate-shaped pontic design. [3] The ovate pontic design improves the esthetic outcome of the dental prosthesis, is highly tolerated by the patient and is easy to clean. [3] Cases of extracted and missing teeth without a provisional ovate pontic may require a surgical correction of the residual alveolar ridge before the final prosthesis. The sub-epithelial connective tissue grafts reported by Langer and Calagna in 1980 and Gaber and Rosenberg in 1981 have greatly helped to completely reconstruct class B defects [4]. The ideal techniques for the increase of the alveolar ridge, are the free grafts in the tunnel, interposed or inlay and superimposed or onlay. In tunnel graft procedures [2] [5], a sub-epithelial envelope is created in the area of the ridge deformity.

In this article a case report was reported showing how placement of sub epithelial connective tissue graft altered the soft tissue pontic relationship in an area with a class B defect of Allen to provide a functional restoration that is in harmony with the adjacent natural dentition.

2. PRESENTATION OF CASE

A 16 years old male patient visited in dental outpatient department for replacement of missing upper anterior teeth. He gave a history of trauma during swimming causes loss of upper anterior teeth about one month back. On examination, it was observed that the patient had lost 11, 21 and 22. 12 was one degree mobile and slightly extruded. Overall oral hygiene was good and gingiva appeared healthy. There was Allen Class B ridge defect present labial to 21 and 22 regions.(Fig.1a) Intra-oral Periapical radiograph (IOPR) showed 12 was slightly extruded (Fig.1b) and sufficient bone support was found around 23 region.(Fig.1c) The whole treatment plan was explained to the Patient and patient's relatives and their consent was taken in a consent form. The patient was instructed for proper plaque control to eliminate periodontal inflammation and if he was a smoker for smoking cessation, since cigarette smoking plays a major role in the outcome of periodontal plastic surgery. [6,7]

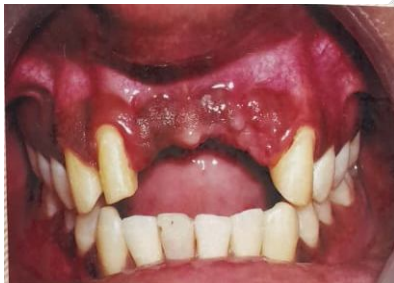

Fig. 1a. Initial View

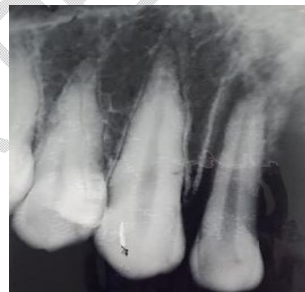


Fig 1b. Initial Radiograph of 12

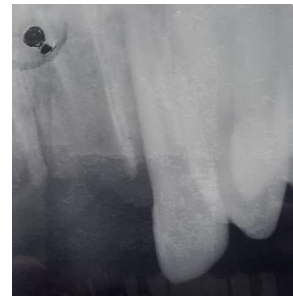

Fig.1c Radiograph of 23 showing sufficient bone

The initial preparation phase for treatment consisted of oral hygiene instructions, scaling and root planing followed by root canal treatment of 12 and occlusal corrections. Re-evaluation were done 6 weeks after the completion of this first phase of therapy. Routine blood investigation was normal. In teeth 13,12,23 abutment preparations were performed for placing temporary bridge.

Amoxicillin (500mg) 8 hourly was prescribed day before the surgery and Ibuprofen (400mg) was prescribed one hour before the initiation of surgery. Before commencing surgical procedure, the patient was asked to rinse with 0.2% chlorhexidine mouthwash (preprocedural rinse). Extra-oral scrubbing was done with 7.5% Povidone-Iodine solution. The area was anesthetized by infiltration anesthesia, 2% Lidocaine anaesthetic solution containing 1:200,000 Lidocaine Hydrochloride with Adrenaline. Number 11 surgical blade

was used to make incision slightly palatally from mesial surface of 12 up to distal surface of 23.(Fig.2a) Partial thickness flap was elevated labially.(Fig.2b) The donor tissue (SCTG) was collected from right palatal surface of 14,15,16 region and immediately placed it on the previously prepared recipient bed.(Fig.2c) A larger graft is more prone to necrosis and also leads to more of an injury to the donor site. [8] So, another small graft from adjacent site was collected and placed immediately.

Flap closed with 5-0, Vicryl absorbable surgical suture material (Ethicon manufactured by Johnson & Johnson Private Limited). The graft was completely submerged and the wound primarily closed.(Fig.2c) Temporary bridge was placed to take the advantage of post inflammatory swelling which will give the normal shaping of gingiva around the bridge.(Fig. 2d)

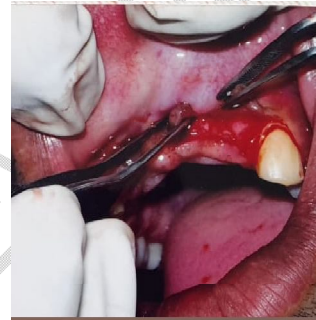
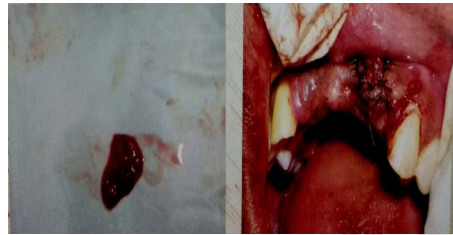
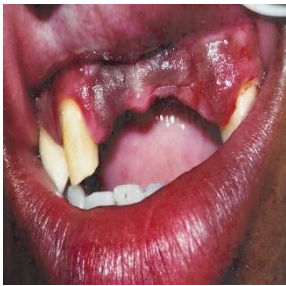
Fig.2a Incision

Fig.2b Flap elevation

Fig.2c Connective tissue graft(CTG) and after flap sutured with CTG placed.

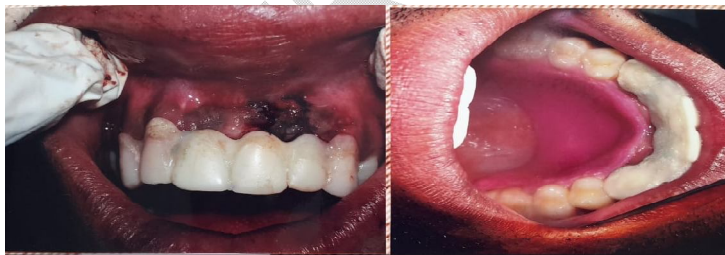

Fig.2d Immediately placed temporary restoration and cover plate placed in donor site.

Chlorhexidine (0.2%) and Hyaluronic acid mouthwash after the operation are recommended to reduce infection and improve soft tissue healing.[9] Post surgical medications should also be prescribed, including antibiotics starting on the day before initiation of surgery and lasting for 7 days (500 mg amoxicillin 8 hourly) post operatively. Post operative analgesics was also prescribed (400mg ibuprofen 8 hourly for 3 days). Patients should be informed in detail with written postoperative instructions after the operation.

Patient was instructed to report after 24 hours of surgery and then after 7 days and 4 months. (Fig. 3b) The temporary bridge was replaced with permanent bridge two months after surgery. There was reduced labial concavity in 21,22 region (Fig 3b).

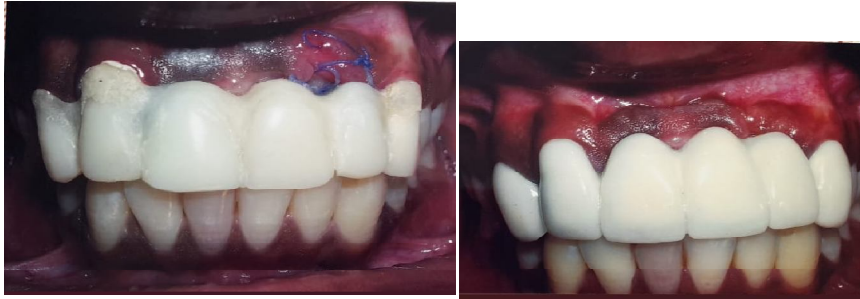

Fig. 3a After 7days with temporary restoration

Fig. 3b After 4 months with permanent restoration

3. DISCUSSION

Surgery of residual alveolar ridge augmentation with connective tissue graft gives the patient favorable results and is low cost since no additional filling materials are needed. Esthetic outcome of fixed prosthesis depends on three-dimensional emergence profile of the pontic which is highly dependent on harmony between soft tissue and prosthesis. Therefore, surgical or mucogingival alteration of hard tissue and soft tissue is essential in the defected area of the ridge to rehabilitate the prosthesis. [10] In a cohort study, it was revealed a median ridge width gain of $\approx 32\%$ using a SCTG in pontic sites with a follow-up of 1 year. [11] It has been stated that up to three-tooth defects of moderate severity can be corrected successfully by less complicated soft tissue augmentation procedure.[12] In a case report, the loss of ridge width was more evident with a little loss of ridge height; hence, an autogenous connective tissue graft was used to augment the ridge defect there.[13]

Similarly, in this present case slight buccolingual dimension was deficient and sub epithelial connective tissue graft (SCTG) from palatal region was placed by creating labial pouch in 21, 22 region. It is accepted that ridges that have been augmented with soft tissues undergo shrinkage over the first 6 weeks postoperative. From 2 months post - surgery, the ridge dimensions remain stable. In this case report, 4 months follow up showed the defect was treated successfully providing excellent emergence profile and speech problem was reduced to normal.

4. CONCLUSION

Soft tissue augmentation has become a common procedure for pre-prosthetic site development allowing the correction of minor to moderate ridge defects prior to the delivery of conventional tooth-borne fixed dental prostheses, especially at pontic sites.[14,15,16] This

is a small attempt to augment or reconstruct soft tissue defect in maxillary anterior region using connective tissue graft and thus to help in achieving excellent emergence profile with absence of black triangle in aesthetic region. As it is a long, time consuming procedure and the patient compliance was minimum complete follow up for at least one year was not possible. Only 4 months follow up was recorded and patient was satisfied. Further work in this field with long time follow up needs to be done for establishment of the importance of SCTG in ridge reconstruction during pre - prosthetic surgery.

CONSENT

As per international standard or university standard, patients' written consent has been collected and preserved by the author(s).

REFERENCES

1. Garber, D.A. and Rosenberg, E.S. The Edentulous Ridge in Fixed Prosthodontics. The Compendium on Continuing Education in General Dentistry 1981;2:212-23.
2. Allen, E.P., Gainza, C.S., Farthing, G.G. and Newbold, D.A. Improved Technique for Localized Ridge Augmentation. A Report of 21 Cases. Journal of Periodontology 1985;56:195-99. <https://doi.org/10.1902/jop.1985.56.4.195>
3. Babiuc I, Geantă I, Tănase G, et al. Clinical aspects dimensional changes of the alveolar crest following tooth extraction—a cone-beam computed tomography study. Acta Medica Transilvanica 2019;24(19):107–10.
4. Langer, B. and Calagna, L. (1980) The Subepithelial Connective Tissue Graft. Journal of Prosthetic Dentistry 1980;44:363-67. [https://doi.org/10.1016/0022-3913\(80\)90090-6](https://doi.org/10.1016/0022-3913(80)90090-6)
5. Miller Jr., P.D. (1986) Ridge Augmentation under Existing Fixed Prosthesis. Simplified Technique. Journal of Periodontology 1986;57:742-45. <https://doi.org/10.1902/jop.1986.57.12.742>
6. Erley KJ, Swiec GD, Herold R, Bisch FC, Peacock ME. Gingival recession treatment with connective tissue grafts in smokers and non-smokers. J Periodontol 2006; 77:1148-55.
7. Trombelli L, Scabbia A. Healing response of gingival recession defects following guided tissue regeneration procedures in smokers and non-smokers. J Clin Periodontol 1997; 24:529-33.
8. Gasparini DO. Double-fold connective tissue pedicle graft: a novel approach for ridge augmentation. Int J Periodontics Restorative Dent 2004;24:280-7.
9. Wang HL, Boyapati L. "PASS" principles for predictable bone regeneration. Implant Dent. 2006;15:8–17.
10. Askary AS. Multifaceted aspects of implants aesthetics: the anterior maxilla. Implant Dent 2001;101:82-91.
11. Strauss FJ, Huber BJ, Valdés A, Jung RE, Mühlemann S, Thoma DS. Pontic site development for fixed dental prostheses with and without soft tissue grafting: 1-year results of a cohort study. Clinical Oral Investigations 2022;26:6305–16. <https://doi.org/10.1007/s00784-022-04582-y>
12. Studer S, Naef R, Schärer P. Adjustment of localized alveolar ridge defects by soft tissue transplantation to improve mucogingival esthetics: A proposal for clinical classification and an evaluation of procedures. Quintessence Int 1997;28:785-805.
13. Shah AD, Mathur S, Sahayta V, Shah A, Makwana R, Shah M. Esthetic localized soft tissue ridge augmentation in a fixed partial denture – a case report. Journal of dental sciences Volume 3 Issue 1, 11-13.
14. Akcali A, Schneider D, Unlu F, Bicakci N, Kose T, Hammerle CH (2015) Soft tissue augmentation of ridge defects in the maxillary anterior area using two different methods:

a randomized controlled clinical trial. Clin Oral Implant Res 2015;26:688–95. <https://doi.org/10.1111/clr.12368>

15. Seibert JS. Reconstruction of the partially edentulous ridge: gateway to improved prosthetics and superior aesthetics. Pract Periodontics Aesthet Dent 1993;5:47–55; quiz 55
16. Thoma DS, Benic GI, Zwahlen M, Hammerle CH, Jung RE (2009) A systematic review assessing soft tissue augmentation techniques. Clin Oral Implant Res 2009;20(Suppl 4):146–65. <https://doi.org/10.1111/j.1600-0501.2009.01784.x>

UNDER PEER REVIEW