

## Case report

### **Mucinous cystadenoma of the appendix is rare entity- Two case reports**

#### **Abstract**

Mucinous cystadenoma is a rare cystic benign neoplasm of the appendix characterized by associated with marked distension of the appendix lumen with mucin, it may be inflammatory, obstruction or tumoral origin. There are four histopathological subtypes occur as mucocele, mucosal hyperplasia, mucinous cystadenoma or mucinous cystadenocarcinoma.

The incidence of 0.2 to 0.7% of dissected specimen of the appendix. Mucinous cystadenoma 63%, mucosal hyperplasia 25% mucinous cystadenoma 11% and retention cyst 1%. Approximately 50 % patients are asymptomatic and more common in females. It usually discovered incidentally during surgery or during radiological investigation on CT abdomen.

Herein we noticed two cases of mucinous cystadenoma of the appendix. Both cases were diagnosed on routine CT abdomen, we did explorative laparotomy in one patient and another patient treated by laparoscopic appendectomy.

#### **Key words**

Appendix, cystadenoma, mucocele,

#### **Introduction**

Appendicitis is a common surgical procedure done globally. Mucinous cystadenoma of the appendix with mucocele is very rare in 0.2 -0.7% of dissected specimen of the appendix Appendiceal mucocele is commonly seen after the age of 50 years with female preponderance. Appendiceal mucocele was first described in 1842 by Rokitsansky. [1,2,3]

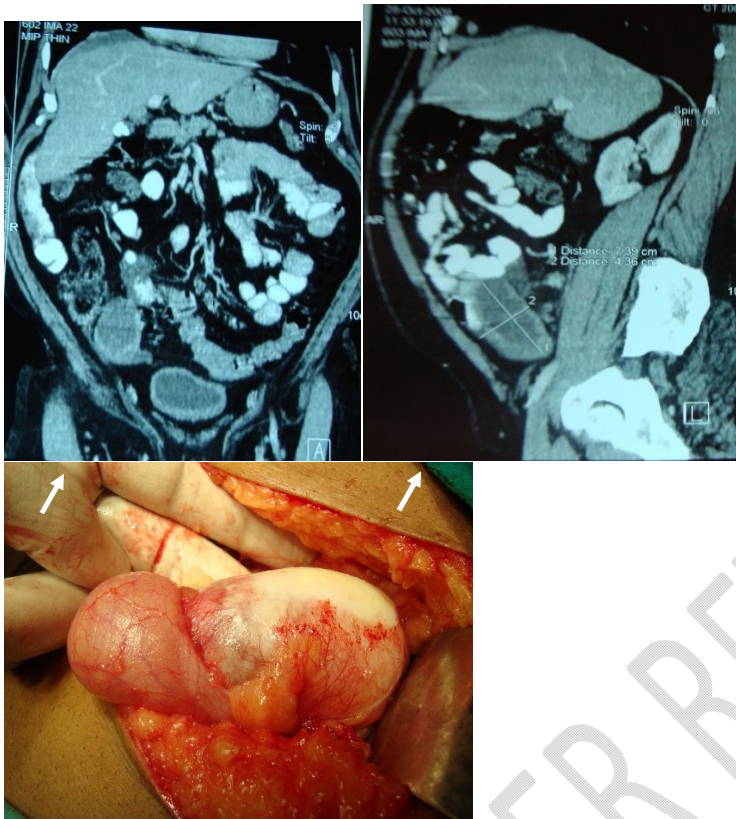
Clinical presentation is delayed, atypical with a vague lower abdominal pain or palpable lumps at Right iliac fossa or tubo-ovarian mass in the female. Preoperative diagnosis is difficult event with use of abdominal sonography or CT. Histopathological examination is needed for a definitive diagnosis. Delayed or missed diagnosis can result in spontaneous rupture of the appendix, resulting pseudomyxoma peritoni, which has a very bad prognosis.

Early surgical resection is recommended for all appendiceal mucocele to exclude mucinous neoplasm and to prevent spontaneous rupture in the abdomen, leading to pseudomyxoma peritoni. After appendectomy open or laparoscopic 5 years survival rate is 91-100% .[3,4,5]

#### **Case Report**

**Case 1-** A 62 years old male patient was admitted in our centre on 14/10/2010 his CT abdomen was done by general physician for evaluation of abdominal pain. Radiologist diagnosed the case on CT abdomen and labelled as case of Mesenteric cyst. So general physician referred the patient for surgery. CT abdomen shows a cystic swelling of size 7.5x4.5 cm in the right iliac fossa. Patient was evaluated for surgery, his all laboratory blood and kidney function test were normal. Abdominal examination revealed mild tenderness over the right iliac fossa without localized guarding or rigidity. There was a palpable cystic lump measuring 6x4 cm over the right iliac fossa.

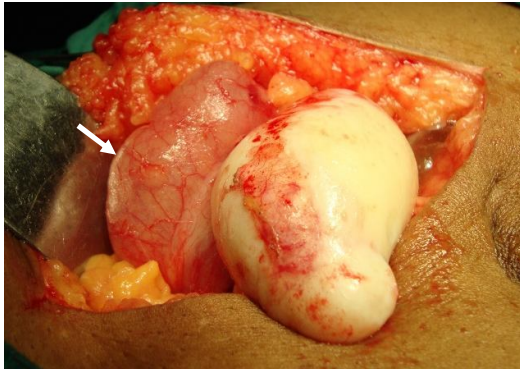
So we decided to plan explorative laparotomy and we found a cystic mass size 7.5x4.5 cm, yellowish white in colour and it was arised from the appendix and confirmed that it was not a case of mesenteric cyst. Mesentery of small bowel was normal. Simple appendectomy was performed as the caecum, base of the appendix and mesenteric nodes were normal. The postoperative course was uneventful and the patient was discharged on 8<sup>th</sup> postoperative day. Histopathological examination confirmed the final diagnosis of a benign mucinous cystadenoma of the appendix. The patient remained well on regular follow up visit over 5 years' period. (Case 1 Figure 1,2,3,4,5,6)



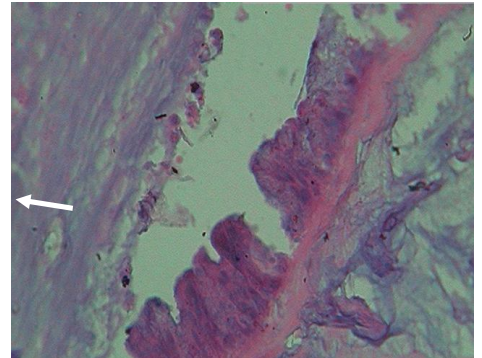
**Case 1- Fig-1,2 CT Abdomen - Showing Cystic SOL  
of size 7.39x4.36 cm at RIF**

**Case 1- Fig-3 Intra operative photographs  
Showing Mucinous cyst of the appendix**

## Mucocele of the appendix



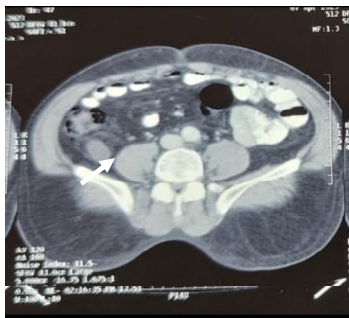**Case 1- Fig-4,5 Intra operative photographs Showing Mucinous cyst of the appendix of size 7.39x4.36 cm**



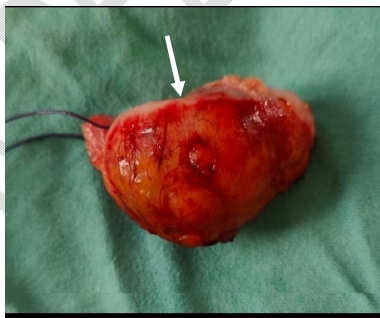**Case 1- Fig-6 Histopathology, microscopic view Showing Mucinous cystadenoma of the appendix**

**Case 2 -** A 60 years old patient was admitted in our centre on 7/04/2023 and presented with right lower abdominal pain for one year. Abdominal CT scan suggested a diagnosis of an appendicular mucocele of size 4.5x2 cm at right iliac fossa.

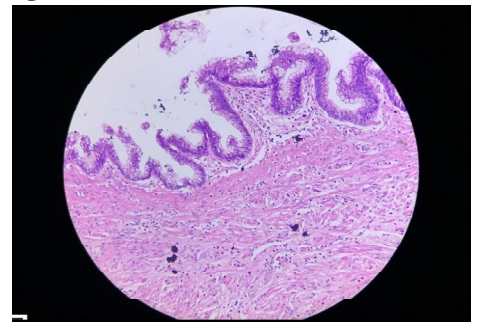
So we decided to performed laparoscopic appendectomy, during laparoscopy we noticed cystic mass of size 4.5x 2 cm arising from the appendix. So we performed simple laparoscopic appendectomy. Caecum and base of the appendix was normal. There were no mesenteric nodes and we exclude the cause for appendicular malignancy i.e. mucinous cystadenocarcinoma. The final diagnosis of mucinous cystadenoma was confirmed by histopathology. Postoperative course was uneventful and patient was discharge on 4<sup>th</sup> postoperative day. **(Case 1 Figure 1,2,3)**



**Case 2- Fig-7 CT Abdomen - Showing Cystic SOL of size 4.5x2 cm at RIF**



**Case 2- Fig-8 Intra operative photographers mucocele of appendix size 4.5x2 cm**



**Case 2- Fig-9 Histopathology, microscopic view Showing Mucinous cystadenoma of the appendix**

noma are pain at right iliac fossa, lump at right iliac fossa, about 25-50% of patients are asymptomatic and cases are found incidentally on imaging or at the time of surgery. [1,2]

There are four histological subtypes of appendiceal mucocele, simple retention cyst, mucocele hyperplasia, mucinous cystadenoma and mucinous cystadenocarcinoma. The initial detection of the lesion on ultrasonography, colonoscopy or CT abdomen. CT of the abdomen usually shows as cystic well-encapsulated mass with mucosal calcification. Ultrasonography findings hypoechoic masses with fine internal echoes. Colonoscopy findings is “Volcano Sign” or lipoma like submucosal mass. [3,4]

Surgical excision of mucocele of appendix can either be by laparotomy or laparoscopy, laparoscopic. Surgery provides the advantages of good exposure and evaluation of entire abdominal cavity and more rapid recovery. However careful handling of the specimen is recommended as

spillage of the mucinous content can lead to pseudomyxoma peritoni if there is evidence of malignancy such as peritoneal deposits, involvement of caecum or mesenteric lymph nodes then indication for right hemicolectomy. [2,5,6,7]

There are two categories of appendiceal mucinous lesion.

1. Non neoplastic – Simple mucocele, retention cyst, inflammatory or obstructive mucocele and benign mucinous cystadenoma.
2. Neoplastic – These lesions are further divided into low grade appendiceal mucinous neoplasm and high grade mucinous neoplasm, depending on cytological grades. Appendiceal neoplasm may rupture and mucin spill in to peritoneal cavity leading pseudomyxoma peritoni, [2,3,9]

## Conclusion

Mucinous cystadenoma of the appendix is rare entity. Open or laparoscopic surgery has excellent long term prognosis. Meticulous surgery is the main stay of treatment and open surgery is the preferred approach than laparoscopy.

## Reference

1. Ng SS, Lee JF. Mucinous cystadenoma of the appendix. *Can J Surg.* 2009 Apr;52(2):158-9. PMID: 19399213; PMCID: PMC2663491.
2. Kılıç MÖ, İnan A, Bozer M. Four mucinous cystadenoma of the appendix treated by different approaches. *Ulus Cerrahi Derg.* 2014 Jun 1;30(2):97-9. doi: 10.5152/UCD.2014.2397. PMID: 25931904; PMCID: PMC4379824.
3. Ben Rymer, Rachael Forsythe, Glen Husada, Mucocoele and mucinous tumours of the appendix: A review of the literature, <https://doi.org/10.1016/j.ijsu.2015.04.052>
4. Nawaf R Alsubaie and others, Appendicular mucinous cystadenoma: a case report, *Journal of Surgical Case Reports*, Volume 2023, Issue 3, March 2023, rjad097, <https://doi.org/10.1093/jscr/rjad097>
5. Stephanie Young MD, MPH, Stefanie K. Sueda MD, Mayo Hotta MD, Michael L. Sung MD, MS, Victoria V. O'Connor MD, Anna M. Leung, Surgical management of appendiceal mucinous neoplasm: Is appendectomy sufficient?, <https://doi.org/10.1002/jso.26108>.
6. Louis TH, Felter DF. Mucocele of the appendix. *Proc (Bayl Univ Med Cent).* 2014 Jan;27(1):33-4. doi: 10.1080/08998280.2014.11929046. PMID: 24381400; PMCID: PMC3862129.
7. Bartlett, C., Manoharan, M. & Jackson, A. Mucocele of the appendix – a diagnostic dilemma: a case report. *J Med Case Reports* 1, 183 (2007). <https://doi.org/10.1186/1752-1947-1-183>
8. Eltaib A Saad and others, Surgical treatment of mucocele of the appendix: a systematic review and case report, *Journal of Surgical Case Reports*, Volume 2018, Issue 6, June 2018, rjy102, <https://doi.org/10.1093/jscr/rjy102>
9. Demetrashvili Z, Chkhaidze M, Khutsishvili K, Topchishvili G, Javakhishvili T, Pipia I, Qerqadze V. Mucocele of the appendix: case report and review of literature. *Int Surg.* 2012 Jul-Sep;97(3):266-9. doi: 10.9738/CC139.1. PMID: 23113858; PMCID: PMC3723229.

10. B Bakula, N Antolić, Laparoscopic appendectomy for appendiceal mucocele, Epublication WebSurg.com, Jan 2022;22(01). URL: <http://websurg.com/doi/vd01en6563>

UNDER PEER REVIEW