

# Hormonal and Morphological Effects of AverrhoaCarambola Fruit Extract on Female Reproduction

## Original Research Article

### ABSTRACT

Medical herbs are dazzling resources that influence female fertility. The effect of *Averrhoacarambola* ethanolic fruit extract on gonadal function and structure in female Wistar rats was investigated in the study. 15 Wistar rats weighing 100 to 143g were divided into three groups of five rats each. Food and distilled water were given to Group A, 500mg/kg of ethanolic fruit extract of *A. carambola* was given to Group B, and 1000mg/kg of ethanolic fruit extract of *A. carambola* was given to Group C every day for 21 days through oral gavage. The animals were anesthetized with chloroform at the end of the experiment, and serum was taken for hormone testing. When compared to the control, there was a significant ( $p < 0.05$ ) weight gain in the test groups. In addition, there was a substantial rise in ovarian and uterine weight in groups B and C after receiving the *Averrhoacarambola* fruit extract compared to the control group. However, when compared to the control group, LH increased ( $p > 0.0$ ) while progesterone declined significantly. According to the findings, the extract's structural effects on the gonads of female rats were shown to be adverse. In conclusion, *Averrhoacarambola* fruit extract may be more beneficial as a contraceptive than a pro-fertility agent, as traditional medicine practitioners claim.

**Key words:** *Averrhoacarambola*, Hormonal, Morphological, Reproduction.

### Introduction

In recent years, medicinal plants have acquired substantial prominence in the management of a variety of human illnesses, outperforming synthetic medications with few side effects. Secondary metabolites found in medicinal plants, such as flavonoids, glycosides, tannin, saponin, terpenoids, and others, have been demonstrated to play a part in the healing process of diseases (Wei *et al.*, 2018). Plant products with higher medicinal properties have been connected to a substantial impact on the development of novel medications.

The fruit of *Averrhoacarambola*, which belongs to the Oxalidaceae family, is noted for its strong therapeutic potential. Star fruit and Chinese gooseberry are the English appellations for it. It's called Kamrakh and Karmal in Hindi, Balimbing and saranate in Phillipino, Belimbing in Indonesian, and Belimbing in Malay (Das Gupta *et al.*, 2013).

It is widely consumed as a fruit in various tropical places around the world, and it is widely grown in Southeast Asia (Khoo 2016).

Infertility, fever, cough, diarrhea, persistent headache, inflammatory skin problems (eczema), and fungal skin infections are all treated using the fruits and other aerial parts of *A. carambola*, according to an ethnomedical review (Wang 2019). Different parts of the plant, particularly the ripening fruits, are employed as antipyretics, laxatives, appetite stimulants, sialogogues, astringents, and other medicinal properties. Inflammation of the throat, mouth ulcers, toothaches, cough, asthma, hiccups, food poisoning, colic, diarrhea, jaundice, malarial splenomegaly, hemorrhoids, skin rashes, pruritis, sunstroke, and some eye disorders are all treated with the fruits.

When crushed and applied topically, the leaves are said to treat chicken pox, ringworm, and headache locally. Oliguria, boils and pyodermas, postpartum edema, gastroenteritis, and traumatic injuries are also treated with the leaves. Fever and malaria are treated using the blossoms. Arthralgia, chronic headache, epitaxis, and spermatorrhea are all treated with the roots. When mixed or blended with sugar, it acts as a toxic antidote (Das Gupta *et al.*, 2013).

*A. carambola* has antioxidant, hypoglycemic, hypotensive, hypocholesterolemic, antiinflammatory, antiinfective, and anticancer properties, according to a pharmacological review (Lakmal 2021). Following the injection of the root extract of *A. carambola* in a diabetic animal, Qin *et al.*, (2020) discovered a considerable drop in blood glucose levels. Aladailehet *et al.*, (2019) found that rats fed high-fat diets had lower serum lipid levels, as well as lower body mass index, atherogenic index, hepatic cholesterol, and triglycerides, and higher fecal cholesterol and bile acids. Leelarungrayubet *et al.*, (2016) found a substantial increase in overall antioxidant capacity, lower levels of malondialdehyde and protein hydroperoxide, and higher levels of vitamin A and C. Cabrini *et al.*, (2011) found that an ethanolic extract of star fruit leaves reduced edema in the croton oil-induced ear edema model of inflammation in a dose-dependent manner. Myeloperoxidase activity was decreased by the ethanolic extract or its fractions, suggesting that these chemicals may influence cell motility during the inflammatory process. TNF alpha, interleukin (IL) 23, and nitric oxide levels were reduced after 4 weeks of star fruit juice drinking, according to Leelarungrayubet *et al.*, (2016).

The strong flavonoids activity was linked by Vastraet *et al.*, (2020) to its substantial anti-ulcer action in gastric damage produced by free radicals. On indomethacin and pylorus ligation-induced ulcer

models, Kulalet *al.*, (2021) demonstrated a gastro protecting and anti-ulcerogenic effect. Also, indomethacin and pylorus ligation have potent ulcer-protective efficacy of up to 71.36 percent and 76.48 percent, respectively, as well as a reduction in stomach volume, total acidity, free acidity, and ulcer index, as well as a rise in gastric pH. According to a phytochemical analysis, *A. carambola* contains saponins, flavonoids, alkaloids, tannins, and pyrogallol steroids (Muthu 2016). Phenols, anthocyanin and anthocyanidin, chalcones and auronones, leucoanthocyanidins, catechins, and triterpenoids were all isolated from different portions of the star fruit (Silva 2021).

Despite its vast medicinal efficacy, research on the effects of Star fruits on gonadal function and structure in female wistar rats is sparse.

## **Materials and methods**

### **Preparation of extract**

*Averrhoa Carambola* (Star Fruit) fruits were cleaned under running tap water and air-dried at room temperature. Using a local grinder, the dried fruits of *Averrhoa carambola* were ground into a coarse powder. 250 grams of dried *Averrhoa Carambola* fruits were macerated for 48 hours in 1000 milliliters of 95 percent absolute ethanol (JHD, China). It was first filtered with a clean porcelain cloth, then with Whatman No 1 filter paper (Sigma Aldrich WHA1001042). A rotatory evaporator (TT-52, Techmel&Techmel, USA) was used to concentrate the filtrate, which was then dried into a gel-like form in a laboratory oven (DHG-9023A, PEC MEDICAL USA) at 45°C. The extract was kept in the refrigerator to be used later. This extraction process was based on Al-Attar's (2013) approach with certain modifications.

### **Acute Toxicity of ethanolic fruit extract of *Averrhoa carambola***

Lorke's (1983) method was used to determine the median lethal dose (LD<sub>50</sub>) of the Ethanolic fruit extract of *Averrhoa carambola*, which was shown to be greater than 2000mg/kg for more than 28 days.

### **Experimental design**

The animals were separated into three groups of five animals each for the study.

Group A received only food and distilled water.

Group B received 500mg/kg of *A. carambola* ethanolic fruit extract

Group C received 1000mg/kg of *A. carambola* ethanolic fruit extract

The extract was given to the subjects once a day for 21 days via oral gavage.

### **Preparation of Serum**

Blood was collected from rats in each group at random through ocular puncture into sterile containers, spun, and stored in the refrigerator. The rats were then sacrificed through cervical dislocation.

### **Hormonal Assay**

The luteinizing hormone and FSH levels were determined using the enzyme immunoassay technique, as stated in the manufacturer's instructions.

### **Histological Examination**

The control and treatment rats' ovary and uterus were fixed in Bouin's fluid for 6 hours before being transferred to 10% formalin for histological assessment. The tissues were treated and examined under a light microscope on a regular basis. The slide was then photomicrographed (Rajiet *al.*, 2010).

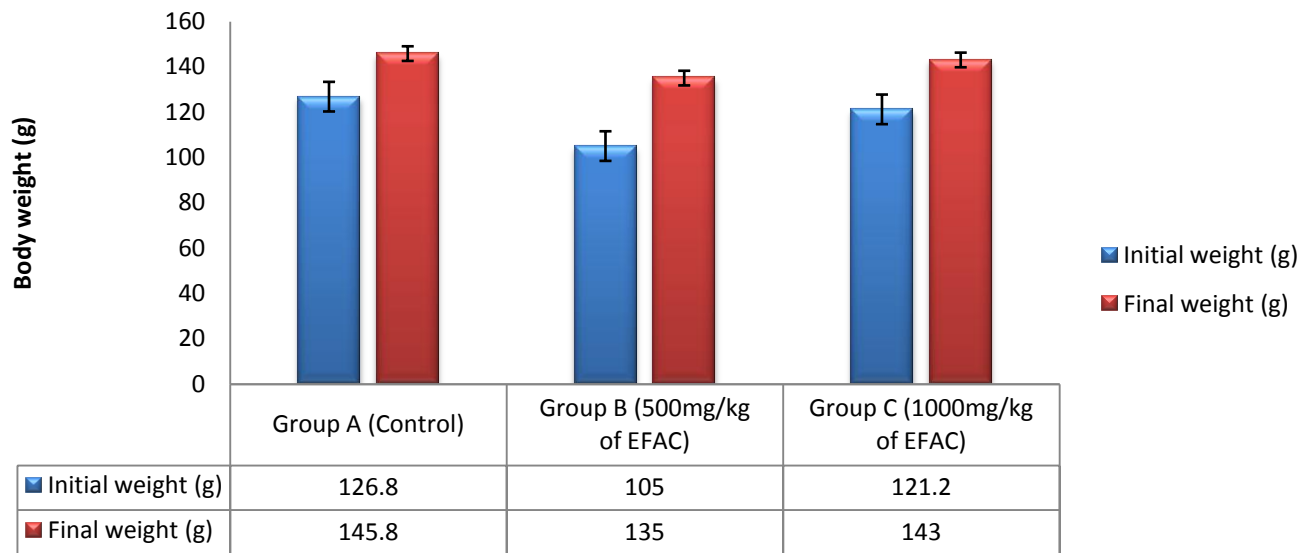
### **Statistical Analysis**

Statistical Science for Social Sciences (SPSS) version 25 was used to analyze the data from this study. The results of the hormonal profile (FSH, progesterone, and LH), as well as the Gonadosomatic index weight (ovary and uterine), were analyzed using ANOVA and post hoc Turkey. The T-dependent test was used to examine body weight. At  $p < 0.05$ , the data was declared significant.

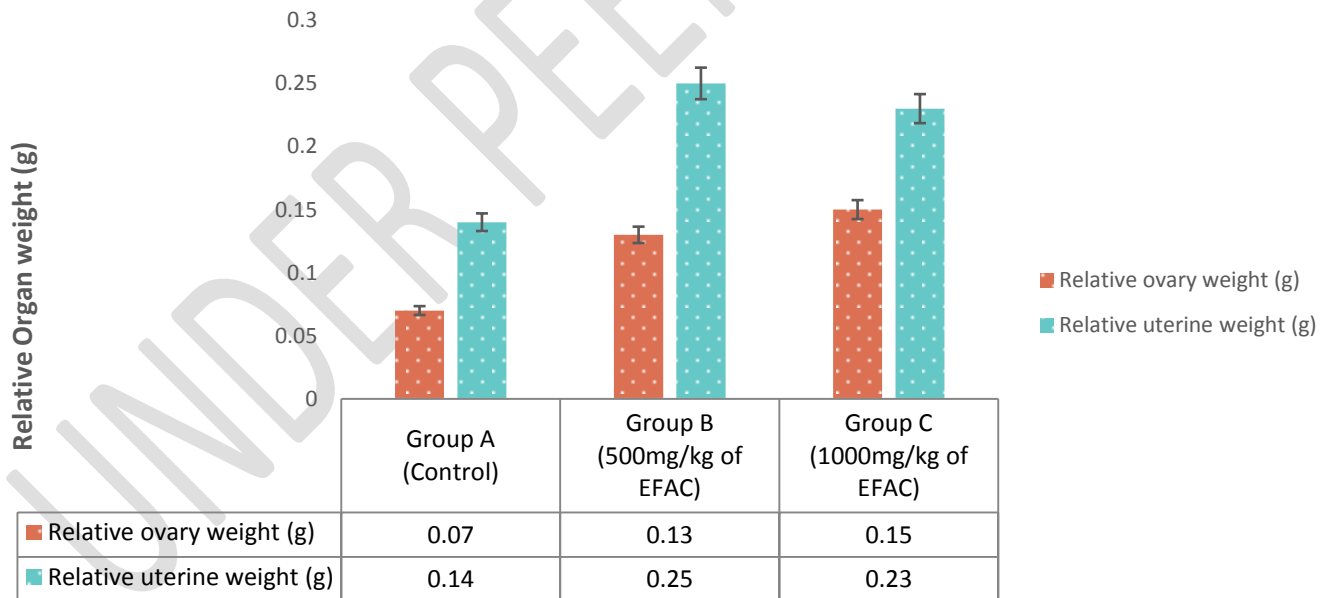
### **Results**

When the initial weight was compared to the final weight, Fig. 1 revealed a substantial ( $p < 0.05$ ) rise in groups B and C. Fig. 2 shows that in groups B and C, ovarian and uterine weights increased significantly ( $p < 0.05$ ) when compared to group A. In comparison to group A, LH levels in groups B and C increased significantly ( $p < 0.05$ ). In comparison to group A, FSH increased insignificantly ( $p < 0.05$ ) in groups B and C. Progesterone levels in groups B and C were significantly lower ( $p < 0.05$ ) than in group A.

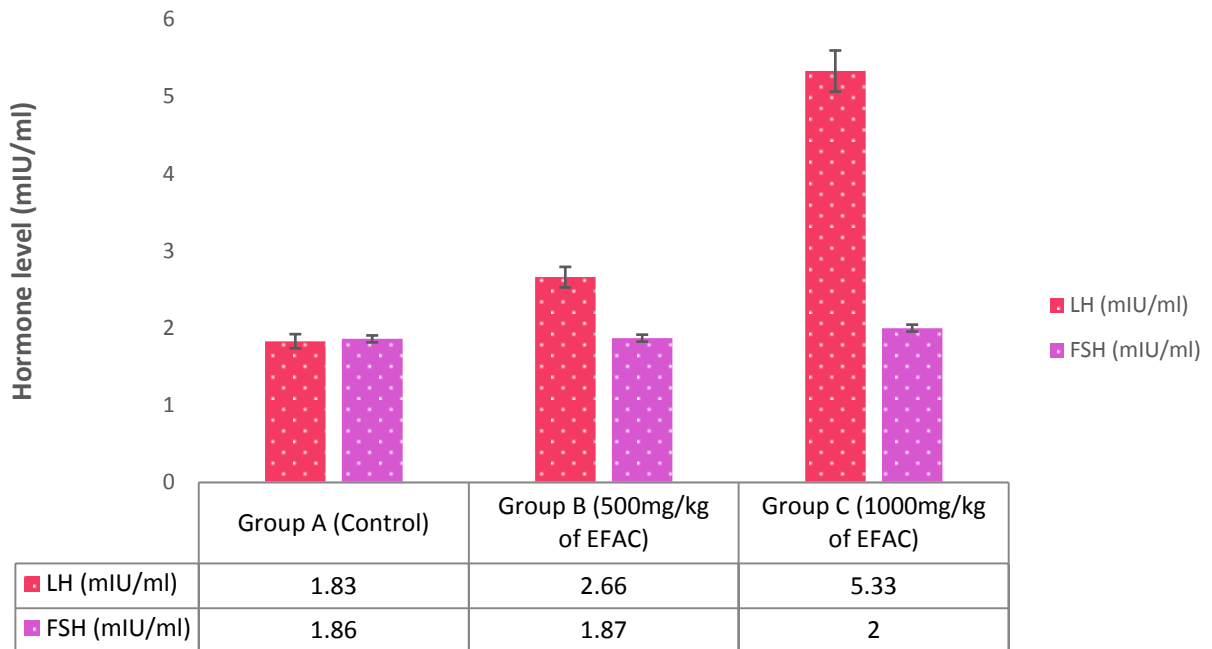
**Figure 1: Values of extract on body weight of study animals.**



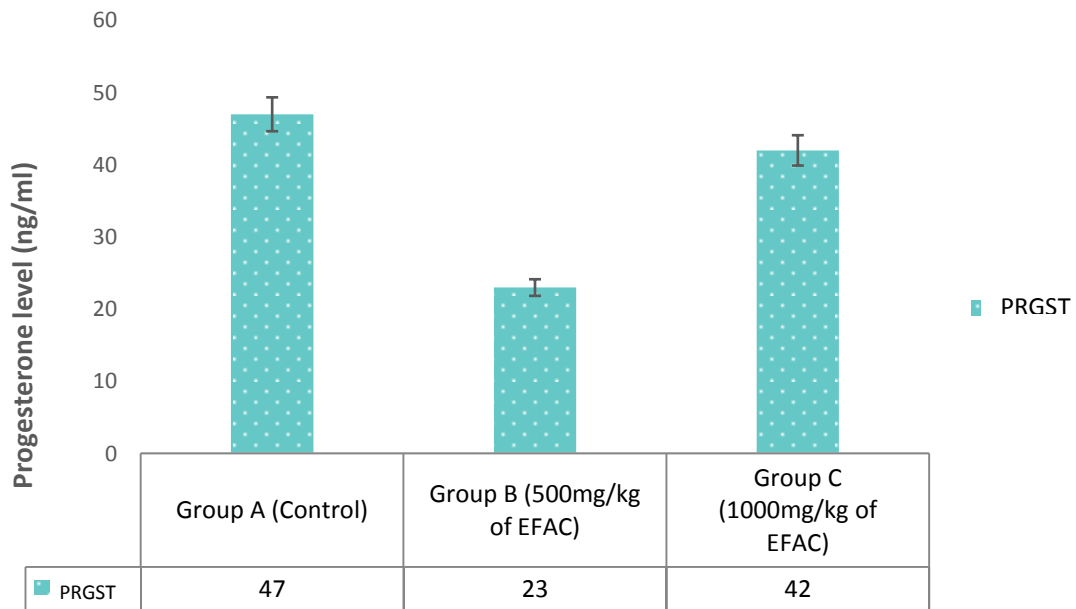
**Figure 2: Values of extract on ovary and uterine weight of study animals.**



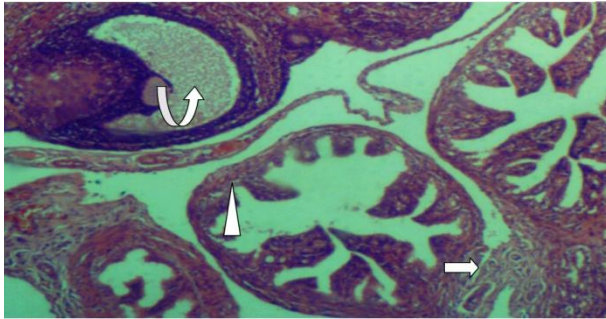
**Figure 3: Values of extract on LH and FSH of study animals.**



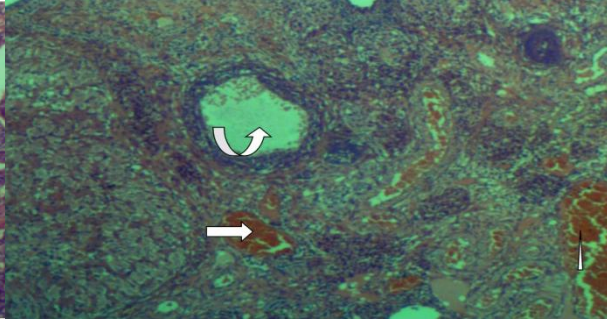
**Figure 4: Values of extract on Progesterone of study animals.**



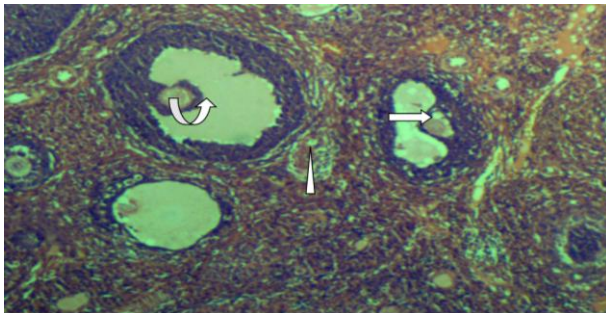
## Ovary and Uterus Histology of Extract



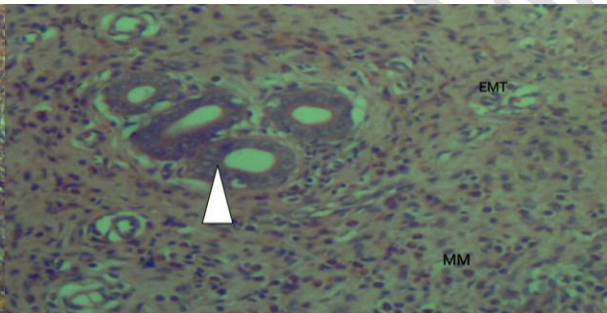
**Plate A (H & E) x 100**



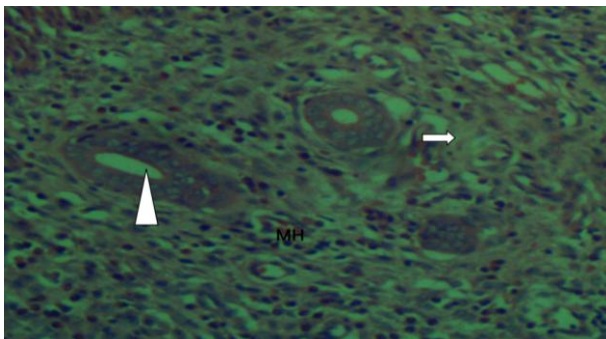
**Plate B (H & E) x 100**



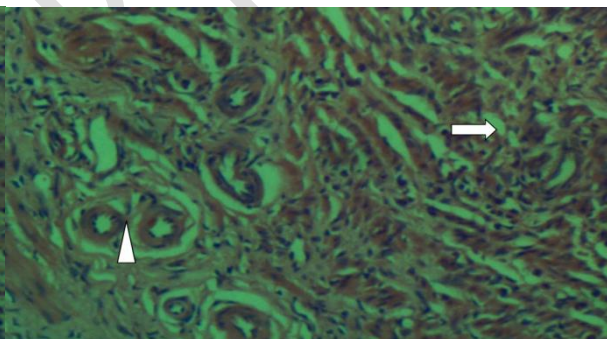
**Plate C (H & E) x 100**



**Plate D (H & E) x 400**



**Plate E (H & E) x 400**



**Plate F (H & E) x 400**

Plates A-C (Ovary) and Plates D-F (Uterus) show the results of the histological investigation of the rat's ovaries and uterus. Plate A depicts a photomicrograph of ovarian tissue with normal morphology. Normal histology can be seen in the follicular cells (arrowhead), primordial follicles (arrow), and oocytes (curved arrow). Plate B shows minor bleeding in follicular cells (arrowhead), but primordial follicles (arrow) and oocytes (curved arrow) have normal histology. Plate C has normal histology with follicular cells (arrowhead), primordial follicles (arrow), and oocytes (curved arrow). The photomicrograph of the uterus in Plate D demonstrates normal myometrium (MM) and endometrial histology (EMT). The stroma and endometrial glands (arrowhead) are both normal, with no signs of damage. In Plate E, the myometrium and endometrium of the uterus have normal histology. With minor hemorrhage, the endometrial glands (arrowhead) and stromal (arrow) are normal. Plate F shows normal endometrial glands (arrow head) and stroma (arrow), with minimal stroma cell vacuolation.

## Discussion

In both animals and humans, female hormones (FSH, LH, and progesterone) are crucial regulators of species continuity (Charles *et al.*, 2021, Marques 2018). Female infertility has also been linked to shortages in these hormones, which has been a source of concern. Averrhoacarambola is a well-known medicinal plant with significant antioxidant properties that is frequently used as a reproductive plant by herbalists without scientific support (Luan 2021).

The effect of ethanolic fruit extract of Averrhoacarambola on FSH, LH, and progesterone in female rats is investigated in this study. The treatment groups gained weight significantly, which could be due to the elevated cellulose activity that regulates energy homeostasis. Furthermore, the control of metabolism is influenced by the energy regulation of the hypothalamic satiety regions, which regulate food and fluid intake (Lund *et al.*, 2020). Zhang *et al.*, (2020) observed a considerable weight gain in diabetic mice after receiving DMDD from Averrhoacarambola roots, which is consistent with our findings. Li *et al.*, (2016) found that DMDD from Averrhoacarambola roots resulted in considerable weight growth, which is similar to our findings. In addition, Singh *et al.*, (2014) found no significant weight gain in a hepatocellular carcinoma model after administration of Averrhoacarambola, which contradicts our result. Furthermore, Ramadan *et al.*, (2020) observed a considerable rise in weight after consuming Averrhoacarambola, indicating high fiber content, which is consistent with this study. Aba and Amadi (2020) reported considerable weight reduction after taking Averrhoacarambola, which contradicts the findings of this study.

In comparison to the control group, the fruit extract of Averrhoacarambola caused a considerable rise in ovarian and uterine weight in groups B and C. The presence of saponin, which has a favorable effect on the organs, could explain the physiology of the increase; nevertheless, the particular mechanism of action is unknown. Aba and Amadi's (2020) research contradicted this study's findings, indicating non-significant weight increase organs in rats. Singh *et al.*, (2014) reported a substantial increase in organ weight after administration of Averrhoacarambola, which is consistent with this investigation.

Luteinizing hormone is a crucial hormone in the female reproductive system that regulates ovarian function. In comparison to group A, the study found a significant ( $p > 0.05$ ) increase in LH levels in groups B and C. The phytoconstituents in the extract may be the mechanism of action for the rise. In addition, FSH increased insignificantly in groups B and C compared to group A, with the cause

unknown. In comparison to group A, the Progesterone result showed a significant drop in groups B and C.

The results of the histological examination of the rat's ovaries and uterus are shown in Plates A-C (Ovary) and Plates D-F (Uterus). The extract produced mild hemorrhage of follicular cells at a low dose (500 mg/kg), while primordial follicles and oocytes were consistent with the normal histology of the ovary of the animals in Group B. The high dose (1000 mg/kg) is inconsistent with the normal histology. Hence, *A. Carambola* can affect a woman's ovary and uterus, which are important reproductive organs.

Oral treatment of the extract at a low dose (500 mg/kg) resulted in modest bleeding of the endometrial glands and stroma of the uterus in the animals in Group E, whereas a high dose (1000 mg/kg) resulted in mild vacuolation of the uterus stroma cells in Group E. When compared to the control (Group D), both doses of the extract have a negative effect on the stroma cells of the uterus of female Albino wistar rats

In conclusion, *Averrhoacarambola* fruit extract may have a beneficial effect on body weight, relative ovary and uterine weight, and FSH and LH activities.

## References

1. Wei, X. J., Xu, X. H., Chen, Z. F., Liang, T., Wen, Q. W. and Qin, N. Protective Effects of 2-Dodecyl-6-Methoxycyclohexa-2,5-Diene-1,4-Dione Isolated from *Averrhoacarambola* L. (Oxalidaceae) Roots on Neuron Apoptosis and Memory Deficits in Alzheimer's Disease. *Cell. Physiol. Biochem.* 2018; 49 (3): 1064–1073.
2. Das Gupta, P., Chakraborty, P. and Bala, N. 'Averrhoa carambola: An updated review', *Int. J. Pharma Res. Rev.*, 2013; 2(7), 54–63.
3. Khoo . Phytochemicals and Medicinal Properties of Indigenous Tropical Fruits with Potential for Commercial Development', *Evidence-based complementary and alternative medicine* 2016: 7591
4. Wang. Stem Cells as a Resource for Treatment of Infertility-related Diseases', *Current Molecular Medicine.* 2019; 19(8), 519–546.
5. Lakmal. Nutritional and medicinal properties of Star fruit (*Averrhoa carambola*): A review', *Food Science & Nutrition.* Wiley-Blackwell, 2021; 9(3), 1810.
6. Qin, L. Protective Effect of Benzoquinone Isolated from the Roots of *Averrhoa carambola* L. on Streptozotocin-Induced Diabetic Mice by Inhibiting the TLR4/NF- $\kappa$ B Signaling Pathway', *Diabetes, metabolic syndrome and obesity : targets and therapy.* *Diabetes Metab Syndr Obes.* 2020;13(06), 2129–2138.
7. Aladaileh, S. H. Antihyperlipidemic and Antioxidant Effects of *Averrhoa Carambola* Extract in High-Fat Diet-Fed Rats', *Biomedicines.* *Biomedicines.* 2019; 7(3), 72.

8. Leelarungrayub. A preliminary study on the effects of star fruit consumption on antioxidant and lipid status in elderly Thai individuals', *Clinical interventions in aging. Clin Interv Aging*. 2016; 11(07), 1183–1192.
9. Cabrini, D. A. Analysis of the Potential Topical Anti-Inflammatory Activity of *Averrhoa carambola* L. in Mice', *Evidence-based complementary and alternative medicine. Evid Based Complement Alternat Med*, 2011; 10.1093
10. Vastra, A. R. The Potential of Sweet Starfruit as a Gastroprotector of Gaster Damage Due to Free Radicals', *Indonesian Journal of Global Health Research. Global Health Science Group*. 2020; 2(1),1–6.
11. Kulal, N. G. Fruits of *Averrhoa carambola* linn. protects Wistar rats against indomethacin and pylorus ligation-induced ulcers: *Thai Journal of Pharmaceutical Sciences (TJPS)*. 2021; (2), 240.
12. Muthu, N. Nutritional, Medicinal and Toxicological Attributes of Star-Fruits (*Averrhoa carambola* L.): A Review', *Bioinformation. Bioinformation*. 2016; 420–424.
13. Silva, K. B. Phytochemical characterization, antioxidant potential and antimicrobial activity of *Averrhoa carambola* L. (Oxalidaceae) against multiresistant pathogens', *Brazilian journal of biology*. 2021; 81(3), 509–515.
14. Al-Attar, A. M. and Abu Zeid, I. M. Effect of tea (*camellia sinensis*) and olive (*olea europaea* L.) leaves extracts on male mice exposed to diazinon', *BioMed Research International. Biomed Res Int*, 2013; 10-1155
15. Raji Y., Akinola, A., Oyeyipo I. P and Femi-Akinlosotu, O. Reproductive activities of female albino rats treated with quassin, a bioactive triterpenoid from stem bark extract of *Quassiaamara*. *Nig. J. Physiol. Science*, 25 (2010) :95 – 102.
16. Marques, P. Physiology of GNRH and Gonadotropin Secretion', *Endotext. MDText.com, Inc.*, 2018; 6(3), 15–25.
17. Luan, F. Traditional Uses, Phytochemical Constituents and Pharmacological Properties of *Averrhoa carambola* L: A Review', *Frontiers in Pharmacology. Frontiers Media S.A.* 2021; 12, 1814–1822.
18. Lund, J., Gerhart-Hines, Z. and Clemmensen, C. Role of Energy Excretion in Human Body Weight Regulation', *Trends in Endocrinology & Metabolism. Elsevier Current Trends*. 2020; 31(10), 705–708.
19. Zhang, H. 2-Dodecyl-6-methoxycyclohexa-2,5-diene-1,4-dione, isolated from the root of *Averrhoa carambola* L., protects against diabetic kidney disease by inhibiting TLR4/TGF $\beta$  signaling pathway', *International immunopharmacology. Int Immunopharmacol*. 2020; 10.1016.
20. Li, J. Protective Effects of 2-Dodecyl-6-Methoxycyclohexa-2,5 -Diene-1,4-Dione Isolated from *Averrhoa Carambola* L. (Oxalidaceae) Roots on High-Fat Diet-Induced Obesity and Insulin Resistance in Mice', *Cellular physiology and biochemistry: international journal of experimental cellular physiology, biochemistry, and pharmacology. Cell Physiol Biochem*. 2016; 40(5). 993–1004.
21. Singh, R., Sharma, J. and Goyal, P. K. Prophylactic role of *Averrhoa carambola* (Star Fruit) extract against chemically induced hepatocellular carcinoma in Swiss albino mice', *Advances in Pharmacological Sciences. Hindawi Publishing Corporation*, 2014; 1–9.
22. Ramadan, N. S. Nutrient and Sensory Metabolites Profiling of *Averrhoa Carambola* L. (Starfruit) in the Context of Its Origin and Ripening Stage by GC/MS and Chemometric Analysis', *Molecules* 2020; 25, 2423

23. Aba, P. E. and Amadi, A. U. Evaluation of the possible hepatotoxic and nephrotoxic potentials of the Averrhoa carambola juice extract in female albino rats', *Journal of Basic and Clinical Physiology and Pharmacology*. 2020; 31(1), 1–10.
24. Charles CN(PhD), Weleh, II (PhD) and Green, IK (MBBS). *FleuryaAestuans* Promotes Oogenesis And Ovulatory Functions In Wistar Rats By Shortening The Estrus Cycle. *World Journal Of Pharmaceutical Research*. 2021, 10(13), 1951-1966.

UNDER PEER REVIEW