

Giant Bartholin Cyst in a Sexually Active Widow: Management and Aspects of Neglected Sexuality

Abstract

The Bartholin glands are paired glands that are typically non-palpable whose function is to secrete fluid onto the mucosal surface of the labia. Disorders with the Bartholin's glands include cysts and abscesses. Bartholin's cyst rarely grows so large as to be confused with the fetal head at crowning. What we are familiar with is either the gynaecological emergency of Bartholin's abscess or the day case cyst of the gland which is considered a registrar's operation list, both of which are best treated by marsupialization.

We came across this unusual presentation of giant Bartholin cyst in a private specialist clinic setting. Our intention is not to create an avenue for lighter mood, but to add to numerous issues with inimical nature of diseases, poverty and ignorance (triad of health problems)peculiar to Sub-Saharan Africa.

The widow in discussion who is burdened with care of her family alone, ought to have been partnered with holistically. She had a sexual partner. The sexual partner, the nuclear family members and the society has their roles to play so that she won't be viewed as a neglected widow. Clinicians should be aware of this entity, although it can be rare

Keywords: Giant Bartholin Cyst, Marsupialisation, Neglected Widow, Sub-Saharan Africa, Triad of Health Problems.

Introduction:

A Bartholin cyst (or vulvar cyst) is a type of vaginal cyst that forms on either side of the labia (vaginal lips) near the opening of the vagina. It's named after the Bartholin glands, which are two small glands that produce the fluid (mucus) that help lubricate the vagina. A Bartholin cyst occurs when a blockage happens at the openings of one of these glands, causing the mucus to build up and form a lump [9,10]. It typically only occurs on one of the two Bartholin glands. Some Bartholin cysts are small and don't cause any pain. Bartholin cysts will occur in about 2% of all women at some time in their life. They are more common in women of reproductive age. The chance of developing a Bartholin cyst decreases after menopause.

Case presentation

A forty-six-year-old widow who was a petty trader presented with a history of perineal mass of five years duration. She was a para five with four living children and Igbo ethnicity. The mass had started as a small bulge at the introitus. It was increasing in size, though painless, two years before she was a widow. The bulge progressed to a mass comparable to the size of the head of a neonate. There was no discharge, no dyspareunia nor was dysuria associated with the mass. Sexual intercourse was with her husband only, for the eleven years of their marriage. She maintained a steady sexual partner as a widow with a family man, who was an artisan just like her late husband. They both enjoyed their sexual activities as she usually displaces the mass upward during sexual intercourse (Plate 2).

She had sought medical care first by drawing the husband's attention and later, the sexual partner and finally her sister, having decided to go outside intimacies to seek for help. The sister brought her to the hospital for the necessary treatment. She had prolonged labour in her 4th pregnancy which ended up as an emergency caesarean section. She went for unsafe maternal care in her 5th pregnancy and recorded failed vaginal birth after caesarean (VBAC) and ended up with a repeat section.

She catered for her family alone, and her educational status was not beyond the primary school level.

Physical Examination revealed an unhappy-looking lady, apparently older than her stated age. She was not malnourished and not pale.

There was a midline sub-umbilical scar that had healed by 2° intention. There was no abdominal mass palpable.

Vaginal Examination showed a mass attached to the distal mesial aspect of the labia minora right side of the vulva. The stalk supporting this tense cystic mass was broad. The mass was the size of the head of a newborn (Plate 3).

Visible prominent vessels reminiscent of usually rich vulval vascularity were seen (Plate 4). Left side of the vulva has no lesion. There were no palpable groin lymph nodes. Speculum examination showed normal vaginal walls and healthy looking cervix. Smear was taken for cervical cytology. Bimanual vaginal examination revealed six weeks uterine size, and free adnexa without excitation tenderness.

A suspicion of rare giant Bartholin cyst was entertained. Urinalysis result was normal with no proteinuria. Packed cell volume was 37%. The patient was counseled on the diagnosis and consent for both surgical treatment and Case publication was obtained. The amputation of a giant Bartholin Cyst on a vulval-attached stalk was carried out by a gynaecologist.

Histology report confirmed a Bartholin cyst with no evidence of malignancy. Cytology of Pap smear was negative for malignant cells.

Procedure

Amputation of Bartholin Cyst Connected to Right Side Vulval Wall via a Highly Vasculature Stalk :

This was a day-case surgery. Spinal anaesthesia was administered and monitored by an anaesthesiologist. Patient was placed in lithotomy position, cleaned with cetrimide in spirit solution, and draped. An encircling subcutaneous surgical incision was made at the vulval attachment, being mindful of the disproportionately bleeding vessels of the vulva.

The exposed connective tissue stalk was double clamped with Kocker's forceps in two divided halves and equally tied in a piecemeal fashion. Ligation was with Vicryl-1- suture. Superficial bleeders commonly encountered in vulval surgeries were ligated with vicryl-2/0-sutures. Skin closure was continuous in fashion. Marsupialization was not necessary because the Bartholin gland had been displaced outside the connective tissue layer of pudendum, leading to its attachment on a stalk and the resulting excision. The left gland maintains the coital lubricant functions. Blood loss was 350mls, remarkably more than expected. Sterile gauze pack was put in position and the patient was assisted by the nurses to wear a tight pant to hold it in place.

The patient was wheeled to the recovery room for post-up management. She was reviewed and discharged home six hours later on the following drugs: Paracetamol tablets 1g oral, bd for 7 days;

Slow release, Piroxicam tablets 20mg once oral daily for 5 days; Ciprofloxacin tablets 500mg bd oral for 7 days; Fesolate (200mg) and folic acid (5mg) oral tablets one each daily for 14 days.

She was to be seen at the outpatient clinic the following day, on 7th day and one month thereafter. The follow-up was uneventful as the patient had returned to her daily activities within one month.

DISCUSSION

The above describes the management of a rare case of giant Bartholin Cyst in a sexually active widow. Neglected care among widows demonstrated by delay in seeking health care and accessing unsafe maternal care was also discussed.

Bartholin gland is a pair of peanut sized, racemic glands on either side of the distal medial aspect of the labia minora and introitus.¹ The exocrine secretion of this gland, along with cervical secretions functions as a lubricant during intercourse.

The duct sometimes gets blocked to form a Bartholin cyst or abscess². A Bartholin cyst occurs when a blockage happens at the openings of one of these glands, causing the mucus to build up and form a lump.³ Procedures like McIndoe vaginoplasty may lead to the blocking of the duct of Bartholin gland and resultant cyst.⁴ Bartholin abscess, as the name implies, is infected and inflamed, and as a result, presents with pain, redness, and differential warmth in addition to swelling. Rare carcinoma of the gland may also present with pain.^{5,6} This patient presented with a painless swelling of the gland, though attenuated in size and attachment due to delay in presentation. Bartholin's abscess may be commoner in adolescents, because of spontaneous sexual patterns, while cyst may be more in later reproductive life. Physical examination (inspection and palpation) will characterize the lesion further and with history of presenting complaint make a diagnosis. Diagnosis is confirmed by anatomic pathology on histology.⁷ The commonest treatment for both the cyst and abscess is marsupialization, with Word's catheter insertion, incision and drainage, and excision as the less favoured option in selected cases^{8,9,10}. Marsupialisation was not practicable in this case because both the gland and the duct were exteriorised and not related to the introitus.

Haemoglobin level should be ascertained and blood even made available if it is low, as vulvar surgeries bleed relatively more due to thin-walled rich arterial supply and anastomosis of the vulva¹¹.

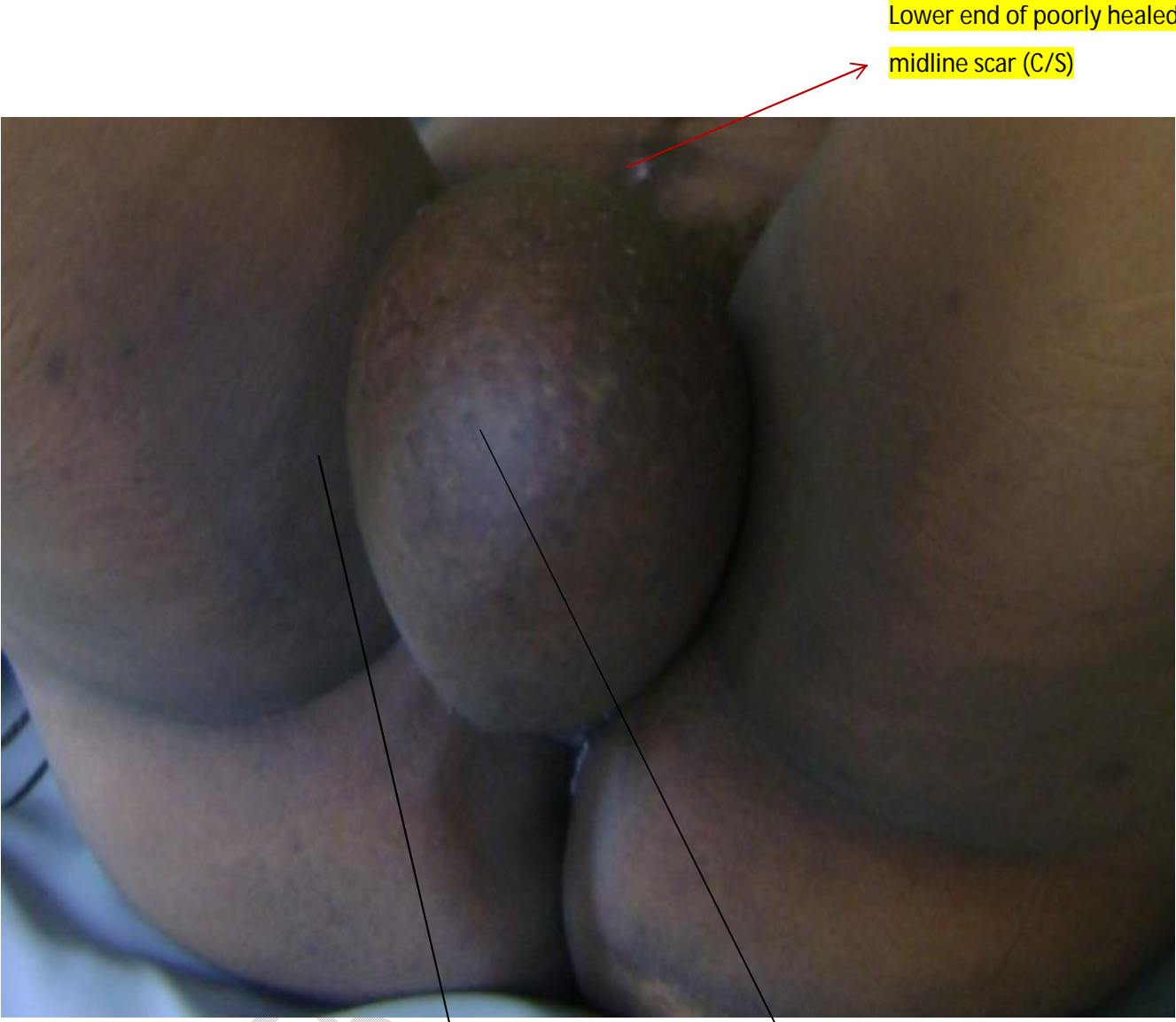
The case in discussion, presented late. The anatomy had been altered. It was like a giant cyst suspended on a broad stalk. The late presentation may have been due to poverty, and/or ignorance, and these two, when added to the nature of disease itself, form the health care challenges peculiar in the sub-sahara region usually expressed as: "The triad of health care in the Tropics".¹² Again, the patient's problem can be viewed from the neglected case perspective, and neglect here can be at an individual level (self-neglect), family level (intimate partners), and

finally community level. The referenced apparent self-neglect was earlier shown in her fifth pregnancy during which she accessed care in a maternity home even with a previous caesarean section. The community, including the government, should champion and support free maternal services and widows' scheme. I believe these were not in place hence the woman went for unsafe maternal services and ended up with features of neglected labour. The husband and later her sexual partner needed to have lived up to expectations as they ought to have offered adequate support with regards to seeking medical care.

This brings to the fore the need for early presentation of medical cases to the clinics and hospitals. There is also a need for a strengthening of the health systems to provide social services for the populace.

Conclusion

This case study underscores the need for early presentation as well as the need by the government to put in place measures that can help individuals especially the vulnerable to access medical care when needed. There is also need for clinicians to watch out for uncommon presentations in practice and be ready to alter known standard interventions for such conditions.



Lower end of poorly healed

midline scar (C/S)

Plate 1: Giant Ba

Hyperpigmented and Excoriated crura

Giant Bartholin Cyst

UNIVERSITY

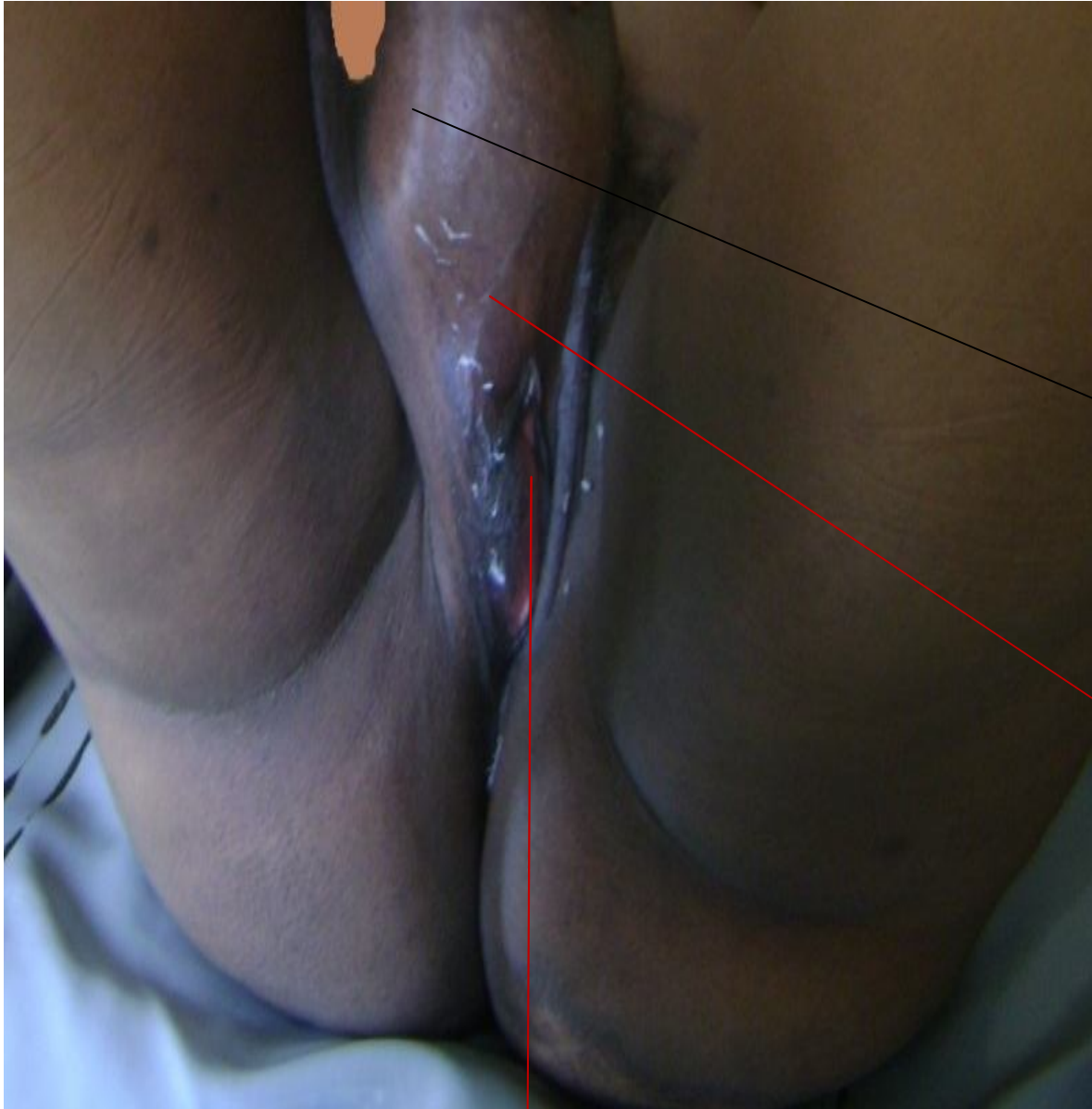

Plate 2: Showing Stalk supporting the mass

Introitus

**Prominent
blood vessels
of the stalk**

Declaration of patient consent

The authors certify that appropriate patient consent was obtained. The patient gave her consent for her images and other clinical information to be reported in the journal. The patient understands that her name and initials will not be published and due efforts will be made to conceal her identity.

Financial support and sponsorship

Nil.

Conflicts of interest

There are no conflicts of interest.

REFERENCES

1. Quaresma C, Sparzak PB. *Anatomy, Abdomen and Pelvis, Bartholin Gland.*; 2020. Available from <https://www.ncbi.nlm.nih.gov/books/NBK557803/> [Cited May 2, 2023.]
2. Omole F, Kelsey RC, Phillips K, Cunningham K. Bartholin duct cyst and gland abscess: Office management. *Am Fam Physician.* 2019;99(12):760-766.
3. Illingworth BJ, Stocking K, Showell M, Kirk E, Duffy JM. Evaluation of treatments for Bartholin's cyst or abscess: a systematic review. *BJOG: An International Journal of Obstetrics & Gynaecology.* 2020 May;127(6):671-8.
4. Klingele CJ, Gebhart JB, Croak AJ, DiMarco CS, Lesnick TG, Lee RA. McIndoe procedure for vaginal agenesis: long-term outcome and effect on quality of life. *American Journal of obstetrics and gynecology.* 2003 Dec 1;189(6):1569-72.
5. Akbarzadeh-Jahromi M, Aslani FS, Omidifar N, Amooee S. Adenoid cystic carcinoma of Bartholin's gland clinically mimics endometriosis, A case report. *Iran J Med Sci.* 2014;39(6):580-583.
6. Goh SP, McCully B, Wagner MK. A case of adenoid cystic carcinoma mimicking a Bartholin cyst and literature review. *Case Reports in Obstetrics and Gynecology.* 2018 Mar 26;2018.
7. Lee MY, Dalpiaz A, Schwamb R, Miao Y, Waltzer W, Khan A. Clinical pathology of Bartholin's glands: A review of the literature. *Curr Urol.* 2014;8(1):22-25.

doi:10.1159/000365683

8. Reif P, Ulrich D, Bjelic-Radisic V, Häusler M, Schnedl-Lamprecht E, Tamussino K. Management of Bartholin's cyst and abscess using the Word catheter: Implementation, recurrence rates and costs. *Eur J Obstet Gynecol Reprod Biol.* 2015;190:81-84. doi:10.1016/j.ejogrb.2015.04.008
9. Karabük E, Aygün EG. Marsupialization versus Word catheter in the treatment of Bartholin cyst or abscess: retrospective cohort study. *J Turkish Ger Gynecol Assoc.* 2022;23(2):71-74. doi:10.4274/jtggg.galenos.2022.2022-1-6
10. Omole F, Simmons BJ, Hacker Y. Management of Bartholin's duct cyst and gland abscess. *American family physician.* 2003 Jul 1;68(1):135-40.
11. Standring, S. *Gray's Anatomy, The Anatomical Basis of Clinical Practice.* 42nd Edition. Elsevier, Amsterdam. 2020: p.139
12. Lucas AO, Gilles HM. *Short Textbook of Public Health Medicine for the Tropics.* 4th ed. Book power. London. 2003: p. 8.