

## Case study

## **Appendicitis Causing Small Bowel Strangulation A Rare Presentation– Three Case Reports**

**Abstract**

A strangulation of the intestine caused by appendicitis is extremely rare with few cases reported in the literature. Strangulation can be due to the appendix wrapping or appendiceal tourniquet around the base of a bowel loop, or when inflamed appendix tip adheres across the loop of small bowel to the mesentery or long appendix tip attached to posterior wall forming a close loop, obstruction may lead to strangulation and gangrene of the bowel.

The diagnosis of such a condition is possible only on the operation table, after midline explorative laparotomy. There are only 10 cases reported in the literature. Mechanical small bowel obstruction and strangulation is a very rare and dangerous complication of a very common disease of appendicitis required emergency laparotomy, to reduce the high mortality. Every emergency surgeon needs to be aware of such possibility.

Herein we are reporting three cases of mechanical small bowel obstruction caused by appendicitis. Two patient were presented with as a strangulation of the small bowel, due to the long appendix causing constriction around a loop of the small bowel, acts as an appendiceal tourniquet or band syndrome, is an extremely rare surgical entity and third case presented with mechanical small bowel obstruction having an appendicular inflamed tip attached to the mesentery, producing constriction or compression of its ileum, producing the obstruction. In all cases we performed midline laparotomy with appendectomy and adhesiolysis

**Key words**

Appendicitis, Appendiceal tourniquet, Intestinal strangulation, Mechanical bowel obstruction,

**Introduction**

Appendicitis causing mechanical intestinal obstruction is uncommon intestinal obstruction caused by appendicitis is extremely rare and few cases reported in the literature. The association between mechanical intestinal obstruction and acute appendicitis with first reported by Hotchkiss in 1901.

There are some of the mechanisms causing mechanical obstruction and strangulation of small bowel. [1,2,3]

1. The tip of inflamed appendix fixed transversally across the ileum to posterior peritoneum causing compression of the lumen of the ileum.
2. Tip of the long inflamed appendix get an adherent in the pelvis, causing closed loop obstruction, may lead to strangulation and gangrene of the bowel.
3. Appendicitis causing intestinal obstruction by forming a knot around a small bowel is uncommon or appendiceal tourniquet forming a close loop and herniation of small bowel strangulation. [4,5,6,7]

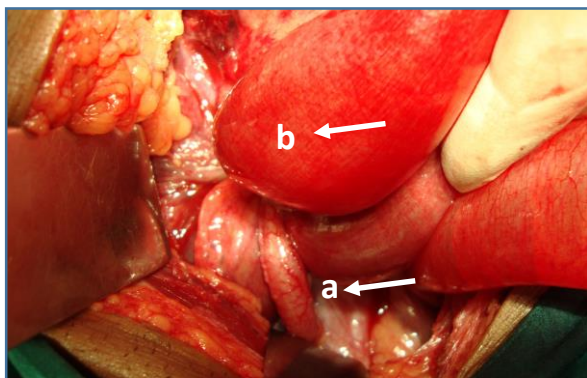
The diagnosis is always made of the time of laparotomy. The treatment varies from appendectomy to intestinal resection or even right hemicolectomy.

**Case reports**

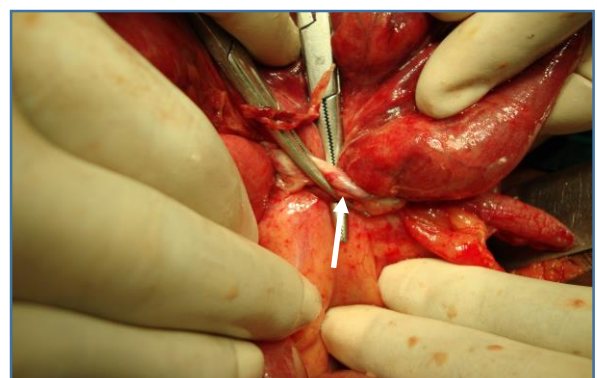
**Case 1-** A 70 years old female patient was admitted in our centre on 18/03/2010 with complains of severe abdominal pain distension of abdomen, vomiting and constipation of 4 days. On her physical examination abdomen was distended, there was tenderness all over the abdomen. She was started supporting therapy with intravenous fluid antibiotics and insertion of nasogastric tube and urinary catheter. Her laboratory investigation shows raised total leukocyte count 21,000 cmm. Her renal function tests were normal. Her plain abdominal radiography showed multiple air-fluid levels

suggestive of small bowel obstruction. Ultrasonography abdomen showed a dilation of the small bowel loops and “to and fro” peristalsis of the bowel contents.

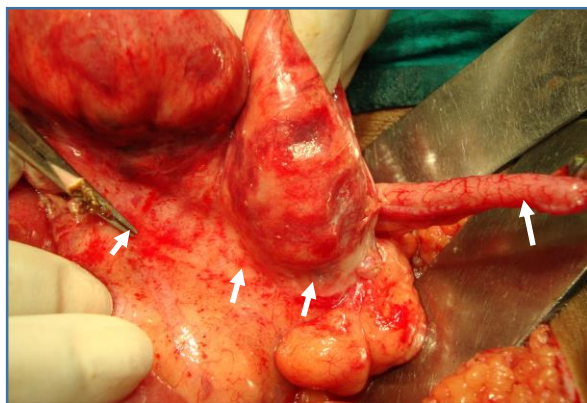
Emergency midline laparotomy was done, there was 700 cc Serosanguineous fluid in the abdominal. The whole small bowel was dilation and there was a strangulated small bowel loop by a 10-12 cm long appendix running from caecal base, which was looping around the distal small bowel segment, acting as appendiceal tourniquet. The band of appendix was released from its attachment to the ileum and appendectomy was done. To our surprise the appendix was 10-12 cm long causing strangulation of small bowel. The bowel loops were assessed and found to be congested and ischemic, gained viability after 5 minutes’ application of warm saline packs, with 100% oxygenation given by our anaesthetist and tested the viability of strangulated small bowel loops. Simple plain sterile plastic drain was inserted and abdomen was closed in layers. Histopathological report revealed acute appendicitis. Post-operative recovery was uneventful and patient discharge home on 8<sup>th</sup> post-operative day. (Case 1 Figure 1,2,3,4)



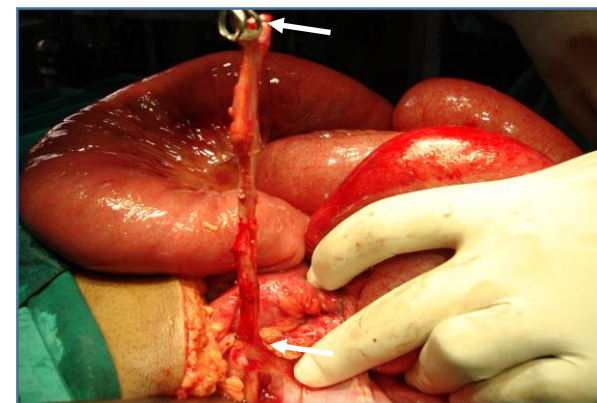
Case 1. Fig-1-a Intra operative photographs  
a-Acute Inflamed appendix. b- small bowel obstruction



Case 1 Fig-2 intra operative photographs showing  
long appendiceal tourniquet



Case 1- Fig-3 intra operative photographs showing  
marking of strangulation (white arrows)

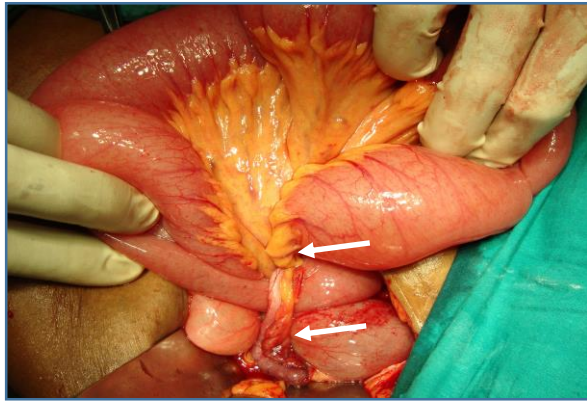


Case 1- Fig-4 intra operative photographs showing  
Long appendix measuring 12cm in length

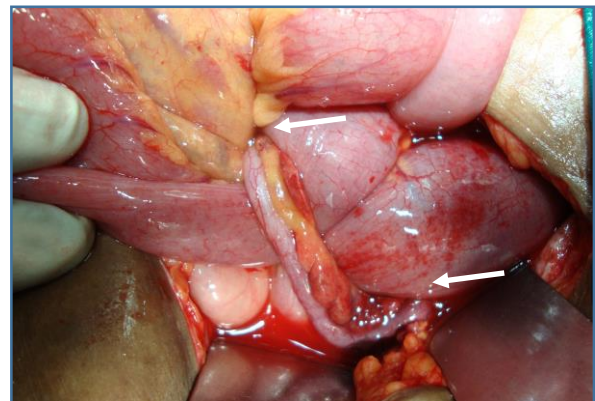
**Case 2** - A 65-year old male patient was admitted in our centre on 03/02/2010 with complains of severe pain in abdomen, distension of abdomen, vomiting and constipation of 3 days old. On physical examination abdomen was distended, tenderness of right lower quadrant of abdomen. His abdominal x-ray showed multiple air & fluid levels, revealed small bowel obstruction. Ultrasonography of abdomen showed dilated small bowel with “to and fro” peristalsis in the right iliac fossa, which are features of small bowel obstruction. Laboratory investigation showed total leukocyte count 17,500 cmm, kidney function test was normal. Then patient was scheduled for emergency laparotomy.

Intraoperatively there was 500 cc haemorrhagic fluid in the abdominal cavity, with dilated small bowel loops proximal to obstruction. There was a 8-10 cm long appendix tip was fixed in the pelvis

on right side, forming a close loop through which small herniation and strangulation. Strangulated loops were congested and oedematous due to appendiceal tourniquet effect. So appendectomy was performed after mobilization of appendicular tip from the pelvis brim and strangulated bowel changed in to normal colour. Histopathological report showed acute appendicitis. Post-operative recovery uneventful and patient discharge home on 8<sup>th</sup> post-operative day. (Case 2 Figure 1,2)



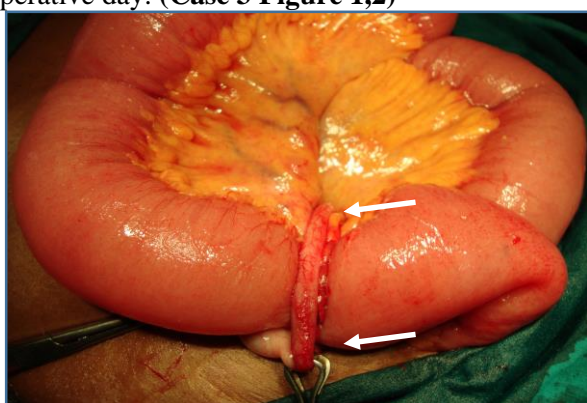
Case 2- Fig-1 intra operative photographs showing strangulated loop of small bowel.



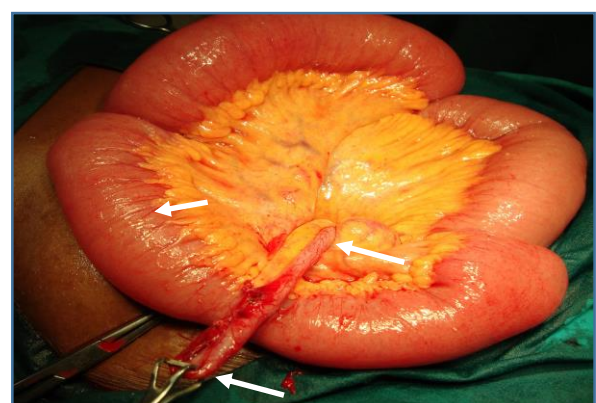
Case 2- Fig-2 Photographs showing strangulated loop of small bowel with long appendix(10cm).

**Case 3-** A 20 years' young boy was admitted to our centre on 13/03/2010 with complains of severe abdomen, distension of abdomen, vomiting and fever since 2 days. An ultrasonography of abdomen was done, which showed acute inflamed appendix and dilated small bowel loops. Plain x-ray abdomen showed dilated ileal loops with multiple air-fluids levels. Laboratory investigation showed increased leukocytes count 18,700 cmm and kidney function tests were normal.

Midline explorative laparotomy performed showed acutely dilated small bowel loops with 5-6 cm long inflamed appendix, which was fiery red in colour. An appendicular tip attached to the mesentery surrounding an ileal loop, producing compression of its lumen and the appendicular tip attached to the intestinal serosa, producing the obstruction by direct compression or torsion of the loop. Inflamed tip of the appendix gently detached from the mesentery of small bowel and appendectomy was performed. There was no free fluid in the abdomen, small bowel segment was healthy. Histopathology report was acute appendicitis. Post-operative recovery was good and discharge home on 7<sup>th</sup> post-operative day. (Case 3 Figure 1,2)



Case 3- Fig-1 Intra operative photograph Showing strangulation of small bowel due to encircling of appendix, tip of the inflamed appendix fixed to the mesentery



Case 3- Fig-2 Showing strangulation of small bowel. Small bowel is dilated

## Discussion

Appendicitis causing intestinal obstruction was described first in 1901 by Lucius Holchikiss. The first case of small bowel strangulation caused by appendix was described by Naumon in 1963. Intestinal obstruction caused by appendicitis could be classified in 2009 by Bhandari et.al reviewed and proposed four categories of obstruction.

1. Adynamic
2. Mechanical
- 3 Strangulation of intestinal
4. Mesenteric ischemia causing intestinal obstruction.

Adynamic obstruction is resulting from appendicular perforations and peritonitis leading to paralytic ileus and more common, seen in 1-5% of appendicitis.

Mechanical obstruction caused by the appendicitis. The various ways in which appendicitis could mechanically because intestinal obstruction includes.

(A) Appendix which lay across loops of bowel and get bound down to the posterior peritoneum of the tip and base by inflammatory adhesions.

(B) The appendix attaching to the wall of the small bowel and form a fulcrum for torsion or kink lead to intestinal obstruction.

(C) The tip of the inflamed appendix could, get attached to the posterior peritoneum and forming a loop, though which bowel could herniate and get strangulation.

(D) Long inflamed appendix forming a appendicular knot or tourniquet or appendicular tie syndrome is and extremely rare surgical entity.

It is important to note that appendix is mobile organ and presenting with variable position within the abdomen. Hence during appendicitis, it has increase tendency to move and get adherent to surrounding structures resulting in mechanical small bowel obstruction. Predisposing factor for developing mechanical obstructions, it mobility long length, recurrent illness and pre-ileal position of the appendix are more prone to develop the obstruction. Preoperative diagnosis is very difficult; the use of abdomen CT scan may not be reliable. So difficulty in diagnosis increases morbidity and mortality.

Strangulation may result from a long standing closed loop obstruction, which can be due to the long appendix constricting around a loop of the small bowel or when it is adherent to the surrounding structures of posterior peritoneum in the cavity forming a loop and part of the bowel herniate through the gap of loop. There are only ten cases reported in the literature reviewed by "O" Donnell et.al. closed loops and strangulating obstruction of the small bowel are serious lesion that requires emergency surgery to minimise the risk of morbidity and mortality. Delayed operation potentially result in high mortality.

## Conclusion

Mechanical bowel obstruction is an extremely rare, uncommon and unanticipated complications of the inflamed appendix, which is a life-threatening complication. Midline explorative laparotomy with simple appendectomy or segmental resection or right sided hemicolectomy should be done.

## Reference

1. Makama JG, Kache SA, Ajah LJ, Ameh EA. INTESTINAL OBSTRUCTION CAUSED BY APPENDICITIS: A SYSTEMATIC REVIEW. *J West Afr Coll Surg.* 2017 Jul-Sep;7(3):94-115. PMID: 30525005; PMCID: PMC6237405.
2. Al-Qallaf A, Shuaib A, Al-Sharaf K, Behbehani A. Acute appendicitis as a rare cause of mechanical small bowel obstruction case report. *Qatar Medical Journal.* 2017 ;2017(2):4. DOI: 10.5339/qmj.2017.4. PMID: 28785536; PMCID: PMC5494686.

3. Bhandari, L., Mohandas, P. Appendicitis as a cause of intestinal strangulation: a case report and review. *World J Emerg Surg* 4, 34 (2009). <https://doi.org/10.1186/1749-7922-4-34>
4. Pham Hong Duca Ngo Minh Xuanb Nguyen Huu Thuyeta Huynh Quang Huyb, Intestinal Obstruction due to Acute Appendicitis DOI: 10.1159/000508435
5. Ondrej ˇ Maly´, Jiriˇ Páral, Appendicitis as a rare cause of mechanical small-bowel obstruction: A literature review of case reports, Contents lists available at ScienceDirect, <https://www.sciencedirect.com/science/article/pii/S2210261216304631>
6. Mekete Wondwosen a, Temesgen Tantu b, Dereje Zewdu , Appendiceal knotting causing small bowel obstruction: A rare case report, <https://doi.org/10.1016/j.ijscr.2022.106970>
7. Harrison S, Mahawar K, Brown D, Boobis L, Small P. Acute appendicitis presenting as small bowel obstruction: two case reports. *Cases J.* 2009 Nov 28;2:9106. doi: 10.1186/1757-1626-2-9106. PMID: 20062683; PMCID: PMC2803903
8. Ahmed, K.A., Hamdy, A.M.F., Seifeldin, M.I. et al. Mechanical small bowel obstruction due to appendiceal tourniquet: a case report and review of literature. *J Med Case Reports* 13, 208 (2019). <https://doi.org/10.1186/s13256-019-2156-y>
9. Awale L, Joshi BR, Rajbanshi S, Adhikary S. Appendiceal tie syndrome: A very rare complication of a common disease. *World J Gastrointest Surg* 2015; 7(4): 67-70 [PMID: 25914785 DOI: 10.4240/wjgs.v7.i4.67]
10. Cite this article as: Arajmand ST, Hassan Y. Appendiceal Tourniquet, an extremely rare condition with an equally rare presentation: A case report and an integrative review, *Journal of Emergency Medicine, Trauma & Acute Care.* 2022(4):20 <http://dx.doi.org/10.5339/jemtac.2022.20>