

Case study

Skeletal Ewing Sarcoma with Multiple Metastases in both lungs Treated with Volumetric Modulated Arc Therapy: A case report

Abstract:

Lung-only metastasis in Ewing Sarcoma (ES) is a rare presentation in an otherwise common skeletal malignancy with a poor 5-year overall survival (OS) of 30% and a 10-year event-free survival (EFS) of 50.3%, respectively. We report a first case of a 11-year-old male with ES lung-only metastatic disease who underwent whole lung irradiation (WLI) post standard chemotherapy with Volumetric Modulated Arc Therapy (VMAT) with an intent to reduce the radiation dose to critical organs at risk (OAR's) viz heart and spinal cord and document dosimetric parameters.

Keywords: Sarcoma, Ewing; Whole Lung Irradiation ; Volumetric Modulated Arc Therapy; Organs at Risk, Pulmonary Function Tests .

Introduction

"Small round cell sarcoma was first described as a diffuse endothelioma of bone by the American pathologist James Ewing (1866 - 1943). It is the second most common malignant bone tumour in children/young adults after osteosarcoma, with a male-to-female (M:F) ratio of 1.5:1, a peak incidence in the second decade of life, and an overall incidence of 3 cases per million per year in the US population" (1). Almost 80% of patients are aged < 20 years. Epidemiologically, it predominantly affects Caucasians, rarely African Americans, Asians and Native Americans. It primarily affects the diaphyseal region of long bones (lower > upper extremity)

"Its pathogenesis is now known to involve several gene fusions involving at least one member of the FET gene family (usually EWSR1) and the E26 transformation-specific (ETS) transcription factor family, which alter gene expression and promote tumorigenesis. The most common translocation is t(11;22) (q24;q12) resulting in EWSR1-FLI1 fusion (85-90%), while the second most common is t(21;22)(q22;q12) resulting in EWSR1-ERG fusion. Other secondary mutations include STAG2 (15-22%), CDKN2A (12%) and TP53 (7%). Together with FUS/TLS and TAF15, EWSR1 forms the FET (or TET) gene family and encodes the ubiquitously expressed EWS protein" (2). Diagnosis requires the integration of clinical, radiographic, immunohistochemical and molecular information.

Microscopically, classic Ewing sarcoma (ES) has uniform small round cells with a sheet-like growth pattern, dense fibrous tissue separated by islands, and where tumour cells are 1 - 2 times the size of lymphocytes, with round nuclei and finely punctate chromatin. "Other variants include a subset with neuroectodermal differentiation (Homer-Wright pseudorosettes), atypical Ewing sarcoma and adamantinoma-like Ewing sarcoma characterised by high grade pleomorphism. On IHC, CD99 (strong, diffuse membranous expression in (90-95%), NKX2.2 (high specificity), vimentin (80-90%) and FLI1 (nuclear staining with EWSR1-FLI1 fusion, (90%). p63 and cytokeratin is diffuse in the adamantinoma variant" (2).

Case Presentation:

A 11-year-old male presented with left knee swelling; one imaging (magnetic resonance), had a distal diaphyseal mass and closely abutted the growth plate posteriorly. He was diagnosed as ES (on IHC showed positivity for FLI1 & cyclin D1 but negative for WT1). Systemic evaluation with 18FDG Positron Emission Tomography (PET) revealed multiple lung nodules. He underwent left femur intercalary resection,

extracorporeal radiation therapy (ECRT), fixation, and fibula grafting, followed by systemic therapy (VCD) vincristine, doxorubicin cyclophosphamide (EURO EWING 2012 Protocol (ARM B VDC/IE) along with ARM A-Zoledronic Acid treatment protocol outside the reporting institution. A check-ray after chemotherapy was clear. After consent, the patient underwent appropriate immobilisation for simulation radiation therapy using customised solution (VacLoc) and acquisition of computed tomography (CT) scan in DICOM format for image segmentation and planning. The planning target volume (PTV) and organ at risk volume (OAR) were delineated using planning software. The prescribed dose to PTV volume was 15Gy in 10 fractions.

Treatment plan was generated using 6MV photon using Elekta™ Synergy linear accelerator with full arc and 8mm segment width for volumetric modulated arc therapy (VMAT). The VMAT plan was generated using Monaco™ V5.1 treatment planning system, along with Monte Carlo dose calculation as shown in figure 1 (a, b & c). Dose volume histogram (DVH) was used for plan quality analysis. Mean dose, max dose and dose volume received by PTV volume (95% of prescribed dose) were 15.3Gy, 17.2Gy and 96%. Similarly, mean dose and dose volume received by OAR, such as heart, liver, and stomach, were 7.3Gy, 6.2Gy and 6.1Gy. The maximum dose to the spinal cord was 14.2Gy. In addition, the results of conformity and homogeneity index were 0.96 and 0.16.

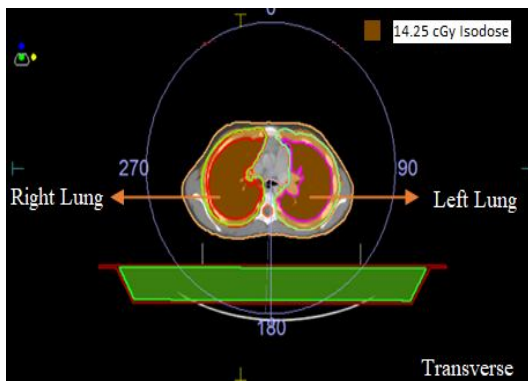


Fig (a)

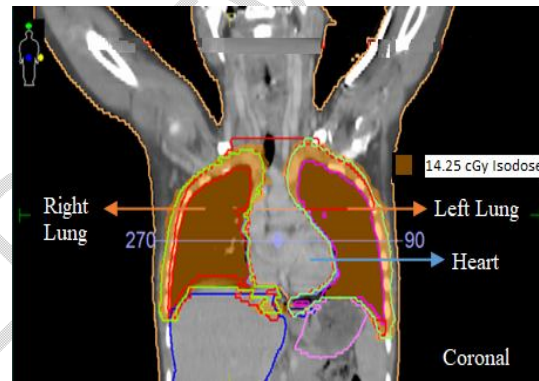
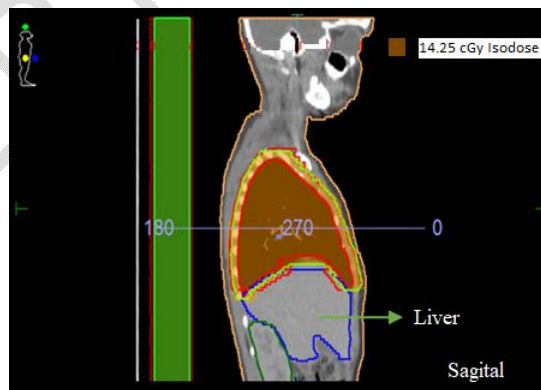

Fig (b)



Fig(c)

Fig 1 (a,b,c). Treatment Planning of Ewing sarcoma using Volumetric Modulated Arc Therapy

Discussion:

The clinical features of ES are largely nonspecific. Patients may present with a pathological fracture (10 to 15%) and nonspecific constitutive symptoms. Blood tests are non contributory, though an elevated serum lactate dehydrogenase level may be correlated with poor prognosis.

"Systemic metastases (usually lung, bone and bone marrow) portend a poor 5-year overall survival (OS) of 30%; ten-year event-free survival (EFS) for patients with ES lung-only metastases is significantly lower than for localised disease (30 vs 48%, respectively), although significantly better than for patients with extrapulmonary metastases (16%)(3). Treatment failure in patients with lung-only metastases is mainly due to pulmonary/pleural recurrence, either isolated or combined with local failure" (4). This raises the question of the role of consolidative local therapy in the lung and pleura - whole lung irradiation (WLI).

The rationale for WLI was established in the first intergroup trial in the 1990s,(5) which demonstrated its efficacy. In the absence of well randomised clinical trials demonstrating the benefit of WLI in the management of metastatic ES, all available evidence is derived from retrospective studies, and only two studies have prospectively evaluated the role of WLI in metastatic ES (ISG/SSG IV Study and Euro Ewing 99).

"163 patients in a retrospective study with metastatic ES (108 patients with lung metastases ± other sites and 73 patients with lung-only disease) was reported and 43 patients were deemed eligible for analysis. Median age of the entire cohort (41 patients) was 11 years (range: 2-17 years); those with lung-only metastases and complete response on radiology were included. 70.7% had bilateral lung lesions and 17% with solitary pulmonary nodules. Patients were treated with Paediatric Oncology Group/Children's Cancer Group protocol, consisting of VAC/IE (vincristine 1.5 mg/m², doxorubicin: 75 mg/m² over 48 h; cyclophosphamide: 1.2 gm/m², alternating with ifosfamide: 1.8 gm/m²/day × 5 days and etoposide: 100 mg/m²/day × 5 days) for 48 weeks. At a median follow-up of 43 months (range: 14-124), 26 patients (58.5%) were alive, 14 patients (34%) had died, three patients were lost to follow-up. WLI was administered at week 30 with 3D conformal radiotherapy (CRT) with parallel opposed antero-posterior/postero-anterior (AP/PA) fields (8,9,10). Clinical target volume (CTV) included bilateral lungs from apex to diaphragm and Planning Target Volume (PTV) was generated with an additional 1 cm margin to CTV to a dose of 15 Gy/10 fractions at 1.5 Gy/fraction once per day" (6).

"5-year EFS showed a statistically significant improvement with WLI (+ve) compared to WLI (-ve) (42.2 vs. 18.2%; p = 0.04) and 5-year progression-free survival (PFS) was better, though not statistically significant (56.9 vs. 27.3%; p = 0.06). 5-year OS was 62.1 vs. 56.3% in WLI (+ve) vs. WLI (-ve) (p = 0.96)" (6).

These results were better than Euro Ewing 99 study (3 years OS and EFS of 51.5 and 50.3%) respectively, with standard chemotherapy and WLI(3). Meanwhile, the ongoing Euro Ewing 2012 trial is randomising lung-only metastatic ES to two arms of different chemotherapy regimens with WLI, which will further establish its role.

Critical OAR dose has been sparingly documented though in EICESS-92 study, WLI was recommended after complete remission with 15-21Gy (at 1.5Gy/fraction once daily or hyperfractionation schedules with 1.25Gy/twice daily and some patients with residual lesion received tumour boost. In follow up, some patients underwent Pulmonary Function Tests (PFT's) graded on severity of dysfunction. 43% had normal PFT's with WLI alone and 7% (2 patients) had severe degradation of PFT's from baseline. 5-year OS was reported better (0.61 for WLI vs. 0.49 for no WLI) though not statistically significant (p=0.363). Some patients had also undergone thoracic surgery and further chemotherapy that confounds the results(7).

Conclusion:

WLI for metastatic ES is safe with a positive impact on OS. Previous studies have used older 3D Conformal radiotherapy techniques (3DCRT) and variable fractionation schedules. Our report with VMAT demonstrates its safety and has the potential for better dosimetric coverage compared to 3D-CRT

techniques. It has been theorised and demonstrated in other subsites that lowering the total dose, limited to partial organ tolerances, significantly affects morbidity. Modern planning systems also allow for an audit trail with recording and verification systems through daily cone beam computed tomography (CBCT) to minimise the influence of translational and rotational movement on the treatment volume, and its safety should be explored in a prospective study. We recommend the use of ventilation-perfusion scanning to determine the physiological association with pulmonary function testing as a functional correlate.

Consent:

As per international standard or university standard, parental written consent has been collected and preserved by the author(s)

Ethical Approval:

As per international standard or university standard written ethical approval has been collected and preserved by the author(s).

References:

1. Kridis WB, Toumi N, Chaari H, Khanfir A, Ayadi K, Keskes H, et al. A Review of Ewing Sarcoma Treatment: Is it Still a Subject of Debate? *Rev Recent Clin Trials*. 2017;12(1):19–23.
2. Riggi N, Suvà ML, Stamenkovic I. Ewing's Sarcoma. *N Engl J Med*. 2021 Jan 14;384(2):154–64.
3. Dirksen U, Brennan B, Le Deley MC, Cozic N, van den Berg H, Bhadri V, et al. High-Dose Chemotherapy Compared With Standard Chemotherapy and Lung Radiation in Ewing Sarcoma With Pulmonary Metastases: Results of the European Ewing Tumour Working Initiative of National Groups, 99 Trial and EWING 2008. *J Clin Oncol*. 2019 Dec 1;37(34):3192–202.
4. Dunst J, Paulussen M, Jürgens H. Lung irradiation for Ewing's sarcoma with pulmonary metastases at diagnosis: results of the CESS-studies. *Strahlenther Onkol*. 1993 Oct;169(10):621–3.
5. Ronchi L, Buwenge M, Cortesi A, Ammendolia I, Frakulli R, Abate ME, et al. Whole Lung Irradiation in Patients with Osteosarcoma and Ewing Sarcoma. *Anticancer Res*. 2018 Sep;38(9):4977–85.
6. Elghazawy H, Nasr A, Zaky I, Zamzam M, Elgammal A, Farid N, et al. Whole lung irradiation for completely responding pulmonary metastases in pediatric Ewing sarcoma. *Future Oncol*. 2020 May;16(15):1043–51.
7. Bölling T, Schuck A, Paulussen M, Dirksen U, Ranft A, Könemann S, et al. Whole lung irradiation in patients with exclusively pulmonary metastases of Ewing tumors. Toxicity analysis and treatment results of the EICESS-92 trial. *Strahlenther Onkol*. 2008 Apr;184(4):193–7.
8. Dang, Alexa, Xiaolan Feng, Jeremy Hamm, Caroline L. Holloway, and Pauline T. Truong. "Survival Outcomes in Metastatic Ewing Sarcoma Treated With Whole-Lung Radiation." *Cureus* 14, no. 7 (2022).
9. Ben Kridis, Wala, Nabil Toumi, Hadil Chaari, Afef Khanfir, Kamel Ayadi, Hassib Keskes, Tahia Boudawara, Jamel Daoud, and Mounir Frikha. "A review of Ewing sarcoma treatment: is it still a subject of debate?." *Reviews on Recent Clinical Trials* 12, no. 1 (2017): 19-23.
10. Paulino, Arnold C., Wei Y. Mai, and Bin S. Teh. "Radiotherapy in metastatic Ewing sarcoma." *American journal of clinical oncology* 36, no. 3 (2013): 283-286.