

fever and shock not always mean septic shock

ABSTRACT

Aim : Hemophagocytic Lymphohistiocytosis is often confused with a septic shock. Hemophagocytic Lymphohistiocytosis is a life-threatening condition in which the immune system overreact. It cause the release of high levels of inflammatory cytokines, leading to fever, cytopenias, hyperferritinemia, and hypertriglyceridemia. HLH can be primary or secondary of an underlying condition such as infection, malignancy, or autoimmune disease. **Presentation :** The article describes a case report of a 65-year-old woman who was admitted to the hospital with bloody diarrhea and fever. The patient had a medical history of diffuse large B-cell lymphoma, coronary artery disease, heart failure, and diabetes mellitus. On admission, the patient had low hemoglobin, platelet count, and leukopenia. The laboratory investigations showed elevated AST and CRP levels, positive CMV PCR, and high levels of ferritin, fibrinogen, and soluble CD25. The patient was treated with dexamethasone and ganciclovir IV. A subsequent lymph node biopsy showed CMV-related lymphadenitis. The article also explain the pathophysiology of the disease and the possibilities of treatment.

Conclusion : Hemophagocytic Lymphohistiocytosis should be suspected if patient do not respond quickly to the treatment. Also, if Hemophagocytic Lymphohistiocytosis flare again it seems not enough to give the same immunosuppressive treatment but a stronger one is needed.

Key words : *Hemophagocytic lymphohistiocytosis, Septic shock, CMV, diffuse large B-cell lymphoma, HLH.*

INTRODUCTION

Hemophagocytic lymphohistiocytosis (HLH) or Hemophagocytic syndrome (HPS) is an undiagnosed life-threatening condition in which uncontrolled activation of lymphocytes and macrophages causes the release of inflammatory cytokines. It is characterized by hyperferritinemia, cytopenias, and hypertriglyceridemia. Common clinical manifestations of HLH include fever, lymphadenopathy, hepatosplenomegaly, and multiorgan failure. HLH may be primary or secondary. The primary form, also called familial HLH is caused by mutations with genetic inheritance. Secondary HLH may occur in the presence of an underlying disorder such as infection, malignancy, autoimmune or auto-inflammatory disease¹.

Here we describe a case of HLH secondary to cytomegalovirus (CMV).

Presentation of the case

A 65-year-old female, with a past medical history of diffuse large B-cell lymphoma eight years prior to admission. She had received treatment with R-CHOP and methotrexate resulting in regression of the disease, according to Pet-Ct performed at the end of treatment eight years before her admission. Seven years later (one year before her admission) she underwent a mastectomy because of a suspicious finding, shown to be Carcinoma in Situ at biopsy. Investigation of this suspicious finding included a Pet Ct which demonstrated enlarged lymph nodes above and below the diaphragm as well as in the neck. Biopsy showed no evidence of malignancy. Apart from this, two years before her admission, she had undergone a coronary catheterization due to a NSTEMI and recent onset of heart failure with a decreased ejection fraction, 25-30%, determined by the cardiac echography. Later an ICD was implanted for primary prevention. She also was being treated for diabetes mellitus type 2 with glucomin and SLGT-2.

On admission she had bloody diarrhea accompanied by fever of up to 39°C. In the emergency room the pulse was 91 bpm, temperature 38.5°C, oxygen saturation in room air 97%, and blood pressure 79/48 mmHg. The clinical examination did not reveal significant finding. The laboratory showed: a hemoglobin (Hg) of 11.8 g/L with low MCV, platelets 118 k/μL (around 300 k/μL in previous blood samples), leukopenia 2.4 k/μL (previously around 7 k/μL), lymphopenia 0.2 k/μL (previously around 2 k/μL), normal absolute neutrophil count, an elevated AST of 63 U/L, a normal creatinine level, and a CRP of 2.62 mg/dl. Isotonic intravenous fluid was administered and an empiric treatment with Ceftriaxone was initiated. The patient was hospitalized in a first department of internal medicine. Investigations included: stool, urine and blood cultures (all negative), and stool PCR (including clostridium difficile), which was also negative. Abdominal ultrasound revealed an enlarged spleen (17 cm.) with no other abnormal findings. On the 7th day of hospitalization, the condition of the patient deteriorated and blood pressure dropped again. An echocardiogram demonstrated an ejection fraction of around 40% without pericardial effusion and no evidence of vegetation. As the condition continued to worsen, a treatment with Meronem, vancomycin and Colistin was started. The patient was transferred to our internal medical department in critical condition for further investigation and treatment. On admission in the department, the blood pressure was 70 mmHg systolic, heart rate was between 70-80 bpm, with a normal saturation. The patient was conscious, and the only complain was weakness. There were no abnormal findings on physical examination. The significant changes in the blood sample as compared with the previous day in the first internal medicine department are : a rise in creatinine to 1.27 mg/dl, alkaline phosphatase to 662 U/L, GGT to 733 U/L AST to 233 U/L, although ALT remained normal. An urgent total body CT was showed a splenic infarct, but otherwise was normal. The laboratory findings on the second day revealed a positive PCR for CMV at 154100 IU/mL. The laboratory also showed a worsening of the thrombocytopenia 23 k/μL (down from 108 k/μL), a rise of INR to 1.6 (previously normal on admission in the ER). The liver enzyme continued to rise and the CRP increased from 2.62 md/dl at admission in emergency room to 15 mg/dL. Other significant findings were a ferritin of 42,100 ng/mL and a fibrinogen of 87 mg/dL. In an interdepartmental discussion with hematologists and infectious disease specialist, the possibility of either HLH (because

CMV reactivation) or a relapse of lymphoma was raised. Due to a high suspicion of HLH it was decided to administer treatment with dexamethasone 20mg and ganciclovir IV. Ensuing blood samples showed a triglyceride level of 383 mg/dL and soluble CD25 of 7530 U/mL. A subsequent lymph node biopsy displayed no evidence of lymphoma but, large cells with inclusions some nuclear with owl eye appearance and large cells with inclusions stained positive for CMV confirmed a CMV-related lymphadenitis. There was no evidence of hemophagocytosis in the bone marrow biopsy. Under the treatment with steroids and ganciclovir the patient's condition improved and it was decided not to start cytotoxic or immunosuppressive treatment. After 8 days of treatment the laboratory finding showed a normal creatinine, near normal CRP, improvement of liver enzyme not yet normalized, a drop in ferritin level to 4752 ng/mL, a rise in platelets to 106 k/ μ L and the viral load of CMV decreased to 117,600 IU/mL. It was decided to lower the steroid. Unfortunately, 10 days after starting treatment, her condition worsened again with a reappearance of diarrhea and high fever. The doses of steroids and ganciclovir were increased without improvement. All cultures were negative although the viral load of CMV rose to 267873 IU/mL. One day later, her condition was much worse; she was intubated due to respiratory and hemodynamic instability. The condition continued to deteriorate and the patient died the same day from internal hemorrhage associated with disseminated intravascular coagulation. The last laboratory findings were as follows: platelets 16 k/ μ L, Hg 8 g/L, INR 1.86, APTT 102 sec, creatinine 1.9 mg/dL, and CRP around 8 mg/dL. The reason of the CMV reactivation still unknown.

Discussion

HLH is a life-threatening, underdiagnosed syndrome caused by the excessive release of inflammatory mediators. There is a primary and a secondary form. In the present case, the patient suffered from the secondary form which was caused by the CMV. The pathophysiology of HLH is complex and involves dysregulation of the immune system, leading to excessive activation of T cells and macrophages, and subsequent tissue damage. In HLH, the immune system overreacts to an initial trigger, such as an infection or malignancy, and fails to control the immune response, leading to uncontrolled inflammation. This uncontrolled inflammation can cause damage to multiple organs, including the liver, spleen, bone marrow, and nervous system. One of the key features of HLH is the activation of cytotoxic T cells and natural killer (NK) cells, which release large amounts of pro-inflammatory cytokines, such as interferon-gamma (IFN- γ). These cytokines stimulate the activation of macrophages which causes the pancytopenia. In addition to the activation of T cells and macrophages, HLH is also characterized by defects in the function of natural killer cells and regulatory T cells, which normally play a role in controlling the immune response and preventing excessive inflammation^{2,3}. (Fig 1). The HLH syndrome occurs with variable symptoms, depending also to the pathologies that could contribute to its presentation⁴. For example, in our case, the presentation was a bloody diarrhea caused by CMV colitis. But the disease may be triggered by a very wide range of diseases including viruses (EBV, HIV,...), Bacteria (*Mycobacterium tuberculosis*,...), Parasites (*Leishmania*, toxoplasmosis,...), fungi (*histoplasma* spp,...), neoplasia (T-cell and B-Cell lymphoma, auto-immune disease (Lupus,...), Transplantation, Drugs, surgery, pregnancy, hemodialysis and others⁵.

The diagnosis of HLH is traditionally made by 5 or more findings (see table 1): fever, splenomegaly, cytopenia, hypertriglyceridemia, low fibrinogen, hemophagocytosis, low NK cell activity, high ferritin and increase of soluble CD 25⁵. Another proposal for diagnosis (Hscore) was developed in 2014. It also considers the Hg, the presence of a hepatomegaly, and the level of AST/ALT⁶. Our patient fulfilled the criteria since there were 7 findings: fever, splenomegaly, cytopenia, hypertriglyceridemia, low fibrinogen, high ferritin and increase of soluble CD 25. The Hscore was 95% probability of HLH. Another validate score based on age, thrombocytopenia and hypertriglyceridemia was also proposed⁶. Our patient had 2 on 4 points.

The management of secondary HLH should include treatment of the cause with an immunosuppressive regime. Indeed, HLH is caused by excessive release of inflammatory mediators. The current treatment of HLH is based on protocols that include immunosuppressive agents, such as dexamethasone, cyclosporine, etoposide and Rituximab as adjuvant treatment. In infection-triggered HLH, a high dose of intravenous immunoglobulins should be considered in combination with steroids. Supportive treatment should be offered to all patients⁴. Our patient was treated by Gancyclovir and dexamethasone with a good response initially. The use of immunosuppressive agents in secondary HLH is discussed in the literature; usually there is a combination of steroid with another immunomodulatory⁸. In our patient, considering the good initial response of the treatment, the rise of DNA CMV and the new acute renal failure, it was decided to only higher the doses of the dexamethasone as first step. Unfortunately the patient died very quickly (one and half day). For unknown reasons, the CMV infection stopped responding to the treatment and finally caused the death of the patient.

Conclusion

This case report illustrates the difficulties to diagnostic the HLH. Its presentation which is similar to septic shock could delay the diagnosis. The difficulty is to identify the syndrome and the underlying disease early. The clinician should be aware of this syndrome in order to diagnose and treat rapidly. HLH should be considered in the differential diagnosis whenever there is an obscure clinical presentation with fever and hypotension, particularly in patient with risk factors such as neoplasm, immunosuppression or auto-immune disease. This case report support that if the patient worsen his condition, it is not sufficient to just return to the earlier immunosuppressive treatment but need a stronger one with the treatment of the etiology (CMV).

References

1. Soy M, Atagündüz P, Atagündüz I, Sucak GT. Hemophagocytic lymphohistiocytosis: a review inspired by the COVID-19 pandemic. *Rheumatol Int.* 2021 Jan;41(1):7-18.
2. Crayne CB, Albeituni S, Nichols KE, Cron RQ. The Immunology of Macrophage Activation Syndrome. *Front Immunol.* 2019 Feb 1;10:119. doi: 10.3389/fimmu.2019.00119. PMID: 30774631; PMCID: PMC6367262.
3. Canna SW, Marsh RA. Pediatric hemophagocytic lymphohistiocytosis. *Blood.* 2020 Apr 16;135(16):1332-1343. doi: 10.1182/blood.2019000936. PMID: 32107531; PMCID: PMC8212354.

4. Koumadoraki E, Madouros N, Sharif S, Saleem A, Jarvis S, Khan S. Hemophagocytic Lymphohistiocytosis and Infection: A Literature Review. *Cureus*. 2022 Feb 20;14(2):e22411.
5. Ramos-Casals M, Brito-Zerón P, López-Guillermo A, Khamashta MA, Bosch X. Adult haemophagocytic syndrome. *Lancet*. 2014 Apr 26;383(9927):1503-1516.
6. Fardet L, Galicier L, Lambotte O, Marzac C, Aumont C, Chahwan D, Coppo P, Hejblum G. Development and validation of the HScore, a score for the diagnosis of reactive hemophagocytic syndrome. *Arthritis Rheumatol*. 2014 Sep;66(9):2613-20
7. G. Urbanski, L. Terriou, G. Fouquet, J.F. Hamel, C. Lavigne, C. Orvain, C. Larroche, O. Hermine, C. Bloch-Queyrat, C. Lacout. Factors associated with mortality at D30 in lymphohistiocytic hemophagocytosis in adults: construction of a mortality score from a multicenter cohort of 170 patients and validation on a cohort of 118 patients. *The Journal of Internal Medicine* Volume 41, Supplement, December 2020, Pages A69-A70
8. Rolsdorph LÅ, Mosevoll KA, Helgeland L, Reikvam H. Concomitant Hemophagocytic Lymphohistiocytosis and Cytomegalovirus Disease: A Case Based Systemic Review. *Front Med (Lausanne)*. 2022 Apr 19;9:819465. doi: 10.3389/fmed.2022.819465. PMID: 35514747; PMCID: PMC9063453.

Table 1. Criteria of HLH

<ul style="list-style-type: none"> • Fever of 38.5°C or more • Splenomegaly • Cytopenias (affecting at least two of three cell lineages in the peripheral blood) <ul style="list-style-type: none"> --Hemoglobin <5.59 mmol/L (infants <4 weeks, <6.21 mmol/L) --Platelets <100 cells per 10⁹ /L --Neutrophils <1 cell per 10⁹ /L • Hypertriglyceridaemia (fasting, >3 mmol/L) or hypofibrinogenaemia (<1.7 mmol/L), or both • Hemophagocytosis in bone marrow, spleen, lymph nodes, or liver • Low or absent natural killer-cell activity • Ferritin greater than 1123.5 pmol/L • Increased soluble CD25 concentration (alpha chain of soluble interleukin 2 receptor)
--

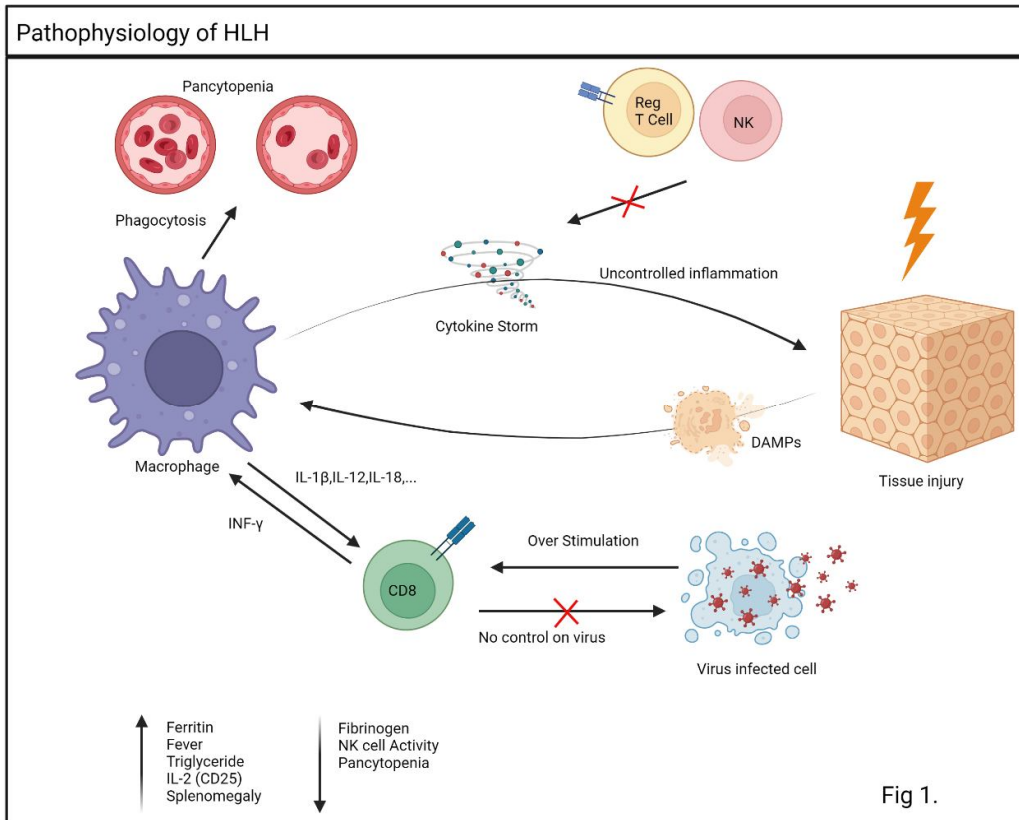


Fig 1. Pathophysiology of HLH

UNDER PEE