

## **Giant Meckel's Diverticulum Causing Small bowel obstruction – 5 Case Reports**

### **Abstract**

Meckel's Diverticulum size more than 5 cm are classified as Giant Meckel's Diverticulum. They are relatively rare and may be more prone complications especially for obstruction. 90 % of Meckel's Diverticulum ranges in size from 1-10 cm. It is estimated that's as 4-9 % cases manifest complications and obstruction is the most common presenting symptom in adults. Large size and length of giant Meckel's Diverticulum are predisposing to obstruction. More over diverticulitis, torsion and volvulus are more common complication in longer Meckel's Diverticulum with narrow base are more prone to axial torsion of giant Meckel's Diverticulum, whereas short and wide base giant Meckel's Diverticulum may promote foreign body entrapment. A revision of English literature and PubMed database shows a total 28 reported cases of giant Meckel's Diverticulum in adults.

Herein we report five rare cases of giant Meckel's Diverticulum and its clinical presentation. Out of five giant Meckel's Diverticulum, three cases presented with obstruction, one case presented with diverticulitis and another case of axial torsion of giant Meckel's Diverticulum with small bowel obstruction in adults. All are successfully managed by explorative laparotomy, surgical resection and end to end anastomosis done.

### **Key words**

Giant Meckel's Diverticulum, Small bowel obstruction, Resection and anastomosis

### **Introduction**

A Meckel's Diverticulum over 5 cm long is classified as a giant Meckel's Diverticulum(GMD). The reported rate of complication is 4-16 %. In pediatric patient's lower gastrointestinal bleeding and obstruction are the common complication while in adults, intestinal obstruction and diverticulitis is the most frequent clinical presentation, mainly intestinal obstruction, volvulus and rarely due to diverticulitis, axial torsion, Mesodiverticular band with strangulation and litre's hernia. [1,2,3]

There is complication of this variant of Meckel's Diverticulum that are directly related to its size and length of Meckel's Diverticulum, predisposes to small bowel obstruction. Small intestine volvulus due to giant Meckel's Diverticulum is rare and is defined by the twist of the small bowel around its vascular axis and requires a timely management to reduce the high mortality and morbidity. [4,5]

Diverticulitis is 10-20% cases present itself as an acute abdominal pain and can lead to perforation and subsequent peritonitis and it may mimic acute appendicitis clinically. It can be results of acid secretion from ectopic gastric and pancreatic tissue, causing inflammation of the adjacent ileal mucosa or diverticulitis cause by entroliths. Therefore, a segmental

resection is recommended after palpation, which includes excision of ectopic tissue. We present a very unusual case of giant Meckel's Diverticulum with axial torsion causing small bowel obstruction and requires emergency surgical resection. [1,4,6]

## **Discussion**

Giant Meckel's Diverticulum is relatively rare. The longest giant Meckel's Diverticulum reported have been 100 cm long, in adult. Case of giant Meckel's Diverticulum causing small bowel obstruction is the most frequent complication in 38-40% patients. Several case reports of Meckel's Diverticulum related obstruction have described strangulation caused by an adherent diverticulum. Many cases, may have resulted from looping and twisting of gut in upon itself, forming a volvulus and small bowel obstruction. The diverticulum large in diameter, long in length predisposes to small bowel obstruction. Thus, an elongated variant with narrow base is more likely to result in torsion, where as a short & wide base diverticulum may present for foreign body entrapment and causing diverticulitis, perforation and peritonitis. [1,2,3,4,5]

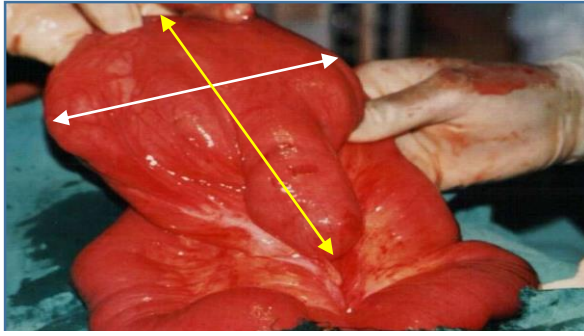
Primary or secondary small bowel volvulus is a rare disease that can result in torsion of the small bowel, As the symptoms progress, patient develop gangrene and perforation due to intestinal ischemia. Therefore, early diagnosis and treatment are the key to prevent intestinal gangrene and perforation. [1,2]

Laparotomy is recommended in emergency situations, especially when the Meckel's Diverticulum is accompanied by intestinal obstruction. Resection of Meckel's Diverticulum can be performed either laparoscopically or through and open explorative laparotomy. Small bowel resection is preferred when there is a palpable abnormal tissue in the diverticulum or when the diverticulum is short and has a broad base. In these condition small bowel resection along with Meckel's Diverticulum with the ectopic tissue is the ideal resection and end to end anastomosis. [1,2,3,4]

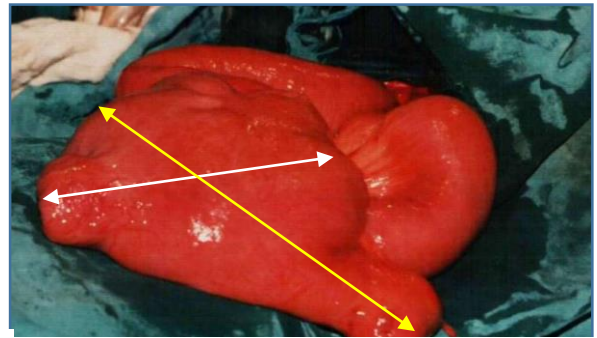
## **Case 1 – Giant Meckel's Diverticulum**

A 25-year-old male patient admitted on our center in 1998, with complaints of Severe pain in abdomen, distension of abdomen & vomiting over the last 24 hours on physical examination patient's abdomen was remarkably distended, plain x-ray abdomen showing multiple air fluid levels say of intestinal obstruction. All laboratory reports were normal and patient was haemodynamically stable.

An emergency laparotomy was performed shows dilation of small bowel segment and having a giant Meckel's Diverticulum size 12 cm wide base and length of 15 cm a the antimesenteric border of the small bowel located in pelvis due to the Meckel's Diverticulum excessively large size and high volume intestinal content leading to sagging in to the pelvic cavity. So we performed total excision of Meckel's Diverticulum along with segment of small bowel and end to end anastomosis done. Histopathology report showing diverticulitis without gastric or pancreatic tissue. Post-operative patient recovery was good and discharged home on 8<sup>th</sup> postoperative day. (Case 1 Figure No. a,b)



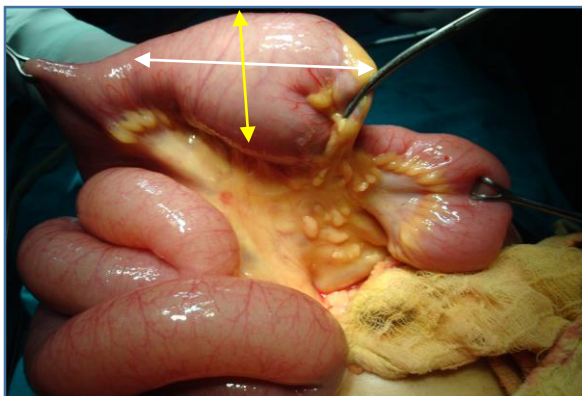
**Case 1 Fig-a** Intra operative photographs  
a-Showing - Giant MD of size 12x15 cm



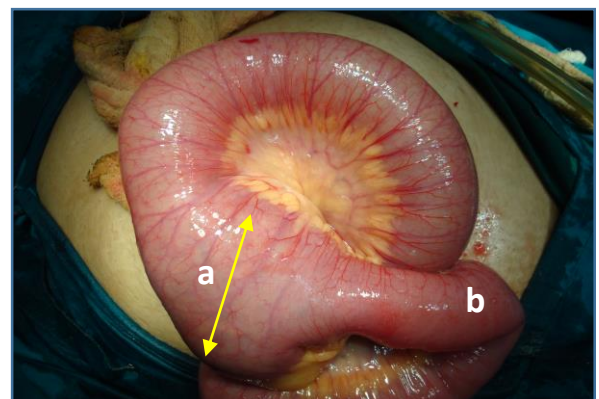
**Case 1 Fig-b** Intra operative photographs  
a-Showing - Small bowel obstruction Giant MD

## Case 2

A 21 years old boy was admitted in our center in 2000, with complains of severe abdominal pain, vomiting distension and constipation for 2 days. All laboratory investigation was normal plain –x-ray abdomen evidence of multiple air-fluid levels, which suggestive of small bowel obstruction. We performed emergency explorative laparotomy which revealed dilated proximal small bowel loop and giant Meckel's Diverticulum size 8x4 cm, causing small bowel obstruction. So we performed small bowel resection along with giant Meckel's Diverticulum and anastomosis. Histopathology report shows diverticulitis and not showing any ectopic tissue. Post-operative recovery was good & discharge patient at home an 8<sup>th</sup> postoperative day. (Case 2 Figure No. a,b)



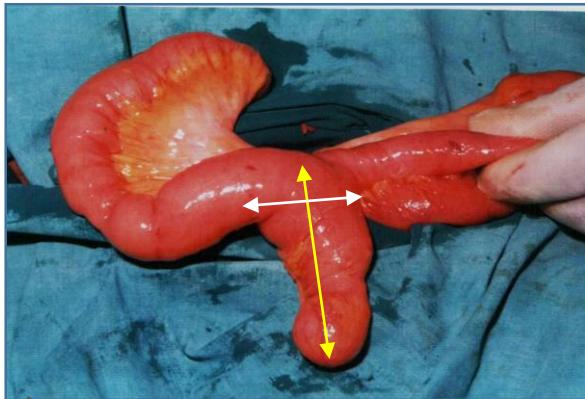
**Case 2 Fig-a** Intra operative photographs  
Showing - Giant MD of size 8x4 cm



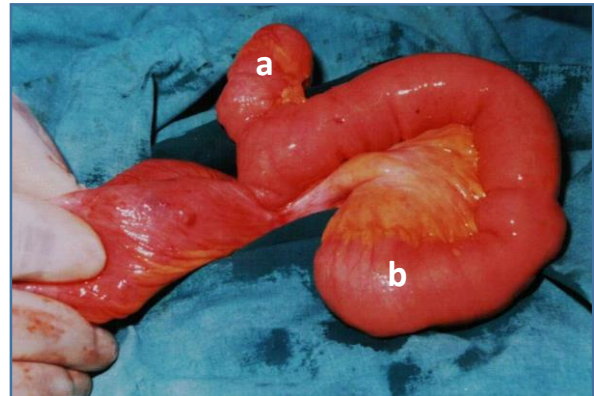
**Case 2 Fig-b** Intra operative photographs  
a-Showing Giant MD. b- Small bowel twist

## Case 3

A 25 years old female admitted in our center in 2001 with complains of abdominal pain, vomiting distension of abdomen and constipation last for 2 days. All laboratory investigation was normal and plain x-ray abdomen shows multiple air-fluid levels represents small bowel obstruction. Emergency explorative laparotomy done through mid-line incision, shows small bowel dilation and there was a giant Meckel's Diverticulum size 8x4 cm causing small bowel obstruction. So we performed small bowel segmental resection along with Meckel's Diverticulum and end to end anastomosis. Histopathology shows diverticulitis with no ectopic tissue. Post-operative recovery was uneventful and discharge on 8<sup>th</sup> post-operative day. (Case 3 Figure No. a,b)



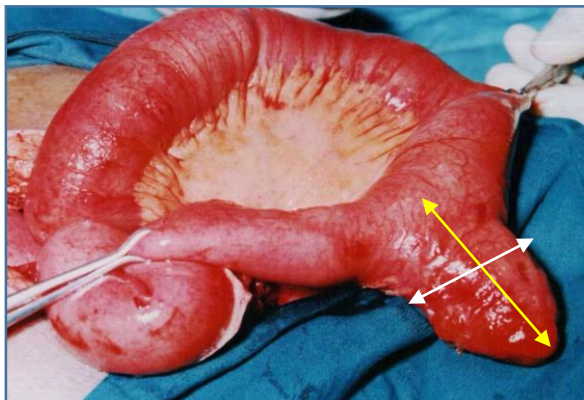
**Case 3 Fig-a Intra operative photographs**  
 Showing - Giant MD of size 8x4 cm



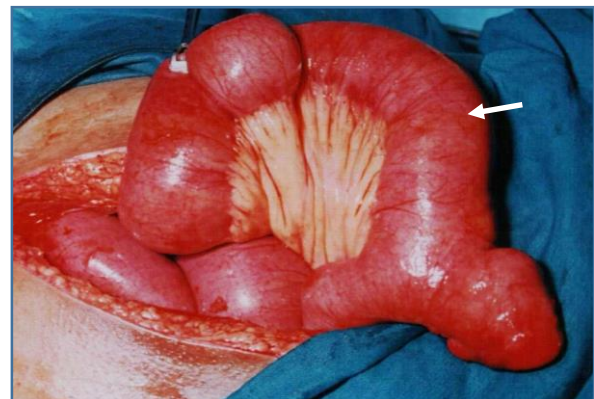
**Case 3 Fig-b Intra operative photographs**  
 a-Showing Giant MD. b- Small bowel obstruction

### Case No. 4

A 32 years male patient was admitted in our center, in 2003, with complaints of severe abdomen pain, distension of abdomen and fever last 4 days. The laboratory blood test total leukocytes count was 21,000 cmm. Physical examination shows tenderness in lower abdomen, guarding and rigidity was present. Abdominal x-ray shows signs of small bowel obstruction. Emergency laparotomy was performed shows dilated small bowel loops and a giant Meckel's Diverticulum size 6x4 cm, was inflamed, there was no perforation and peritonitis. So we performed segmental small bowel resection along with Meckel's Diverticulum. Histopathology report was acute diverticulitis with no ectopic tissue. On 8<sup>th</sup> postoperative day patient was discharged. (Case 4 Figure No. a,b)



**Case 4 Fig-a Intra operative photographs**  
 Showing - Giant MD of size 6x4 cm



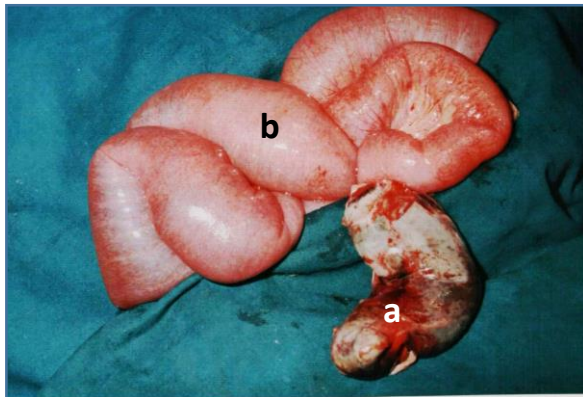
**Case 4 Fig-b Intra operative photographs**  
 Showing - Small bowel obstruction Giant MD

### Case No. 5

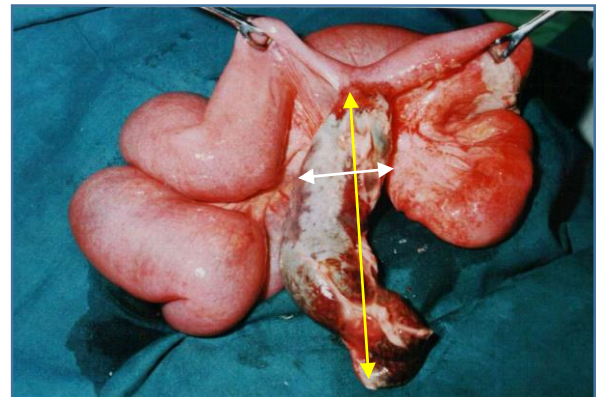
A 25 years-old male patient with complaints of severe abdominal pain, distension of abdomen and constipation of 3 days. Physical examination, patient was hemodynamically stable. Patient was admitted at our center in the year 2002. Abdomen plain X-ray showing acute small bowel obstruction with multiple fluid levels. On ultrasonography and CT abdomen confirmed the diagnosis of acute intestinal obstruction. Therefore, an emergency explorative laparotomy was performed, using a vertical midline incision and revealed 500 ml

serosanguineous fluid in the peritoneal cavity with distended small bowel loops, there was a gangrenous giant Meckel's Diverticulum.

Intraoperatively a twisted narrow base of giant Meckel's Diverticulum of size 12x4 cm with gangrene. Giant Meckel's Diverticulum was axially torted, which caused small bowel obstruction. The twisted & gangrenous Meckel's Diverticulum was resected along with 5 cm of ileum proximal & distal to its base and end to end anastomosis using 2.0 vicryl suture was made to reestablished the continuity of small intestine. A through peritoneal wash was done followed by the insertion of pelvic drain. Post-operative recovery was uncomplicated and patient was discharged on the 8th post-operative day. (Case 5 Figure No. a,b)



**Case 5 Fig-b** Intra operative photographs  
Showing – a- Axis torsion of giant MD. b- Small bowel obstruction



**Case 5 Fig-a** Intra operative photographs  
Showing - Giant MD of size 12x4 cm

## Conclusion

A giant Meckel's Diverticulum is an extremely rare condition, these diverticula are associated with more complications, presenting a higher risk of torsion, volvulus or intestinal obstruction. Emergency laparotomy is recommended, especially when the giant Meckel's Diverticulum is accompanied by intestinal obstruction and segmental resection of small bowel along with Meckel's Diverticulum and end to end anastomosis performed.

## References

1. Akbulut S, Yagmur Y. Giant Meckel's diverticulum: An exceptional cause of intestinal obstruction. *World J Gastrointest Surg.* 2014 Mar 27;6(3):47-50. doi: 10.4240/wjgs.v6.i3.47. PMID: 24672650; PMCID: PMC3964415.
2. Rout, Alexandra MBChB\*; Morreau, Phil FRACS\*; Bird, Helen FRANZCR†; Roberts, Amin FRACP‡,§. Giant Meckel's Diverticulum in a 9-Year-Old Boy: An Unusual Presentation With Isolated Faltering Growth. *JPGN Reports* 3(3):p e208, August 2022. | DOI: 10.1097/PG9.0000000000000208
3. Andreas Minh Luua Kirsten Meurera Torsten Herzoga Waldemar Uhla Andrea Tannapfelb Chris Braumann, Small Bowel Obstruction due to a Giant Meckel's Diverticulum, *Visc Med* 2016;32:434–436 DOI: 10.1159/000450589

4. Lei Ying, Jeong-moh John Yahng, A rare case of Meckel's diverticulum causing small bowel obstruction in a 50-year-old man  
<https://doi.org/10.1016/j.ijscr.2020.01.047>
5. Feinberg L, Morris C, Srinivasan A, Bhattachyra P, Charan K, Zaman S. An Atypical Presentation of Giant Meckel's Diverticulitis: A Case Report. *J Gastroenterol Hepatol Endosc.* 2019; 4(3): 1065.
6. Alfredo Vivas Lopez, Daniel Pastor Altaba, Oana-Anisa Nutu, Alberto Marcacuzco Quinto Servicio de Cirugía General, Giant Meckel Diverticulum: A Rare Cause of Intestinal Obstruction, DOI: 10.1016/j.cireng.2019.03.010
7. Kumar MSK, Vijayalakshmi V, Girieasen SM, Deepika S, Kannan R. Torsion of giant meckel's diverticulum causing acute small bowel obstruction. *Int Surg J* 2022;9:718-21
8. Marc Weijie Ong<sup>1</sup>, MBBS, Ker Kan Tan<sup>1</sup>, MMed, FRCSE, Richard Sim<sup>1</sup>, MBBS, FRCSE, Laparoscopic resection of a huge gangrenous Meckel's diverticulum in an adult, *Singapore Med J* 2013; 54(4): e83-e84 doi: 10.11622/smedj.2013087
9. Nunes QM, Hotouras A, Tiwari S, Sheth A. Gangrene due to axial torsion of a Giant Meckel's Diverticulum containing multiple stones in the lumen: a case report. *Cases J* 2009; 2:7141.
10. Dumper J, Mackenzie S, Mitchell P, et al. Complications of Meckel's diverticula in adults. *Can J Surg* 2006;49:356-7.