

# Histo-Architectural and Testicular Weight Changes in Wistar Rats Fed with Graded Doses of *Piliostigma thonningii* (Schumach)

## ABSTRACT

### Introduction:

*Piliostigma thonningii* is an under explored leguminous plant that belong to the family, Leguminosa – caealpiniodae. The objective of this study therefore was to investigate the effect(s) of its ethanolic leaf extract on male testicular weight and histo-architecture.

### Material and Methods:

Forty (40) male Wistar rats of an average of 160-200 g weight were used for the experiment. They were randomly divided into four (4) groups of ten (10) rats each. The groups were represented as: group 1 served as control, while groups 2, 3 and 4 were treated with 500 mg/kg, 1000 mg/kg and 1200 mg/kg of the extract for 14 days respectively. At the end of the experiment, the rats were sacrificed, testes harvested, weighed and checked for histological changes in seminiferous tubules, epididymis and vas deference. Where necessary, obtained values were subjected to One-way Analysis of Variance (ANOVA) and a level of  $p < 0.05$  was considered significant.

### Results:

Results showed that ethanolic leaf extract of *P. thonningii* caused a significant ( $p < 0.05$ ) decrease in testicular weight following 14days of administration. Histomicrograph showed that 500mg/Kg *Piliostigma thonningii* for 14 Days caused vascular dilatation and congestion within the lining of the seminiferous tubules, 1000 mg/kg *P. thonningii* for 14 days caused less deteriorating effects on the histo-architecture of the rats' testes as the seminiferous tubules appeared normal; even though there was mild hyperplasia of the interstitial cells of Leydig. 1200 mg/kg *Piliostigma thonningii* caused vascular dilatation and active congestion in the seminiferous tubules with moderate hyperplasia of the interstitial cells of Leydig. Histological features of the testes showed the presence of marked vascular dilatation, active congestion and mild hyperplasia of interstitial cells of Leydig in the testes of rats treated with 500 mg/kg and 1000 mg/kg *P. thonningii*. Thus, this study has shown that 14 days treatment of 500 mg/kg *Piliostigma thonningii* caused active interstitial congestion, 1000 mg/kg with plump fibroblast in the epididymis.

**Key words:** *Piliostigma thonningii*, Epididymis, Seminiferous tubules, vas deferens

### Introduction

Male reproduction is a complex process involving the testicles, epididymis, sex glands of the accessory sex, and related hormones. The tests perform the two (2) highly ordered and

complex spermatogenesis and steroidogenesis functions that are essential for life perpetuation [1]. The medical use of botanicals in their natural unprocessed forms undoubtedly began when intelligent animals noticed that certain food plants altered particular body function [2]. In many parts of the world, most especially in developing countries, there is a major dependence on the use of traditional medicine to treat variety of diseases [3, 4]. The pharmacological properties of African medicinal plants are immense: remedies made from plants play an important role in the health of millions of people especially in the rural areas [5].

Although orthodox medicine is generally acceptable, traditional medicine is still preferred and relied upon in many parts of the world [6, 7]. This is common in the developing country where the cost of orthotodox medicine is astronomical and unaffordable to a large size of the populace. According to world Health Organization (WHO), about 80% of folks in the developing country depend mainly on traditional medicine for their primary health care and about 85% of such traditional medicine involves the use of plant extract [8].

Purified plant extracts are vigorously studied and their positive and negative impact on various organs and tissues of the body have been identified [9]. One of the target tissues of plant extracts are reproductive tissues, such as histo-architecture of testes and several sperm parameters. Numerous studies have shown the effect of different plant extracts on the tissues of the reproductive system of laboratory mammals [10]. *P. thonningii* have extensively been used in the treatment of several ailments, ranging from hematological, renal, hepatic and cardiovascular disorders [11, 12, 13]. Information on the role of the ethanolic plant extract of *P. thonningii* on male reproduction is scarce, and the few existing studies have been contradictory. Previous studies on *P. thonningii* effects on male reproduction has focused on the plant extract's role on physiologic process of spermatogenesis and steroidogenesis without proper harmonization with changes in the histology and biometry of male reproductive organs; hence there is a need for a study of this nature.

*P. thonningii* is an under explored leguminous plant that belong to the family, Leguminosa – caealpiniodae [14].It is a common native plant [15]. *P. thonningii* bears common names or local names as in Arabic (tambareibi khuf, kharubi, abu khamerira); English (wild bauhinia, Rhodesian bauhinia, monkey bread, camel's foot; Uganda (Kigali); Ndebele (ihabahaba); shona (mutukutu); Swahili (mchikichi, mchekeche). In Nigeria it bears such local names as Abefa (Yoruba), Kalgo (Hausa) and Okpoatu (Ibo) [16]. It is described in Nigeria by

two related species: *Piliostigma thonningii* and *P. reticulatum* [17]. If appropriate precautions are not taken, the effect of male factor infertility is likely to increase. In the past, since many African countries have fertility rates, it was also believed that infertility in Africa did not require special intervention. If appropriate precautions are not taken, the effect of male factor infertility is likely to increase.

There have been contradicting reports on the effect of *Piliostigma thonningii* on male reproductive structures and functions, few studies such as Ighodaro *et al.*, (2012), have shown aphrodisiac and spermatogenesis stimulatory effect while studies from Dasofunjo *et al.*, (2018), Ighodaro and Omole (2012), have shown anti-fertility potential of the plant extract [18, 19]. Thus, this study.

### **Aim of Study**

The aim of this study was to investigate the Effects of Ethanolic extract of *P. thonningii* (schumach) Miine- Redh Leaves on Male testicular weight and histo-architecture; using Adult Wistar rats. Specifically, the study determined the histo-architectural changes in seminiferous tubules, epididymis and vas deference of male wistar rats fed with ethanolic extract of *P. thonningii*

### **Materials and Methods**

#### **Location of Study**

This study was conducted at the Department of Anatomy and Cell Biology, faculty of Basic Medical Sciences, Delta State University, Abraka, Delta State, Nigeria. The experimental rats were obtained from and bred in the Animal House of the Faculty of Basic Medical Sciences, Delta State University. Two (2) weeks period of acclimatization was allowed for the animals' acclimatization before commencement of experiment. During the acclimatization period, the rats had free and continuous access to normal rat chow and clean drinking water. The rats used for the study weighted between 160 to 180 grams.

#### **Research Design**

The research design for current study was experimental. A total of forty (40) albino male wistar rats were randomly divided into four (4) groups of five rats each;

- Group 1 = Normal Control rats (n=5)
- Group 2 = Fed with 500mg/Kg of ethanolic leaf extract of *P. thonningii* for 14 days (n = 5)
- Group 3 = Fed with 1000mg/Kg of ethanolic leaf extract of *P. thonningii* for 14 days (n = 5)
- Group 4 = Fed with 1200mg/Kg of ethanolic leaf extract of *P. thonningii* for 14 days (n=5)

The choice of these concentrations of ethanolic extract of *P. thonningii* was based on the knowledge that the LD<sub>50</sub> of *P. thonningii* has been estimated to be 5000 mg/kg body weight in rats [20]. Therefore, the three different concentrations of the plant extract were administered at separate doses below 5000 mg/kg body weight. The gradation in concentration was aimed at inducing graded dose dependent changes in the male testicular weight and histo-architecture, following administration of *P. thonningii* extract and because previous work has been done with lower concentrations.

### **Ethical Considerations**

Animals used in this study were handled according to standard protocols for the use of laboratory animals (National Institute of Health USA Public Health Service Policy on Humane and Use of Laboratory animals, 2002). Ethical approval was sought from and granted by the Research Ethics Committee of the Faculty of Basic Medical Sciences, Delta State University, Abraka, Delta State with REF No. REC/FBMS/DELSU/18/34

### **Animal Treatment**

Forty (40) adult male Wistar rats of comparable age of 10 to 12 weeks (160-180g) were used for this study. Each group was maintained under standard environmental and uniform husbandry conditions of light (12 h light and 12 h darkness) and ambient room temperature (28 – 30°C) and fed with grower's mash produced by Bendel Feeds and Flour Mills Limited. The feed

and drinking water was provided *ad libitum*. The experimental procedures were carried out in Department of Human Anatomy and Cell Biology Laboratory, Delta State University, Abraka.

### **Plant Identification and Collection**

Fresh leaves of *P. thonningii* were collected from Sabongida Ora, Edo State Nigeria. The plant was identified and authenticated by Botanist Dr. Erhenhi A.H, of the Department of Botany, Delta State University Abraka, Delta State and was kept in the Department Hebarium

### **Extraction Procedure**

The leaves of *P. thonningii* was collected at once in the month of march 2018 and air dried for fourteen (14) days, the dried leaves which were brown in color was pulverized to coarse powder by blender machine. The powdered form of the plant leaves were weighed and recorded as 3.597/ 3.60 Kg and 2.17kg was weighed out and used for the experiment. This was dissolved in 6979.7ml of 70% ethanol for 24 hours to achieve maximum extraction. The solution was filtered using using a plastic bucket and a white cloth. The cloth was placed over the bucket and the solution was collected into the bucket while the residual particles in the cloth was removed and discarded. The filtrate was then placed in conical flask where it was further filtered using a Buchner funnel apparatus and Whatman No.1 filter paper. The Buchner funnel was connected to a vacuum pump for filtration. After this was done, the extract was evaporated using a beaker in the water bath at 40<sup>0</sup>C to obtain a solvent free extract, which was in solid form and dark brown in colour. The extract was stored in a thermocool refridgerator at 4°C. This was done in pharmaceutical technology Research Laboratory with the assistance of the lab technician in the Department of Pharmacognosy, Faculty of Pharmacy, Delta State University, Abraka.

### **Preparation Stock Solution**

Stock solution of 50mg/ml was prepared from the plant extract (i.e. solvent free extract). From the extract, 100g of the extract was measured out using electronic weighing balance and the stock solution was prepared by dissolving the extract in distilled water using the following calculation

For every 100g of extract,

$$\text{Converting g to mg: } 100 \text{ g} = 100 \times 1000 = 100,000\text{mg}$$

$$\frac{100,000}{X} = 50\text{mg/ml}$$

Where x is the amount of water

$$X = \frac{100,000}{50} = 2000\text{ml}$$

Therefore, 100g of extract was dissolved in 2000ml of distilled water

For 30g of extract,

Converting g to mg:  $30\text{g} = 30 \times 1000 = 30,000\text{mg}$

Concentration of extract in 50mg/ml

$$\frac{30,000}{x} = 50\text{mg/ml}$$

Where x is the amount of the water

$$x = \frac{30000}{50} = 600\text{ml}$$

Therefore 130g of solvent free extract was dissolved in 2,600 ml of water and stored in the refrigerator. At the time of administration, the dosage administered to each Wistar rat was calculated and administered to the animal.

### **Dosage calculation**

Dosage calculation and preparation of stock solution of crude plant extract for experimental animals. After the concentration of the crude extract, it was kept in the refrigerator and at the time of use, the dose to be administered to each animal was calculated using the body weight of the animal. This was done using the formular for Guidelines on dosage calculation and stock solution preparation in experimental animal studies described by Erhirhie *et al.*, 2014 [21].

### **Dosage calculation for the animals**

Body weight of animal = 165 g

Dosage in mg =  $\frac{\text{Body Weigth of Animal (g)} \times \text{dose (mg)}}{1000\text{g}}$

Dosage in mg =  $\frac{165\text{g} \times 500 \text{ (mg)}}{1000\text{g}} = 82.5\text{mg}$ .

Stock solution was calculated to be 50mg/ml

$$\begin{aligned}
 &\text{Therefore, } 50\text{mg} \longrightarrow 1\text{ml} \\
 &\quad 82.5\text{mg} \longrightarrow X\text{ml} \\
 X &= \frac{82.5}{50} \times 1 = 1.65\text{ml}
 \end{aligned}$$

Therefore, for animal weighing 165g was administered with 1.6 ml of the extract.

#### Dosage Administration

*P. thonningii* ethanolic leaf extract were administered at separate doses in this study were 500 mg/kg, 1000 mg/kg and 1200 mg/kg for 14 days, 28 days and 45 days respectively before the animals were sacrificed. The different concentrations were administered orally via oral cannula. The choice of the separate doses of *P. thonningii* was based on previous studies which have shown anatomical and physiological changes following administration of 250 mg/kg [22] and 400 mg/Kg.bw [18]. The separate doses of 500 mg/Kg, 1000 mg/Kg and 1200 mg/Kg were calculated as 10%, 20% and 24% of LD<sub>50</sub> (5000 mg/Kg) of *P. thonningii*

#### Collection of Samples

The rats were sacrificed by cervical dislocation. The rats were dissected and internal organs exposed. Blood samples were first collected into plain bottles via cardiac puncture, and were taken immediately for hormonal assay (Testosterone, Follicle Stimulating Hormone and Luteinizing Hormone) was done. The abdomen and scrotum of the rats were incised, the testes were removed from the scrotum. The caudal and caput section of epididymis of the experimental rats and control animals were separated and then the semen was placed immediately on the slides and read under the light microscope for semen analysis. Slides of the seminiferous epithelium, vas deferens and epididymis, were made separately and studied. The right testes were harvested for histomorphometric analysis while the left testes were harvested for biometric analysis.

#### Testicular Weight Measurement

After sacrificing and dissecting the rats, the weight of the left testis was measured using an electronic sensitive analysis balance (Gallenkomp FA2104A) and recorded.

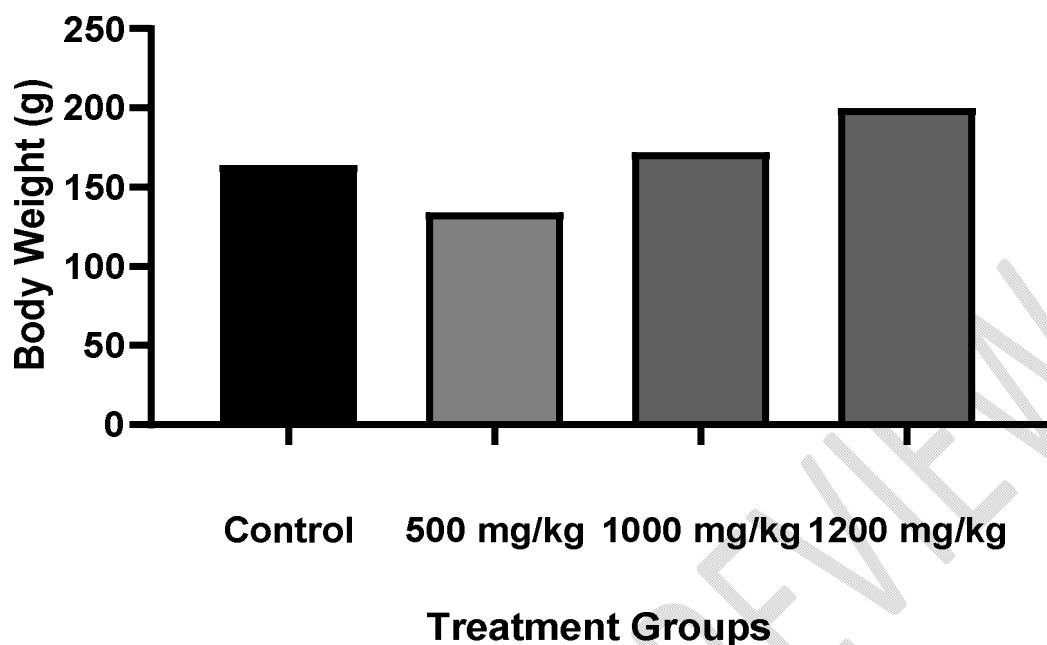
#### Preparation of Tissues for Histological Analysis

The tissue of the seminiferous epithelium, vas deference and epididymis, were fixed in Bouin (75% saturated picric acid, 25% formaldehyde, 5% glacial acetic acid) for 24hr and then transferred to a container with 70% ethanol. After that, dehydration was done by the removal of inherent water content of a given specimen of tissue in a gradual way, by placing in alcohol in the following way: 70% alcohol for 2 hours; 90% alcohol for 2 hours; 95% alcohol for 1 hour; Absolute alcohol - 2 changes for 2 ½ hours and Absolute alcohol overnight. Clearing was later done by using two changes of xylene for 1 ½ hour each. The tissues were then dropped in three changes of paraffin wax for 1 hour each, the aim was to enable the paraffin wax permeates the tissue that is to fill up the vacuoles left by dehydration. The infiltrated tissues were then positioned in molten paraffin wax and left until they become solidified. After solidification, the tissues were sliced into blocks of tissues which have been held firmly in position by the paraffin wax. The tissues were then sectioned with the aid of a microtome at a precise thickness of 3 microns. The sectioned tissue were then stained with haematoxylin and eosin (H and E) stain. Photomicrograph showing histological details of the testes, epididymis and vas deference were obtained by photomicrography using a microscope with a digital camera to obtain micrographs for both the control and experimental at the Department of Human Anatomy and Cell Biology, Delta State University, Abraka, Delta State.

## **Results**

### **Effects of ethanolic leaf extract of *Piliostigma thonningii* on Percentage Change in Body Weight**

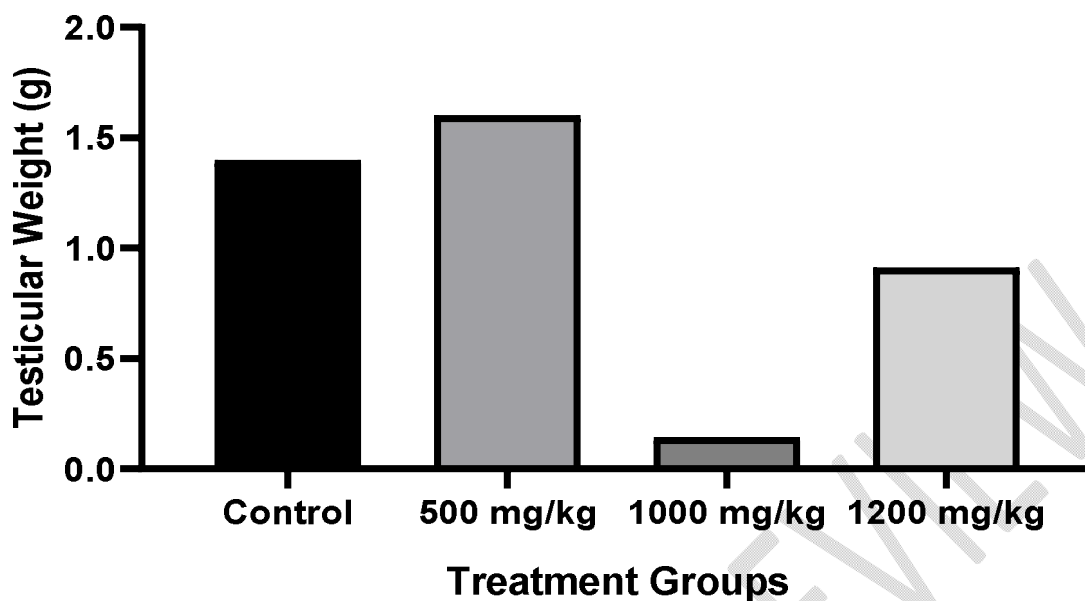
Data shows that *P. thonningii* caused significant ( $p < 0.05$ ) decrease in percentage change in body weight except for rats treated with 500mg/kg *P. thonningii*. Following 14 days administration of 1000 mg/kg and 1200 mg/kg of *P. thonningii*, a significant ( $p < 0.05$ ) increase was observed in percentage change in body weight for rats when compared with control (figure I).



**Figure 1: Effects of Ethanolic leaf extract of *P. thonningii* on Percentage Change in Body Weight**

**Effects of ethanolic leaf extract of *Piliostigma thonningii* on Testicular Weight**

This aspect of the study showed the changes in testicular weight of albino Wistar rats treated with *P. thonningii* ethanolic leaf extract. Here, *P. thonningii* caused a significant ( $p < 0.05$ ) decrease in testicular weight of the male rats. This decrease was observed in rats treated with 1200mg/kg *P. thonningii* for 14 days as compared with control



**Figure 2. Effects of Ethanolic leaf extract of *Piliostigma thonningii* on Testicular Weight**

#### **Effects of *Piliostigma thonningii* Ethanolic Leaf Extract on the Histology of Epididymis**

This experiment also showed the changes in the histology of epididymis of albino Wistar rats. Figure 3 shows normal histology of the epididymis. The epididymis contained large number of matured sperm cells.

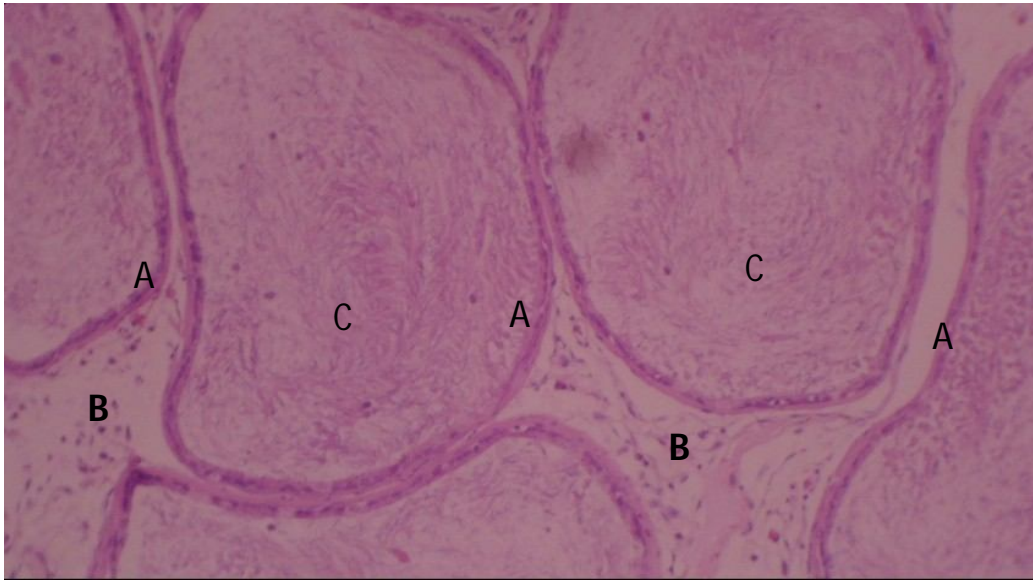
Fig 4 showed the changes in the histology of epididymis of albino Wistar rats. It was observed that administration of 500 mg/kg of *P. thonningii* caused active interstitial congestion. The Epididymis also contained large amount of matured sperm cells.

Fig 5 showed the changes in the histology of epididymis of albino Wistar rats. It shows the presence of plump fibroblast, suggesting histological alterations following 14 days of 1000 mg/kg *P. thonningii* administration

Fig 6 showed the changes in the histology of epididymis of albino Wistar rats treated with 1000 mg/kg *P. thonningii* for 14 days. It was observed that 1000 mg/kg *P. thonningii* caused epididymal changes. Plump fibroblast were also present in the Epididymis despite the presence of large sperm cells.

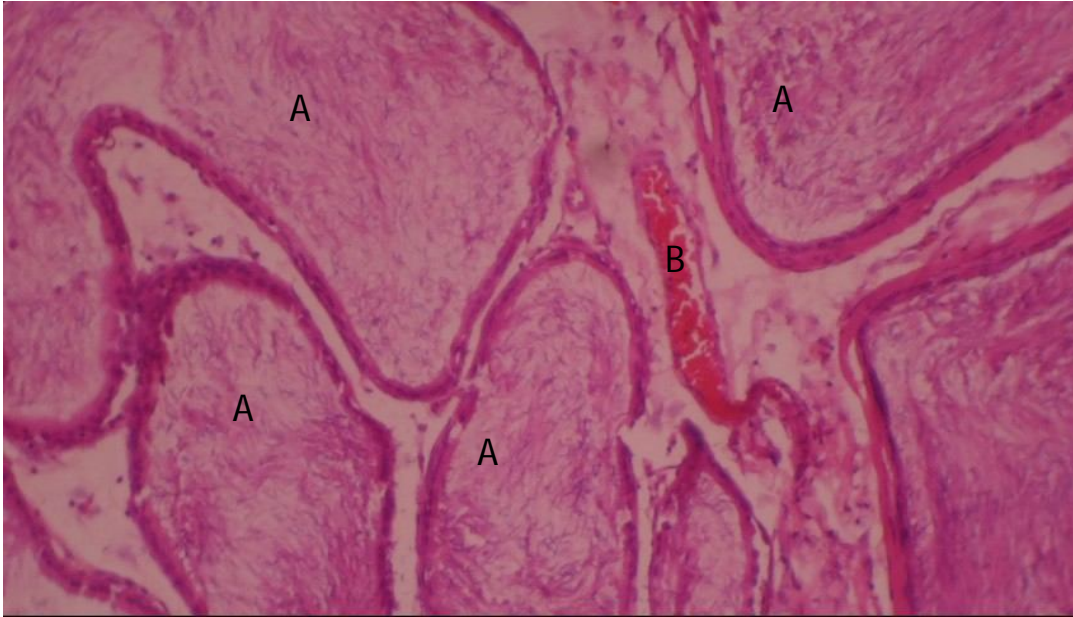Fig 7 showed the changes in the histology of epididymis of albino Wistar rats treated with 500 mg/kg *P. thonningii*. Findings from the study showed that 1000 mg/kg of *Piliostigma thonningii* caused alterations in the histology of epididymis by causing moderate interstitial congestion.

This epididymal modifications were observed to be more severe when compared to the mild interstitial congestion caused by 500 mg/kg *P. thonningii* for 14 days



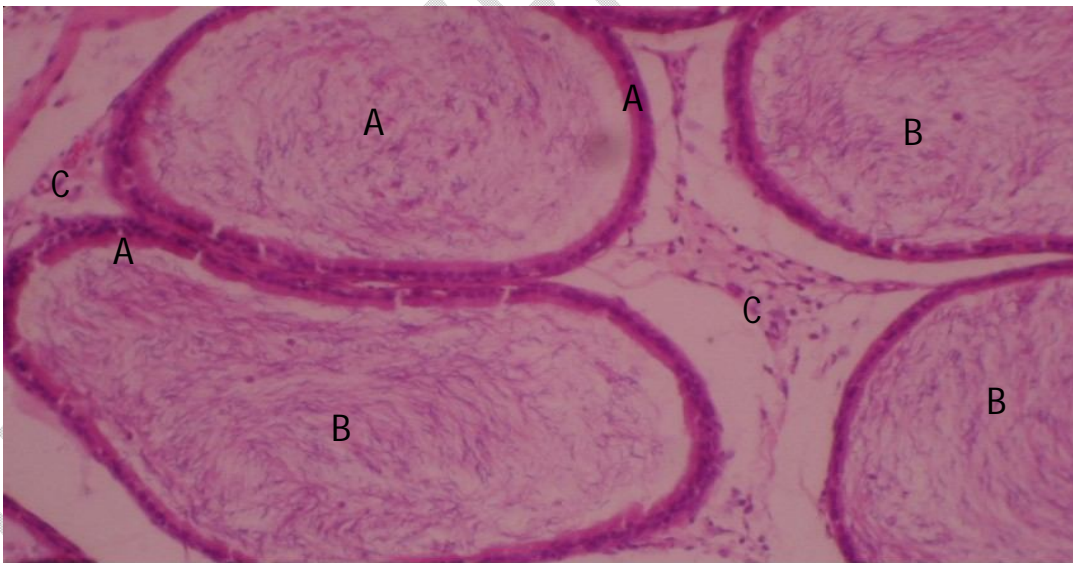
**Fig 3. Histology of Epididymis for Control Rats**

*Control: Rat epididymis composed of A, tubules lined by low columnar epithelium, B, separated by loose connective tissue interstitium and C, packed with mature spermatozoa (H&E x 100)*



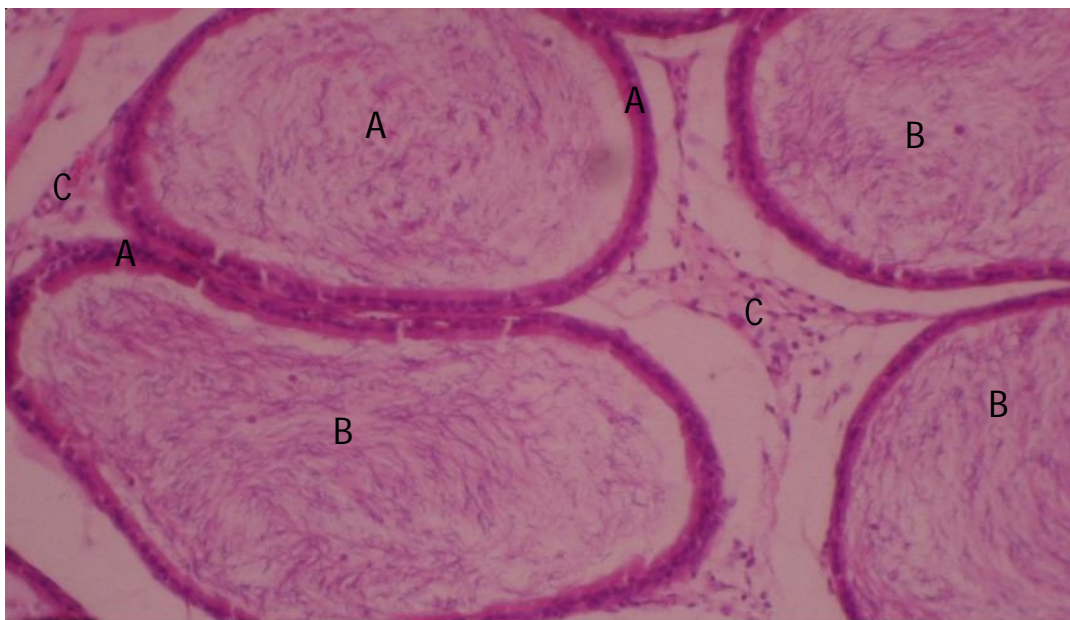
**Fig 4: Histology of Epididymis for Rats treated with 500 mg/kg *P. thonningii* Ethanolic Leaf Extract for 14 Days**

*Rat epididymis showing A, tubules packed with mature spermatozoa and B, mild active interstitial congestion (H & E x 100)*



**Fig 5: Histology of Epididymis for Rats treated with 1000 mg/kg *P. thonningii* Ethanolic leaf extract for 14 Days**

*Rat epididymis showing: A, normal tubules packed with B, mature sperm cells and C, interstitial connective tissue with plump fibroblasts (H & E x 100)*



**Fig 6: Histology of Epididymis for Rats treated with 1200 mg/kg *P. thonningii* Ethanollic Leaf Extract for 14 Days**

*Rat epididymis showing: A, normal tubules packed with B, mature sperm cells and C, interstitial connective tissue with plump fibroblasts (H&E x 100)*

#### **Effects of *Piliostigma thonningii* on the Histology of Vas Deferens of albino Wistar rats**

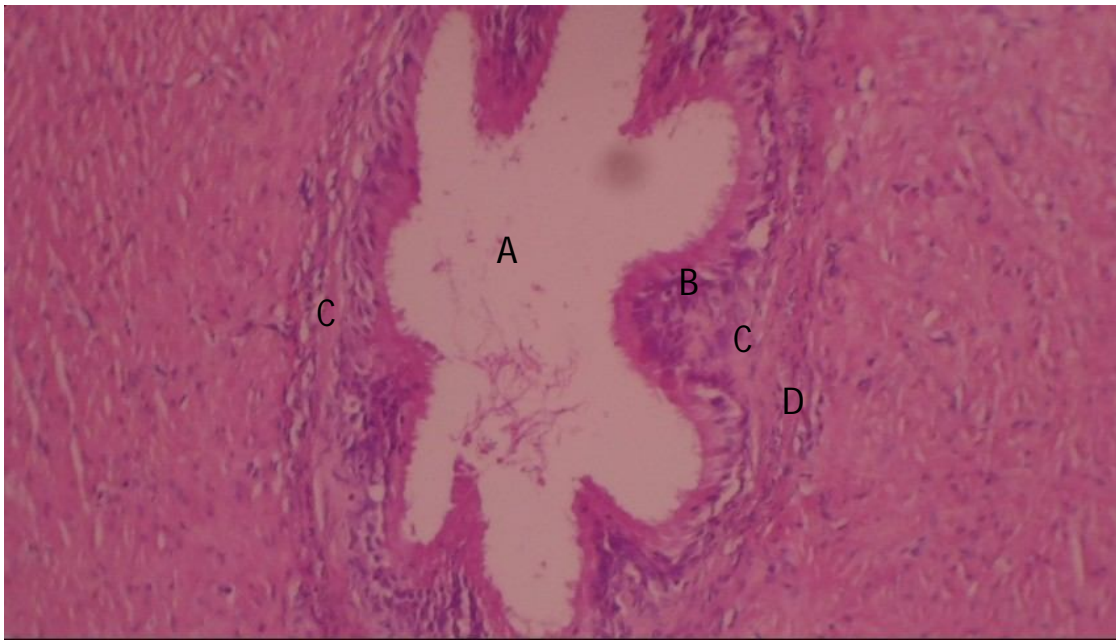
The changes in the histology of vas deferens of albino Wistar rats are shown below. A Normal histology of the vas deferens was observed in control group. Fig 7 showed normal lumen, pseudostratified columnar epithelium, laminar propria and muscle coat.

Fig 8 showed the changes in the histology of vas deferens of albino Wistar rats treated with 500mg/Kg *Piliostigma thonningii* for 14 Days. Administration of 500 mg/Kg *Piliostigma thonningii* for 14 Days did not cause any tissue derangement as normal ductal architecture and lumen containing spermatozoa was observed.

Fig 9 showed the changes in the histology of vas deferens of albino Wistar rats treated with 1000 mg/Kg *Piliostigma thonningii* for 14 Days. Similarly, 14 days administration of 1000 mg/Kg *Piliostigma thonningii* did not alter the histological features of the vas deferens as normal ductal system was observed along with the presence of matured spermatozoa in the lumen of the vas deferens.

The changes in the histology of testes of albino Wistar rats treated with 1200 mg/Kg *Piliostigma thonningii* for 14 Days is shown in fig 10. Despite the administration of 1200 mg/Kg *Piliostigma thonningii* for 14 days, no histological assault induced. Result shows that 14 days

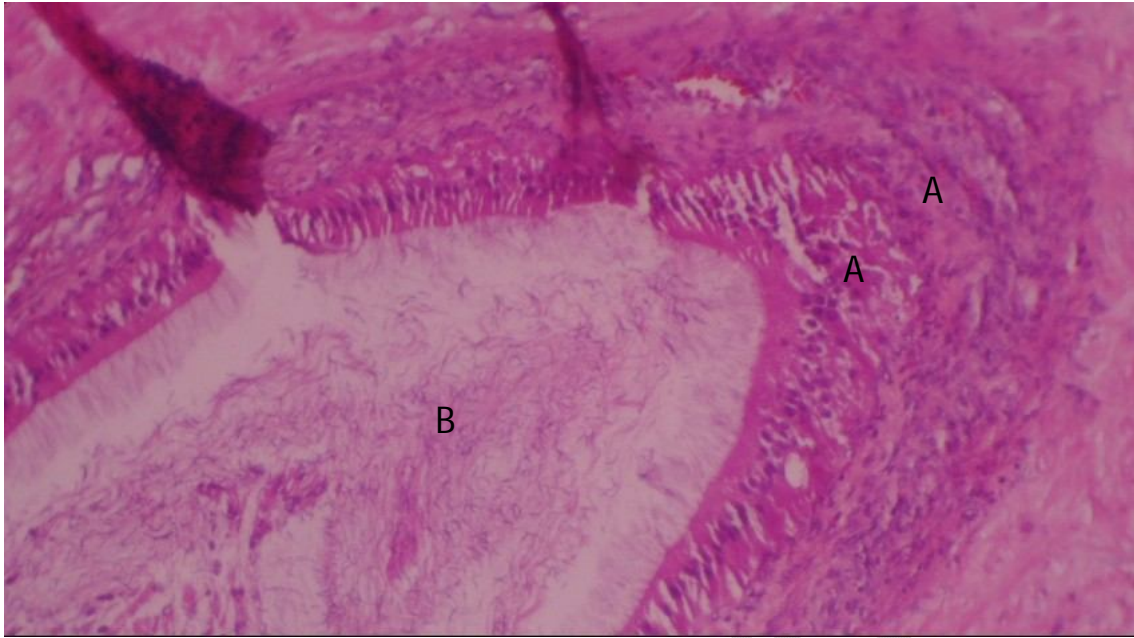
treatment of *Piliostigma thonningii* irrespective of the dose applied in this study does not cause damaging effect to the vas deferens



**Fig 7. Histology of vas Deferens for Control Rats**

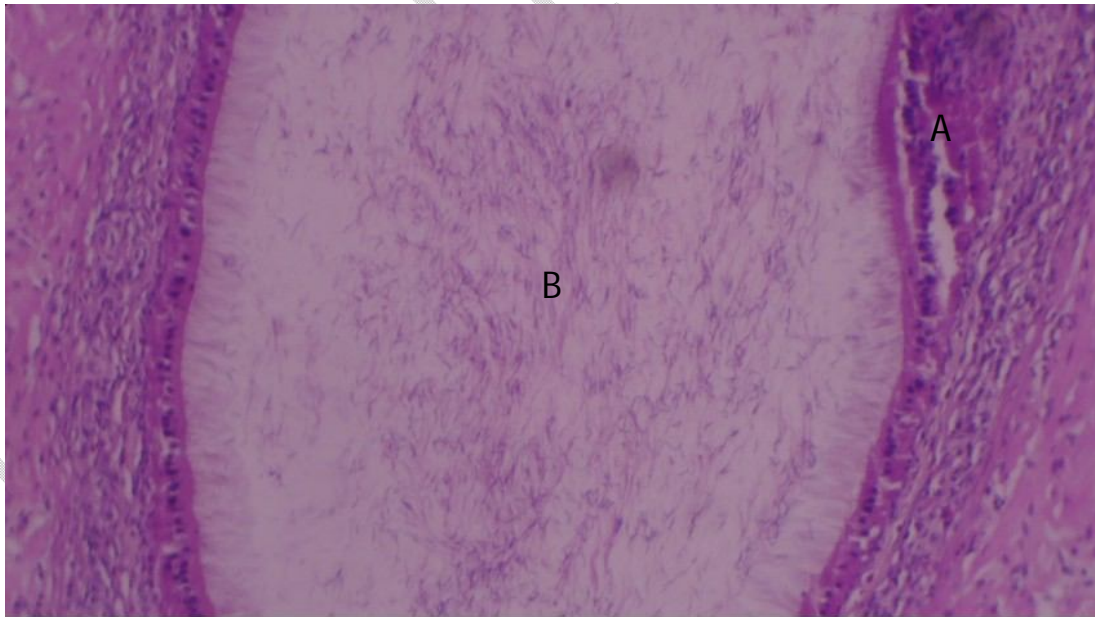
*Rat vas deferens composed of: A, lumen, B, Pseudostratified columnar epithelium, C, lamina propria and D muscle coat (H&E x 100)*

UNDER PUBLICATION



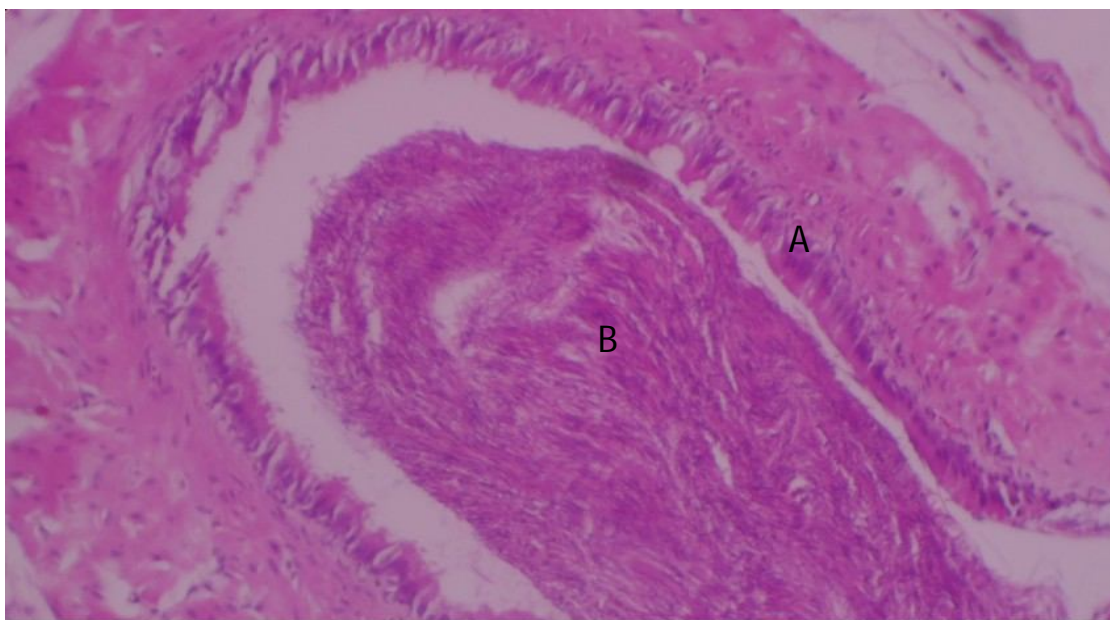
**Fig 8: Histology of vas Deferens for Rats treated with 500mg/kg *P. thonningii* Ethanolic leaf extract for 14 Days**

*Rat vas deferens showing: A, normal ductal architecture and B, patent lumen containing spermatozoa (H&E x 100)*



**Fig 9: Histology of vas Deferens for Rats treated with 1000mg/Kg *Piliostigma thonningii* Ethanolic leaf extract for 14 Days**

*Rat vas deferens showing: A, normal duct wall surrounding B, a lumen containing spermatozoa (H&E x 100)*



**Fig 10: Histology of vas Deferens for Rats treated with 1200 mg/kg *Piliostigma thonningii* ethanolic leaf extract for 14 Days**

*Rat vas deferens given high dose extract for 2 weeks showing A, normal duct wall surrounding, B, a lumen packed with spermatozoa (H&E x 100)*

### **Discussion**

This study showed the effects of ethanolic extract of *Piliostigma thonningii* leaf on the histology and testicular weight of the male reproductive organ in adult male wistar rats. From the results, the sperm count was seen to decrease in 14 days administration, then increased, speculatively because of hyperplasia in the leydeg cells which sent positive feedback response to the anterior pituitary glands. This effect may be traceable to the result of some potent phytochemical constituents in the ethanol extract of *Piliostigma thonningii*. Phytochemical substances such as alkaloids have been shown to cause male infertility, this assertion was confirmed by previous finding from Yakubu *et al* (2007) showing that alkaloid extracted from different plant extracts have caused the reduction of total protein content of the testes of animals thereby reducing the synthetic activities of testes [23]. Figures from this study also showed that *Piliostigma thonningii* caused alterations to the epididymis through mild to moderate active congestion despite the presence of matured sperm cells. Epididymis is known to secrete certain proteins than enhances the motility of sperm cells. This could also explain the reduction in the percentage of sperm with progressive motility. The reduced numbers of spermatozoa, decreased

motility, sperm viability and/or increased number of malformed spermatozoa are the leading causes of disturbed fertility or infertility [24].

Another possible antifertility effect of *P. thonningii* on the seminiferous tubules, interstitial cells of Leydig and tissues of the epididymis could be due to the dose administration. The gonadotoxic effects of *P. thonningii* is attributed to the higher concentration of the plant extract used in this study as compared to findings of previous studies where minimal toxic effects were recorded. Asuzu and Nwaehujor (2013) and Ighodaro *et al.* (2012) showed that *P. thonningii* improved the testicular function and histomorphological features, which is in contrast to findings of this study [18, 25]. The previously acclaimed studies had also administered *P. thonningii* for shorter duration of 14 days or less, which could likely induce cytotoxic effects on the tissues of both testes and epididymis.

Another antifertility inducing component of *P. thonningii* is saponins which has been reported to have abortifacient and anti-implantation properties in rodents [26]. Saponins have been reported to affect cell membranes by forming pores, and they also exert a lytic action on erythrocytes membranes [27]. The vascular congestion and hyperplasia showed that the extract may have affected membrane of some cells. Eberstadt and Shah (2011) showed that saponin from aqueous extract of *P. thonningii* at 250 mg/kg, 500 mg/kg and 1000 mg/kg to male Wistar rats also affect fertility by degeneration of Leydig cells and distortion of spermatogenic cells and decrease in sperm count, sperm motility, sperm morphology and serum testosterone levels [28].

## **Conclusion**

Findings from this study showed that ethanolic leaf extract of *P. thonningii* administered at 500mg/Kg, 1000mg/Kg and 1200mg/Kg for 14 days has antifertility effects. Data from this study also showed that *P. thonningii* pose a substantial threat to male reproductive health. Similar studies should be carried out to assess if similar antifertility effect of *P. thonningii* is observed in female reproductive structure and functions. There is also need for further investigation on the effects of ethanolic extract of *P. thonningii* on male reproductive structures and functions with smaller doses as previous studies have shown that *P. thonningii* administration in doses much lower than what was applied in this study have beneficial effects on other systems and organs.

## References

1. Ogbuewu, I.P., Unamba-Oparah, I.C., Odoemenam, V.U., Etuk, I.F. and Okoli, I.C. (2011). The potentiality of medicinal plants as the source of new contraceptive principles in males. *North Am J Med Sci.*, 3(6):255–263.
2. Dennehy, C. E. and Tsourounis, (2004). *Basic and Clinical Pharmacology*. McGraw Hill, 9, 1076-1080
3. Awiti, J.O. (2014). Poverty and health care demand in Kenya. *BMC Health Serv Res.*, 22(14):560.
4. Mee, P., Wagner, R.G., Gómez-Olivé, F.X., Kabudula, C., Kahn, K., Madhavan, S., Collinson, M., Byass, P. and Tollman, S.M. (2014). Changing use of traditional healthcare amongst those dying of HIV related disease and TB in rural South Africa from 2003 - 2011: a retrospective cohort study. *BMC Complement Altern Med.*, 14:504.
5. Grabley S. and Sattler I. (2003). *Natural products for lead identification: Nature is a valuable resource for providing tools*. In: Hillisch A., Hilgenfeld R. (eds) *Modern Methods of Drug Discovery*. EXS, vol 93. Birkhäuser, Basel
6. O'Brien, K. (2004). Complementary and alternative medicine: the move into mainstream health care. *Clin. Exp. Optom.*, 87: 193 – 194.
7. Leckridge, B.J. (2004). The future of complementary and alternative medicine – models of integration. *Altern. Complement. Med.*, 10:413 – 41.
8. Busia, K. (2005). Medical Provision in Africa – Past and Present. *Phytotherapy Res.*, 9(11): 919-923.
9. Fokunang, C.N., Ndikum, V., Tabi, O.Y., Jiofack, R.B., Ngameni, B. and Guedje, N.M. (2011). Traditional Medicine: past, present and future research and development prospect and integration in the national health system of Cameroon. *Afr J Trad Complement Altern Med.*, 8:284–295
10. Handelsman, D.J. (2000). Hormonal male contraception. *Int J Androl.*, 23:8–12.
11. Igoli, J.O., Ogaji, O.G., Tor-Anyin, T.A., Igboli, N.P. (2005). Traditional Medicine Practice Amongst the Igede People of Nigeria. Part 11. *Afri. J. Trad. Cam.*, 2: 134 – 152.
12. Togola, A., Diallo, D., Dembele, S., Barsett, H. and Paulsen, B.S. (2005). Ethnopharmacological survey of different uses of seven medicinal plants from Mali, (West Africa) in the regions Doila, Kolokani and Siby. *J. Ethnobiol. Ethomed.*, 1: 7.

13. Ibewuike, J.C., Ogungbamila, F.O, Ogundaini, A.O., Okeke, I.N. and Bohlin, L. (1997). Antiinflammatory and antibacterial activities of C - methylflavonols from *Piliostigma thonningii*. *Phytother. Res.*, 11: 281-284.
14. Jimoh, F. O. and Oladiji A. T. (2005). Preliminary studies on *Piliostigma thonningii* seeds: Preliminary analysis, mineral composition and phytochemical screening. *Afr. J. Biotechnol.*, 4: 1439-1442.
15. Orwa-Muta A., Kindt, R., Jamnadass. R. and Simon, A. (2009). A Tree Reference and Selection Guide Version. Agroforestry Database 4.0.
16. Burkill, H. M. (1995). The Useful plant of West Tropical Africa. Royal Botanical Gardens; 2(3):50 – 177.
17. Karioti, A., Skaltsa, H. and Gbolade, A.A. (2007). Constituents of the distilled essential oils of *Citrus reticulata* and *C. paradisi* from Nigeria. *J Essent Oil Res.*, 19:520-2
18. Ighodaro, O. M. and Omole, J. O. (2012). Effects of Nigerian *Piliostigma thonningii* Species Leaf Extract on Lipid Profile in Wistar Rats. *Int. Scholarly Res. Net. ISRN Pharmacol.* 387942: 1 – 4
19. Dasofunjo. K., Nwodo, O. F. C., Ezugwu, H.C., Atunka, E.A. and Onah, L.N. (2018). Impact of oral administration of Ethanol leaf extract of *Piliostigma thonningii* on fertility hormones of male Wistar rats. *Perspectives in Medical Research* 2018; 6(2):16-20
20. Madara, A. A., Ajayi, J. A., Salawu, O. A. and Tijani A. Y. (2010). Anti-malarial activity of ethanolic leaf extract of *Piliostigma thonningii* Schum. (Caesalpiniaceae) in mice infected with *Plasmodium berghei berghei*. *Afr. J. Biotechnol.*, 9(23): 3475-3480
21. Erhirhie, E. O., Ekene, N. E. and Ajaghaku, D. L. (2014). Guidelines on dosage calculation and stock solution preparation in experimental animals' studies. *J. Natural Sci. Res.*, 4(18).
22. Awhin, E. P., Jeroh, E., Anigboro, A.A., and Nwaoroko, R. (2013). Effect of Chronic Consumption of *Piliostigma thonningii* on Activities of Alanine Aminotransferase and Aspartate Aminotransferase in Serum and Liver in *Rattus norvegicus*. *Pakistan J. Biol. Sci.*, 16, 2062-2065.
23. Yakubu MT. Effect of a 60-day oral gavage of a crude alkaloid extract from *Chromolaena odorata* leaves on hormonal and spermatogenic indices of male rats. *J Androl.* 2012 Nov-Dec; 33(6):1199-207
24. Chauhan, N.S. and Dixit, V.K. (2008). Spermatogenesis activity of rhizomes of *Curculigo orchioides gaertn* on male rats. *Int J Appl Res Natl Prod.*, 10:26–31.

25. Asuzu, I.U. and Nwaehujor, C.O. (2013). The Anti-diabetic, Hypolipidemic and Anti-oxidant activities of D-3-O-methylchiroinositol in alloxan-induced diabetic rats. *Hygeia. J. D. Med.*, 5(2): 27-33.
26. Dande, P.R., Bonde, C. and Pandita, N. (2014). Evaluation of saponins from *Sesbania sesban* L. Merr for its antifertility effects in female albino rats. *World J. Pharmacy Pharmaceutical Sci.*, 3:1039-1054.
27. Francis, G., Kerem, Z., Makkar, H.P.S. (2002). The Biological action of saponin in Animal systems: A review. *Br. J. Nutr.*, 88:587-605.
28. Eberstadt, N. and Shah, A. (2011). Fertility decline in the Muslim world: A veritable sea-change, still curiously unnoticed. The American Enterprise Institute Working Paper Series on Development Policy; 7:1-15.

UNDER PEER REVIEW