

Exploring Disease Spectrum of Tuberculous Lymphadenitis

Abstract

Background: Tuberculosis (TB) remains a global health problem with 25% of the world's population infected from the causative agent *Mycobacterium tuberculosis*(MTB). Indian ranks first amongst the eight countries reported to have highest burden of MTB across the globe. TB is categorized into pulmonary and extrapulmonary(EPTB); the most common clinical manifestation of EPTB being tuberculous lymphadenitis(LNTB). LNTB generally occurs due to reactivation of latent infection and cervical lymph nodes are the most common sites.

Objective:The present research work was conducted to explore disease spectrum of LNTB highlighting specific histopathologic features.

Materials and Methods:Twenty-one patients with clinically diagnosed LNTB were included and one lymph node biopsy was obtained from each patient. The formalin-fixed paraffin tissue sections were subjected to standard hematoxylin & eosin staining (H & E stain) to understand different histologic features of LNTB.

Results:LNTB displayed a disease spectrum which can be categorized into four broad categories as: 1. Early granulomas(n=2); 2. Non-caseating granulomas(n=12); 3. Caseating granulomas(n=6); 4. Massive extensive caseation without Langhan's giant cells(n=1).The well-formed, non-necrotic, epithelioid cell granulomas were prominent feature of LNTB in our study.

Conclusion: The above study supports the existence of a disease spectrum of LNTB with histologic features ranging from early granulomas to massive caseation necrosis. This can aid clinicians for better diagnosis of LNTB so to aid for early detection and an appropriate treatment of the disease.

Introduction

According to World Health Organization (WHO) tuberculosis (TB) is one of the top ten causes of death from a single infectious agent across globe. Approximately 25% of the world's population is infected with its causative organism known as *Mycobacterium tuberculosis* (MTB).¹ Recent estimates suggest that India ranks first amongst the eight countries reported to have a high burden of MTB in the world.²

Extrapulmonary tuberculosis (EPTB) accounted for 16% of the all TB cases in 2019. In India, tuberculous lymphadenitis also called as lymph node TB (LNTB) is the most common form of EPTB roughly constituting 35% of all EPTB cases.³

Often, TB is characterized by two states: active disease and latent infection(LTBI). In latent TB the granulomas contain low quantity of organisms therefore minimum pathology, with no symptomatology of the disease and MTB is generally not culturable from routine samples. The active TB is implicated to have a large number of organisms with poor immunologic response leading to marked pathology and symptomatic presentation with MTB is usually culturable. In pulmonary TB, pathogenesis is depicted by cavitation, allowing extracellular bacillary replication in an oxygen-rich environment. This leads to a substantial increase in bacillary load

within respiratory secretions, causing microscopic visualization of acid fast bacilli (smear positive) and spread of the infection.⁴

The most common extrapulmonary manifestation of TB is LNTB which generally occurs due to reactivation of latent infection. Cervical lymph nodes are the most common sites of LNTB infection but various other benign and malignant conditions imitate the disease (e.g. non-specific hyperplasia, non-TB mycobacteria, sarcoidosis, malignant lymphomas, and metastatic carcinomas). This can be a diagnostic challenge for clinicians who are unfamiliar with this manifestation of TB. Common symptoms of TB such as fever, fatigue, weight loss, and night sweats are often less or absent, and the clinical presentation is usually identical from lymphadenitis caused by other conditions. Patients from high TB incidence regions, with extended lymphadenopathy, and with or without systemic symptoms should be investigated for LNTB.⁵

We propose that LNTB can be more precisely represented as a spectrum of disease states with specific morphological changes associated with this extrapulmonary form of the disease.

Materials and Methods

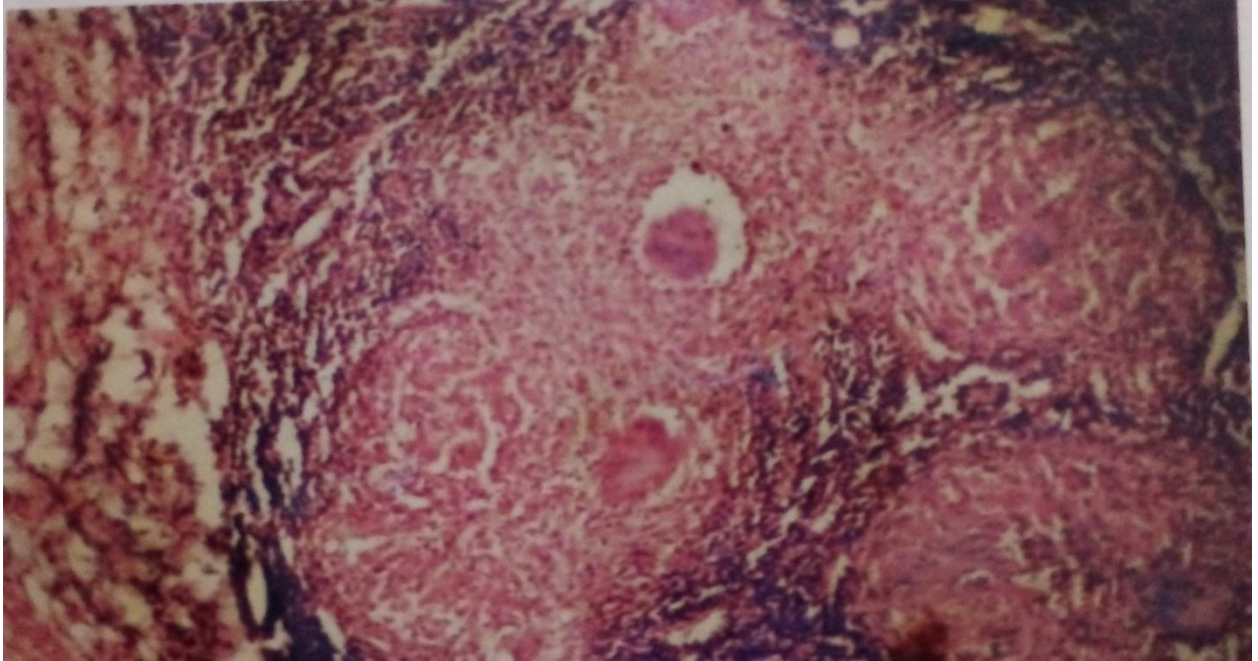
The study was conducted in Department of Pathology, Sarojini Naidu Medical College, Agra, Uttar Pradesh, India. Twenty one patients of clinically diagnosed LNTB, from August 2004 to August 2005 were reviewed for histopathological features. Only hematoxylin and eosin (H&E) preparations were used for histologic examination. No other special stains were used.

Results

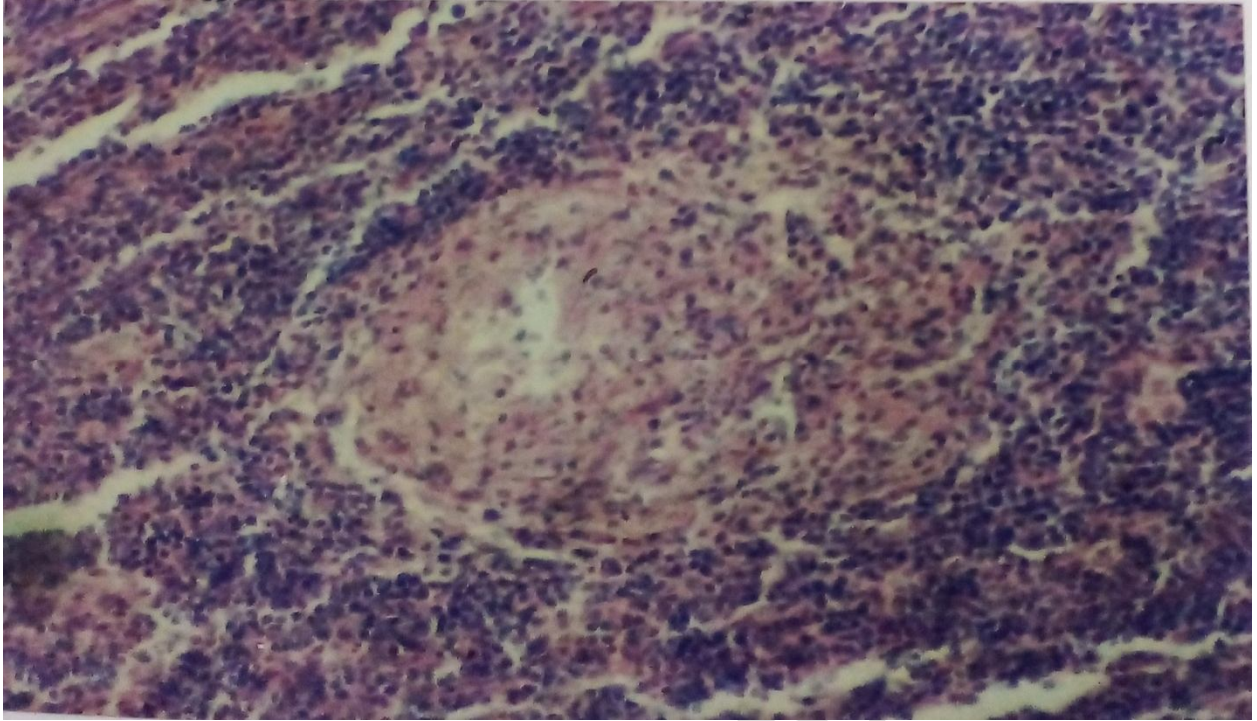
In our study the histopathological spectrum of LNTB showed four different types of morphological features of granulomatous inflammation: 1. Early granulomas (n=2); 2. Non-caseating granulomas (n=12), 3. Caseating granulomas (n=6), 4. Extensive/massive caseation necrosis (n=1).

The histologic pattern of LNTB presented a pleomorphic picture ranging from well-organized, non-necrotic, epithelioid cell granuloma to a poorly organized necrotic granulomas with macrophages and very few epithelioid cells. The granuloma pathology showed macrophages, epithelioid cells (differentiated macrophages) and multinucleated giant cells (also known as Langhans giant cells), surrounded by T lymphocytes. Caseous granulomas were divided into three zones: 1. an outer rim of lymphocytes of the T- and B-cell types, 2. transition zone of necrotic material interspersed with epithelioid macrophages, 3. a central acellular necrotic region. **(Pictures 1-7).**

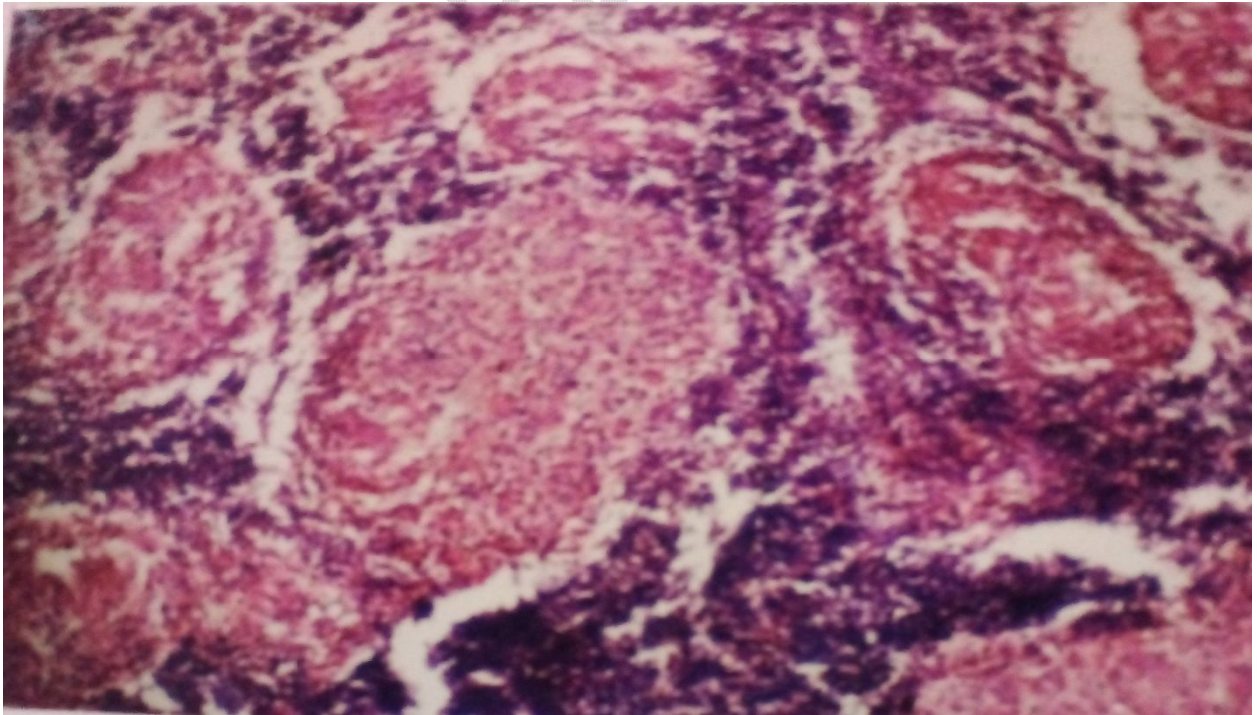
Picture 1 Granulomatous Lymphadenitis showing Langhan's Giant Cells (H&E 8X10 Magnification)



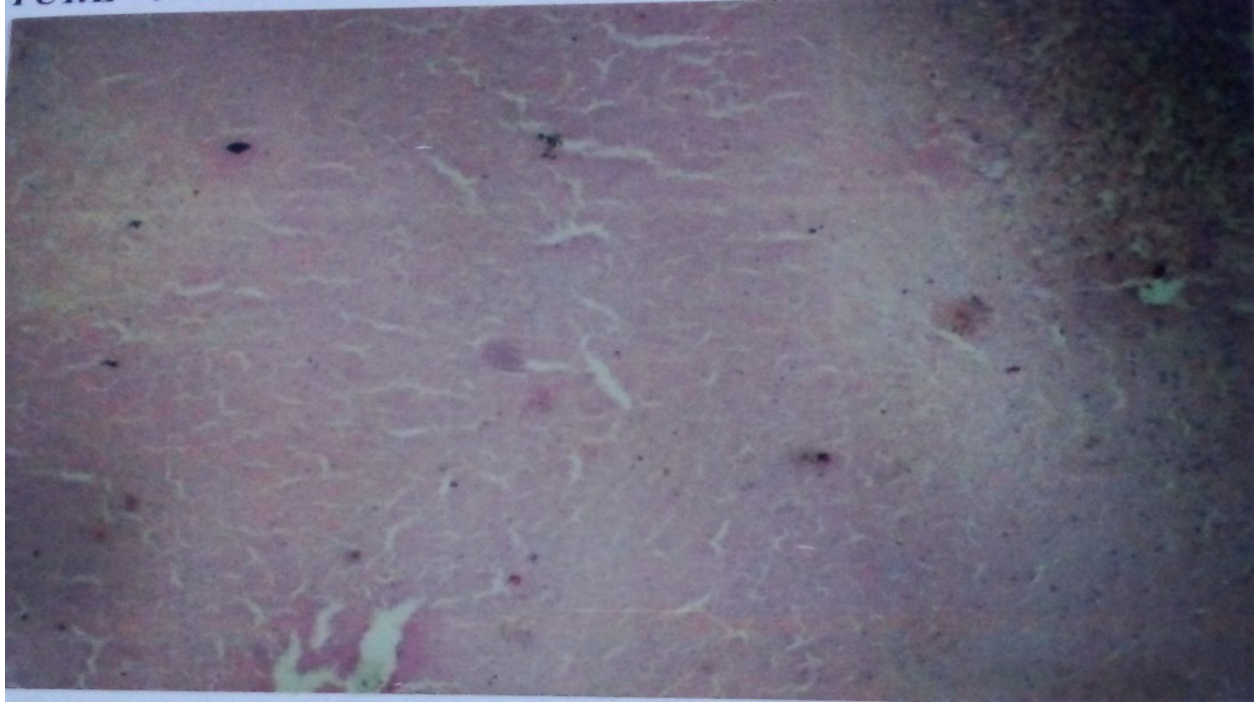Picture 2 Only Epithelioid Cell Granulomas (H&E 8X 20 Magnification)



Picture 3 Non-Caseating Granulomas (H&E 8X10 Magnification)



Picture 4 Massive/Extensive Caseation; No Langhan's Giant Cells (H&E 8X10 Magnification)



Discussion

In the present study, the disease spectrum of LNTB depicted four types of histological characteristics: early granulomas, non-caseating granulomas, caseating granulomas, and massive/extensive caseation with no Langhan's giant cells. Granulomatous lymphadenitis with Langhan's giant cells was one of the main histologic features present in our study. The granulomas were of two types: 1. well-organized granulomas with central group of epithelioid histiocytes, Langhan's giant cells surrounded by a peripheral layer of lymphocytes and fibrous tissue; 2. poorly organized necrotic granulomas scattered with lymphocytes, histiocytes. Our findings are consistent with Ahmed *etal*⁶ who also reported well-and poorly-organized granulomas in 100 LNTB patients in a retrospective study in Yemen. The primary histological features of LNTB were giant cell (88%), caseation necrosis (84%), epithelioid cells (80%), granuloma and caseation (68%), lymphocytes (31%), and histiocytes (4%).⁶ Similar findings of well- and poorly- organized granulomas in LNTB have been reported by Huda *etal*⁷ in 50 patients in Bangladesh also. Varying degree of caseation necrosis was also observed in this study showing focal caseation necrosis (18% of patients), moderate caseation necrosis (54% of patients) and extensive caseation necrosis (28% of patients).⁷

In our study, the major histological feature was non-caseating granulomas (57%; 12/21) followed by caseating granulomas (28%; 6/21).The presence of early granulomas and extensive/massive caseation necrosis was observed in 10% and 5% cases, respectively in our study. A plethora of

published literature has also documented almost similar histologic features in LNTB with a varied spectrum of the disease thus supporting the findings of our study.

Jayalakshmi *etal*⁸ reported epithelioid cell granulomas in 100% of cases with central caseation necrosis in 96.6% of cases. Agarwal *etal*⁹ reported caseous necrosis as the most prominent feature in lymph node biopsies even in the absence of granulomas or in the presence of poorly formed ones in LNTB patients present with human immunodeficiency virus (HIV) infection. We also reported caseation necrosis as a primary finding in our study. Ramanathan *etal*¹⁰ described four histologic stages of disease spectrum in lymph node biopsies of Indian patients as **hyperplastic**: a well-organized epithelioid cell granuloma with very slight necrosis (22.4%), **reactive**: a well-organized epithelioid cell granuloma with macrophages, lymphocytes and plasma cells and eosinophilic caseation necrosis (54.3%), **hyporeactive**: a poorly-formed granuloma with macrophages, immature epithelioid cells, lymphocytes, plasma cells and basophilic caseation necrosis, and **nonreactive**: unorganized granuloma with macrophages, lymphocytes, plasma cells and non-caseating necrosis (3.6%). Histopathological results in a study conducted on 111 lymph node biopsies by Sharif *etal*¹¹ were divided into **five stages**: necrotizing granulomatous inflammation (60%); 2. chronic caseating granulomatous lymphadenitis(24%); 3. reactive lymphoid hyperplasia(6%); 4. cold abscess(6%); 5. others (atypical lymphoid infiltrate, repeat biopsy, nonspecific lymphadenitis, necrotizing histiocytic lymphadenitis) (4%). Similarly, Tahseen *etal*¹² reported four stages of LNTB disease spectrum in lymph node biopsies: (i) **HP-1**: well-organized granulomas without necrosis; (ii) **HP-2**: well-organized granulomas with caseous necrosis (iii) **HP-3**: poorly (ill)-organized granulomas with necrosis (iv) **HP-4**: caseous necrosis only with no granuloma. Histopathological diagnosis was considered as integral tool for detecting LNTB and 95 % of cases can be diagnosed with histopathologic diagnosis in combination with molecular methods compared to less than 60% by molecular method alone.¹²

Conclusion

In conclusion, well-formed granuloma is most prominent feature of LNTB with combined variety of other histopathologic features. The disease spectrum can be loosely divided into 4 categories as early granulomas, non-caseating granulomas, caseating granulomas and massive/extensive caseation without Langhan's giant cells.

References

1. Global tuberculosis report 2020. <https://www.who.int/publications/i/item/9789240013131> (Accessed on March 4, 2023).
2. Global tuberculosis report 2022. <https://www.who.int/publications/i/item/9789240013131> (Accessed on March 4, 2023).
3. Shetty, D., Vyas, D. Combination method for the diagnosis of Tuberculous lymphadenitis in high burden settings. *Surg Exp Pathol.* 2022. **5**, 11.
4. Esmail H, Macpherson L, Coussens AK, Houben RMGJ. Mind the gap - Managing tuberculosis across the disease spectrum. *EBioMedicine.* 2022 **78**:103928.

5. Mathiasen VD, Andersen PH, Johansen IS, Lillebaek T, Wejse C. Clinical features of tuberculous lymphadenitis in a low-incidence country. *Int J Infect Dis.* 2020; 98: 366-371.
6. Ahmed HG, Nassar AS, Ginawi I. Screening for tuberculosis and its histological pattern in patients with enlarged lymph node. *Patholog Res Int.* 2011; 2011:417635.
7. Huda MM, Taufiq M, Yusuf, MA, Rahman,MR, Begum F, KamaM. Histopathological Features of Lymph Nodes of Tuberculous Lymphadenitis Patients: Experience of 50 cases in Bangladesh. *Bangladesh Journal of Infectious Diseases.* 2017; 3(2), 40–42.
8. Jayalakshmi P, Malik AK, Soo-Hoo HS. Histopathology of lymph nodal tuberculosis - University Hospital experience. *Malaysian .I Pathol.* 1994; 16(1): 43 – 47.
9. Agarwal L, Agrawal M, Geetha V, Saxena R. Histological features of tubercular lymphadenitis in hiv positive patients. *Adv Cytol Pathol.* 2017; 2(5):150-154.
10. Ramanathan VD, Jawahar MS, Paramasivan CN, Rajaram K, Chandrasekar K, Kumar V, Palanimurugan K, Prabhakar R. A histological spectrum of host responses in tuberculous lymphadenitis. *Indian J Med Res.* 1999;109: 212-20.
11. Sharif N, Ahmed D, Mahmood RT, Qasim Z, Khan SN, Jabbar A, et al. Comparison of different diagnostic modalities for isolation of *Mycobacterium Tuberculosis* among suspected tuberculous lymphadenitis patients. *Braz J Biol.* 2023; [Internet]. 2023;83:e244311.
12. Tahseen S, Ambreen A, Ishtiaq S, Khanzada FM, Safdar N, Sviland L, Mustafa T. The value of histological examination in the diagnosis of tuberculous lymphadenitis in the era of rapid molecular diagnosis. *Sci Rep.* 2022.12(1):8949.