

## **Effect of Dexamethasone Addition to Local Anesthetics in Supraclavicular Brachial Plexus Block**

### **Abstract**

**Background:** The addition of dexamethasone to local anesthetics in supraclavicular brachial plexus block has been studied to evaluate its impact on block onset and duration, potentially enhancing the efficacy of regional anesthesia.

**Objective:** In this study, our main goal is to evaluate the effect of dexamethasone added to local anesthetic on the onset and duration of supraclavicular brachial plexus block.

**Method:** This cross-sectional study was carried out at a tertiary hospital from January 2022 to January 2023. Where 100 adult patients undergoing various orthopaedic surgeries on forearm and around the elbow under supraclavicular brachial plexus block were selected and divided into 2 groups of 50 each. In group A patients received 35 ml of mixture of lignocaine 2%, bupivacaine 0.5% while in group B patients received the same amount of local anaesthetics with dexamethasone (8 mg). The onset of sensory and motor block and duration of analgesia in two groups were compared and development of complications were observed.

**Results:** Both Group A (48%) and Group B (42%), where most of the patients in the research are located, have a median age of 41 years. There were 80% males and 20% females in Group A. There were ninety males and ten females in Group B. There was a statistically significant ( $p < 0.05$ ) early onset of sensory and motor block in group B. The analgesic effect lasted much longer in group B ( $p < 0.001$ ) than in group A. In addition, 45% of group A participants were diagnosed with Horner's syndrome, and 7% had dyspnoea or chest pain. The recurrent laryngeal nerve was blocked in 3% of patients, whereas 2% had insufficient occlusion. In group B, 31% of people experienced Horner's syndrome, and 5% had dyspnoea or chest pain. Two percent of patients had a block of the recurrent laryngeal nerve, with one percent experiencing an inadequate block.

**Conclusion:** Addition of dexamethasone to 1.5% lidocaine with adrenaline in supraclavicular brachial plexus block speeds the onset and prolongs the duration of sensory and motor blockade.

However,

the use of dexamethasone to prolong the effect of local anesthetics is not encouraged. It might be useful in situations when epinephrine use is limited (such as in hypertension or cardiovascular disease).

**Keywords:** dexamethasone, local anesthesia, supraclavicular brachial plexus block

## Introduction

Supraclavicular brachial plexus block is a widely employed regional anesthesia technique for surgeries involving the upper extremity. It provides effective anesthesia and postoperative analgesia while minimizing the risks associated with general anesthesia. In recent years, there has been growing interest in exploring the use of adjuvants to local anesthetics in order to enhance the quality and duration of nerve blocks.<sup>1-5</sup>

Dexamethasone, a potent corticosteroid with anti-inflammatory and analgesic properties, has emerged as a promising adjuvant for regional anesthesia. By adding dexamethasone to the local anesthetic solution, researchers have investigated whether this combination can improve the onset and duration of supraclavicular brachial plexus block.<sup>6-8</sup>

The rationale behind the use of dexamethasone stems from its ability to reduce inflammation, decrease neuronal excitability, and inhibit the release of pain mediators. These properties make dexamethasone a potential enhancer of nerve block effectiveness.<sup>7-9</sup>

Several studies have evaluated the impact of adding dexamethasone to local anesthetics on the onset and duration of supraclavicular brachial plexus block. The outcomes of interest include the time to achieve complete sensory and motor blockade, as well as the duration of postoperative analgesia.<sup>10</sup>

Understanding the effects of dexamethasone as an adjuvant in supraclavicular brachial plexus block is of great clinical significance. Optimizing the onset and duration of nerve blocks can result in improved intraoperative conditions, better postoperative pain control, and potentially shorter hospital stays. Additionally, by reducing the need for systemic opioids, the use of dexamethasone as an adjuvant may help mitigate opioid-related side effects and contribute to enhanced patient satisfaction.<sup>11</sup>

In this discussion, we will explore the current body of literature and evidence regarding the effect of adding dexamethasone to local anesthetics on the onset and duration of supraclavicular brachial plexus block. By critically evaluating the available studies, we can gain insights into the potential benefits and implications of incorporating dexamethasone as an adjuvant in regional anesthesia practice.<sup>12-15</sup>

## Objective

## **Primary Objective**

In this study our main goal is to evaluate the effect of dexamethasone added to local anaesthetics on the onset and duration of supraclavicular brachial plexus block.

## **Secondary Objective**

- To evaluate the quality of block of the patients
- To assess Socio demographic characteristics of the patients

## **Methodology**

From 2022, a tertiary hospital conducted a cross-sectional research. One hundred adults receiving orthopaedic procedures on the forearm and elbow were included with a supraclavicular brachial plexus block. They were randomly split into two groups of fifty. Patients in Group A were given a lignocaine and bupivacaine combination (35 ml) with a 2% and 0.5% concentration, respectively.

Patients also got 8 mg of dexamethasone along with the local anaesthetics. Two groups were studied to examine the onset of sensory and motor block, the duration of analgesia, and the occurrence of problems.

Patients were distributed into 2 groups of 30 each. In Group-A patients received 15 ml of lignocaine 2%, 15 ml of bupivacaine 0.5% while in Group-B patients received injection dexamethasone 2 ml (8 mg) in addition to the above mixture. Total volume was made to 35 ml by adding distilled water in both the groups. On arrival to the operating room, multi-parameter monitor was attached and the initial pulse, blood pressure (BP), respiratory rate, SpO<sub>2</sub> was recorded as pre-block values. A 20 gauge IV cannula was inserted in a peripheral vein in the contra lateral arm. After appropriate patient positioning and strict aseptic and antiseptic precautions midclavicular point, external jugular vein and subclavian artery pulsation were identified. About 2 cm above the midclavicular point just lateral to subclavian artery pulsation, a 24 gauge 1.5 inch needle was introduced and directed caudal and medially until paraesthesia was encountered, when 35 ml of local anaesthetics with or without dexamethasone was injected in this area. After the procedure patients were taken for surgery. Time of onset of sensory block and onset of motor block were noted. Patients were monitored routinely and any untoward side effects were also noted. Duration of analgesia was measured

by interviewing the patient in the postoperative ward. Analgesia was given when patients complained of pain.

Results are shown as MeanSD for a total of seven different tests. The unpaired student's t-test was used to establish statistical significance. The cutoff for statistical significance was set at 0.05. When comparing three or more groups, we used an ANOVA test, and we considered the result to be statistically significant if the p value was less than 0.05.

## Results

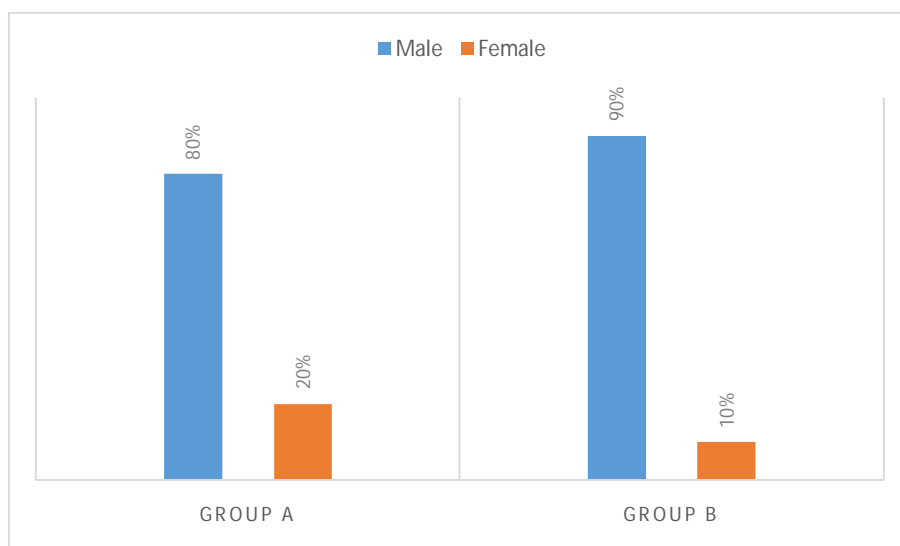
In table-1 shows aged distribution of the patients where most of the patients belong to 41-50 years age group for both Group A (48%) and group B (42%). The following table is given below in detail:

**Table-1: Aged distribution of the patients**

Group	Group A%	Group B%
31-40	7%	6%
41-50	48%	42%
51-60	35%	37%
>60	10%	15%

In figure-

1 shows gender distribution of the patients. This study patient was divided into Group A and Group B, wherein Group A 80% were male and 20% were female. In Group B 90% and 10% were male and female respectively. The following figure is given below in detail:



**Figure-1: Gender distribution of the patients.**

In table-

2 shows sociodemographic characteristics of the patients where, in group A 60% patients were diabetic whereas in group B it was 71%. In addition, mean weight of group A was  $69 \pm 9.0$  kg whereas in group B  $62 \pm 9.1$  kg.

The following table is given below in detail:

**Table-2; Sociodemographic characteristics of the patients**

Variable	Group A	Group B
Weight	$69 \pm 9.0$	$62 \pm 9.1$
Height	$173 \pm 6.0$	$172 \pm 5.0$
Educational Status		
Illiterate	6%	1%
Primary	12%	19%
Secondary	23%	21%
Graduate	59%	60%
Working status:		
Serviceholder	32%	28%
Business Man	15%	11%
Housewife	27%	25%
Others	26%	36%

Diabetic status of the patients:		
Diabetic:	60%	71%
Nondiabetic:	40%	29%

Table-

3 shows distribution of the patients according to duration of surgery where in group A mean duration of surgery was  $78.75 \pm 10.50$  min whereas in group B it was  $82.50 \pm 11.12$ .

**Table-3: Distribution of the patients according to duration of surgery**

Group	Duration of Surgery, min	P value
Group A	$78.75 \pm 10.50$	>0.005
Group B	$82.50 \pm 11.12$	

Table-

4 shows Comparison of quality of block in two groups in the patients where there was a statistically significant ( $p < 0.05$ ) early onset of sensory and motor blocking in group B. The analgesic effect lasted much longer in group B ( $p < 0.001$ ) than in group A.

**Table-4: Comparison of quality of block in two groups**

Quality of block Group	Group A	Group B	P value
Onset of sensory block (min)	$11.64 \pm 2.19$	$09.89 \pm 1.97$	<0.005
Onset of motor block (min)	$13.32 \pm 0.98$	$11.09 \pm 1.28$	<0.005
Total duration of analgesia (hour)	$03.43 \pm 0.49$	$11.87 \pm 0.53$	<0.001

Table-

5 shows Incidence of side effects during block in two groups where in 45% of those diagnosed with group A Horner's syndrome also had Dyspnoea or chest pain. The recurrent laryngeal nerve was blocked in 3

% of patients, whereas 2% had insufficient occlusion. Group B contained 31% of instances of Horner's syndrome, 5% of cases of dyspnea or chest pain, 2% of cases of recurrent laryngeal nerve block, and 1% of cases of inadequate block.

**Table-5: Incidence of side effects during block in two groups**

Side effects	Group A	Group B	P value
Horner's syndrome	45%	31%	>0.05
Dyspnea or chest discomfort	7%	5%	>0.05
Recurrent laryngeal nerve block	3%	2%	>0.05
Inadequate block	2%	1%	>0.05

## Discussion

The brachial plexus block is a simple and safe treatment for surgical procedures involving the upper limbs. Although improved operating conditions were achieved using a mixture of lignocaine and bupivacaine, analgesia lasted for about 4–6 hours at most. Incorporating steroids into local anesthetics has been shown to hasten the onset of pain relief and increase its duration of effect.<sup>12</sup> Steroids are powerful in their ability to reduce inflammation and inhibit the immune system. There is evidence that steroid injection into an nerve's perivascular space may affect pain relief after surgery. Back and sciatic discomfort were treated with the epidural steroid injections.<sup>9</sup> Several steroids have been tried for this, but the synthetic glucocorticoid dexamethasone is recommended due to its very powerful anti-inflammatory effect, which is around 25–30 times as strong as hydrocortisone and does not include mineralocorticoid action. This method was determined to be risk-free and effect-free.<sup>13</sup>

Oral and intravenous pre-operative dexamethasone treatment has been found to decrease postoperative pain ratings and analgesic needs without side effects in a variety of oral and general surgical procedures.<sup>14</sup> The anti-nausea and anti-vomiting effects of dexamethasone are well-documented. Dexamethasone's anti-

inflammatory properties may underlie its analgesic and antiemetic effects,<sup>15-</sup>

<sup>16</sup>Earlier onset of sensory and motor block was seen in group-B than in group-A in the described research.

In one study showed steroid treatment considerably increases the duration of analgesia after nerve block of the extremities.<sup>17</sup> Adding dexamethasone to lignocaine considerably increased the duration of analgesia without affecting the start time, according to a research of axillary block. Dexamethasone, when used as an adjuvant in a combination of local anesthetics, has been shown in another trial of supraclavicular block to dramatically accelerate the onset and extend the duration of analgesia.<sup>18.</sup>

<sup>21</sup>The success rate for both groups was far over 90%. Complication rates were minimal overall and were about the same among the groups, with the exception of a slightly increased rate of Horner's syndrome. In this investigation, no cases of clinical pneumothorax were found.

Comparable to other research,<sup>19</sup> we found that 45% of patients in group A and 31% of patients in group B had Horner's syndrome. Seven percent of group A patients and five percent of group B patients had dyspnea or chest pain. Inadequate block was seen in one patient in both groups, and recurrent laryngeal nerve block occurred in 2% of Group A patients and 1% of Group B patients, respectively.

## **Conclusion**

Addition of dexamethasone to 1.5% lidocaine with adrenaline in supraclavicular brachial plexus block speeds the onset and prolongs the duration of sensory and motor blockade. However, the use of dexamethasone to prolong the effects of local anesthetics is not encouraged. It might be useful in situations when epinephrine use is limited (such as in hypertension or cardiovascular disease).

## **Reference**

1. Crile H. Great moments in the history of anaesthesiology in - A practice of anaesthesia 7th ed. London, UK: Lloyd-Luke; 2003. p.8.
2. Jeon DG, Kim W. Case series: ultrasound-guided supraclavicular block in 105 patients. Korean J Anesthesiol 2010 Mar; 58(3): 267-271.
3. Singh A, Gupta R, Vashisth M, Singh S, Kumari A, Auja KS. Comparison of Effectiveness of Brachial Plexus Block by Supraclavicular and Axillary Approach Alone or in Combination. J Anaesth Clin Pharmacol 2010; 26(1): 31-34.

4. Yang CM, Kwon HU, Cho CK, et al. A comparison of infraclavicular and supraclavicular approaches to the brachial plexus using neurostimulation. *Korean J Anesthesiol* 2010 Mar; 58(3): 260-266.
5. Neal JM, Gerancher JC, Hebl JR, Ilfeld BM, et al. Upper Extremity Regional Anesthesia: *Reg Anesth Pain Med* 2009; 34(2): 134-170.
6. Wakhlo R, Gupta V, Raina A, Gupta SD, Lahori VU. Supraclavicular Plexus Block: Effect of Adding Tramadol or Butorphanol as an Adjunct to Local Anaesthetic on Motor and Sensory Block and Duration of Post-operative Analgesia. *J Anaesth Clin Pharmacol* 2009; 25(1): 17-20.
7. Gabriella I, Adnan M, Desire-Pascal D, et al. The effect of clonidine added to mepivacaine for paronychia surgery under axillary brachial plexus block. *Anesth Analg* 2005; 100(4): 1179-1183.
8. Lalla RL, Anant S, Nanda HS. Verapamil as an Adjunct to Local Anaesthetic for Brachial Plexus Blocks. *MJAFI* 2010; 66: 22-24.
9. Benzon HT. Epidural steroids. In: Raj PP, editor. *Pain medicine, a comprehensive review*. UK: Mosby Publications; 1999. p. 259-263.
10. Glasser RS, Knego RS, Delashaw JB, Fessler RG. The perioperative use of corticosteroids and bupivacaine in the management of lumbar disc disease. *J Neurosurg* 1993; 78: 383-7.
11. Mirzai H, Tekin I, Alincak H. Perioperative use of corticosteroid and bupivacaine combination in lumbar disc surgery: a randomized controlled trial. *Spine* 2002; 27: 343-6.
12. Castillo J, Curley J, Hotz J, et al. Glucocorticoids prolong sciatic nerve blockade in vivo from bupivacaine microspheres. *Anesthesiology* 1996; 85: 1157-66.
13. Droger C, Benziger D, Gao F, Berde CB. Prolonged intercostal nerve blockade in sheep using controlled-release of bupivacaine and dexamethasone from polymer microspheres. *Anesthesiology* 1998; 89: 969-74.
14. Kopacz DJ, Lacouture PG, Wu D, et al. The dose response and effects of dexamethasone on bupivacaine microcapsules for intercostal blockade (T9 to T11) in healthy volunteers. *Anesth Analg* 2003; 96: 576-82.
15. Stan T, Goodman E, Cardida B, Curtis RH. Adding methylprednisolone to local anesthetic increases the duration of axillary block. *Reg Anesth Pain Med* 2004; 29: 380-382.
16. Golwala MP, Swadia VN, Dhimar AA, Sridhar NV. Pain Relief by Dexamethasone as an Adjuvant to Local Anaesthetics in Supraclavicular Brachial Plexus Block. *J Anaesth Clin Pharmacol* 2009; 25(3): 285-288.

17. Elhakim M, Ali NM, Rashed I, et al. Dexamethasone reduces postoperative vomiting and pain after paediatric tonsillectomy. *Can. J Anaesth* 2003;50:392-97
18. Bisgaard T, Klarskov B. Pre-operative dexamethasone improves surgical outcome after laproscopic cholecystectomy. A randomized double blind placebo controlled trial. *Ann Surg* 2003;238:651-60.
19. Liu K, Hsu CC, Chia YY. Effect of dexamethasone on postoperative pain and emesis. *Br J Anaesth* 1998;80:85-86.
20. Shrestha BR, Maharjan SK, Tabedar S: Supraclavicular brachial plexus block with and without dexamethasone - A comparative study. *KUMJ* 2003;1(3):158-160.

UNDER PEER REVIEW