

## Crohn's Disease Mimicking Intestinal Tuberculosis: A Case Series

**Abstract-** The overall estimated burden of Inflammatory bowel disease in India in 2010 came out to be 1.4 million. Aim of our study was to focus on histomorphological findings of rare Crohn's disease and discuss the role of serum Antisaccharomyces cerevisiae (ASCA) antibody level and short standard anti-tubercular therapy for 15 days. We reported 4 cases on histopathology at our institute between June 2021 to March 2022. Both intestinal tuberculosis and Crohn's disease are chronic granulomatous lesions, but the absence of well-defined microgranuloma and caseous necrosis on histopathology are clinching points against Intestinal tuberculosis, favouring Crohn's disease. Microbiological findings and serum ASCA antibody level were of no use in differentiating Crohn's from tuberculosis. Early diagnosis of both entities is important as management differs from one another.

**Key words:** Intestinal tuberculosis, Crohn's disease, Antisaccharomyces cerevisiae antibody level.

### Introduction:

Differentiating Crohn's disease from tuberculosis is very difficult in developing countries due to higher burden of tuberculosis. Only a few cases of Crohn's have been reported from India. Developing countries like India are at the stage of epidemiological transition with the decreasing incidence of infectious diseases and an increasing trend of chronic non-infectious diseases (1). Chronic granulomatous disorder of the intestine is one such example of diagnostic dilemma due to the epidemiological transition from intestinal tuberculosis to Crohn's disease, a subtype of inflammatory bowel disease. (2). Differentiating intestinal tuberculosis (ITB) from Crohn's disease (CD) is very important as the management of the two are very different. But differentiating TB and Crohn's is very difficult because of overlapping clinical, endoscopic, radiological, serological, and pathological findings. A definite diagnosis of ITB depends on methods that have unsatisfactorily low sensitivities, including 5.3% to 37.5% for acid-fast bacilli tissue staining, and 36.4% to 67.9% for a polymerase chain reaction. (3,4). We are reporting 4 cases of Crohn's disease of intestine on histopathology at our institute between June 2021 to March 2022.

### CASE PRESENTATION-

SN	CHARACTERISTICS	CASE 1	CASE 2	CASE 3	CASE 4
1	Age in years	15	24	65	42
2	Sex	Male	Male	Male	Male
3	Abdominal Pain	Present, last 3 months	Present, last 1 year		Present

4	Abdominal lump	Present, last 3 months	Present, last 1 year		
5	Spiking fever	Present, last 3 months	Present, last 1 year		
6	Weight loss	Present, last 3 months	Present, last 1 year		Present
7	Vomiting		Present, last 1 year		
8	Pus discharge			From perianal region from last 5 months.	
9	Anal bleeding				Present
10	Past History	Pulmonary kochs at 4 years of age	Appendicectomy and it is a follow up case of right iliac fossa sinus. On fisulogram, a thin linear track was seen for a length of approximately 2 cm which was communicating with a colonic loop in right iliac fossa.	Hematemesis associated with melena	
11	Physical Examination	A hard lump of 5x5 cm size felt in right lumbar region with smooth surface, tender and fixed.		Soft, non tender and a right inguinal scar was present. No fistulous tract was identified.	A lump was noted in right iliac fossa.
12	Occult blood in stool.			Positive	
13	Radiological findings	CT- Circumferential hypochoic thickening of	Endoscopy report- a	USG- An ulcerative lesion with multiple defects in	CT - A hypochoic

		ileocaecal junction and terminal ileal walls with intussusception	polypoidal mass was seen in caecum near ileocaecal valve.	anterior and anterolateral (12 o'clock and 11 o'clock) position. Multiple external fistulous opening with multiple nodularity was present.	ileal stricture was noted with hepatic nodules.
14	Serum ASCA level	Raised			Raised
15	AFB-Stain	Negative	Negative	Negative	Negative
16	TB-PCR	Negative	Negative	Negative	Negative

In all 4 cases surgery was done and specimen was sent to pathology dept for HPE.

There gross findings and histopathological findings are tabulated in table 1 and table 2 respectively.

**Table 1. Gross examination findings**

Case	Surgical specimen	Cut section	Cobble stone appearance	Mesenteric fat wrap	Skip lesion
1	Hemicolectomy With Part Of Ileum	Nodular lesion with stricture	Positive	Positive	Not Seen
2	Hemicolectomy+ Ileum+Transvere Colon	Thickened area	Negative	Negative	Not Seen
3	Rectal fragmented tissue bits	-	-	-	-
4	Ileal segment with hepatic nodule	Stricture with ulceration	Negative	Negative	Not Seen.

In Table 1 ,Case 1 and 2 were hemicolectomy specimen with part of ileum, having greyish white thickened area .Case 3 was small rectal biopsy in fragmented form, so we don't have its specific findings on gross examination.Case 4 showed ileal segment, having stricture with gross ulceration. Cobble stone appearance , mesenteric fat wrap were noted in only 1<sup>st</sup> case , but skip lesion was not seen in any case.



Fig 1 (a, b, & c) showing Gross specimens of case 1 , 2 and 4 respectively. Fig 1 (a) shows cobblestone appearance and mesenteric fat wrap. Skip lesion not seen in any of the 4 cases.

**Table2 . Histopathological Findings**

Case	Transmural inflammation	Architectural distortion and branching	Microgranuloma +_giant cell	Ulceration	Pyloric gland metaplasia	Dysplasia
1	+	+	Giant cell+ epithelioid cells+	+	+	-
2	+	+	Microgranuloma+	+	-	-
3	+	+	Microgranuloma+	+	-	-
4	+	+	Microgranuloma+	+	-	-

Table 2. shows histopathological findings of all 4 cases. Sections from all 4 cases showed transmural involvement . Both architectural abnormalities and transmural inflammation noted. Architectural abnormalities includes crypt distortion (non parallel crypts and cystically dilated glands) , crypt branching (>branched crypts) and crypt shortening (decreased crypt length). Inflammatory features includes transmural inflammation comprising of lymphoplasmacytic infiltration . Microgranuloma (<200um) was noted in all cases except in Case 1 in which we got only very few epithelioid cell . Surface mucosal denudation and superficial ulcer was also noted in all 4 cases. pyloric metaplasia was noted in case 1 only. Dyaplasia was not seen in any case.

MICROSCOPY

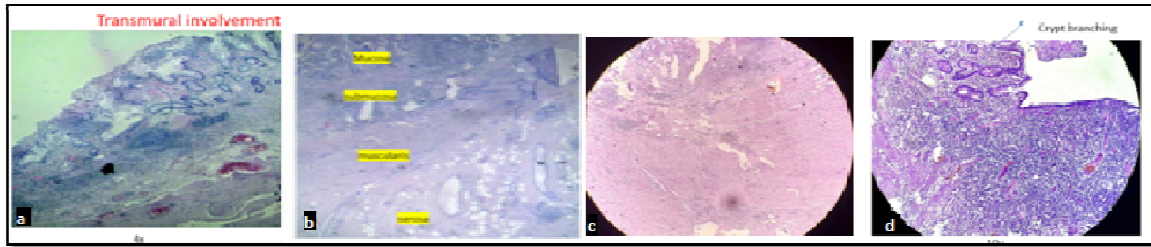


Fig 2(a, b, c, & d) 4x. view showing transmural inflammation in all 4 cases.

Muscular Layer

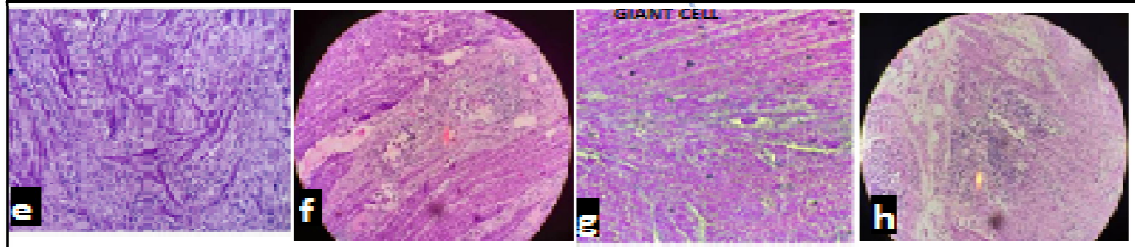


Fig 2(e, f, g, & h) 10x view showing muscular proper layer infiltrated by lymphoplasmacytic infiltration in all 4 cases.

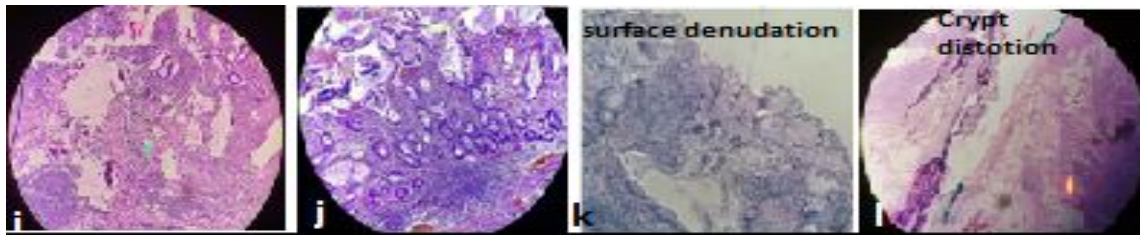


Fig 2(i, j, k, & l) 4x. view showing crypt architectural distortion in all 4 cases.

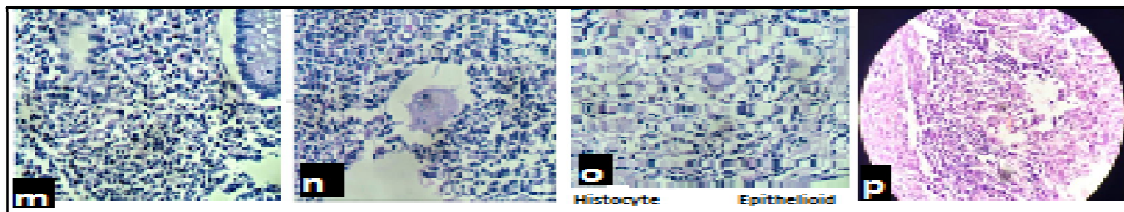


Fig 2 (m, n, o & p) 10x view showing only few epithelioid cells in case 1 (Fig 2m) and microgranuloma in other 3 cases.

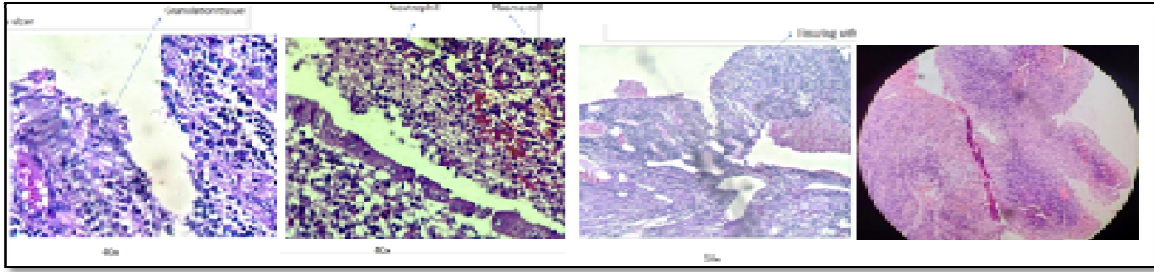


Fig 2 ( q, r, s, & t) 10x. view shows surface denudation and superficial mucosal ulceration in all 4 cases.

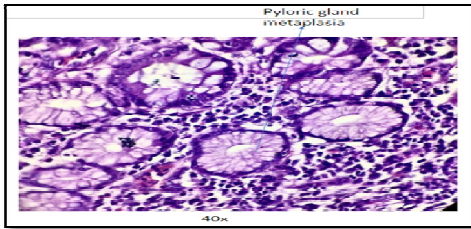


Fig 2 (u) show pyloric gland metaplasia in case 1.

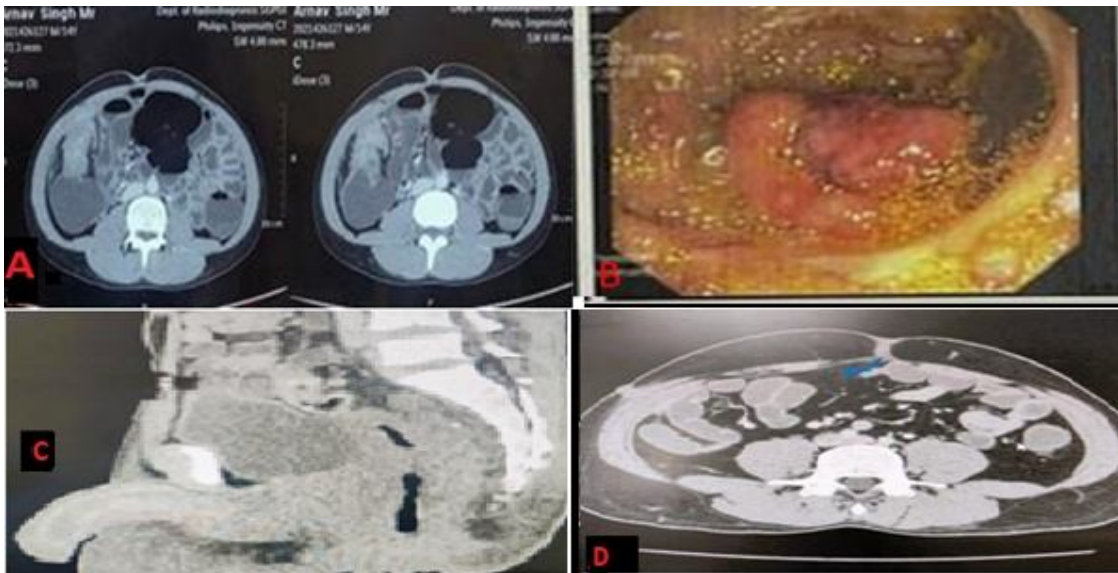


Fig 3(a,c & d) show CT findings of gut wall thickening in Case 1,3 & 4 respectively. Fig 3(b) show endoscopic finding of case 2.

In all 4 cases , neither well defined microgranuloma nor caseous necrosis seen on histopathology added by the negative microbiological findings, the chance of intestinal tuberculosis was very less and we were more in favour of Crohns disease.

We have started management of cases 2,3 and 4 in line of Crohns disease and patient responded very well.

But we were in diagnostic dilemma in Case 1 as patient has history of tuberculosis and discrete microgranuloma not noted. So we gave a short trial of ATT in cases 1 for 15 days, but got no good response. After which we have started management with corticosteroids and immunomodulators. Patient responded well and was stable.

### **Discussion:**

Diagnosing Crohn's disease is very difficult in developing countries due to higher burden of tuberculosis. Very few cases of Crohn's have been reported from India.

Among the clinical features, diarrhea, hematochezia, perianal disease, and EIMs favored CD, while fever, night sweats, lung involvement and ascites favored ITB. However, none of these features is exclusive for either disease and alone cannot diagnose CD or ITB.(5). Overlapping clinical features was also noted in our 4 cases.

"In recent studies from India, it was found that radiological findings that were more common in patients with CD as compared to ITB were involvement of the left colonic segment (22% vs 6%), long-segment involvement (69% vs 28%), presence of skip lesions (63% vs 42%), and presence of comb sign (44% vs 20%). On the other hand, the involvement of ileocecal area (70% vs 43%), shorter length of involvement, and presence of lymph nodes larger than 1 cm (20% vs 2%) were more common in ITB"(6). But these features are also not very specific for either of 2, as seen in our cases.

"Both the disorders are characterized by chronic granulomatous inflammation in the GI tract, and pathological features can be classified into architectural and inflammatory features. Architectural abnormalities such as crypt distortion (non-parallel crypts, variable diameter or cystically dilated crypts), crypt branching (> 2 branched crypts), crypt shortening, decreased crypt density) and microgranuloma(<200un) more common in CD but can also be seen in ITB"[9,10]. "Inflammatory features including, transmural inflammation, focal cryptitis, aphthoid ulcers, proximal location of ulceration and paneth cell metaplasia and macro granulomas with caseation are more common in ITB. Granuloma is a collection of epithelioid histiocytes (macrophages) with vaguely defined outlines. Tubercular granulomas are usually large (> 200 m), confluent, dense (> 5-10/hpf), located in submucosa, and are characterized by central caseation, which is diagnostic and exclusive for ITB"(7-10). Granulomas in CD are usually small (microgranuloma), discrete, ill-defined and sparse. So, the HPE findings of our 4 cases are more in favour of Crohn's disease than tuberculosis as described in recent studies.

“Intestinal TB is a paucibacillary disease and is responsible for poor sensitivity of microbiological tests. Demonstrating the bacillus with acid-fast bacillus (AFB) staining would be easiest, but has very poor sensitivity of 2.7%-37.5% . Polymerase chain reaction (PCR) for AFB in endoscopic biopsies is not exclusive for ITB, hence cannot be diagnostic for ITB. Therefore, among the microbiologic tests, AFB stain, and Gene-Xpert MTB are diagnostic for ITB, however, these tests are associated with very poor diagnostic sensitivity, limiting their role in the diagnosis of ITB”. (11-13). In our 4 cases AFB stain and PCR are negative , but as sensitivity of these microbiological tests are not so sensitive, so reliability is very less on these tests.

“Positive serology for Anti-saccharomyces cerevisiae antibody (ASCA) has no role in differentiating CD from ITB, as shown in two studies from India” [14] . In all our 4 cases Anti ASCA ab was found to be positive, but it has no specificity for any of two.

### **Conclusion-**

Unfortunately Crohn’s remains an under diagnosed disease in developing countries such as India due to overlapping findings with tuberculosis. Age, clinical features , radiological findings are not specific and has no significance. But the absence of well defined microgranuloma and caseous necrosis on histopathology are clinching point against intestinal tuberculosis, favouring Crohn’s disease. As ITB is a paucibacillary disease, so microbiological tests accounts for poor sensitivity. We could go for short standard antitubercular therapy in developing countries like India, if there is diagnostic struggle between both diseases. The earliest distinction between these two lesion is must as there management are very different from each other.

### **Consent**

As per international standard or university standard, patient(s) written consent has been collected and preserved by the author(s).

### **Ethical Approval:**

As per international standard or university standard written ethical approval has been collected and preserved by the author(s).

### **REFERENCES-**

1. Omran A. The epidemiologic transition theory revisited thirty years later. World Health Stat Q. 1998;51:99–119.

2. Kedia S, Ahuja V. Is the emergence of inflammatory bowel disease a prime example of "the third epidemiological transition?". *Indian J Gastroenterol*. 2018;37:183–85.
  3. Wei, J. P. *et al*. Misdiagnosis and mistherapy of Crohn's disease as intestinal tuberculosis: Case report and literature review. *Medicine* 95(1), e2436 (2016).
  4. Makharia GK, Srivastava S, Das P, Goswami P, Singh U, Tripathi M, *etal* . Clinical, endoscopic, and histological differentiations between Crohn's disease and intestinal tuberculosis. *Am J Gastroenterol*. 2010;105:642–51.
  5. Kedia S, Sharma R, Nagi B, Mouli VP, Aananthakrishnan A, Dhingra R, *etal*. Computerized tomography-based predictive model for differentiation of Crohn's disease from intestinal tuberculosis. *Indian J Gastroenterol*. 2015;34:135–143.
  6. Park YH, Chung WS, Lim JS, Park SJ, Cheon JH, Kim TI, *etal*. Diagnostic role of computed tomographic enterography differentiating crohn disease from intestinal tuberculosis. *J Comput Assist Tomogr*. 2013;37:834–39.
  7. Kedia S, Sharma R, Sreenivas V, Madhusudhan KS, Sharma V, Bopanna S, *etal*. Accuracy of computed tomographic features in differentiating intestinal tuberculosis from Crohn's disease: a systematic review with meta-analysis. *Intest Res*. 2017;15:149–159.
  8. Kleer CG, Appelman HD. Surgical pathology of Crohn's disease. *Surg Clin North Am*. 2001;81:13–30.
  9. Morson BC. Pathology of Crohn's disease. *Ann R Coll Surg Engl*. 1990;72:150–51.
  10. Geboes K, van den Oord J, De Wolf-Peeters C, Desmet V, Rutgeerts P, Janssens J, *etal*. The cellular composition of granulomas in mesenteric lymph nodes from patients with Crohn's disease. *Virchows Arch A Pathol Anat Histopathol*. 1986;409:679–92.
  11. Li Y, Stocchi L, Liu X, Rui Y, Liu G, Remzi FH, *eal*. Presence of Granulomas in Mesenteric Lymph Nodes Is Associated with Postoperative Recurrence in Crohn's Disease. *Inflamm Bowel Dis*. 2015;21:613–618
  12. Patel N, Amarapurkar D, Agal S, Baijal R, Kulshrestha P, Pramanik S, *etal* . Gastrointestinal luminal tuberculosis: establishing the diagnosis. *J Gastroenterol Hepatol*. 2004;19:1240–46.
  13. Amarapurkar DN, Patel ND, Amarapurkar AD, Agal S, Baigal R, Gupte P. Tissue polymerase chain reaction in diagnosis of intestinal tuberculosis and Crohn's disease. *J Assoc Physicians India*. 2004;52:863–67.
  14. Kim YS, Kim YH, Kim WH, Kim JS, Park YS, Yang SK, *etal*. Diagnostic utility of anti-Saccharomyces cerevisiae antibody (ASCA) and Interferon- $\gamma$  assay in the differential diagnosis of Crohn's disease and intestinal tuberculosis. *Clin Chim Acta*. 2011;412:1527–32.
-