

Original Research Article

Three-dimensional evaluation of the upper airway after orthognathic surgery in angle Class II and Class III patients

ABSTRACT

Aims: Orthognathic surgeries aim to correct dento-skeletal discrepancies and thus re-establish the patient's facial harmony and ideal occlusion. The objective of this observational cohort study was to evaluate in three dimensions (3D) the volume and minimum axial area of the upper airway (UA) after 180 days of orthognathic surgical procedures performed in the maxilla, mandible and chin in patients with type II and III malocclusion.

Study design: Observational study.

Place and Duration of Study: The sample came from patients who underwent bimaxillary orthognathic surgery for Angle Class II and Class III correction between 2018 and 2019 in a private clinic, consisting of 58 patients.

Methodology: Through the analysis of computed tomography (CT) scans of patients admitted to bimaxillary surgery with virtual planning, the preoperative (T1) and 180-day post operative (T2) moments were evaluated using the Dolphin Imaging® software. The sample came from the analysis of the clinical records of patients admitted to surgery between the years 2017 and 2019.

Results: Among the 50 records analyzed, 16 were excluded from the research because they did not meet the eligibility criteria, or due to problems arising in reading the software. Of those eligible, measurements were taken of: total volume and minimum axial area of the upper airway. Patients undergoing orthognathic surgery for class II showed a significant difference after performing medical therapy with an increase in minimum values in total area and axial area, unlike class III patients, who did not present a significant difference ($p \leq 0.05$).

Conclusions: Class II patients had a significant increase in UAV, while class III patients did not present a significant change in UAV. The importance of good planning and combined movements make orthognathic surgery increasingly predictable and with better results.

Keywords: Orthognathic Surgery. Airway Obstruction. Facial Asymmetry.

1. INTRODUCTION

Orthognathic surgeries aim to correct dento-skeletal discrepancies and thus re-establish the patient's facial harmony and ideal occlusion. The literature mentions dental-skeletal discrepancies as predisposing factors to a decrease in upper airway volume (UAV), thus impairing respiratory functions, such as the risk for the development of obstructive sleep apnea (OSA). [1-3]

In orthognathic surgeries for bimaxillary advancements, there is strong evidence of an increase in the total volume of the upper airway (UA) due to increased tension in the suprahyoid and velopharyngeal musculature. In the case of combined orthognathic surgeries of maxillary advancement and mandible retreat, controversial data on the repercussions on the upper airways have been reported. [4-6] Some studies have demonstrated a greater increase in UAV in counterclockwise rotations of the maxillomandibular complex, where, in addition, such movement can lead to additional volumetric gain in the nasopharyngeal region. [7,8]

Among the evaluated studies, it was verified that there was no standardization regarding the limits used in order to anatomically determine the upper airways. de Souza Carvalho et al. (2012), used the oropharynx limited superiorly by the tangent plane that passes through the posterior nasal spine and inferiorly by the tangent plane that passes from the tip of the epiglottis to the posterior pharyngeal wall and perpendicular to the sagittal plane. The nasopharynx was limited superiorly by the roof of the airway and by a tangent plane that extends from the posterior nasal spine to the posterior pharyngeal wall, perpendicular to the sagittal plane at the level of the basium. [2]

It cannot be said that there is a mathematical relationship between the effects on UA according to the surgical movement performed three-dimensionally (3D) in orthognathic surgery. [9] The skeletal movements caused by orthognathic surgery can promote changes in the tissue in the oropharynx region, with changes in the volume of this space, with the probable consequences of an increase / decrease in the volume of air in the airways. [10,11] Studies that can elucidate this relationship between the volume and minimum axial area of the UA pathways after orthognathic surgery procedures performed in the maxilla, mandible and chin in patients with Class II and III malocclusion are scarce in the literature. [12-14]

The aim of this study was to evaluate changes in UA space after performing Maxillomandibular advancement (MMA), over a follow-up period of at least 6 months, using cone beam computed tomography (CT).

2. METHODOLOGY

The sample came from patients who underwent bimaxillary orthognathic surgery for Angle Class II and Class III correction between 2018 and 2019 in a private clinic, consisting of 58 patients. The sample was calculated based on a previous pilot study, and 11 patients were required to achieve a test power higher than 80%, a significance level of 5%, and a large effect size (0.40). The study evaluated the characteristics of patients with Class II and III malocclusion who underwent a surgical procedure in a hospital setting under general anesthesia with bimaxillary osteotomy and rigid fixation with a titanium plate and screw system. orthognathic (T1) and 180 days after the procedure (T2).

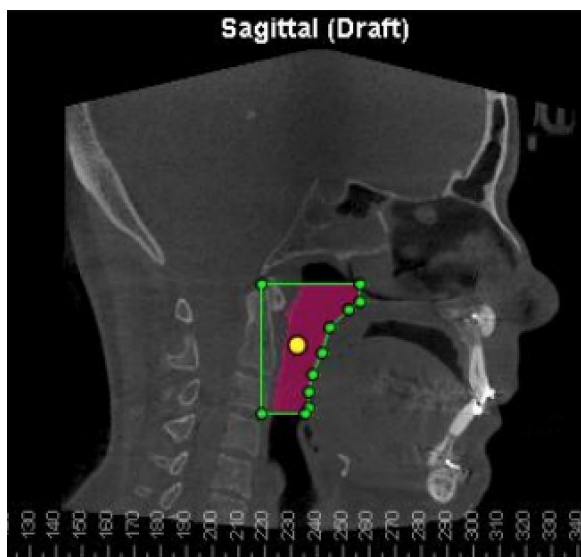
The criteria for inclusion in the sample were previously defined: (a) individuals submitted to orthognathic surgery to correct Class II and III malocclusion, (b) medical records containing pre- and postoperative 30-day CT scans, and (c) patients who underwent uneventful procedure during surgery, (d) due to indication of respiratory difficulty diagnosed by a specialist physician. As sample exclusion criteria: (a) medical records not filled out properly and without patient signatures; (b) patients who did not have a Class II or III malocclusion; (c) patients with systemic diseases; (d) patients with facial trauma, (e) patients with joint prostheses.

All MMA surgeries were performed in a private hospital, under general anesthesia and following the same protocol. were performed by the same surgical team and it followed the same surgical and rigid internal fixation protocols. Orthognathic surgery was done using a standard Bilateral Sagittal Osteotomy and LeFort I osteotomies. [15]

CT examinations were performed in the Kodak 9500 3D Cone Beam Radiography System tomograph (Carestream Health, Rochester, NY) at the following times: before orthognathic surgery (initial preoperative period: classified as T1), intermediate postoperative period (6 months after surgery: classified as T2), and longitudinal follow-up (4 years after surgery: classified as T3). The work regime was of 85 kV, 6.3 mA, exposure time of 11.30 seconds, and extended field of view with voxel set at 0.30 mm. During the examination, the volunteer was standing up in maximal habitual intercuspation. The Frankfort horizontal plane was parallel to the ground. The head Direction was the same for each CBCT image taken by the same experienced operator. The patients were instructed not to swallow during the test. [18,19] The images were stored in the Digital Image and Communication in Medicine format and imported to the Dolphin Imaging software (version 11.9; Dolphin Imaging and Management Systems, Chatsworth, Calif) to visualize and manage the CT examinations. The images were measured by only 1 blind examiner, and the intraexaminer error was evaluated by repeating all the measures 30 days after the first ones were taken. The method allowed for applying the reproducibility test and intraclass correlation analysis, indicating excellent values with correlation analysis. [16]

The anatomical structures evaluated, as well as their limits, were defined in: upper limit: Basium and posterior nasal spine (retropalatal region, delimited by a line parallel to the Frankfurt plane, which passes through the most superior portion of the hard palate and touches the posterior portion of the air); lower limit: third vertebra up to the anterior wall of the oropharynx (hypopharyngeal region, line crossing the superior posterior space of the airway up to the height of the base of the epiglottis, parallel to the posterior limit); Posterior limit: End of the Axis tooth to the inferior limit of the third vertebra and, anterior limit: Anterior wall of the oropharynx, soft palate, tongue and epiglottis, as exemplified by Figure 1. [17]

Figure 1 - Example of definition of anatomical limits for UB. Sagittal Cut.



Data were submitted to the Shapiro-Wilk normality test. Normality was observed for the Total Volume data and non-normality for the Minimum Axial Area data. For Total Volume data, the t-test for independent samples was applied and, for Minimum Axial Area, the Mann-Whitney test was used. Data were analyzed using IBM SPSS Statistics version 25.0 (IBM Corp., Armonk, NY, USA), adopting a 95% confidence level for all analyses. In the descriptive analyses, the mean and standard deviation of the initial and final measurements of the total area, the total volume, and the minimal axial area of the airway

3. RESULTS AND DISCUSSION

Of the 50 individuals analyzed during the study period, 16 individuals were excluded from the research because they did not meet the eligibility criteria, or even because of problems in measuring the sample. Thus, 34 cases (n=34) were included in this study. The sample includes male and female individuals, with a mean age of 31 and 29 respectively, and Class II and Class III facial deformities (Table 1).

Table 1 - Sample qualification according to Angle Class, Gender and Age.

	SAMPLE (n)	GENDER		AGE*
		F	M	
Class II	15	12	3	31
Class III	19	11	8	29
Total	34	23	11	30

*Medium age of patients

The results showed that both Class II patients (Table 2) and Class III patients (Table 3) who underwent orthognathic surgery showed statistically significant increases in the measurements performed by the program in relation to the upper airway between T1 and T2.

For Air Way, the data were normal and the t-test for independent samples was applied, with a significant difference $p= 0.024$ when comparing times T1 (mean of 15068.9) and T2 (mean of 21299.6) in group 1. In group 2, no difference was observed between T1 (mean 17608.7) and T2 (mean 19852.7) times (Table 4).

Table 2 - Values of Total Volume and Minimum Axial Area of Class II individuals.

Class II	Inicial 1	Final 1	Inicial 2	Final 2
----------	-----------	---------	-----------	---------

	Total Volume mm ³	Total Volume mm ³	Minimum Axial Area mm ²	Minimum Axial Area mm ²
1	21469	26822	1	8
2	22475	30111	2	3
3	12319	26685	2	4
4	21361	24776	1	2
5	12149	14047	4	31
6	11625	33651	1	1
7	7901	9541	12	4
8	14487	17103	1	5
9	24104	36682	1	2
10	13191	18414	11	4
11	9932	13598	3	8
12	8039	9181	12	4
13	20128	25142	5	5
14	11482	16875	7	1
15	15372	16867	2	1

Table 3 - Values of Total Volume and Minimum Axial Area of Class III individuals.

Class III	Inicial 1	Final 1	Inicial 2	Final 2
	Total Volume mm ³	Total Volume mm ³	Minimum Axial Area mm ²	Minimum Axial Area mm ²
1	9072	11965	5	5
2	31181	27617	1	4
3	30169	29659	67	98
4	22178	19642	1	2
5	15506	15804	1	1
6	16762	19654	3	1
7	22808	34601	3	3
8	7798	9432	1	5
9	21391	19990	1	1
10	12554	17888	3	4
11	12371	22240	4	7
12	23424	19975	1	3
13	15224	22979	1	2
14	8310	14525	3	1
15	11341	11592	2	4
16	16755	20436	2	5
17	30691	30589	2	6
18	19028	20074	2	3
19	8003	8540	6	1

Table 4 - Results for Total Volume when comparing T1 and T2. Test used Test-t.

Group	Time	Média (mm ³)	p	%
Class II	T1	15.068,9	0.024	40
	T2	21.299,6		
Class III	T1	17.608,7	0.876	11
	T2	19.852,7		

For the Minimum axial area (Table 5), the data did not show normality, and the non-parametric statistical test for independent Mann-Whitney samples was applied. In group 1, no difference was observed between times T1 and T2 ($p=0.5476$). In group 2, no difference was observed between times either ($p=0.1939$).

Table 5 - Results for Minimum Axial Area when comparing T1 and T2. Test used Mann-Whitney.

Grupo	Tempo	Média (mm ²)	p
Classe II	T1	4.33	0.547
	T2	5.53	
Classe III	T1	5.73	0.193
	T2	8.81	

The World Health Organization (WHO) considers malocclusion one of the most important oral health problems, after caries and periodontal disease. Its prevalence is highly variable and is estimated to be between 39% and 93% in children and adolescents. Class III skeletal deformity is characterized as mandibular prognathism or maxillary deficiency. Such malocclusion is a problem that affects almost a fifth of the world's population, becoming, consequently, one of the main causes of demand for orthodontic treatment, for example, with 33% of orthodontic patients in Japan and 20% in China. The prevalence of Class II malocclusion in the Asian population is around 29.5%. Such values are less found when compared with values in the Caucasian population (35%). The prevalence of class I occlusion according to angle ranged from 34.9% to 93.6%, class II from 4.4% to 44.7% and class III from 1.4% to 19.4%. [18]

In mandibular setback surgery, the main finding is a significant decrease in the pharyngeal airway in all dimensions. However, there are controversies about PAS changes after bimaxillary surgery. [10] Some studies reported a significant decrease in linear measurements and retrolingual axial cross-sectional area, while others observed a substantial increase in volume in the oropharyngeal and hypopharyngeal areas. [11]

The VAS is an irregularly shaped 3D space, so single linear measurements performed on conventional lateral cephalograms cannot accurately describe its morphology. Previous studies have shown that VAS morphology can be accurately measured by CBCT with high reliability. [14] In this study, the ICC values to determine the inter- and intra-observer reliability were calculated for all measurements and found above 0.75, indicating an acceptable reliability of the VAS measurements. [2, 5, 19] Although orthognathic surgeries are performed to correct bony discrepancies, they inevitably affect the relationship between soft and skeletal tissues. Maxillary and/or mandibular surgical replacement can cause different alterations in the area and volume of the oral and nasal

cavities, depending on the magnitude and direction of the correction and, subsequently, can influence the quality

Most studies examine changes in the pharyngeal airways using lateral cephalometric radiographs. Although lateral cephalometric radiography only provides two-dimensional information of the pharyngeal airway, it is still a popular method for evaluating craniofacial structures and sleep apnea. The advantages of cephalometry consist of its availability, simplicity, low cost, ease of comparison with other studies. In addition, cephalometry is a routine diagnostic material for orthodontic and orthognathic treatment. However, CT has significant advantages as it allows for better delineation of soft tissues and air. Maxillary and mandibular skeletal changes can be described only by the change in the sagittal dimension, but pharyngeal soft tissue changes must be considered in all three dimensions. [3,5] Some studies have reported a significant correlation between SBP measured with cephalometry and pharyngeal airway volume in CT, but cephalometry does not provide information about the lateral structures and cross-sectional area of the UA. [20] The results of this study are in line with other authors who proved that upper airway obstruction is associated with a retrusive mandible, vertical growth pattern and a Class II tendency. [21,22] Previous studies on the morphology of the airways of patients with Class III malocclusion focused on changing the size of the airways after treatment with mandibular setback or bimaxillary surgery. [7, 8, 23].

Dental professionals should be aware that airway dimensions can be affected by skeletal patterns. Therefore, when surgery is considered, it is advisable that possible dimensional changes in the airways be studied for each patient. According to Schendel et al. (2012), who studied growth and development in a 3D analysis, the size and length of the airway increase until the age of 20, when it stabilizes. [24] Their results showed a large increase (approximately 3210 mm³) in mean airway volume from the 12 to 14 year age group to the 15 to 17 year age group, which was the main difference observed between two subsequent 6 to 60 year age groups. . For this reason, age above 15 years was selected as an inclusion criterion in this review.

Regarding the gender of the patients, the results of this study corroborate with other studies that report differences between the genders in the analysis of the VAS. [25] However, some authors divide patients according to gender and surgical procedure and do not report statistically significant differences between genders. As there is no consensus, all studies were considered together in this review. However, if this proves to be a limitation, further studies should consider sex in their analyses.

According to the results presented, professionals should consider linear, area and volumetric measurements to perform a complete analysis of the airways. Agreeing with Alsufyani et al. (2013), total volume and minimum AST measurements were the most commonly evaluated airway parameters. [26] This is probably due to the relevance of the total volume, which represents the amount of air that can occupy the airways, as well as the minimum AST, which represents the region of greatest constriction and is the smallest area of reasonable passage. There is an association between the minimum area of the airways and the occurrence of obstructive sleep apnea, since the smaller the minimum area, the greater the predisposition to OSAS. [17] Therefore, this study considered the minimum axial area and volume, with the volumetric measurement being the most frequently observed in the included articles.

According to the results of the present analysis, the consequences of orthognathic surgery represent more of a benefit in the dimensions of the airways (volume in cases of maxillary and/or mandibular advancement) than a loss (in cases of mandibular setback). This can be inferred from the magnitude of the volume increase in MMA (approximately 7000 mm³) compared to the decrease in MdA + MdS and MdS (between 1500 and 2000 mm³).

The comparisons used in this study with the analysis carried out in adult individuals and the dimensions of the postoperative oropharyngeal airway were compared to those of the preoperative period. Collaborating with the results, some authors observed an average decrease of 2.88 mm in men and 2.70 mm in women in the sagittal dimension of the theopharynx and an average decrease of 4.46 mm in men and 3.20 mm in women in the space minimum pharyngeal airway in a longitudinal study in adults with 20 years follow-up. This can be critical if a major narrowing of the airway is observed as a result of orthognathic surgery.

This study was able to show that a significant correlation was found between the pharyngeal airway space measured with cephalometric radiography and the volume of the hypopharyngeal airway on CT. Although CT has been more widely used in scientific articles in the last decade, there are still few studies evaluating changes in oropharyngeal airway volume after orthognathic surgeries that correct anteroposterior bone discrepancies. [3, 4, 11, 14] These studies are necessary to confirm the results obtained so far. The results of this study in patients undergoing maxillary advancement associated with mandibular reversal surgery showed a significant decrease in linear measurements

at the level of the soft palate, base of the tongue and vallecula and in the axial sectional area at the level of the base of the tongue.

The results of the meta-analysis are consistent with the anteroposterior findings, showing that the bimaxillary advancement surgery can effectively increase the volume of the upper airways. [6] Few studies have evaluated changes in the lateral width of the oropharyngeal airway, but Changes in the axial cross-sectional area of the oropharyngeal airway were evaluated by three studies. [9, 12, 13] They observed a significant postoperative decrease in pharyngeal cross-sectional area at the base of the tongue in mandibular setback surgery, but no significant change in bimaxillary surgery to correct Class III discrepancy.

The correlation between mandibular asymmetry and UA morphology is rarely studied, in this study class II individuals showed a significant increase in UA volume, further studies are needed based on this, where we can measure the lung capacity caused by this increase in UA as well how to know the favorable and unfavorable reactions of these patients in the long term to this gain of great significance and plan approaches in a multidisciplinary way.

4. CONCLUSION

Class II patients had a significant increase in UAV, while class III patients did not present a significant change in UAV. The importance of good planning and combined movements make orthognathic surgery increasingly predictable and with better results.

Ethical approval

All recruited individuals were offered verbal and written explanations of the objectives, methodology, benefits and eventual risks related to participation in the project. Thus, individuals who accepted participating in the study signed the Free and Informed Consent Form, previously evaluated and approved by the Research Ethics Committee of the Santo Amaro University - UNISA number 4.220.324

REFERENCES

1. Turnbull NR, Battagel JM. The effects of orthognathic surgery on pharyngeal airway dimensions and quality of sleep. *J Orthod.* 2000; 27: 235–247.
2. de Souza Carvalho AC, Magro Filho O, Garcia IRJR, Araújo PM, Nogueira RL. Cephalometric and three-dimensional assessment of superior posterior airway space after maxillomandibular advancement. *Int J Oral Maxillofac Surg.* 2012; 41(9):1102-11.
3. Pereira PKN, de Castro Rocha VÁ, Degan VV, Garib DG, Vedovello SAS, de Menezes CC. Upper airways after mandibular advancement orthognathic surgery: A 4-year follow-up. *Am J Orthod Dentofacial Orthop.* 2021; 159(6):743-749.
4. Degerliyurt K, Ueki K, Hashiba Y, Marukawa K, Simsek B, Okabe K, et al. The effect of mandibular setback or two-jaws surgery on pharyngeal airway among different genders. *Int J Oral Maxillofac Surg.* 2009; 38(6):647–52.
5. Souza Pinto GN, Iwaki Filho L, Previdelli ITDS, Ramos AL, Yamashita AL, Stabile GAV, Stabile CLP, Iwaki LCV. Three-dimensional alterations in pharyngeal airspace, soft palate, and hyoid bone of class II and class III patients submitted to bimaxillary orthognathic surgery: A retrospective study. *J Craniomaxillofac Surg.* 2019; 47(6):883-894.
6. Rosário HD, Oliveira GMS, Freires IA, de Souza Matos F, Paranhos LR. Efficiency of bimaxillary advancement surgery in increasing the volume of the upper airways: a systematic review of observational studies and meta-analysis. *Eur Arch Otorhinolaryngol.* 2017; 274(1):35-44.

7. Fairburn SC, Waite PD, Vilos G, Harding SM, Bernreuter W, Cure J, Cherala S. Three-dimensional changes in upper airways of patients with obstructive sleep apnea following maxillomandibular advancement. *J Oral Maxillofac Surg.* 2007; 65(1):6-12.
8. He L, He S, Wu X, Huang Y. Three-Dimensional Morphological Changes of the Upper Airway in Patients With Skeletal Class III Malocclusion After Orthognathic Surgery. *J Craniofac Surg.* 2019; 30(8):2451-2455.
9. Brunetto DP, Velasco L, Koerich L, Araujo MT. Prediction of 3-dimensional pharyngeal airway changes after orthognathic. surgery: a preliminary study. *Am J Orthod Dentofacial Orthop.* 2014; 146:299–309
10. Bin LR, Filho LI, Yamashita AL, de Souza Pinto GN, Mendes RA, Ramos AL, Dos Santos Previdelli IT, Iwaki LCV. How does bimaxillary orthognathic surgery change dimensions of maxillary sinuses and pharyngeal airway space? *Angle Orthod.* 2020; 90(5):715-722.
11. Kim Y, Hong J, Hwang Y, Park Y. Three-dimensional analysis of pharyngeal airway in preadolescent children with different anteroposterior skeletal patterns. *Am J Orthod Dentofacial Orthop.* 2010; 137:301–306.
12. Raffaini M, Pisani C. Clinical and cone-beam computed tomography evaluation of the three-dimensional increase in pharyngeal airway space following maxillo-mandibular rotationadvancement for class II-correction in patients without sleep apnoea (OSA). *J Craniomaxillofac Surg* 2013; 41:552–557.
13. Valladares-Neto J, Silva MA, Bumann A, Paiva JB, Rino-Neto J. Effects of mandibular advancement surgery combined with minimal maxillary displacement on the volume and most restricted cross-sectional area of the pharyngeal airway. *Int J Oral Maxillofac Surg.* 2013; 42:1437–1445.
14. Shokri A, Ramezani K, Afshar A, Poorolajal J, Ramezani N. Upper Airway Changes Following Different Orthognathic Surgeries, Evaluated by Cone Beam Computed Tomography: A Systematic Review and Meta-analysis. *J Craniofac Surg.* 2021; 32(2):e147-e152.
15. Bennett MA, Wolford LM. The maxillary step osteotomy and Steinmann pin stabilization. *J Oral Maxillofac Surg* 1985; 43:307-11.
16. Bazina M, Cevidanes L, Ruellas A, et al, Precision and reliability of Dolphin 3-dimensional voxel-based superimposition. *Am J Orthod Dentofac Orthop.* 2018; 153:599–606.
17. Schendel SA, Broujerdi JA, Jacobson RL. Three-dimensional upper-airway changes with maxillomandibular advancement for obstructive sleep apnea treatment. *Am J Orthod Dentofacial Orthop.* 2014; 146(3):385-93.
18. Cenozo N, Nobili A, Maspero C. Prevalence of Dental Malocclusions in Different Geographical Areas: Scoping Review. *Dent J (Basel).* 2021; 9(10):117.
19. Susarla SM, Abramson ZR, Dodson TB, Kaban LB. Cephalometric Measurement of Upper Airway Length Correlates With the Presence and Severity of Obstructive Sleep Apnea. *J Oral Maxillofac Surg.* 2018; 68(11):2846–55.
20. Chung ILM, Beltri Orta P. Comparison of cephalometric patterns in mouth breathing and nose breathing children. *Int J Pediatr Otorhi.* 2014; 78:1167–1172.
21. Flores-Mir C, Korayem M, Heo G, Witmans M, Major MP, Major PW. Craniofacial morphological characteristics in children with obstructive sleep apnea syndrome: a systematic review and meta-analysis. *J Am Dent Assoc.* 2013; 144:269–277.
22. Zheng ZH, Yamaguchi T, Kurihara A, Li HF, Maki K. Threedimensional evaluation of upper airway in patients with different anteroposterior skeletal patterns. *Orthod Craniofac Res.* 2014; 17:38–48.
23. Jakobsone G, Stenvik A, Espeland L. The effect of maxillary advancement and impaction on the upper airway after bimaxillary surgery to correct Class III malocclusion. *Am J Orthod Dentofacial Orthop.* 2011; 139:369–376.
24. Schendel SA, Jacobson R, Khalessi S. Airway growth and development: a computerized 3-dimensional analysis. *J Oral Maxillofac Surg.* 2012; 70:2174–83.
25. Panou E, Motro M, Ates M, Acar A, Erverdi N. Dimensional changes of maxillary sinuses and pharyngeal airway in class III patients undergoing bimaxillary orthognathic surgery. *Angle Orthod.* 2013; 83:824–31.
26. Alsufyani NA, AL-Saleh MA, Major PW. CBCT assessment of upper airway changes and treatment outcomes of obstructive sleep apnoea: a systematic review. *Sleep Breath.* 2013; 17:911–23.

UNDER PEER REVIEW