

Case study

ANTI COLTON-A FOETO-NEONATAL HAEMOLYTIC DISEASE: DIAGNOSIS; CLINICAL OUTCOME AND FAMILY STUDY.

Abstract

The authors report a case of neonatal hemolytic disease (HDN) attributable to maternal allo immunization to a high frequency antigen present on paternal red blood cells which has been identified as Colton-a (Co^a).

The case seemed worthy of reporting not only for the relative rarity of HDN from anti Co^a but for the rigorous approach followed in the immunohaematological follow-up of pregnancy and for the diagnostic effort expended in identifying the specificity of the antibody. A family study of ascendants, collaterals and descendants was also carried out using genotyping techniques.

Key-words

Anti-Co^a, Family study, Genotyping, HDFN,

Short Title: HGFN and anti-Co^a

Introduction

Haemolytic disease of the foetus and new-born (HDFN) is a clinical condition that occurs as a result of haemolysis of foetal or neonatal red blood cells (RBCs) due to maternal red cell IgG antibodies that can cross the placenta. Active transplacental transfer of maternal antibodies via the neonatal Fc receptor will take place when the antibody production has switched from the initial IgM response to IgG; transfer will accelerate in the 2nd and 3rd trimester and can lead to HDFN [1]. The clinical onset of HDFN is characterized by foetal and neonatal anaemia with erythroblastosis fetalis, hepatic dysfunction leading to hypoalbuminemia, ascites, hydrops, congestive heart failure, intrauterine growth retardation, acute bilirubin encephalopathy and kernicterus spectrum disorder [1,2].

Clinically significant red cell alloantibodies are those that have the potential to cause haemolysis of red cells bearing the corresponding antigen [1]. Maternal antibodies capable of causing HDFN could either be ABO antibodies or non-ABO alloantibodies that can develop in the mother due to sensitization following a blood transfusion or previous pregnancy with red cell antigenic differences [2]. Before the introduction of immunoprophylaxis with RhIG, maternal anti-D alloimmunization was the most common cause of HDFN. However, strict implementation of RhIG prophylaxis has drastically reduced the incidence of anti-D associated HDFN over the last half-century. Introduction of postnatal RhIG administration in the late 1960s brought the incidence of RhD associated HDFN in the USA down from 45.1 per 10,000 births in the early 1970s to 10.6 per 10,000 births in the mid-1980s [3]. The incidence of RhD associated HDFN decreased further to as low as 0.1% with the implementation of antenatal RhIG immuno-prophylaxis [4]. Consequently, ABO and other maternal alloantibodies have now emerged as a major cause of HDFN in developed countries [2]. Studies investigating the prevalence of red cell alloantibodies amongst pregnant women have been done in different western countries and prevalence of clinically significant red cell alloantibodies has been reported to be anywhere between 0.3% and 3.4% in different studies [5–8].

Case Report

Patient BL, born on February 6 1983, in the 28th week of pregnancy, came to our observation in September 2021, sent for consultation by a spoke hospital in order to investigate a positive indirect antiglobulin test (IAT).

The IAT positivity was detected at the first control carried out at the beginning of pregnancy, the titre was low (1/2) and the involved immunoglobulin class was IgG without the implication of complement fractions. It was not possible to identify the specificity of the antibody which was pan-reactive with all the test red blood cells within the group O polyantigenic panels we used. As pregnancy progressed, a constant increase of the antibody titre was observed and in the 27th week of gestation it reached 1/256 (see figure 1).

An evaluation of the pathological and obstetric anamnesis was carried out at our outpatient clinic. The patient reported a first pregnancy in 2020, full-term, with operative delivery, male newborn, group O+, DAT negative. The infant developed mild hyperbilirubinemia treated with phototherapy after delivery. The IAT performed postpartum was negative. In 2021 the patient experienced a miscarriage, two IATs were performed - the first immediately and the second after two weeks - and both were negative. The pathological history was essentially silent. Routine examinations showed only a lengthening of activated partial prothrombin time (aPTT) which was investigated by searching for lupus anticoagulant and antiphospholipid autoantibodies, dosage of FVII, FVIII, FIX, FXI and FXII - all resulting within the norm. The presence of organ- and non-organ-specific autoantibodies was then searched for, with negative results.

At our laboratory patient BL was extensively studied from an immuno-haematological point of view: she typed A positive, CcDee kk. IAT positivity was confirmed by the presence of a pan-agglutinating IgG class antibody on all available panels of group O polyantigenic red blood cells. The positivity was present and remained unchanged both using untreated and enzyme-treated red blood cells. The reaction was detectable only using the Liss-Coombs method at 37°, while it was not detectable in saline solution at 4°C or 20°C (see figure 2). Negative DAT and negative autologous control tests were confirmed (which made the presence of an autoantibody unlikely). Extended serotyping was also performed, and patient BL resulted Fy (a-b+), Jk (a-b+), MNss, Le (a-b+), Lu (a-b+). As routinely done in our structure, we simultaneously performed an immuno-haematological study of the patient's partner (indicated as DS) who was group B positive, CcDee kk Fy (a-b+), Jk(a-

b+), MNss, Le (a-b+), Lu (a-b+). Hence, based on the serological studies, no specific antigens were identified which could induce an immunization with the observed pan-reactive pattern. Investigating the hypothesis of an allo-antibody directed towards a high frequency antigen, we decided to proceed with genotyping both BL and DS. The genotyping panel included the following systems: Rh, Kell, Kidd, Duffy, MNSs, Lutheran, Diego, Colton, Dombrock, Landsteiner-Wiener, Scianna. The result of genotyping – reported in table I – was one single incompatibility: BL showed the rare Colton (a-b+) predicted phenotype (reported in less than 0.3% of the Caucasian population) while DS showed the common Co (a+b-) phenotype. The possible presence of an allo-antibody with anti-Colton-a specificity was therefore further investigated by sending a fresh blood sample from patient BL to the Immuno-haematology Reference Laboratory of Policlinico in Milan, where the specificity against Colton-a was confirmed. As reported in figure 3 a family study was also conducted with regard to Colton genotyping, showing the peculiarity of BL's condition and the role of Colton-a incompatibility in her pregnancies.

Delivery took place on day November 3rd, at 36+2 gestational week w by elective caesarean section. The newborn (DL) was a male with Apgar index 9/10/10, weight 2,120 g (2nd percentile), length 45 cm (5th percentile), head circumference 33 cm (29th percentile); Blood testing result of the newborn was AB positive, DAT weakly positive (+---) for IgG but not for complement fractions, eluate testing positive. DL was discharged from Hospital on the third day of life weighing 2,000 g. On November 9th a check was carried out during which a marked icteric complexion was found, with the child in good general condition and normal neurological examination, total bilirubin 26.26 mg/dl, of which 0.76 mg/dl direct, therefore phototherapy and intravenous hydration was administered, but considering the obstetric history arrangements were made for the transfer of the baby to Neonatal Intensive Care Units in Treviso. Upon admission to the ward, pan phototherapy was started in association with intravenous hydration and intravenous single dose (1 g/Kg) administration with immunoglobulins. Although the transfusion network of the Veneto Region was activated for the retrieval of Co(a-b+)red blood cells, DL did not need exchange transfusion or conventional transfusion support as he developed only a modest anaemia (Hb 139 g/L) and the serial checks of the capillary bilirubin showed a rapid and gradual reduction of the values down to safe levels. Phototherapy was then suspended on November 10th and the patient could be discharged on November 13th. One year after birth, DL had regular psycho-somatic growth: length 79 cm (88th percentile), weight 12.1 kg (92nd percentile) no neurological relics were observed.

Discussion

In 1965 in Oslo, Norway, the discovery of an antibody targeting a “public” (or high prevalence) antigen was linked to other cases reported earlier in Minneapolis, Oxford, and London. The antigen was named Co^a (Colton a) in 1967, after the name of the first patient showing the presence of these antibodies, while three years later the antithetical antigen, Co^b, was first described. In the analysis of unrelated people of European ethnicity, the occurrences of the three major Colton phenotypes were as follows: Co (a+b-) 0.914, Co (a+b+) 0.084, and Co (a-b+) 0.002 [9-11]. CO*A and CO*B are codominant alleles of the AQP1 gene located in the short arm of chromosome 7. Product of this gene is a transmembrane water channel protein, aquaporin-1 (AQP-CHIP), which is found in the membranes of erythrocytes and renal epithelial cells of the proximal tubule. Further characterization of this protein indicates that Co^a and Co^b antigens correspond to the respective presence of alanine or valine at position 45 within the first extracellular loop of aquaporin-1 [12-15].

Antibodies to Colton blood group antigens are generally IgG and react best by the antiglobulin test, especially when protease-treated RBCs are used. Some anti-Co^a and some anti-Co^b may bind complement. Few reports of significant delayed or acute transfusion reactions or haemolytic disease of the foetus and newborn attributable to anti-Co^a have been reported, although both are known to occur with severe morbidity; anti-Co^b is relatively rare and often found in patient's sera containing other alloantibodies. In vivo studies have shown that anti-Co^a and anti-Co^b antibodies are able to reduce the survival of targeted erythrocytes [16]. There are also reports of auto-antibodies mimicking Colton specificities [13-15].

The case presented in this paper seemed worthy of reporting for several reasons. Diagnosis and management of anti-Co^a alloimmunisation during pregnancy is a rare and challenging condition and only few cases have been reported in literature, mainly in the 1970s; moreover diagnosis and management has changed in the meantime [16]. Alloimmunisation of a Co^a negative pregnant woman, carrying a Co^a positive foetus, may cause HDFN. In order to closely monitor a foetus at risk of developing HDFN complications, a pregnancy follow-up with repeated doppler flow measurements of the peak systolic velocity of the middle cerebral artery is recommended. On the other hand, antibody titration seems to be of little help in defining the risk of developing foetal anaemia, due to the lack of a correlation between the observed titre increase and the onset of

clinical manifestation, and to the fact that different analytical methods may result in different titration values. In the case reported here doppler flow measurements always gave normal results, while antibody titration showed a constant increase. The foetus suffered only a moderate HDFN, characterized by significant hyperbilirubinemia and mild anaemia. Transfusion therapy was not necessary and the baby responded promptly to post-natal phototherapy, hydration and intravenous IgG injection. In this clinical scenario the significance of antibody titration remained unclear.

Transfusion therapy in these patients can be very problematic due to the difficulty of finding Co^a negative red blood cells. In the case described we made available 4 units of RBC thanks to the support of the transfusion network of the Veneto Region and the collaboration of the Immuno-haematology Reference Laboratory of Policlinico in Milan.

In order to reach to a positive outcome in such complex cases, not only the monitoring and the treatment are crucial, but also a rigorous methodological approach to immunohaematological diagnosis is needed, starting from the confirmation of the results observed in the spoke structure, moving on to further investigations through extensive phenotyping, antibody characterization, studies with enzymes and genotyping.

A final, non-secondary point of interest is the Colton genotyping study we conducted on BL's family, which allowed us to conclude that the pregnancy issues BL has encountered in her life are most likely linked to the lack of CO*A, while this specific trait is present in the rest of her family.

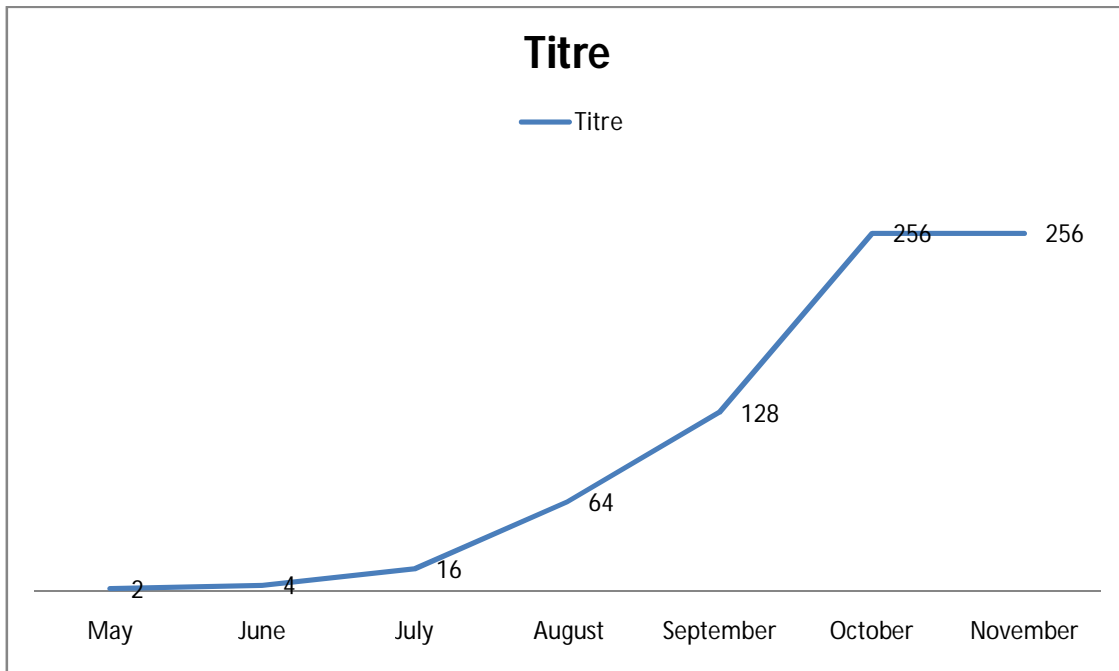
In this report we describe a case of HDFN attributable to an allo-antibody with Colton-a specificity. The rarity of this antibody and the complexity of the diagnostic process, which included a genomic study of the entire propositus' family, make this report interesting in the field of obstetrical and gynaecological practice.

References

1. Milkins C, Berryman J, Cantwell C, et al. Guidelines for pre-transfusion compatibility procedures in blood transfusion laboratories. British Committee for Standards in Hematology. *Transfus Med.* 2013;23(1):3–35. doi:10.1111/j.1365-3148.2012.01199.x
2. Basu S, Kaur R, Kaur G. Hemolytic disease of the fetus and newborn: current trends and perspectives. *Asian J Transfus Sci.* 2011;5 (1):3–7. doi:10.4103/0973-6247.75963
3. Chavez GF, Mulinare J, Edmonds LD. Epidemiology of Rh hemolytic disease of the newborn in the United States. *J Am Med Assoc.* 1991;265(24):3270–3274. doi:10.1001/jama.1991.03460240066029

4. Liembruno GM, D'alessandro A, Rea F, et al. The role of antenatal immunoprophylaxis in the prevention of maternal foetal anti Rh (D) alloimmunisation. *Blood Transfus.* 2010;8(1):8–16. doi:10.2450/2009.0108-09
5. Dajak S, Stefanović V, Capkun V. Severe hemolytic disease of fetus and newborn caused by red blood cell antibodies undetected at first-trimester screening. *Transfusion.* 2011;51(7):1380–1388. doi:10.1111/j.1537-2995.2010.03006.x
6. Smith HM, Shirey RS, Thoman SK, Jackson JB. Prevalence of clinically significant red blood cell alloantibodies in pregnant women at a large tertiary-care facility. *Immuno-hematology.* 2013;29(4):127–130.
7. Solves P, Gomez-Segui I, Guinot M, et al. Prevalence of red cell antibodies in pregnant women and hemolytic disease of newborn in a tertiary care hospital. *ARC J Gynaecol Obstet.* 2017;2(2):18–22.
8. Erikstein BS, Hagen KG, Hervig T. RBC alloantibody prevalence and specificity in a Western Norwegian tertiary hospital. *Transfus Med.* 2018. doi:10.1111/tme.12511
9. Heistö H, van der Hart M, Madsen G, et al. Three examples of a new red cell antibody, anti-Coa. *Vox Sang* 1967;12:18–24.
10. Reid ME, Lomas-Francis C. The blood group antigen factsbook. 2nd ed. San Diego, CA: Academic Press, 2004.
11. Wray E, Simpson S. A further example of anti-Coa and two informative families with Co(a-) members. *Vox Sang* 1968;14:130–2.
12. Smith BL, Preston GM, Spring FA, Anstee DJ, Agre P. Human red cell aquaporin CHIP. I. Molecular characterization of ABH and Colton blood group antigens. *J Clin Invest* 1994;94:1043–9.
13. Giles CM, Darnborough J, Aspinall P, Fletton MW. Identification of the first example of anti-Cob. *Br J Haematol* 1970;19:267–9.
14. Lewis M, Kaita H, Anderson C, Chown B. Independence of Colton blood group. *Transfusion* 1971;11:223–4.
15. Zelinski T, Kaita H, Gilson T, Coghlan G, Philipps S, Lewis M. Linkage between the Colton blood group locus and ASSP11 on chromosome 7. *Genomics* 1990;6:623–5.
16. Kurtz SR, Kuszaj T, Ouellet R, Valeri CR. Survival of homozygous Coa (Colton) red cells in a patient with anti-Coa. *Vox Sang* 1982;43:28–30.
17. Covin RB, Evans KS, Olshock R, Thompson HW. Acute hemolytic transfusion reaction caused by anti-Coa. *Immuno-hematology* 2001;17:45–9.
18. Simpson WKH. Anti-Coa and severe haemolytic disease of the newborn. *S Afr Med J* 1973;47:1302–4.
19. Michalewska B, Wielgos M, Zupanska B, Bartkowiak R. Anti-Coa implicated in severe haemolytic disease of the foetus and newborn. *Transfus Med* 2008;18:71–3.

Figure 1: Antibody titre trend during pregnancy

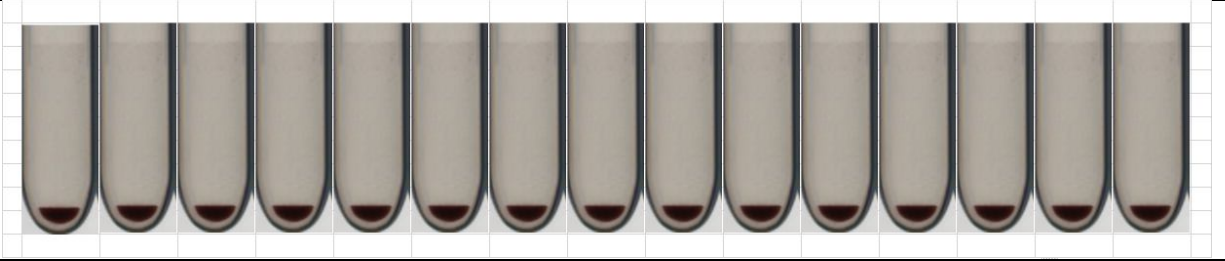


As shown in the figure, during pregnancy the antibody titre progressively increased from 1/2 to 1/256.

UNDER PEER REVIEW

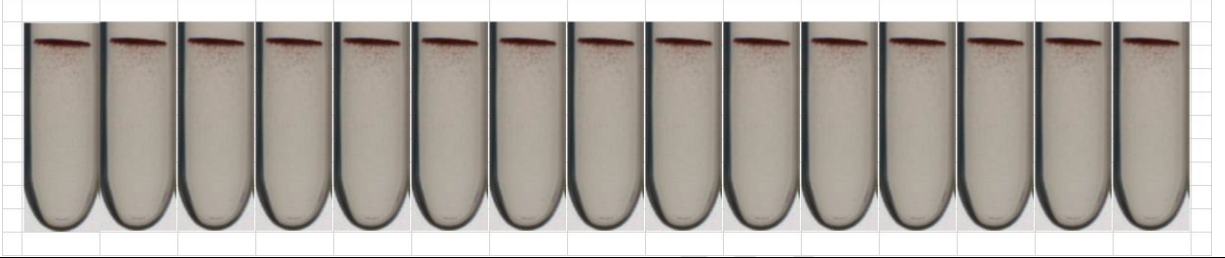
Figure 2: Characterization of the allo antibody in patient BL

Figure 2a: Test performed in saline solution at +22°C, untreated panel.



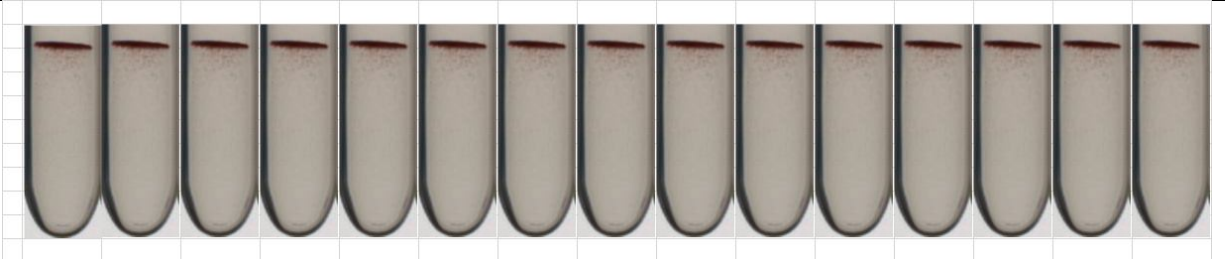
No reactivity was observed

Figure 2b: Test performed in liss-Coombs at 37°C, untreated panel.



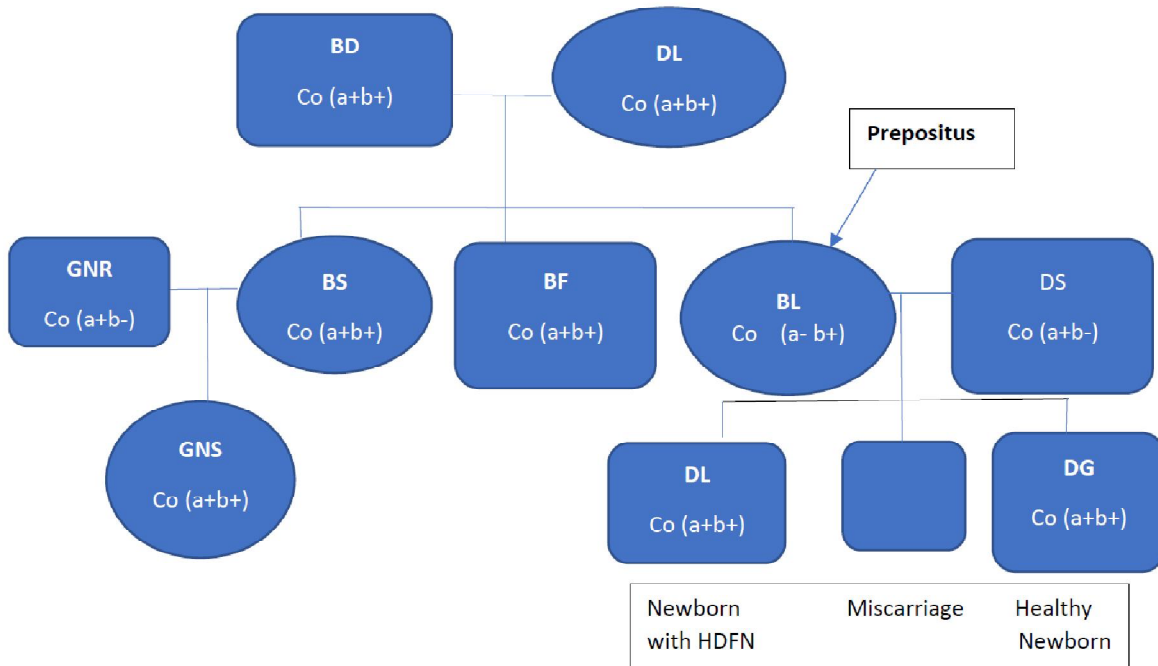
An antibody reactive with all the cells making up the panel was highlighted without differences in the reaction score

Test performed in liss-Coombs at 37°C. panel treated with ficin



An antibody reactive with all the cells making up the panel was highlighted without differences in the reaction score

Figure 3: Familiar study



As indicated in the figure, starting with patient BL (prepositus), we performed a family study that took into consideration ascendants, collaterals, affines and descendants. BL's parents (BD and DL) were heterozygous Co (a+b+). Of the three children, BL was homozygous Co (a-b+) while the brother (BF) and sister (BS) were both heterozygous Co (a+b+). Both sisters were pregnant at the time of observation and therefore we performed genotyping for the Colton system for both husbands (DF and GNR) which resulted Co (a+b-). the daughter of BS and GNR (GNS) was heterozygous Co (a+b+). BL and DF had a first healthy heterozygous Co (a+b-), child (DG). A second pregnancy resulted in abortion. The second child DL heterozygous Co (a+b+) who developed a moderate HDFN.

Table I: Genotyping of BL and DS

Blood Groups	Antigen	DS	BL
Rh	c	Positive	Positive
	C	Positive	Positive
	e	Positive	Positive
	E	Negative	Negative
Kell	K	Negative	Negative
	k	Positive	Positive
	Kpa	Negative	Negative
	Kpb	Positive	Positive
	Jsa	Negative	Negative
	Jsb	Positive	Positive
Kidd	Jka	Negative	Negative
	Jkb	Positive	Positive
Duffy	Fya	Negative	Negative
	FYb	Positive	Positive
MNSs	M	Positive	Positive
	N	Positive	Positive
	S	Negative	Negative
	s	Positive	Positive
Lutheran	Lua	Negative	Negative
	Lub	Positive	Positive
Diego	Dia	Negative	Negative
	Dib	Positive	Positive
Colton	Coa	Positive	Negative
	Cob	Negative	Positive
Dombrock	Doa	Positive	Positive
	Dob	Negative	Positive
	Joa	Positive	Positive
	Hy	Positive	Positive
Scianna	Sc1	Positive	Positive
	Sc2	Negative	Negative