

## **Original Research Article**

### **Haematological and Hepatorenal Alterations Induced by Potash (*Akanwu*) on Male Wistar Rats**

#### **Abstract**

#### **Introduction**

Potash refers to the various naturally occurring water-soluble compounds of potassium used as a traditional food additive in Nigeria. Several health warnings have highlighted the deleterious effect of their consumption.

#### **Aim**

The present study is aimed at evaluating the effects of graded doses of potash consumption on haematological and hepatorenal indices using Wistar rat models.

#### **Materials and Methods**

Potash was locally sourced and the elemental composition was determined by X-Ray diffraction (XRD). Twenty (20) male Wistar rats (170 – 200g) were used for the study and were divided into four (4) groups of five (5) animals each. Group 1 served as the control while Groups 2 – 4 served as the experimental group and received an aqueous mixture of potash via oral gavage at 200, 400 and 800mg/kg respectively for thirty (30) days.

#### **Results**

XRD elemental analysis of potash revealed the presence of potassium (27.44%), phosphorus (14.27%), antimony (5.18%), barium (4.27%), fluorine (2.78%), cadmium (2.06%), yttrium (1.63%), tellurium (1.32%), caesium (1.12%), niobium (1.04%), sodium (0.42%) and germanium (0.06%). Results from haematological and hepatorenal parameters show a significant reduction in mean values of red blood cell count, haemoglobin concentration and packed cell volume among the experimental groups compared to control ( $p < 0.05$ ) and significantly increased mean corpuscular volume, mean corpuscular haemoglobin, white blood cell count, lymphocytes, neutrophils, MID cell percentage, aspartate aminotransferase, alanine aminotransferase, alkaline phosphatase, urea, creatine, sodium, potassium and chloride ions among the experimental group compared to the ( $P < 0.05$ ).

#### **Conclusion**

The data presented has shown that the chronic consumption of potash at 800mg/kg can negatively alter the haematological and hepatorenal profiles of Wistar rats. Therefore, this study considers potash, a possible toxicant to the blood, liver and kidney.

**Keywords:** Potash, *akanwu*, Haematology, Hepatorenal, Liver and Kidney

#### **INTRODUCTION**

Potash is the term commonly associated with various naturally mined compounds of potassium (potassium sulfates, hydroxides, chlorates, nitrates and carbonates). Potash refers to water-

soluble crude and manufactured potassium carbonate produced by the leaching of wood ashes soaked in large pots long before industrial advancement [1, 2]. Potash ore deposits are also found below the earth's surface as potash salts in evaporite sequences in pre-Quaternary sedimentary basins formed in arid climates with restricted seawater [3]. They are obtained by shaft or dissolution mining [4]. They typically exist as white or a mixture of grey and reddish brown depending on the presence of other trace elements like Iron and Manganese [5].

In Nigeria, potash is traditionally called *kaun*, *kanwa* and *akanwu* by the Yoruba, Hausa and the Igbos respectively while the Igalas and the Egbira refer to them as *okanwa* and *ikoro* respectively. Huge deposits are found in northern Nigeria like Kano and Maiduguri and other border countries like Niger and Chad [5, 6]. It is widely used in the local production of fertilizers, soap, fire extinguishers and bleaching textiles with varying uses for culinary and medicinal purposes. They are traditionally used as a tenderizing agent in cooking beans, breadfruit (*ukwa*), black Mexican beans (*akidi*) and cowpea beans (*fiotio*) and cowhide (*ponmo*). Also employed to retain and enhance the green colour of jute leaves (*ewedu*) and okra vegetables and to emulsify oil and water in the preparation of local delicacies like *nkwobi ugba* and *abacha*. In folk medicinal applications, they are used in the treatment of stomach ache, toothache, cough and constipation. They have also found use among nursing mothers to enhance lactation [7-9].

Haematological and hepatorenal parameters are vital indicators of the overall health status and the functional state of vital organs in the body and can be used to assess the presence of diseases, the functioning of the immune system, the body's nutrient levels and more importantly, the possible toxicity of certain chemicals on body organs like the heart, kidney and liver [10, 11].

Despite its aforementioned culinary and medicinal uses, several research reports have documented experimental evidence of some of the hazardous effects of potash consumption. It has been found to be injurious to the liver [8, 12], the kidney [2] and the heart [13] and sperm cells [14]. However, studies on their possible haematological alterations are scarce, hence the present study aims to evaluate the effects of graded doses of potash consumption on haematological and hepatorenal indices using Wistar rat models to plug this knowledge gap.

## **MATERIALS AND METHODS**

### **Procurement and Identification of Potash**

Potash was sourced from the local market in Choba, Port Harcourt and the samples were authenticated at the Department of Geology, University of Port Harcourt. Chemical components of the Potash were identified using X-Ray Diffraction (XRD) method (Olympus, TERRA-575, USA) at the Department of Pure and Applied Chemistry, University of Port Harcourt.

### **Experimental Animals**

Ten (10) male mice (20 – 30g) were used for the determination of the LD<sub>50</sub> while twenty (20) male Wistar rats (170 – 200g) were used for the experimental study. These animals were sourced from the animal house of the Department of Pharmacology, University of Port Harcourt. The animals were allowed to acclimatize for four (4) weeks before the commencement of the experimental study. The animals were allowed standard rat chow and water *ad libitum* under

standard hygienic animal husbandry conditions: room temperature (25°C), relative humidity (45 to 55%), and 12 hours of light/dark cycle.

### **Determination of LD50**

Acute toxicity test Potash was carried out using Lorke's method as previously described [15-17]. Potash was thoroughly mixed with water and constituted into 10, 100 and 100mg/kg and administered to three (3) groups of mice of two (2) mice per group. In the same way, the potash was constituted into 4000, 8000 and 1600mg for the second phase and administered to three (3) groups of mice of one (1) mouse per group. The animals were regularly monitored for signs of toxicity: decreased body/limb movement, respiration and eventual mortality.

The LD50 was calculated as follows:

$$LD_{50} = \sqrt{D_0 \times D_{100}}$$

Where  $D_0$  = Highest dose that gave no mortality.

$D_{100}$  = Lowest dose that produced mortality.

The LD<sub>50</sub> of the potash sample was determined to be >2000mg/kg

### **Experimental Design**

Twenty (20) male Wistar rats (170 – 200g) were randomly divided into four groups (4) of five (5) animals each and treated as follows for thirty (30) days: Group 1 served as the control and received distilled water, while the experimental groups 2, 3 and 4 received 200, 300 and 400mg/kg of an aqueous mixture of potash respectively.

### **Blood Collection and Assay**

Following the 30 days administration of an aqueous mixture of potash for the experimental group and distilled water for the control group, the animals were anaesthetized using cervical dislocation and blood was collected by cardiac puncture. Blood samples were transferred into EDTA bottles for haematological assay (Autohaematology Analyzer, Mindray, China) and dry sample bottles for biochemical analysis using standard test kits (Randox, UK).

### **Statistical Analysis**

Data were subjected to statistical analysis using SPSS v25. The mean and standard error of the mean were determined. The mean of the experimental groups was compared to that of the control group using the one-way ANOVA followed by an LSD post hoc analysis. The difference in means was considered significant at  $P < 0.05$ .

## **RESULTS**

**Table 1:** Elemental composition of Potash

Element	Amount (weight %)
Oxygen (O)	27.64%
Potassium (K)	27.44%

Phosphorus (P)	14.27%
Antimony (Sb)	5.18%
Barium (Ba)	4.27%
Fluorine (F)	2.78%
Cadmium (Cd)	2.06%
Yttrium (Y)	1.63%
Tellurium (Te)	1.32%
Caesium (Cs)	1.12%
Niobium (Nb)	1.04%
Sodium (Na)	0.42%
Germanium (Ge)	0.06%
Lee (sum)	31.36%

**Table 2:** Chemical Composition of Potash

Chemical Compound	Chemical formula	Amount (%)	Total number of peaks
	$\text{KH}_2\text{PO}_3$	55.4%	992
Lime	CaO	12.6	20
Potassium	K	9.4%	24
	$\text{NaCaCdYF}_8$	7.6%	26
	$\text{Ba}_3\text{O}_6\text{Te}$	6.6%	306
Antimony	Sb	5.2 %	18
Cesium germanium tridecaniobate	$\text{Cs}_{85}\text{Ge}_8$	3.2%	166

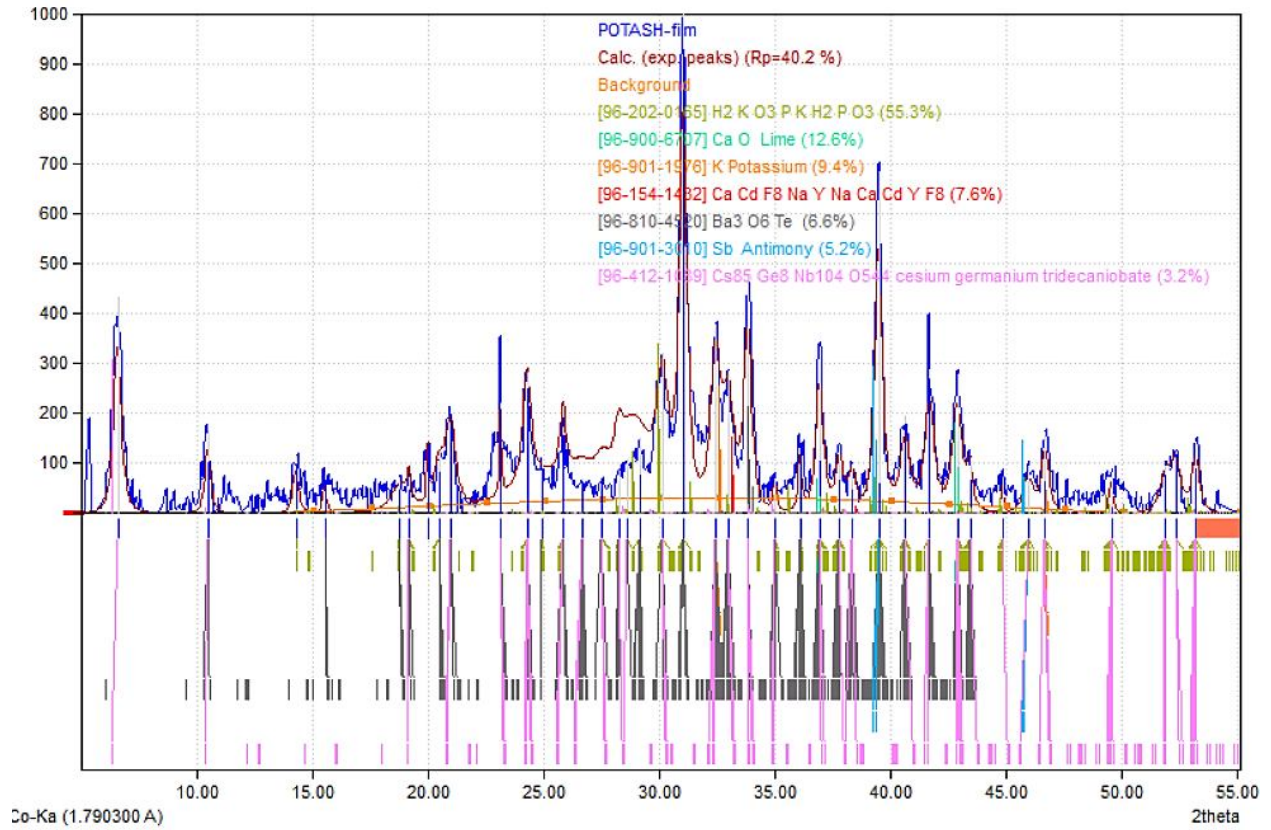


Figure 1. XDR Diffraction Pattern of the chemical components of Potash

**Table 3.** The Effect of potash on haemoglobin concentration, packed cell volume, red blood cell and red blood cell indices of Wistar Rats

Parameters	Control (n=5)	200mg/kg (n=5)	400mg/kg (n=5)	800mg/kg (n=5)
Red blood cell ( $\times 10^{12}/L$ )	8.79 $\pm$ 0.24	6.90* $\pm$ 0.53	5.60* $\pm$ 0.60	5.68* $\pm$ 0.63
Haemoglobin concentration (g/dl)	16.56 $\pm$ 0.74	13.28* $\pm$ 0.98	11.42* $\pm$ 1.12	12.76* $\pm$ 0.76
Packed cell volume (%)	46.94 $\pm$ 1.15	49.94 $\pm$ 3.37	41.32* $\pm$ 3.37	34.02* $\pm$ 3.98
Mean corpuscular volume (fL)	56.86 $\pm$ 0.83	59.73* $\pm$ 0.72	60.42* $\pm$ 0.98	60.42* $\pm$ 2.20
Mean corpuscular haemoglobin (pg)	18.82 $\pm$ 0.52	19.26 $\pm$ 0.45	20.49 $\pm$ 0.34	23.45* $\pm$ 2.30
Mean corpuscular haemoglobin concentration (g/dL)	33.15 $\pm$ 0.51	32.27 $\pm$ 0.51	33.11 $\pm$ 3.30	34.37 $\pm$ 0.97

Result is given as mean $\pm$ standard error of mean;\*significantly different compared to control (p<0.05)

Table 3 shows the alterations in haemoglobin concentration, packed volume, red blood cell and red blood cell in indices of Wistar following a 30 administration of graded doses of an aqueous mixture of potash. The result indicates that the red blood cell count and haemoglobin concentration were significantly decreased among Wistar rats treated with 200, 400 and 800mg/kg of potash compared to the control (p<0.05). Similarly, packed cell volume was significantly decreased for rats treated with 400 and 800mg/kg of potash compared to the control (P<0.05). However, the mean corpuscular volume significantly increased for rats treated with 200, 400 and 800mg/kg of potash (p<0.05) while the mean corpuscular haemoglobin was significantly increased for animals that received 800mg/kg potash compared to the control group (p<0.05). There were no significant changes in the mean corpuscular haemoglobin concentration among the research groups.

**Table 4:** Effect of Potash on total white blood cells, white blood differentials and platelets of Wistar Rats

Parameters	Control (n=5)	200mg/kg (n=5)	400mg/kg (n=5)	800mg/kg (n=5)
While blood cells ( $\times 10^9/L$ )	8.74 $\pm$ 1.42	6.92 $\pm$ 1.07	6.88 $\pm$ 1.03	12.40* $\pm$ 1.31
Lymphocytes ( $\times 10^9/L$ )	5.60 $\pm$ 0.78	6.06 $\pm$ 1.27	7.32 $\pm$ 0.56	9.90* $\pm$ 0.67
Neutrophil ( $\times 10^9/L$ )	1.08 $\pm$ 0.49	1.96 $\pm$ 0.48	0.80 $\pm$ 0.21	4.82* $\pm$ 1.17
MID cells percentage ( $\times 10^9/L$ )	1.22 $\pm$ 0.27	0.84 $\pm$ 0.27	0.40 $\pm$ 0.23	2.54 $\pm$ 0.95
Platelets	564.80 $\pm$ 85.29	664.20 $\pm$ 136.72	513.20 $\pm$ 44.39	559.55 $\pm$ 44.39

Result is given as mean $\pm$ standard error of mean;\*significantly different compared to control (p<0.05)

Table 4 shows the variations in the mean levels of platelets, white blood cell count and white blood differentials of Wistar following 30 days of oral administration of graded doses of an aqueous mixture of potash. The result indicates that the total white blood cell count, lymphocytes, neutrophil and MID cell percentage were significantly increased among Wistar rats treated with 800mg/kg of an aqueous mixture of potash compared to the control group (p<0.05). There were no significant alterations in the platelet count among the research groups.

**Table 5:** Effect of some biochemical parameters of Wistar rats

Parameters	Control (n=5)	200mg/kg (n=5)	400mg/kg (n=5)	800mg/kg (n=5)
Aspartate aminotransferase (U/L)	11.26±2.59	18.37±2.00	25.02*±1.49	34.58*±3.34
Alanine aminotransferase (U/L)	44.35±1.95	44.71±2.36	48.72±1.46	51.08*±0.23
Alkaline phosphatase ALP (U/L)	51.06±0.29	52.05±2.26	54.47±1.92	56.05*±0.38
Sodium ion (mmol/L)	136.06±1.29	160.72*±3.53	183.66*±2.13	159.33*±2.13
Potassium ion (mmol/L)	2.87±2.40	3.20*±0.13	3.38*±2.87	3.83*±0.10
Chloride ion (mmol/L)	134.10±1.32	132.03±1.74	137.10±2.50	144.20*±0.13
Urea (mg/dL)	14.4±1.32	18.73±1.38	29.84*±1.07	24.21*±1.82
Creatinine (mg/dL)	0.44±0.17	0.56±0.04	0.89*±0.04	0.64*±0.07
Result is given as mean±standard error of mean; *significantly different compared to control (p<0.05)				

Table 5 presents the mean levels of some hepatorenal parameters of Wistar rats following 30 days of oral administration of graded doses of an aqueous mixture of potash. The results indicate that the mean level of aspartate aminotransferase was significantly increased among rats treated with 400 and 800mg/kg of potash compared to the control group ( $p<0.05$ ) while the mean levels of alanine aminotransferase and alkaline phosphatase were significantly increased only for rats treated with 800mg/kg of potash compared to the control group. Also, a significant increase in sodium and potassium ions was observed for animals treated with 200, 400 and 800mg/kg of potash while only the animals treated with 800mg/kg of potash showed a significant increase in chloride ions when compared with the control ( $P<0.05$ ). Urea and creatinine levels were found to increase among the groups treated with 400 and 800mg/kg of potash compared to the control ( $p<0.05$ ).

## DISCUSSION

The present study determined the chemical components of a locally sourced potash sample by X-Ray Diffraction (XRD) and assessed the effect of its oral consumption on haematological and some hepatorenal parameters using Wistar rat models.

Our sample of potash revealed detectable quantities of potassium (27.44%), phosphorus (14.27%), antimony (5.18%), barium (4.27%), fluorine (2.78%), cadmium (2.06%), yttrium (1.63%), tellurium (1.32%), caesium (1.12%), niobium (1.04%), sodium (0.42%) and germanium (0.06%) as shown in Table 1. Similar elemental composition of potash has been previously reported [18, 19]. However, using a more advanced Energy-dispersive X-ray fluorescence (EDXRF) spectrometry, Uzoho *et al.* reported the presence of manganese, iron, zinc, copper, lithium and aluminium [20]. Among the locals in Nigeria, it is increasingly becoming difficult to distinguish between greyish-white crystal soda *akanwu* (also referred to as Trona and Natron) and yellowish-white crystal *akanwu* (also referred to as potash) [9]. The result of our elemental analysis indicates that our sample of "potash" (*akanwu*) is crystal Potash ( $K_2CO_3 \cdot 2H_2O$ ) and not Trona ( $Na_2CO_3 \cdot Na_2CO_3 \cdot 2H_2O$ ) or Natron ( $Na_2CO_3 \cdot NaHCO_3 \cdot 2H_2O$ ) [20]. The naturally occurring *akanwu* mineral varieties

(Potash, Trona, Natron) are known to contain other impurities like sand, silicon, quartz, clay and titanium [9, 19], hence some of the slight chemical differences are attributable to the nature and source of the potash [1].

Significant reduction in the mean values of haemoglobin concentration (Hb), packed cell volume (PCV) and red blood cell (RBC) among the rats treated with an aqueous mixture of potash compared to the control group ( $p < 0.05$ ) (Table 3). The marked reduction in RBC, Hb and PCV could be attributed to the deleterious effect of cadmium which was found to be a detectable chemical component of our potash sample. The presence of cadmium in the blood has been shown to stimulate the formation of reactive oxygen species causing oxidative stress. This leads to lipid peroxidation, causing RBC membrane damage haemolysis and possible impairment of haemoglobin synthesis [21, 22]. Also, other contaminants of potash like quartz are known to remain unaltered in the gastrointestinal system where they cause irritations, abrasion and the reduction of the absorption of vital micro and macro elements required for erythropoiesis [17, 23] and possibly leading to anaemia. This could lead to anaemia. However, the result of the present study indicates that the mean corpuscular volume (MCV) and mean corpuscular haemoglobin (MCH) significantly increased among the experimental groups compared to the control ( $P < 0.05$ ). MCV and MCH are measures of the average size and haemoglobin content in red blood cells respectively. Where RBC is reduced as observed in the present study, the MCV may be increased as seen in macrocytosis or megaloblastic anaemia. In the same way, the MCH may increase as compensation to maintain oxygen delivery to the tissue [24-26]. Evbu *et al.* [18] observed no significant changes in the RBC, Hb and PCV of Wistar rats following a 28 days Trona administration while Ani *et al.* [27] observed significantly lower RBC, Hb and PCV among Wistar animals fed with Natron.

The present study observed a significant increase in white cell count (WBC), lymphocytes, neutrophil and MID cell and the percentage were significantly increased among Wistar rats treated with 800mg/kg of an aqueous mixture of potash compared to the control group ( $p < 0.05$ ). This could be due to the presence of heavy metals such as barium, cadmium, yttrium, tellurium, caesium, niobium, germanium and possibly other impurities contained in the potash sample. WBCs are part of the immune system and help to protect the body against infections and other foreign substances. However, exposure to heavy metals may cause the immune system to respond by increasing the production of WBCs in an attempt to remove harmful substances from the body [28-30].

Also, mean levels of aspartate aminotransferase (AST), alanine aminotransferase (ALT) and alkaline phosphatase (ALP) significantly increased among animals treated with 800mg/kg of potash compared to control ( $P < 0.05$ ) (Table 5). Serum AST, ALT and ALP represent routine liver function tests (LFTs) used for the investigation of possible liver diseases or toxicity [31, 32]. AST is found in the liver as well as the kidney, the heart and the skeletal muscle [31, 33]. Elevated AST is associated with degenerative and necrotic liver diseases. Similarly, ALT is also found in the kidney and muscles but with a higher concentration in the liver. Increased ALT activity is associated with ischemic or toxin-related hepatocellular damage [34, 35]. These elevated liver enzymes could be due to the presence of cadmium in our potash sample. Cadmium is said to bind with red blood cells and albumin in the blood from where they are transported to the liver and bind with metallothionein (MT). The cadmium-MT complex is then released back into circulation where they accumulate in the blood stress and accumulates in the

liver, kidney, lung and testis, causing oxidative stress and necrotic damage [21, 36]. Other documented histo-pathological evidence suggests that potash caused liver damage [6, 8, 12, 37]

Furthermore, this study observed a significant increase in mean values for sodium, potassium, and chloride ions among the animals exposed to potash compared to the control group ( $p < 0.05$ ) (Table 5). Similarly, urea and creatinine levels were significantly increased compared to the control ( $p < 0.05$ ) (Table 5). The measurement of urea, creatinine and some electrolytes (sodium, potassium and chloride ions) represent simple markers of renal function. Creatinine is a breakdown product of creatine phosphate in muscle and they are used to assess the progression of renal disease. Also, elevated values can be an indication of anaemia (as observed in this study) and tubular necrosis [38]. Urea, a nitrogenous end product of the breakdown of amino acid is produced in the liver, distributed in the blood and filtered by the glomeruli [39], hence significantly elevated values are an indication of impaired kidney function [38]. Also, elevations in serum potassium, sodium and chloride could be due to the concentrations of these electrolytes in our sample of potash and are suggestions of impaired renal function. Other documented histo-pathological evidence suggests that potash caused renal damage [37, 40].

## CONCLUSION

From the data presented, the present study has shown that the chronic consumption of potash at 800mg/kg can negatively alter the haematological and hepatorenal profiles of Wistar rats. Therefore, this study considers potash, a possible toxicant to the blood, liver and kidney.

## Ethical Considerations

The study was carried out in line with guidelines for animal experimentation. The research design and protocol were approved by the institutional research ethics committee.

## References

1. Garrett DE. *Potash: deposits, processing, properties and uses*: Springer Science & Business Media; 2012.
2. Airaodion AI, Emaleku SA, Osunmuyiwa OJ, Megwas AU, Ayita EB, Oluba SO, et al. Nephrotoxic Nature of Potash (Kaun) in Wistar Rats. *International Journal of Health, Safety and Environment*. 2021;7(04):830-7.
3. Warren JK. Evaporites through time: Tectonic, climatic and eustatic controls in marine and nonmarine deposits. *Earth-Science Reviews*. 2010;98(3-4):217-68.
4. Khan IA. *Management of Agricultural Inputs*. Rajasthan: Agrotech Publishing Academy; 2014.

5. Momoh TB, Yaro CA, Usuman SO, Iyeh VA. Effect of potash on the tenderness and phytochemical constituents of *Cajanus Cajan*. *Trends Applied Sciences Research*. 2019;14(4):278-82.
6. Kutshik RJ, Idogun FO, Ujah FE, Gotom SS. Comparative investigations of the effects of Kanwa (Trona) and Tokansenyi (plant potash) on liver and kidney of albino rats. *International Journal of Biological and Chemical Sciences*. 2018;12(1):422-30.
7. Odiraa. Potash (Akanwu) Consumption and the effects on Human Health. 2020.
8. Oladele FC, Airaodion AI, Agunbiade AP, Adedeji AA, Megwas AU, Ayita EB, et al. Hepatotoxic Nature of Potash (Kaun) in Wistar Rats. *International Research Journal of Gastroenterology and Hepatology*. 2021;4(2):40-51.
9. Ibeme IU. Medicinal Uses of Kanwa (Akanwu) in Nigeria. *Healthy Living. Northeast Star Online Journal*; 2015.
10. Javed M, Usmani N. Impact of heavy metal toxicity on hematology and glycogen status of fish: a review. *Proceedings of the National Academy of Sciences, India Section B: Biological Sciences*. 2015;85(4):889-900.
11. Loi F, Pilo G, Franzoni G, Re R, Fusi F, Bertocchi L, et al. Welfare Assessment: Correspondence Analysis of Welfare Score and Hematological and Biochemical Profiles of Dairy Cows in Sardinia, Italy. *Animals*. 2021;11(3):854.
12. Iweka FK, Dic-Ijiewere OE, Oaikhena F, Bankole JK, Festus OO, Dada FL. The effect of potash on liver function of wistar rats. *International Journal of Basic, Applied and Innovative Research*. 2016;5(1):13-20.
13. Ogundare SO, Sirajuddin M, Iyevhobu KO, Ogundare EI. Histopathological Effects of Potash on the Hearts of Adult Wistar Rats. *Asian Journal of Cardiology Research*. 2020;6(3):23-30.
14. Ajayi AF, Akhigbe RE. Antispermogenic Mechanism of Trona is Associated with Lipid Peroxidation but Not Testosterone Suppression. *J Hum Reprod Sci*. 2017;10(2):124-7.
15. Chinedu E, Arome D, Ameh FS. A new method for determining acute toxicity in animal models. *Toxicology international*. 2013;20(3):224.
16. Lorke D. A new approach to practical acute toxicity testing. *Archives of toxicology*. 1983;54(4):275-87.
17. Chinko BC, Amah-Tariah FS, Ekenna IC. Evaluation of the effects of calabash chalk on the haematological profile of Wistar rats. *Notulae Scientia Biologicae*. 2022;14(3):11281-.
18. Evbu I, Precious O, Iriagbonse E. Haematological indices and blood lipid profile of rats administered Trona; a natural food additive. *The Egyptian Journal of Biochemistry and Molecular Biology*. 2016;34(1-2):15-22.
19. Olisa OG, Ajibade OM, Nafiu LO, Olajide-Kayode JO, Abdus-Salam MO. Mineralogy and health risk assessment of trona consumed in parts of Ibadan, southwestern Nigeria. *Arabian Journal of Geosciences*. 2022;15(15):1-13.
20. Uzoho CU, Onyekonwu M, Akaranta O. Characterization of Local Alkali, Surfactant and Polymer Used For Enhanced Oil Recovery. *International Journal of Engineering Research And Management (IJERM)*. 2019;6(5):41-6.
21. Ashour TH, El-Shemi AG. Caffeic acid phenyl ester prevents cadmium intoxication induced disturbances in erythrocyte indices and blood coagulability, hepatorenal dysfunction and oxidative stress in rats. *Acta Haematologica Polonica*. 2014;45(3):272-8.

22. Ovie K-S, Ikomi U. Alterations in some haematological parameters of the African Snakehead: *Parachanna africans* exposed to cadmium. *Notulae Scientia Biologicae*. 2011;3(4):29-34.
23. Von Garnier C, Stünitz H, Decker M, Battegay E, Zeller A. Pica and refractory iron deficiency anaemia: a case report. *Journal of medical case reports*. 2008;2(1):1-3.
24. Lanzkowsky P. *Manual of pediatric hematology and oncology*: Elsevier; 2005.
25. Kauffmann T, Evans DS. Macrocytosis. *StatPearls* [Internet]: StatPearls Publishing; 2021.
26. Lanzkowsky P. Classification and diagnosis of anemia in children. *Lanzkowsky's Manual of Pediatric Hematology and Oncology*: Elsevier; 2016:32-41.
27. Ani CO, Olasunkanmi MJ, Ene CB, Chime PU, Onwuka CO, Egharevba JE, et al. Assessment of the Effects of Fresh Palm Oil, Natron (Kanwa) and Natron-Treated Palm Oil on Some Hematological Parameters in Wistar Rats. *Journal of medical science and clinical research*. 2017;5(6):24113-20.
28. Mahurpawar M. Effects of heavy metals on human health. *Int J Res Granthaalayah*. 2015;530:1-7.
29. Witeska M. Stress in fish-hematological and immunological effects of heavy metals. *Electronic journal of ichthyology*. 2005;1(1):35-41.
30. Blumenreich MS. The white blood cell and differential count. *Clinical Methods: The History, Physical, and Laboratory Examinations*. 3rd edition. 1990.
31. Gowda S, Desai PB, Hull VV, Avinash AK, Vernekar SN, Kulkarni SS. A review on laboratory liver function tests. *The Pan african medical journal*. 2009;3.
32. Macpherson I, Abeysekera KWM, Harris R, Mansour D, McPherson S, Rowe I, et al. Identification of liver disease: why and how. *Frontline Gastroenterology*. 2022;3(5).
33. Hall P, Cash J. What is the real function of the liver 'function' tests? *The Ulster medical journal*. 2012;81(1):30.
34. Hoekstra LT, de Graaf W, Nibourg GAA, Heger M, Bennink RJ, Stieger B, et al. Physiological and biochemical basis of clinical liver function tests: a review. *Annals of surgery*. 2013;257(1):27-36.
35. Hann H-W, Wan S, Myers RE, Hann RS, Xing J, Chen B, et al. Comprehensive analysis of common serum liver enzymes as prospective predictors of hepatocellular carcinoma in HBV patients. *PloS one*. 2012;7(10):e47687.
36. US Department of Health Human Services. *Toxicological profile for cadmium. draft for public comment*; 1991.
37. Imam TS, Sani A, Hassan A. Heavy Metals in Blood and Histopathological Analysis Of Wistar Rats Exposed To Five Natron (Kanwa) Varieties Sold in Kurmi Market Kano, Northern Nigeria. *Fudma Journal of Science*. 2019;3(3):472-81.
38. Gowda S, Desai PB, Kulkarni SS, Hull VV, Math AA, Vernekar SN. Markers of renal function tests. *North American journal of medical sciences*. 2010;2(4):170.
39. Cholongitas E, Shusang V, Marelli L, Nair D, Thomas M, Patch D, et al. renal function assessment in cirrhosis—difficulties and alternative measurements. *Alimentary pharmacology & therapeutics*. 2007;26(7):969-78.
40. Bankole JK, Ngokere AA, Ajibade OM, Igunbor CM, Eloka CCV. Degenerating effects of potash (Kaun-K<sub>2</sub>CO<sub>3</sub>) on the kidney: Unabated continental challenge to human health in Nigeria. *Annals of Biology Research*. 2015;6(3):12-8.

UNDER PEER REVIEW