

Original Research Article
IMMUNOEXPRESSION OF MUTATED BRAF V600E PROTEIN
IN PAPILLARY THYROID CARCINOMA

Abstract

Background and Objectives: In papillary thyroid cancer (PTC), BRAF V600E is the most prevalent genetic alteration, and in different populations, its frequency ranges from 29% to 83%. BRAF mutation is mostly detected by DNA-based molecular methods, which are labor-intensive and time-consuming. A method, immunohistochemistry (IHC), was recently introduced to detect BRAF-mutated proteins. This method enables a monoclonal BRAF V600E mutation-specific antibody that can distinguish BRAF V600E from wild-type protein in conventionally processed, formalin-fixed, paraffin-embedded tissue and the mutant protein was directly visualized in tumour cells in a tissue context. This study aimed to determine the BRAF V600E-mutated protein's immunoexpression in papillary thyroid carcinoma.

Methodology: The study was a laboratory-based descriptive cross-sectional study. A total of 44 histologically proven paraffin-embedded tissue blocks of PTC were collected. Anti-BRAF V600E rabbit monoclonal primary antibody was used for immunohistochemistry on tissue sections, and the staining intensity was scored from 0 to 3 (+): 0, no cytoplasmic staining in tumour cells; 1: faint cytoplasmic staining in over 10% of tumour cells; 2+, moderate cytoplasmic staining in over 10% of tumour cells; 3+, strong cytoplasmic staining in over 10% of tumour cells.

Results: Among 44 cases, 34 (77.3%) were positive, and 10 (22.7%) were negative for the mutated BRAF V600E protein by IHC staining. In terms of staining intensity, 4 (9.1%), 20 (45.5%), and 10 (22.7%) cases had IHC scores of 1+, 2+, and 3+, respectively. This study reported a high-frequency rate (77.3%) of mutated BRAF protein, similar to the frequency reported in other Asian countries. There was no association between mutated BRAF V600E protein status and either age or gender.

Conclusion: The most effective PTC diagnostic marker is BRAF V600E mutation. The IHC technique using BRAF V600E mutation-specific antibodies is relatively simple and faster and is therefore proposed as the most reliable first-line method for detecting BRAF V600E-mutated proteins.

Keywords: Myanmar, Immunohistochemistry (IHC), BRAF V600E, Papillary thyroid carcinoma, Formalin-fixed paraffin-embedded tissue, Monoclonal antibody, Cytoplasmic staining

1. Introduction

Papillary thyroid carcinoma (PTC) contributes to 80–90% of all thyroid malignancies [1]. Despite the fact that PTC is generally a highly curable disease, 25–35% of cases still have a poor prognosis, and patients tend to be more susceptible to recurrence following surgery and metastasis. Therefore, prognosis prediction of papillary thyroid cancer and customising individualised treatment has become a topic of interest [2].

Mutations involving the mitogen-activated protein kinase (MAPK) pathway, such as RET/PTC, RAS, and B-type Raf kinase (BRAF), are frequently observed in PTC [3]. The BRAF mutation fundamentally influences the pathogenesis of PTC and is reported to be present in 25-82% of PTC cases [4].

The BRAF V600E mutation, the most reliable diagnostic marker of PTC, is typically linked to more aggressive clinical behaviour. The mutation of BRAF V600E in cancer is linked with a faster growth rate and metastasis, as well as an increased mortality risk [4]. The MAPK pathway is, therefore, a potential therapeutic target for PTC, and potent MEK inhibitors may be the first effective therapeutic agents for thyroid cancer, suggesting that the BRAF V600E mutation should be tested in every case of papillary thyroid cancer. Testing for this mutation can aid in selecting initial treatment and monitoring [3].

Several techniques are available in routine clinical practice for BRAF mutation detection. These include allele-specific real-time PCR, colorimetric mutant assay, high-resolution melting (HRM) analysis, deoxysequencing, and pyrosequencing. These techniques vary in terms of sensitivity, assay complexity, and cost [5]. Immunohistochemistry (IHC) technique was recently developed to detect mutated BRAF proteins using anti-BRAF V600E antibodies specific to this BRAF-mutant protein [6]. This study was conducted to determine mutated BRAF V600E protein immunoexpression in histologically diagnosed papillary thyroid carcinoma.

2. Materials & Methods

The histologically proven, paraffin-embedded tissue blocks of 44 papillary thyroid carcinoma patients who attended the Otorhinolaryngology, Head and Neck Surgery Specialist Hospital, Yangon, were collected. Immunohistochemistry by using the peroxidase-anti-peroxidase method was performed with a commercially available recombinant rabbit monoclonal BRAF V600E mutation-specific primary antibody (RM8) (Catalog No. MA5-24661, Invitrogen, Thermo Fisher Scientific, Massachusetts, USA).

2.1 Microtomy and mounting on the slides

The obtained paraffin blocks were sliced to a 3 μm thickness using a rotary microtome (SLEE, Germany). One tissue section was mounted on an ordinary clean slide, stained with hematoxylin and eosin, examined under a light microscope, and identified as papillary thyroid carcinoma by the guidance of the supervisor. Another section for immunohistochemical staining was transferred to a salinised slide, incubated at 37 °C overnight, and dried at 55 °C on a slide-warmer for 2 hours. The samples were deparaffinized, rehydrated, and washed in water, followed by an immunohistochemistry process.

2.2 Deparaffinization and rehydration

The paraffin needs to be removed entirely to avoid some background staining. The tissue sections were deparaffinized in xylene I, II, and III for 5 minutes each. The tissue sections were rehydrated for three minutes in 100% ethanol, 90% ethanol, and 70% ethanol. Then, the tissue sections were washed three times for five minutes with phosphate-buffered saline.

2.3 Antigen retrieval

Antigen retrieval is done by immersing the slides in pre-warmed citrate buffer in the microwave at a high temperature (not more than 98°C) three times for five minutes, cooling to room temperature for 30 minutes, and then washing with phosphate-buffered saline (PBS).

2.4 Blocking endogenous peroxidase activity

Endogenous peroxidase was blocked at room temperature for 30 minutes with 3% H_2O_2 and then rinsed three times for 5 minutes with phosphate-buffered saline (PBS).

2.5 Procedure for immunostaining

The tissue sections were covered with the primary antibody using prediluted antibodies, and incubated overnight at 4°C in a wet chamber. After cooling to room temperature for 30 minutes, the slides were washed for 5 minutes in PBS buffer three times. The tissue sections were then incubated for 30 minutes at room temperature with a secondary antibody (N-histofine, Simple Stain™ MAX PO-MULTI, Nichirei Biosciences Inc., Japan) and washed with 3 changes of PBS for 5 minutes each.

Tissue sections were immersed for 5–10 minutes in freshly prepared DAB (diaminobenzidine) solutions. The slides were rinsed with water before being counterstained with hematoxylin for thirty seconds. The sections were dehydrated, cleared, and mounted with distyrene (DPX) and a coverslip. In every immunohistochemical staining batch, both positive and negative controls were performed. BRAF V600E mutation-positive melanoma tissue was used as a positive control in every batch, as was the omission of the application of primary antibodies to the tissue section for the negative control.

2.6 Reporting of the Slides

On the basis of the intensity of brown cytoplasmic staining in tumour cells, IHC results are rated as follows, on a scale from 0 to 3 (+): 0, the absence of cytoplasmic staining in tumour cells; 1+ indicates faint cytoplasmic staining in more than 10% of tumour cells; 2+ indicates moderate cytoplasmic staining in more than 10% of tumour cells; 3+ indicates strong cytoplasmic staining in more than 10% of tumour cells [7]. The tumour cell was considered positive for mutated BRAF V600E expression if the score was 1+ or higher and negative if it was 0 [8]. Immunostained slides were examined using a light microscope under the supervisor's guidance. The results were also interpreted, and photomicrographs were taken with a CETI microscope (Medline Scientific Limited, UK). This study was permitted by the University of Medical Technology, Yangon, Institutional Review Board.

2.7 Data analysis

Statistical analysis was conducted using version 20 of the SPSS software (SPSS, Inc., Chicago, IL, USA). The data were described with descriptive statistics, including frequencies, percentages, and crosstabs. Fisher's exact test was used to assess the differences between categorical variables, and the P value of less than 0.05 was considered statistically significant.

3. Results

This study was designed to investigate the immunoexpression of mutated BRAF V600E protein in papillary thyroid carcinoma using the peroxidase anti-peroxidase method. A total of 44 paraffin blocks of papillary thyroid carcinoma were histologically confirmed with haematoxylin, and eosin staining, and then immunohistochemical staining for mutated BRAF V600E protein was performed. The slides were examined, and mutated BRAF V600E protein was recorded by the investigator under the guidance of the supervisor.

3.1 Age distribution of patients with papillary thyroid carcinoma

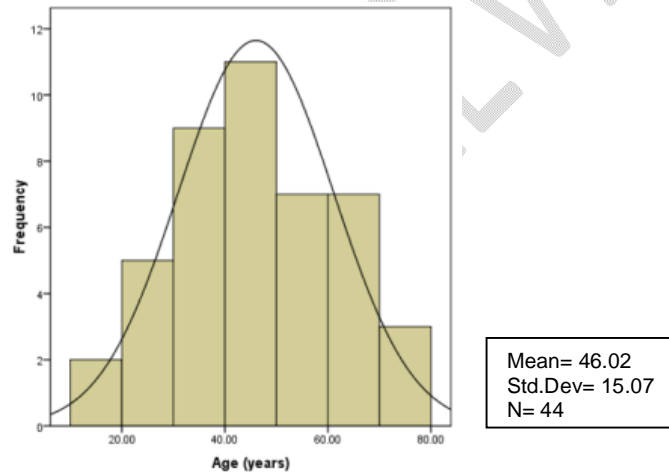


Fig. 1. Age distribution of patients with papillary thyroid carcinoma

Fig. 1 indicates the age distribution of papillary thyroid cancer patients. A mean age of 46.02 years and a median age of 45 were found in the study population, ranging from 17 to 75. Nearly half of the patients were between the ages of 41 and 60, while 22.7% were over 60. The remaining 36.4% were aged 40 years and below.

3.2 Gender distribution of papillary thyroid carcinoma patients

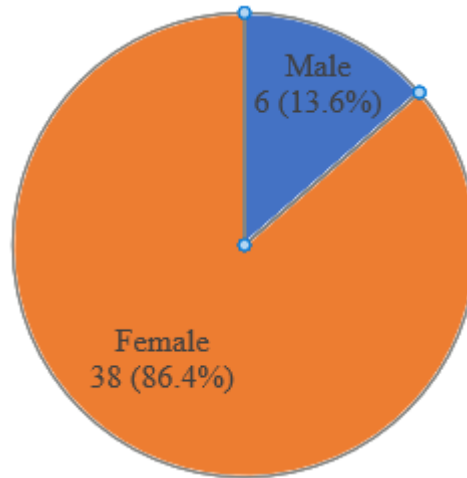


Fig. 2. Gender distribution of papillary thyroid carcinoma patients

Fig. 2 presents the gender distribution of patients with papillary thyroid carcinoma; most patients were female, representing 38 (86.4%) of the study population. Out of 44 patients, only 6 (13.6%) were male.

3.3 . BRAF V600E protein immunoexpression score in papillary thyroid carcinoma

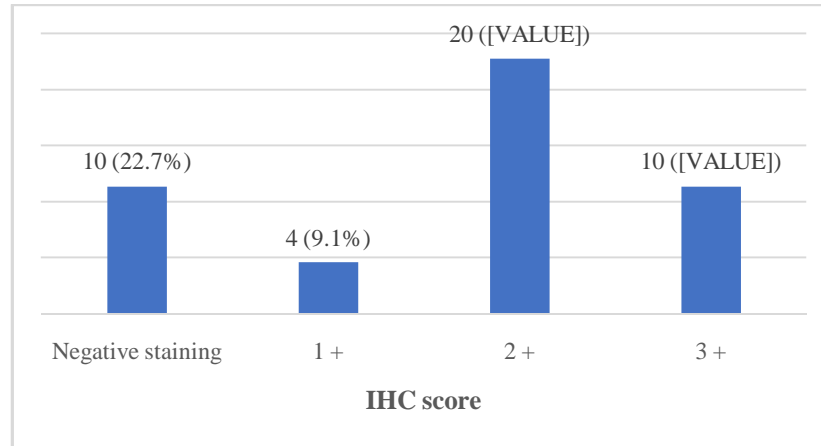


Fig. 3. BRAF V600E protein immunoexpression score in papillary thyroid carcinoma

Fig. 3 shows mutated BRAF V600E protein immunoexpression in papillary thyroid carcinoma, in which, on a scale from 0 to 3, the staining intensity of BRAF V600E in tumour cells was quantified. Mutated BRAF V600E protein positive IHC staining was 3+ in 10 (22.7%), 2+ in 20 (45.5%), 1+ in 4 (9.1%), and negative in 10 (22.7%) cases, respectively. Based on an examination of BRAF status on PTC samples, BRAFV600 mutated protein positivity was found in 34 (77.3%) of the patients studied.

3.4 Age group and BRAF V600E immunohistochemical score

Table 1. Age group and BRAF V600E immunohistochemical score

Age Group	BRAF V600E IHC Score					Fisher's exact test p value
	Negative	1 +	2 +	3 +	Total	
≤ 40	5 (31.2%)	2 (12.5%)	6 (37.5%)	3 (18.8%)	16(100%)	0.46
41- 60	3 (16.7%)	1 (5.6%)	9 (50%)	5 (27.8%)	18 (100%)	
> 60	2 (20%)	1 (10%)	5 (50%)	2(20%)	10 (100%)	
Total	10 (22.7%)	4 (9.1%)	20 (45.5%)	10 (22.7%)	44 (100%)	

As shown in [Table 1], BRAF IHC scores of 0 and 1+ were more common in ≤ 40 age groups, while scores of 2 and 3 were more common in those aged over 40. However, the correlation between age group and BRAF IHC score in papillary thyroid carcinoma was not statistically significant ($P = 0.46$).

3.5 Comparison of ages according to the BRAF V600E IHC score

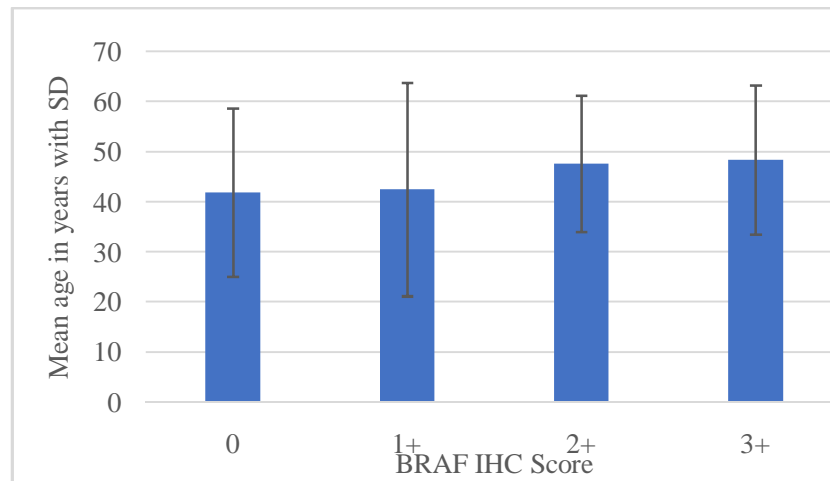


Fig. 4. Comparison of ages according to the BRAF V600E IHC score

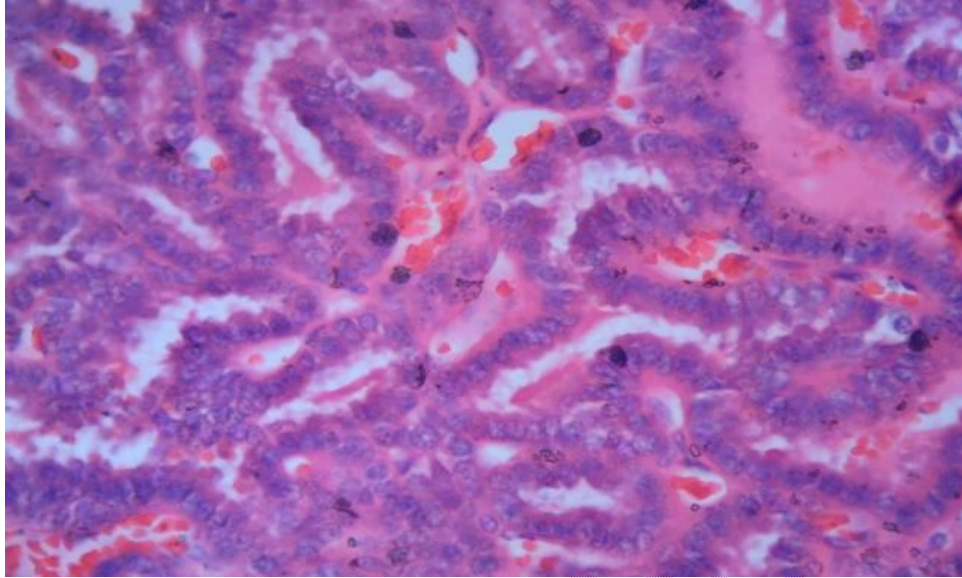
The comparison of ages according to the mutated BRAF V600E protein IHC score is shown in Fig. 4, and the mean age of patients increases as the mutated BRAF V600E protein IHC score increases. Among the scores of 0, the mean age was 41.9 years, which increased to 42.5 years, 47.6 years, and 48.4 years when the score was raised to 1+, 2+, and 3+, respectively.

3.6 Gender and BRAF V600E immunohistochemical score

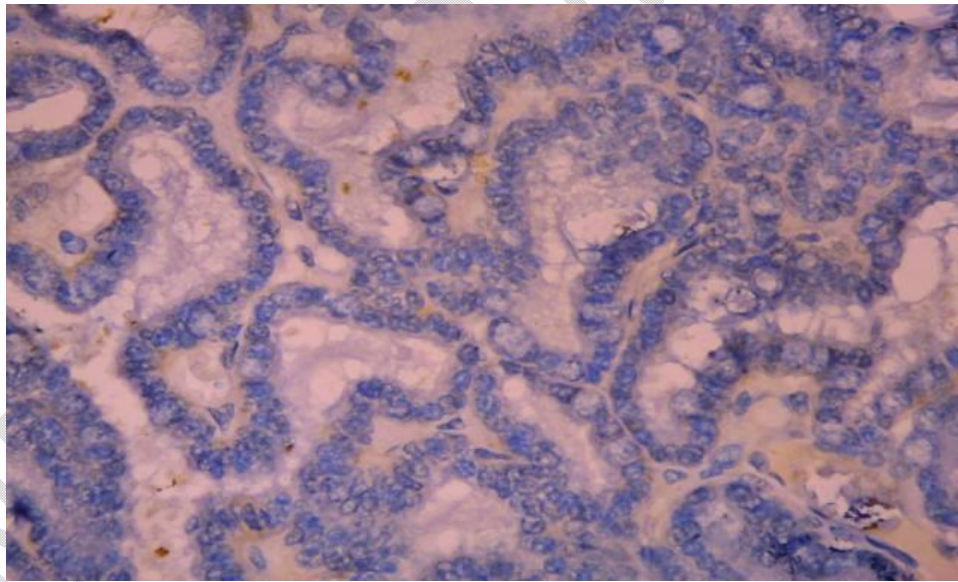
Table 2. Gender and BRAF V600E immunohistochemical score

Gender	BRAF IHC Score					Fisher's exact test p value
	Negative	1 +	2 +	3 +	Total	
Male	2 (33.3%)	0 (0.0%)	4 (66.7%)	0 (0.0%)	6 (100%)	0.43
Female	8 (21.1%)	4 (10.5%)	16 (42.1%)	10 (26.3%)	38 (100%)	
Total	10 (22.7%)	4 (9.1%)	20 (45.5%)	10 (22.7%)	44 (100%)	

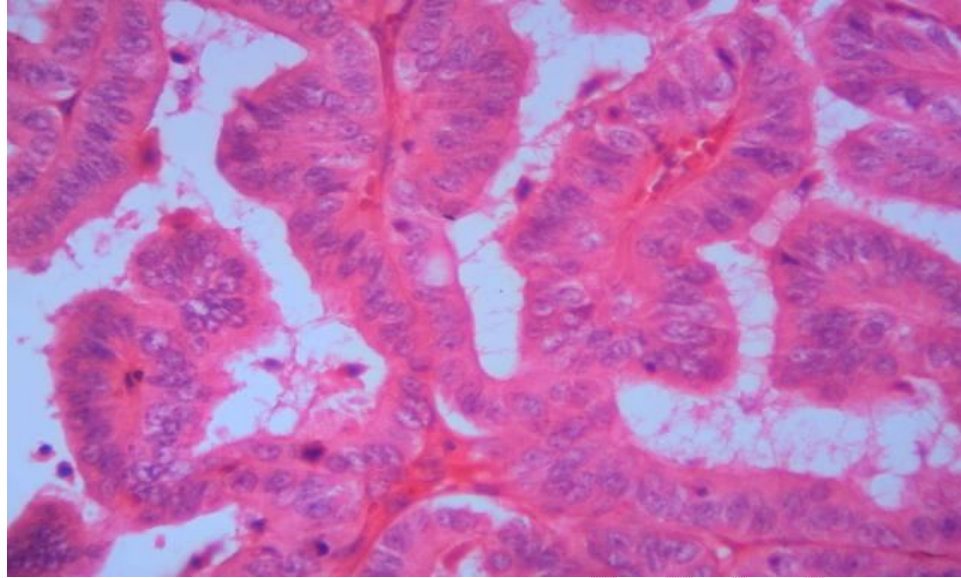
As shown in [Table 2], among the six male patients, 2 (33.3 %) were negative, and 4 (66.7%) were an IHC score of 2+. Among the 38 female patients, 8 (21.1%) were negative, 4 (10.5 %) were 1+, 16 (42.1 %) were 2+, and 10 (26.3%) were an IHC score of 3+. There was no considerable difference between male and female BRAF IHC scores ($P = 0.43$).



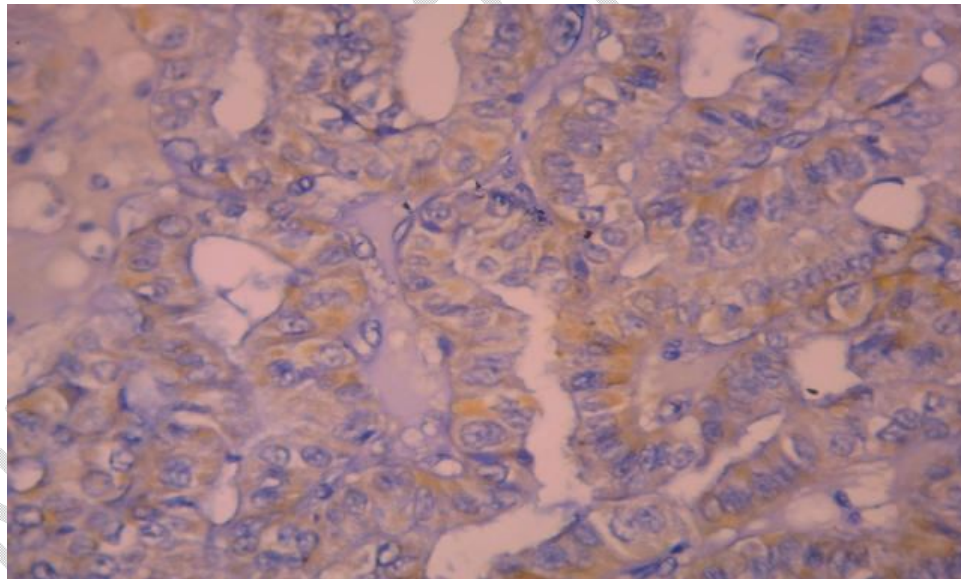
**Fig. 5. Papillary Thyroid Carcinoma (H&E x 400)
(Case No. 21)**



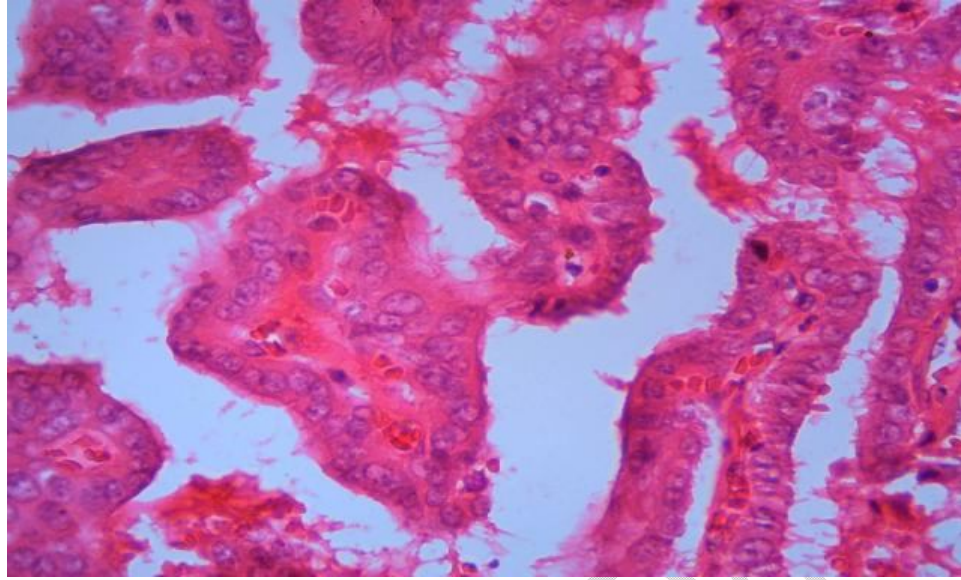
**Fig. 6. BRAF V600E Score 0 (Negative expression)
in papillary thyroid carcinoma, (IHC x 400) (Case No. 21)**



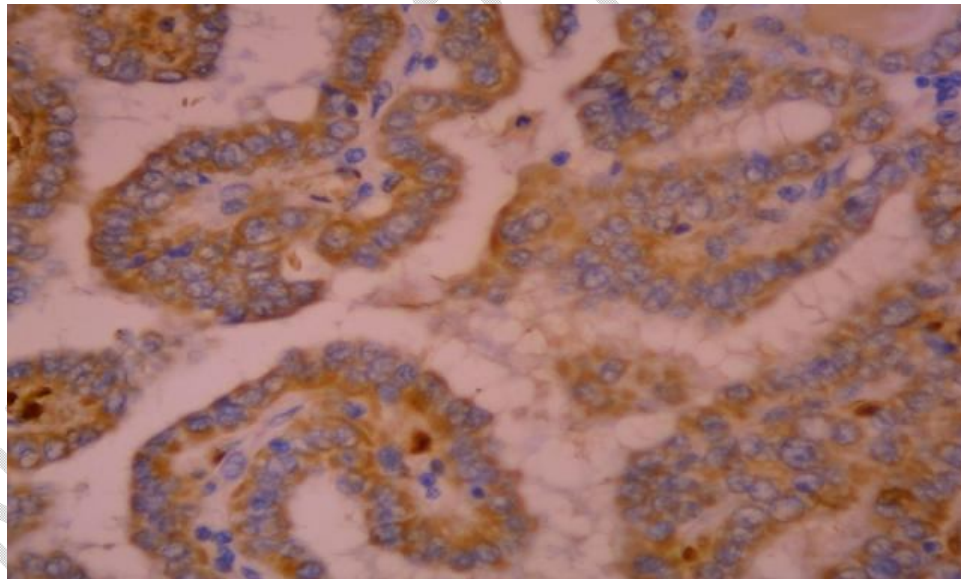
**Fig. 7. Papillary Thyroid Carcinoma (H&E x 400)
(Case No. 14)**



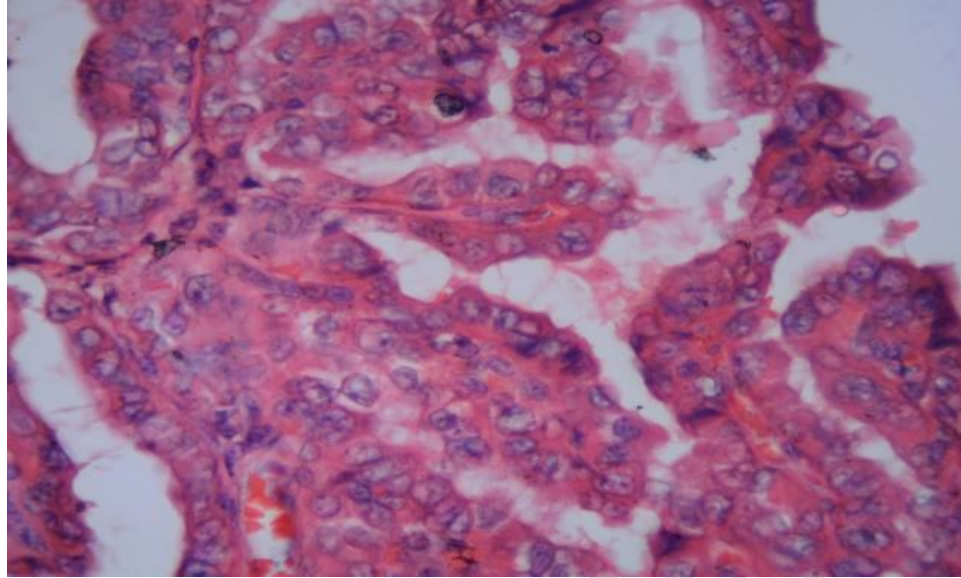
**Fig. 8. BRAF V600E Score 1+ (Weak positive expression)
in papillary thyroid carcinoma, (IHC x 400) (Case No. 14)**



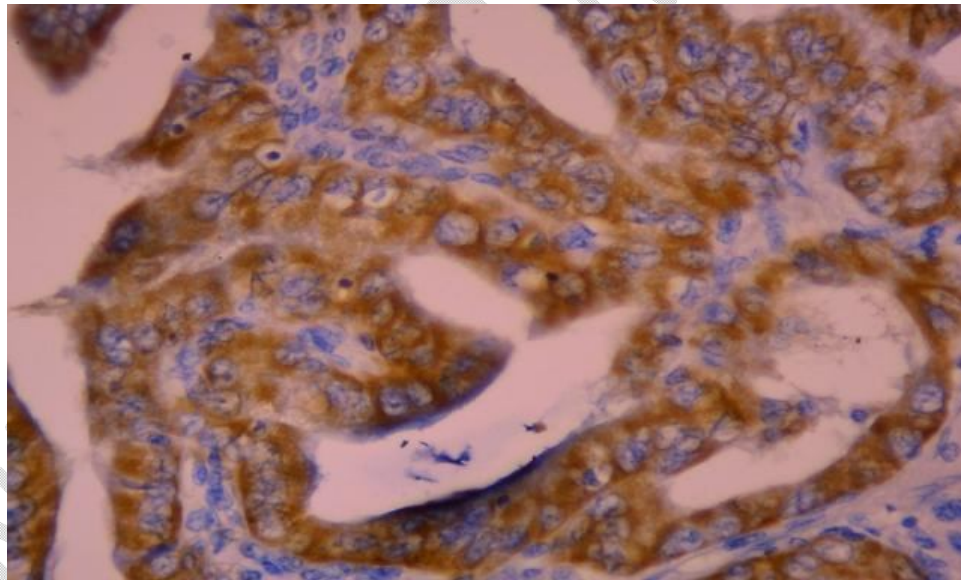
**Fig. 9. Papillary Thyroid Carcinoma (H&E x 400)
(Case No. 19)**



**Fig. 10. BRAF V600E Score 2+ (Moderately positive expression)
in papillary thyroid carcinoma (IHC x 400) (Case No. 19)**



**Fig. 11. Papillary Thyroid Carcinoma (H&E x 400)
(Case No. 31)**



**Fig. 12. BRAF V600E Score 3+ (Strong positive expression)
in papillary thyroid carcinoma (IHC x 400) (Case No. 31)**

4. Discussion

The majority of diagnostic tests were developed to detect only the BRAF V600E mutation, which accounts for approximately 95% of all BRAF mutations. Among these tests, monoclonal antibodies against the BRAF V600E-mutated protein have been developed and used in immunohistochemistry to detect the presence of the mutant protein [9]. In addition to being a well-established diagnostic and prognostic marker for PTC and other subtypes of thyroid carcinoma, mutations in BRAF V600E provide a valuable target for specific inhibitors of BRAF V600E [10, 11]. This study reported the institutional experience of detecting mutated BRAF V600E protein on PTC specimens using immunohistochemistry. It confirmed the usefulness of the IHC method for detecting mutated BRAF V600E protein.

All PTC cases were initially evaluated on hematoxylin-eosin stained slides to ensure the presence of the tumour. The presence of complete nuclear changes such as overlap, clear nuclei, oval nuclei, irregular nuclear membrane, intranuclear clefts, and intranuclear pseudo inclusion was reviewed. Furthermore, the presence or absence of round eosinophilic cytoplasm-containing cells (“plump pink cells”), psammoma bodies that have invaded tumour borders, and stromal reactions were also evaluated under the guidance of the supervisor [12].

4.1 Age Distribution in papillary thyroid carcinoma

PTC is distinct from other cancers in that the patient's age is included in the staging criteria [13]. PTC can occur at any age but is typically diagnosed between the third and fifth decades of a patient's life, with a mean age of [14]. Therefore, the age threshold for papillary thyroid cancer may be variable between 40 and 55 years of age [15].

In this study, regarding the age distribution of papillary thyroid cancer, the mean age of 44 cases was 46 ± 15.07 years, and most prevalent age range was 41 to 60 years old, accounting for 28 patients (40.9%). In the studies of Cho et al., (2012) [16], Szymonek et al., (2017) [17], and Girardi (2017) [18], papillary thyroid carcinoma was most commonly seen in those aged 35 to 55, with mean ages of 47, 52, and 48 years, respectively. The finding of the present study was nearly consistent with those studies showing that the risk of papillary thyroid carcinoma increases with increasing age.

4.2 Gender distribution in papillary thyroid carcinoma

Regarding gender distribution, it is known that, due to hormonal effects, thyroid cancer is only cancer that occurs predominantly in women [10]. In this study, 38 cases (86.4% of all cases) were female, while only six patients (13.6%) were male, for a ratio of female-to-male 6.3 :1, supporting the fact that papillary thyroid cancer is more prevalent in females. This finding was very similar to the reports of Kaliszewski et al., 2020 [13], LeClair et al., 2021 [19], and Jonklaas et al., 2012 [20], female to male ratio in PTC were 6.8:1, 4.28:1, and 2.7:1 respectively. Estrogen could be a risk factor for thyroid cancer as it probably has a growth-promoting effect in benign and malignant thyroid tumours and may play a role in its progression [21]. It could be one of the reasons for female predominance in PTC.

4.3 Immunohistochemical detection of mutated BRAF V600E protein

To perform immunohistochemical screening for BRAF-mutant tumours, a BRAF V600E mutant-specific antibody has been developed. According to initial studies, this antibody detects mutant BRAF V600E in various cancer types, such as papillary thyroid cancer [22]. In the present study, the BRAF V600E mutated protein IHC was conducted on 44 cases of papillary thyroid carcinoma by immunohistochemical staining with positive and negative controls.

Immunohistochemistry is significantly impacted by pre-analytical factors, such as poor tissue handling and delayed fixation. Improper tissue preparation, such as the fixation (type, length of time, temperature and pH of the fixative), dehydration, clearing, wax impregnation, and embedding processes, can render IHC inconsistent, complex, or impossible to perform, as well as a result in the loss of antigens and alterations antigen expression level that affect immunoreactivity. To overcome these conditions, the temperature and quality of reagents used in tissue processing were constantly monitored, and H&E stained slides were examined under the supervision of the supervisor prior to IHC staining. The optimal conditions for staining BRAF V600E have been established through previous studies, including fixatives, fixation times, and the pH of solutions used to retrieve the stain [23].

The type and pH of the antigen retrieval buffer solution and the antigen retrieval method can affect the final IHC results. Some antigens are retrievable in a low-pH solution, while others are retrievable in a high-pH solution [24, 25]. Currently, heat treatment in citrate buffer (10 mM sodium citrate, pH 6.0) is the most common method for the retrieval of antigens

[26]. This study used citrate buffer pH 6.0 with microwave oven heat-induced epitope retrieval (HIER) method for antigen retrieval, and phosphate buffer saline pH 7.2-7.6 was used as washing buffer. The constituents of stock buffer solutions were balanced with standardized electrical balance and dissolved in distilled water. The stock buffer solutions were kept in the refrigerator (2-8°C), and working buffer solutions were freshly prepared before use. The pH of the buffer solution was measured by a standardized pH meter to produce satisfactory immunostaining in PTC samples [25].

Heating temperature and time are also essential factors in the HIER process. Antigens require either a higher temperature for a shorter period of time or a lower temperature for a longer period of time to achieve the same retrieval effect [25, 27]. In this study, to maintain the consistency of heating between runs, the same number of tissue sections were placed in the Coplin jar, filled with a suitable amount of antigen retrieval solution. The jar was also covered with aluminium foil to prevent evaporation during the HIER method. At some point, heat-induced antigen retrieval caused cancer cells to have nonspecific or false-negative nuclear staining. Increasing the retrieval time may enhance the BRAF V600E IHC positive signal but substantially increase the likelihood of nuclear nonspecific staining [23]. So, the sections were left in the microwave oven at high temperature, and an antigen retrieval time of 5 minutes three times worked best in this study. After antigen retrieval, the Coplin jar was placed in tap water for 15 minutes to prevent immediate temperature change and achieve a perfect staining result.

As an analytical variable, the primary antibody incubation is a fundamental step in any immunostaining and starting with a high-quality antibody is very important. It is also essential to determine the optimal titers of the primary antibody before putting them into diagnostic procedures to avoid unsatisfactory results. In this study, a series of titers (1:50, 1:100, and 1:200) was prepared to determine optimal titers with the first titer of 1:50 suggested by the manufacturer and further 2-fold dilutions and studied on several different known positive cases as well as many known negative cases.

Critical criteria for evaluating staining results include differential staining between cells and proper staining localization. Common causes of false positive stains are edge and trapping artefacts, bubble artefacts, chromogen freckles, hemosiderin or melanin pigmentation, drying artefacts, and inadequate fixation artefacts [26,28]. Both positive and

negative control slides were run simultaneously in each experiment to ensure the consistency of performance and reproducibility of results.

Mutated BRAF V600E protein immunoexpression was evident as brown cytoplasmic staining. In the past few decades, numerous scoring systems have been developed [29]. For evaluating the BRAF V600E status of PTC samples, a 4-tiered scoring system is more appropriate, and most studies assessed staining intensity using a 4-tiered system (0, 1+, 2+, 3+) [23]. In this study, grading IHC staining was based on both staining intensity and percentage of positively stained cells same as Zhao et al., 2019 [7], in which a score of 1+ (> 10% of tumour cells showing weak cytoplasmic brownish staining), 2+ (> 10% of tumour cells displaying moderate cytoplasmic distinct brownish staining), and 3+ (> 10% of tumour cells presenting strong cytoplasmic brownish staining) were regarded as positive staining for BRAF V600E, whereas score 0 (no staining in tumour cells) was considered as negative IHC staining

4.4 Distribution of mutated BRAF V600E protein in papillary thyroid carcinoma

In the present study, regarding BRAF V600E IHC, positive staining was detected 3+ in 10 (22.7%), 2+ in 20 (45.5%), 1+ in 4 (9.1%), and negative in 10 (22.7%) cases, respectively. Nearly half of the cases showed moderate staining, and a significant number (30 of 44) of BRAF mutated protein presented strongly to moderate IHC staining. Immunostaining-positive (score 3) tumours displayed diffuse and strong staining throughout the entire tumour area. Non-homogeneous staining was mainly found in the 1+ stained tissue section, and the scoring system determined the positivity. Distribution of tumour cells that had mutations in the positive cases also varied. The strongly positive stained cells range from 50-100% of tumour cells. This result is consistent with research conducted by De Biase et al. [30], and heterogeneous staining was not caused by improper tissue fixation or preservation [31].

Clinicopathological characteristics (age, histological type) and the study population have a significant impact on the incidence of the BRAF V600E mutation in papillary carcinoma. According to studies, 45–50% cases of PTC in the Western series, originating from the United States and Europe, have a BRAF V600E mutation. However, prevalence is more variable in the Asian population, with reported percentages ranging from 31% to 87% [32].

In the current study, the overall mutated BRAFV600 protein positivity was identified in 34 cases (77.3%) of PTC patients. This study reported a high-frequency rate of

mutated BRAF protein compared to the previous studies done by immunohistochemistry on the FFPE PTC tissue; Pakistan, Thai, Indonesian, and Indian populations reported that the prevalence of mutated BRAF protein in PTC as 29%, 61%, 34%, and 44% respectively [10,11,31,33]. Possibly, the differences in BRAF V600E frequencies may be due to selection bias in samples, but more importantly, to ethnic heterogeneity [10]. Furthermore, exact cancerous tissues were detected and scraped from the slice, significantly reducing false-negative results from the pericarcinous portion [34].

The present study's findings were comparable to those of other Asian investigations; Choden et al., (2020) and Jung et al., (2014) reported a prevalence rate of 86% and 84.2%, respectively, in Korea [32,35]. China-based studies by Zhang et al., 2018 [23], Zhao et al., 2019 [7], and Zhang et al., 2021 [36] also reported a high prevalence rate of 84%, 76.8%, and 96.8%, respectively.

4.5 Association of BRAF V600E immunoexpression with age

The prognosis of patients diagnosed with PTC is highly influenced by their age. Historically, a risk stratification cutoff age of 45 has been used. However, this threshold only makes sense if all patients over 45 have the same probability of death and recurrence, regardless of how close they are to the cutoff. Recent data suggest that the survival rate of patients over 45 declines with age. Consequently, a new age limit of 60 years has been considered [37].

Patients over 60 have lower disease-specific survival and disease-free survival following a diagnosis of PTC, regardless of disease stage. These findings support the addition of three age categories, 18-44 years, 45-59 years, and 60 years, as survival and recurrence predictor irrespective of the existing staging recommendations because survival declines with age in patients older than 45 years [37].

In this study, out of 44 patients, a BRAF IHC score of 1+ was common in the age group of ≤ 40 , and scores of 2+ and 3+ were more common in those over 40 years. The mean age of patients was also increased according to the increase in BRAF IHC score. Among the total positive rate of BRAF V600E-mutated protein, 25% (11/44) were detected in the ≤ 40 age group, whereas 52.3% (23/44) were found in those older than 40, indicating that BRAF V600E-mutated protein positivity increases with age; however, it was not statistically significant ($P = 0.46$).

Similarly, a meta-analysis by Carol Li in 2012 [38] showed nine studies, including 2015 patients, indicating a higher prevalence of BRAF V600E in elderly patients. Several studies by Koperek et al., 2012 [39], Sun et al., 2015 [40], Szymonek et al., 2017 [17] and Choden et al., 2020 [32] have observed that patient age and BRAF mutations are related. Nevertheless, a significant association between age and the BRAF V600E rate was not observed in the present study, which was similar to the studies by many other authors, Zagzag et al., 2013 [41], Zhang et al., 2016 [34], Barreno et al., 2022 [42], Rashid et al., 2021 [10] and Kristiani et al., 2021 [31].

4.6 Association of BRAF V600E immunoexpression with Gender

In this study, 38 cases (86.4%) were female, and 6 patients (13.6%) were male. Out of 6 male patients, 4 (66.7 %) were BRAF V600E positive with the IHC score of 2+, while among the 38 female patients, 30 (68.2 %) were BRAF positive, BRAF score of 4 (10.5 %) were 1+, 16 (42.1 %) were 2+ and 10 (26.3%) were IHC score of 3+, respectively. There was no significant difference in BRAF IHC score as well as BRAFV600 positivity between males and females ($P=0.43$). Some studies, McKelvie, 2013 [43] and Kristiani et al., 2021[31], stated BRAF V600E mutation is linked with the male gender. However, in this study, gender was not associated with BRAF status. This finding was in concordance with many other studies, Zagzag et al., 2013 [41]; Zhang et al., 2016 [34]; Barreno et al., 2022 [42]; Rashid et al., 2021 [10]; and Choden et al., 2020 [11].

The strength of this study was the use of IHC to establish the presence or absence of BRAF V600E mutations. A false positive result could be substantially reduced or avoided by employing a negative control. In addition, IHC yields faster results than other molecular tests, hence, decreasing turnaround time in diagnostic laboratories. Therefore, in time, targeted therapy can be given to an aggressive BRAF V600E mutated thyroid cancer. Furthermore, the BRAF IHC technique can be introduced in small centers without sophisticated equipment. This IHC procedure also requires fewer human resources because it can be carried out in the same department using the same sample as the traditional histology procedure.

Nevertheless, the present study has several limitations. Firstly, the study did not include PTC variants other than the conventional type; however, many past studies have shown

that BRAF immunostaining and subtypes of PTC have a strong link [44]. Secondly, due to limited resources, BRAF status in the present study could not be confirmed by molecular genetic studies. Finally, this study is a single-center, small-patient study; therefore, a substantial sample size should be used to validate the clinical effectiveness of IHC in detecting BRAF V600E.

5. Conclusion

In conclusion, the current study showed the feasibility of IHC performed on paraffin sections in identifying the mutated BRAF V600E protein in papillary thyroid carcinoma. The process of IHC using BRAF V600E mutation-specific antibodies is relatively simple, rapid, and helpful in screening for BRAF V600E mutant papillary thyroid carcinoma. In addition, it should be validated by molecular genetic studies prior to implementation.

Ethical Approval

This study was approved by the University of Medical Technology, Yangon, Institutional Review Board (Ethics Review Committee) (IRB Approval No. IRB/UMTY/2-2022/002).

References

1. Al-Salam S, Sharma C, Afandi B, Al Dahmani K, Al-Zahrani AS, Al Shamsi A, et al. BRAF and KRAS mutations in papillary thyroid carcinoma in the United Arab Emirates. *PLoS One*. 2020;15(4):e0231341.
2. Ge J, Wang J, Wang H, Jiang X, Liao Q, Gong Q, et al. The BRAF V600E mutation is a predictor of the effect of radioiodine therapy in papillary thyroid cancer. *J Cancer*. 2020;11(4):932-9.
3. Xing M. BRAF mutation in papillary thyroid cancer: pathogenic role, molecular bases, and clinical implications. *Endocr Rev*. 2007;28(7):742-62.
4. Liu C, Chen T, Liu Z. Associations between BRAF(V600E) and prognostic factors and poor outcomes in papillary thyroid carcinoma: a meta-analysis. *World J Surg Oncol*. 2016;14(1):241.

5. Huang T, Zhuge J, Zhang WW. Sensitive detection of BRAF V600E mutation by Amplification Refractory Mutation System (ARMS)-PCR. *Biomark Res.* 2013;1(1):3.
6. Lasota J, Kowalik A, Wasag B, Wang Z-F, Felisiak-Golabek A, Coates T, et al. Detection of the BRAF V600E mutation in colon carcinoma: critical evaluation of the immunohistochemical approach. *The American journal of surgical pathology.* 2014;38(9):1235-41.
7. Zhao J, Liu P, Yu Y, Zhi J, Zheng X, Yu J, et al. Comparison of diagnostic methods for the detection of a BRAF mutation in papillary thyroid cancer. *Oncol Lett.* 2019;17(5):4661-6.
8. Zhu X, Luo Y, Bai Q, Lu Y, Lu Y, Wu L, et al. Specific immunohistochemical detection of the BRAF V600E mutation in primary and metastatic papillary thyroid carcinoma. *Exp Mol Pathol.* 2016;100(1):236-41.
9. Martinuzzi C, Pastorino L, Andreotti V, Garuti A, Minuto M, Fiocca R, et al. A combination of immunohistochemistry and molecular approaches improves highly sensitive detection of BRAF mutations in papillary thyroid cancer. *Endocrine.* 2016;53(3):672-80.
10. Rashid FA, Tabassum S, Khan MS, Ansari HR, Asif M, Sheikh AK, et al. VE1 immunohistochemistry is an adjunct tool for detection of BRAF(V600E) mutation: Validation in thyroid cancer patients. *J Clin Lab Anal.* 2021;35(2):e23628.
11. Choden S, Keelawat S, Jung CK, Bychkov A. An affordable immunohistochemical approach to estimate the prevalence of BRAF(V600E) in large cohort studies-establishing the baseline rate of BRAF mutation in an institutional series of papillary thyroid carcinoma from Thailand. *Gland Surg.* 2020;9(5):1867-77.
12. Escobar J, Guzmán GE, Urbano MA, Ballen LJ, Martínez V, Arrunategui A. Histological and Immunohistochemical BraF V600e Mutation Detection in Papillary Thyroid Carcinoma. *Research Square.* 2022;10(5):1-13
13. Kaliszewski K, Diakowska D, Nowak L, Wojtczak B, Rudnicki J. The age threshold of the 8th edition AJCC classification is useful for indicating patients with aggressive papillary thyroid cancer in clinical practice. *BMC Cancer.* 2020;20(1):1166.

14. Abdullah MI, Junit SM, Ng KL, Jayapalan JJ, Karikalan B, Hashim OH. Papillary Thyroid Cancer: Genetic Alterations and Molecular Biomarker Investigations. *Int J Med Sci.* 2019;16(3):450-60.
15. Drake T. What Is the Ideal Age Cutoff for Papillary and Follicular Thyroid Cancer Staging, and Should the Cutoffs Be Different? *Clinical Thyroidology.* 2021;33(4):177-9.
16. Cho JS, Yoon JH, Park MH, Shin SH, Jegal YJ, Lee JS, et al. Age and prognosis of papillary thyroid carcinoma: retrospective stratification into three groups. *Journal of the Korean Surgical Society.* 2012;83(5):259-66.
17. Szymonek M, Kowalik A, Kopczyński J, Gąsior-Perczak D, Pałyga I, Walczyk A, et al. Immunohistochemistry cannot replace DNA analysis for evaluation of BRAF V600E mutations in papillary thyroid carcinoma. *Oncotarget.* 2017;8(43):74897.
18. Girardi FM. Thyroid Carcinoma Pattern Presentation According to Age. *Int Arch Otorhinolaryngol.* 2017;21(1):38-41.
19. LeClair K, Bell KJL, Furuya-Kanamori L, Doi SA, Francis DO, Davies L. Evaluation of Gender Inequity in Thyroid Cancer Diagnosis: Differences by Sex in US Thyroid Cancer Incidence Compared With a Meta-analysis of Subclinical Thyroid Cancer Rates at Autopsy. *JAMA Intern Med.* 2021;181(10):1351-8.
20. Jonklaas J, Noguera-Gonzalez G, Munsell M, Litofsky D, Ain KB, Bigos ST, et al. The impact of age and gender on papillary thyroid cancer survival. *J Clin Endocrinol Metab.* 2012;97(6):E878-87.
21. Rahbari R, Zhang L, Kebebew E. Thyroid cancer gender disparity. *Future Oncol.* 2010;6(11):1771-9.
22. Qiu T, Lu H, Guo L, Huang W, Ling Y, Shan L, et al. Detection of BRAF mutation in Chinese tumor patients using a highly sensitive antibody immunohistochemistry assay. *Sci Rep.* 2015;5:9211.
23. Zhang X, Wang L, Wang J, Zhao H, Wu J, Liu S, et al. Immunohistochemistry is a feasible method to screen BRAF V600E mutation in colorectal and papillary thyroid carcinoma. *Exp Mol Pathol.* 2018;105(1):153-9.
24. Shi S-R, Gu J, Turrens J, Cote RJ, Taylor CR. Development of the antigen retrieval technique: philosophical and theoretical bases. *Antigen Retrieval Techniques: Immunohistochemistry and Molecular Morphology.* 2000:17-40.

25. Anitha N, Malathy L. Immunohistochemistry-a brief note on technical protocols. *European Journal of Molecular & Clinical Medicine*. 2020;7(10):696-702.
26. Shi Z, Stack M. An Update on Immunohistochemistry in Translational Cancer Research. *Cancer Translational Medicine*. 2015;1(4):115.
27. Bussolati G, Leonardo E. Technical pitfalls potentially affecting diagnoses in immunohistochemistry. *J Clin Pathol*. 2008;61(11):1184-92.
28. Shi Z, Stack M. An Update on Immunohistochemistry in Translational Cancer Research. *Cancer Translational Medicine*. 2015;1(4).
29. Parker KG, White MG, Cipriani NA. Comparison of Molecular Methods and BRAF Immunohistochemistry (VE1 Clone) for the Detection of BRAF V600E Mutation in Papillary Thyroid Carcinoma: A Meta-Analysis. *Head Neck Pathol*. 2020;14(4):1067-79.
30. De Biase D, Cesari V, Visani M, Casadei GP, Cremonini N, Gandolfi G, et al. High-sensitivity BRAF mutation analysis: BRAF V600E is acquired early during tumor development but is heterogeneously distributed in a subset of papillary thyroid carcinomas. *J Clin Endocrinol Metab*. 2014;99(8):E1530-8.
31. Kristiani E, Hardjolukito ES, Harahap AS, Makes B. BRAF V600E Immunoexpression in Papillary Thyroid Carcinoma and Its Association with Prognostic Factors and Histopathologic Variant. *Medicinus*. 2021;8(1):12-21.
32. Choden S, Keelawat S, Jung CK, Bychkov A. VE1 Immunohistochemistry Improves the Limit of Genotyping for Detecting BRAF(V600E) Mutation in Papillary Thyroid Cancer. *Cancers (Basel)*. 2020;12(3).
33. Fonseca D, Murthy S, Tagore R, Rao V, Rao C, N. Raju KV, et al. BRAF status in the variants of papillary thyroid carcinoma. *International Journal of Head and Neck Pathology*. 2018;1(2).
34. Zhang B, Xu C-W, Wu Y-F, Man Q-H, Song Y-Y, Wang J-J, et al. Diagnostic significance of the BRAF V600E mutation in conventional papillary thyroid carcinomas. *Int J Clin Exp Med*. 2016;9(5):8296-303.
35. Jung YY, Yoo JH, Park ES, Kim MK, Lee TJ, Cho BY, et al. Clinicopathologic correlations of the BRAF V600E mutation, BRAF V600E immunohistochemistry, and BRAF RNA in situ hybridization in papillary thyroid carcinoma. *Pathology-Research and Practice*. 2015;211(2):162-70.

36. Zhang Y, Liu L, Liu Y, Cao N, Wang L, Xing C. Clinical significance of immunohistochemistry to detect BRAF V600E mutant protein in thyroid tissues. *Medicine (Baltimore)*. 2021;100(16):e25566.
37. Kauffmann RM, Hamner JB, Ituarte PHG, Yim JH. Age greater than 60 years portends a worse prognosis in patients with papillary thyroid cancer: should there be three age categories for staging? *BMC Cancer*. 2018;18(1):316.
38. Li C, Lee KC, Schneider EB, Zeiger MA. BRAF V600E mutation and its association with clinicopathological features of papillary thyroid cancer: a meta-analysis. *J Clin Endocrinol Metab*. 2012;97(12):4559-70.
39. Koperek O, Kornauth C, Capper D, Berghoff AS, Asari R, Niederle B, et al. Immunohistochemical detection of the BRAF V600E-mutated protein in papillary thyroid carcinoma. *The American journal of surgical pathology*. 2012;36(6):844-50.
40. Sun J, Zhang J, Lu J, Gao J, Lu T, Ren X, et al. Immunohistochemistry is highly sensitive and specific for detecting the BRAF V600E mutation in papillary thyroid carcinoma. *International journal of clinical and experimental pathology*. 2015;8(11):15072.
41. Zagzag J, Pollack A, Dultz L, Dhar S, Ogilvie JB, Heller KS, et al. Clinical utility of immunohistochemistry for the detection of the BRAF v600e mutation in papillary thyroid carcinoma. *Surgery*. 2013;154(6):1199-204; discussion 204-5.
42. Barreno LRQ, Mello JBH, Barros-Filho MC, Francisco AL, Chulam TC, Pinto CAL, et al. Characterization of BRAF mutation in patients older than 45 years with well-differentiated thyroid carcinoma. *Braz J Otorhinolaryngol*. 2022;88(4):523-8.
43. McKelvie PA, Chan F, Yu Y, Waring P, Gresshoff I, Farrell S, et al. The prognostic significance of the BRAF V600E mutation in papillary thyroid carcinoma detected by mutation-specific immunohistochemistry. *Pathology*. 2013;45(7):637-44.
44. Ilie MI, Lassalle S, Long-Mira E, Bonnetaud C, Bordone O, Lespinet V, et al. Diagnostic value of immunohistochemistry for the detection of the BRAF V600E mutation in papillary thyroid carcinoma: comparative analysis with three DNA-based assays. *Thyroid*. 2014;24(5):858-66.

UNDER PEER REVIEW