

**THE BEST TIME TO DENTAL IMPLANT PLACEMENT IN PATIENTS WITH HEAD AND NECK CANCERS: AN EVER-GOING DEBATE**

**ABSTRACT**

With 500,000 new cases diagnosed each year, head and neck cancers (HNC) are among the most prevalent cancers in the world. The most effective organ-sparing therapy for patients with locally advanced HNC is concurrent chemoradiotherapy (C-CRT). Many HNC patients lose multiple teeth and develop soft and hard tissue defects over the course of the disease and treatment, leading to functional limitations and cosmetic deformity. Such devastating effects harm the patient's ability to eat, chew, and swallow as well as their psychological, financial, and social well-being. Additionally, multiple tooth losses and subpar oral rehabilitation services can cause cachexia, rapid weight loss, and weakened immunity. The use of conventional prostheses to address tooth losses may not be permitted due to detrimental changes in the structure of the oral cavity. Conventional prostheses may aggravate the harmful side effects of radiotherapy, including xerostomia, mucositis, and a deterioration of bone healing processes. Dental implants may be a better choice for oral rehabilitation. However, because the area of bone involved in implant placement is frequently within the irradiation zone, dental implant planning and timing in HNC patients can be extremely difficult. Additionally, the placement of dental implants may precipitate some specific side effects of cancer treatments, such as osteoradionecrosis. Because the best time to use dental implants is one of the essential components of successful dental rehabilitation for HNC survivors and has not yet been clarified in the literature, this review article aims to gather and provide information in the head and neck region by reviewing the available literature.

**Keywords:** Head and neck cancer, dental implant, timing, implant survival, oral rehabilitation.

## **INTRODUCTION**

Head and neck cancer (HNC), the sixth most common cancer type, has a 5-year survival rate of just above 50% with modern anticancer therapies (1–3). Chemotherapy, radiation therapy (RT), and surgical removal of the tumor are the most effective treatments currently available. However, after such aggressive therapies, a growing number of survivors experience significant soft and hard tissue defects, tooth loss, fistulas, jaw fractures, skin deficits, chronic pain, tissue fibrosis, diminished neuro-sensory functions, chewing capacity, and swallowing (4,5). Xerostomia, vulnerable mucosa, trismus, and osteoradionecrosis (ORN) are severe long-term RT adverse effects (3,6,7).

Due to a combination of persistent salivary decline, excessive sugar consumption, and high levels of cariogenic bacterial flora, patients undergoing head and neck RT are more likely to develop tooth caries (8). Multiple tooth loss occurs in this group of patients following RT due to deep rampant caries caused by a decrease in salivary volume, deterioration of salivary components, and RT comorbidities such as mucositis, which dramatically and adversely influence oral hygiene (9, 10). Because of this, patients require dental rehabilitation to enhance their ability to chew, swallow, and bite, to meet their daily nutritional needs, and to improve their aesthetic, social, psychological, and economic quality of life (11). Traditional removable dentures may not fit comfortably after treatments like RT and surgery because of anatomical changes in the orofacial region and jaws, like dry mouth; for this reason, dental implants are frequently chosen (12, 13). This decision is typically based on the fact that dental implants may provide more effective oral rehabilitation in terms of chewing, aesthetics, and speech function in this patient population (14).

A dental implant is an artificial tooth root that is surgically implanted into the jaw to support a bridge or prosthetic tooth, and it serves as the anchor for the restoration (15). The bone damage caused by the dental implant procedure is repaired in the same way that ordinary extractions heal. The damaged bone first resorbs, then realigns itself around the implant, and finally, osseointegration causes the dental implant to become permanently affixed to the bone (16). High radiation doses, accelerated or hyper-fractionation, additional chemotherapy, and surgical intervention in the radiation-damaged area, however, have all been connected to a delay or prevention of bone healing, which carries the risk of serious complications like ORN (17, 18). It can also be difficult to use implants in some patients because the area of bone needed for the procedure is frequently in the radiation-damaged zone (14), which could lead to more implant failures due to progressive tissue and vessel fibrosis and resultant reduced healing capacity of the injured site, tissue dehiscence, and ORN (19-21).

The timing of implant placement, the selected anatomical site for implantation, the radiation dose in that area, and the ensuing risk of ORN are just a few of the variables that can affect the success of implant rehabilitation in irradiated patients (22,23). Despite being a major concern, there is still no consensus in the literature regarding the optimal implant placement time for this patient group in relation to RT. As a result, the primary objective of this review is to investigate the time frame during which the most durable implant survival can be accomplished in HNC patients who are planning or have received RT and to advance knowledge in the fields of radiation oncology, head and neck oncology, and dentistry by compiling the literature.

## **METHODOLOGY**

This review article was conducted by examining the systematic reviews, original articles, meta-analyses, cohort studies, case reports, and abstracts published in English between January 1980 and November 2022. The keywords 'radiotherapy', 'dental implant', 'implant

placement', 'implant survival', 'osseointegration', and 'head and neck cancer' were used to search PubMed to identify relevant articles..

## **THE IMPACT OF RADIOTHERAPY ON THE OSSEOINTEGRATION OF DENTAL IMPLANTS**

Cure and function maintenance are the ultimate goals of HNC treatment, which calls for multidisciplinary management involving dentists, allied health professionals, radiation oncologists, medical oncologists, oral and maxillofacial surgeons, radiologists, and more. Dental implants and dental implant-supported prostheses improve patients' daily oral activities, such as nutrition, speaking, and swallowing, and thus their overall quality of life when used in multidisciplinary rehabilitation following and during C-CRT (12).

The deleterious consequences of RT, including ORN and early implant loss in irradiated bone, have been reported (24). In contrast, Schiegnitz et al. (25) examined six studies published between 2007 and 2013 on implant survival in the irradiated jaw versus the non-irradiated jaw and found no significant difference in implant survival between non-irradiated and irradiated patients. As can be seen from the readily available literature, there is still no agreement on the full impact of RT on dental implant survival and osseointegration, which is one of the most prudent determinants of long-term implant survival.

Osseointegration, defined as a direct structural and functional connection between ordered, living bone and the surface of a load-bearing implant, is critical for implant stability and is regarded as a prerequisite for implant loading and the long-term clinical success of endosseous dental implants (26). The alveolar bone and implant body first interlock during the osseointegration processes, and then the implant is biologically fixed through ongoing bone apposition and remodeling (27). Any lesion of the pre-existing bone matrix activates direct bone healing during the osseointegration process. Non-collagenous proteins and growth factors are released when the matrix is exposed to extracellular fluid, triggering bone repair

(28). Also, osseointegration is demonstrated radiographically by direct bone-implant contact, and a strong connection indicates that the implant will be stable and survive within acceptable limits (26). Implant survival and successful osseointegration are influenced by the surgeon's experience, bone quality and topography, implant length and diameter, and technical factors like primary stability, total radiation dose, and timing of implant placement (29, 30).

RT works by causing single-strand or double-strand DNA breaks in the irradiated healthy or tumor cells. Knowing how ionizing radiation affects the cell cycle at the cellular level will help us understand the mechanism of action better (31). Neoplastic cells, osteoblasts, and bone marrow cells that divide quickly are susceptible to cellular death at relatively low doses of radiation (50 Gy), and osteocytes become devitalized at high doses (70 Gy), leading to connective tissue fibrosis (32) (Figure 1). At different rates and for variable lengths of time, cellular death occurs at the tissue level, with both acute and long-term effects. Naturally, these effects hinder the normal healing process following oral surgical procedures and must be considered when treating patients who underwent RT (31). The main long-term effect of RT is a vascular alteration that reduces bone nutrition, leading to an osteoporotic-like condition that may harm the longevity of dental implants (33). Another issue is that soft tissues are more likely to dehiscence while bones are more susceptible to ORN, the most severe chronic complication from RT (31). ORN is thought to be caused by increased endarteritis with decreased microcirculation, resulting in hypoxic, hypovascular, and hypocellular bone (24). Osteoblasts and osteocytes suffer irreparable harm, and the periosteum above them undergoes fibrosis (24). When tissue hypoxia occurs, necrotic bone is exposed, and natural healing processes do not occur (34,35). As a result, issues with the bone after RT may not only affect the implant's success but also result in issues like ORN, which can have devastating consequences and hinder the patient's ability to support their oral rehabilitation.

Basically, a hole is drilled into the jawbone during the placement of a dental implant, which creates a defect in the jawbone, albeit voluntarily. In addition to primary fracture healing and osseointegration being triggered by any lesion of the pre-existing bone matrix, direct bone healing also happens in defects (26). Non-collagenous proteins and growth factors are released when the matrix is exposed to extracellular fluid, activating bone repair (28). Once activated, osseointegration follows a common, biologically determined program divided into three stages: (1) incorporation by woven bone formation, (2) adaptation of bone mass to load (lamellar and parallel-fibered bone deposition), and (3) adaptation of bone structure to load (bone remodeling). For this reason, it can be assumed that RT, which is involved in bone healing, is also active in the osseointegration process. The formation of inflammation under the influence of RT, vascular occlusion by inflammatory mediators, and activation of fibrosis by both tissue hypoxia and fibrinolytic agents will all prevent the development of the bone implant anchor around the implant (21, 32). Moreover, implant stability may be compromised, implant loss may occur, and non-healing bone necrosis may be observed due to ORN's involvement in this cascade of damaging events (21).

Soares et al. conducted an in vivo study in which the authors examined the biomechanical and morphological alterations brought on by ionizing radiation in the bone tissue surrounding the dental implants of 20 rabbits (36). Rabbits were used in the study because they have Haversian systems similar to humans and a three times faster rate of bone turnover, allowing for short-term analysis of the osseointegration process. The animals were divided into two groups: those with and without RT, and the group receiving RT received a single dose of 30 Gy two weeks after implant placement. Animals were sacrificed four weeks after the implant procedure, and implant/bone samples were used in each experiment. A 4-week gap between implant placement and animal sacrifice was used to simulate the early period of osseointegration that is the foundation of current human treatment protocols. The

micro-CT findings that were examined in this study included cortical volume, cortex thickness, and porosity, which describe the integrity and quality of cortical bone. The authors concluded that the decrease in bone mass found in irradiated groups of bone tissue both close and far from the implant could be attributed to impaired vascularization and osteoblast activity.

It has been reported that the dose of radiation has an effect on osseointegration (37). There is, however, no agreement on the maximum threshold radiation doses that patients should not receive in order to achieve a high implant survival rate. According to some studies on RT doses, radiation dosages higher than 40–50 Gy may impair bone healing, which may jeopardize implant osseointegration (38, 39). In contrast, Javed colleagues' review of the literature revealed that dental implants that had been exposed to radiation doses of up to 65 Gy showed osseointegration rates of up to 100% (40). Accordingly, radiation dosages between 50 and 65 Gy may be assumed by some to have no negative impact on osseointegration. However, in the Cao and Weischer study, one of the rare studies examining the effect of RT on osseointegration, the prognosis of 131 dental implants was investigated in 27 patients who received RT (range: 36–76 Gy) for the treatment of oral carcinoma. After roughly two years of follow-up, their findings revealed that irradiated patients had a significantly lower implant survival rate than non-irradiated patients (41). Klein et al. studied the survival of 116 dental implants placed in native bone that received 50–70 Gy and found that the 5-year implant survival rates were 77.5% and 90.9% in implants that received more than 50 Gy and less than 50 Gy, respectively (35). This result was explained by the deterioration of blood flow and nutrition in the bone tissue brought on by the long-lasting effects of RT over time (35). Similarly, in the study of Nack et al., dental implants were placed in patients who received 72 Gy RT in the head and neck region approximately 6 months after the end of the treatment. Implant survival was estimated to be 92 percent, 80%,

and 75.2%, respectively, at the 1-, 3-, and 5-year mark (42). Therefore, patients who have received radiation should always be informed about the potential side effects of implant surgery and should formally consent to them because of the ongoing discussion on the best timing for implant placement.

When assessing the prevalence of ORN (43) and dental implant survival (35, 42), researchers primarily use the total RT dose applied to the jaw area as a base. However, the mean, median, maximum, and V<sub>x</sub> (mandibular volume receiving X Gy or more) doses are the main variables that determine the actual risk of ORN and, consequently, the success of osseointegration (44). Although total RT doses delivered to the tumor are one of the factors that influence ORN formation (45), planning target volumes and jaw doses may differ significantly across tumor types, even if all other parameters are distributed equally. With this information in mind, Li et al. (46) evaluated the survival of 151 implants in 58 HNC patients who underwent RT and discovered that the median dose administered to the tumor was 62.4 Gy, while the average dose administered to the implant bed was 40 Gy. Despite the lack of volumetric data, the authors stated that bone resorption around implants that received more than 40 Gy was significantly larger than that around implants that received less than 40 Gy. These results highlight the importance of volumetric dose exposures and imply that the dosage prescribed to the tumor site alone may not be sufficient to assess ORN risk or dental implant survival and will not accurately reflect the true prevalence of these complications.

The relationship between rising implant failure rates and high radiation doses may be explained by the deterministic effects of radiation on irradiated tissues: the higher the radiation dose, the more intensely and frequently the tissue damage occurs. Ionizing radiation has been demonstrated to produce vascular endothelial cell damage as a function of dose that is followed by the obliteration of some blood vessels, reducing the perfusion of osteogenic cells, particularly in bone formation and growth areas (47, 48). As a result of direct tissue

damage or hypoxic/malnourished conditions brought on by ionizing radiation, osteoblasts undergo apoptosis because they are more radiosensitive than other bone cells (49). Furthermore, it is hypothesized that RT exposure alters collagen modulation, which slows down the mineralization process and affects implant failure (36). This hypothesis is supported by the fact that irradiation causes free radicals to be created through the radiolysis of water molecules, destroys collagen molecules, and prevents fibrillary sliding processes, all of which interfere with the proper molecular configuration for the biomineralization process to take place (50–52). Furthermore, irradiation may influence osteoblast activity in terms of normal deposition and the formation of hydroxyapatite crystals from the inorganic matrix (50,51).

Based on the interpretation of these pathophysiological mechanisms and the outcomes of the earlier studies, it seems reasonable to postulate that implant survival and the radiation dose exposed at the implant placement site are closely related. Doses above 40–50 Gy seem to be linked to higher rates of implant failure than their lower dose counterparts, though the exact **dose-response** relationship is unknown. However, it is worth noting that future investigations analyzing the dose-volume-response correlations are needed to elucidate essential RT doses or volume of the implant placement location receiving doses over a critical threshold value that may accurately predict implant failures in this patient population.

#### **DETERMINING THE EXACT TIME FOR DENTAL IMPLANT APPLICATIONS IN HEAD AND NECK CANCER PATIENTS**

While ORN is an already-expected late RT complication, the incidence of this severe complication may rise after bone-traumatizing procedures in irradiated patients, such as tooth extraction and dental implant surgery (53). Jawbone trauma of varying degrees will occur as a result of dental implant surgery because it is an invasive procedure (54). When the wound caused by the trauma cannot heal after either an early (4 months after RT) or a late (4 months or more after RT) trauma, ORN develops after cell death becomes evident (21). The bone and

soft tissues become more susceptible to mitotic death and necrosis as time passes after RT. Therefore, patients who received prior RT continue to be at risk for long-term radiation-related complications that could be brought on by surgery or infections (21, 55, 56). Because the risk of ORN persists throughout the patient's remaining life span, every invasive surgical procedure, including dental implant placement, should be foregone with meticulous treatment planning (57).

Although the literature supports and suggests relatively safer implant implantation 6 to 12 months after irradiation, there is no well-established scientific evidence for the ideal timing of implant placement (57,58). On the other hand, some authors advise implant placement after tumor surgery and claim that this schedule is advantageous because the initial implant healing (osseointegration) takes place before irradiation, and as a result, the risk of ORN is thought to be decreased (50-63). In this regard, in their insightful systematic review of 16 studies involving 3,445 HNC patients, Pitorro and colleagues assessed the survival rate of implants placed before and after RT or without RT (64) (Figure 2). The authors reported that the survival rates for post-RT, pre-RT, and non-RT implants were 80% to 100%, 89.4% to 97%, and 92.2% to 100%, respectively. As a result, despite the alterations generated by ionizing radiation in the tissues surrounding the implant, dental implants placed before and after RT showed great survival rates comparable to those implanted without RT, according to the authors. In a similar systematic review, Collela et al. found statistically indistinguishable failure rates for implants placed after RT versus before RT (3.2% and 5.4%) and reported that implant failures occurred 36 months after RT(65). This finding is congruent with Delanian's theory of radiation-induced fibrosis formation in bone tissue as measured by implant failure time. So, if the implant is placed more than 8 months after RT, the resulting wound may heal by fibrosis formation due to vascular obliteration and impaired blood supply in the affected bone, inducing bone resorption and possibly ORN (35). Hence, on these grounds, it may be

rationaly speculated that the longer the implantation procedure is delayed following RT, the greater the chance of dental implant loss.

When Kim et al. originally developed implant-based dental rehabilitation in oral cancer patients, the authors said that the implants were frequently placed after oncologic treatment (66). This fixed time for dental implant placement involves further surgery for irradiated patients on antimicrobial prophylaxis and additional therapeutic stress for older patients, many of whom have multiple comorbid conditions. Patients who are offered implant therapy in the post-RT phase are less likely to accept additional surgical procedures because they are already overburdened by the side effects of RT, even though they may greatly benefit from an implant-supported prosthesis.

Dental implants can potentially be implanted during tumor surgery as an alternative (67). Because the majority of osseointegration occurs during the healing period prior to RT, this treatment sequence avoids extra surgery and saves a large amount of time. Resultantly, the patient can function with an implant-supported prosthesis substantially sooner after completing oncologic treatment (68). The disadvantages of this method include the possibility of incorrect implant placement due to changes in anatomy during surgery, as well as the likelihood of implants not being used due to tumor recurrence or patients dying before the administration of **the dental prosthesis** (unnecessary expenditure of resources).

There are no solidly recommended and appreciated timelines for starting oral rehabilitation with dental implants in HNC patients, and there is debate over how RT affects the osseointegration process and implant survival rates. Overall, only a small number of systematic reviews have been published, most focusing on the timing of implant placement after RT (69, 70). However, the hypothesis that dental implant placement may become more important over time due to the steadily declining bone's ability to heal after RT outweighs the available evidence, according to studies done in recent years (71, 72).

## **DISCUSSION**

There is ongoing discussion regarding the best time for dental implant placement in HNC patients. Even though most studies used retrospective designs and examined implant placement in diverse patient populations, placing dental implants—regardless of when they are placed in relation to RT—seems to be an efficient treatment option for this group of patients. However, some concerns may need to be addressed before making firm recommendations on the best time to place dental implants in patients with HNC who require RT. First, when should dental implants be placed in HNC patients in order to maximize implant survival and functional outcomes? Second, is pre-treatment dental implant placement beneficial for all HNC patients, or is it only appropriate for specific patient populations? The literature on the timing of dental implant placement in HNC patients should be thoroughly reviewed in light of the advancements in dental implant therapy and techniques over the past ten years to construct dependable recommendations for clinical practice. The dental implant site, timing of placement, RT dose, concurrent chemotherapy and/or steroid use, poor oral hygiene, gingival diseases, systemic inflammatory diseases like diabetes, alcohol and tobacco addiction, and insufficient osseointegration are the most frequently mentioned factors affecting dental implant survival in HNC patients (69).

Osseointegration is a dynamic process that requires the normal execution of the inherent biological processes during bone remodeling, especially the resorption of old bone by osteoclasts and the formation of new bone by osteoblasts (73); these processes are both necessary for osseointegration. Angiogenesis, the formation of immature blood capillaries, is critical to these activities because bone cells, like all cells in the human body, require an adequate blood supply. As a result, drugs and applications that interfere with bone remodeling and angiogenesis can compromise osseointegration and lead to early dental implant failure (74, 75).

Despite debatable issues regarding their methodological designs and endpoints, numerous studies on the timing of implant placement and implant survival in HNC patients have been conducted. Claudy et al. discovered that placing dental implants 6 to 12 months after RT was associated with a 34% higher risk of implant loss than placing them 12 months after RT, so they established a one-year waiting period (71). Sammartino et al., on the other hand, suggest delaying treatment for at least 12 months to achieve the best clinical results (76). Additionally, Ganström et al. advise that implant therapy be completed between 6- and 18 months following radiation (55). Disputing all of these findings, Schoen et al. concluded that there was no connection between the loss of implants and the time between RT and implant placement (77). Therefore, even though the precise timing has not yet been established, based on the findings of the available studies, implant placement is typically not advised in the first six months of the post-RT period (78). Nonetheless, because tooth extraction and dental implant placement are both invasive surgical procedures, this recommendation appears to contradict the findings of ORN research, which advocate for early tooth extractions to reduce the development of this crippling RT consequence. Therefore, appropriately planned, large-scale randomized studies are required to obtain reliable conclusions regarding the best time to place dental implants in HNC patients who have undergone or have been scheduled to undergo RT or C-CRT to the head and neck region. These moves are essential to striking a balance between implant survival success and ORN-prevention efforts.

Dental implant placement procedures are recognized as surgical trauma that may result in ORN in RT-exposed tissues (79). Although debatable, implant placement in irradiated jaws may increase implant loss rates (19). Radiation-induced changes to already traumatized jaws or radiation-induced jaw trauma prior to implant placement may lead to noticeably higher rates of implant loss, even though the underlying mechanisms may be more intricate and

multifaceted. This phenomenon can be rationally explained as follows: The healing capacity of tissues may be reduced due to the potential of RT to cause progressive fibrosis of vessels and soft tissues. High doses of ionizing radiation can disrupt the dynamic balance of bone resorption and remodeling by injuring blood vessels and causing hypocellularity in bone tissue. In addition to delaying bone healing, RT may lessen bone neovascularization, leading to ORN (80). Radiation-induced fibro-atrophic mechanisms, which include the formation of free radicals, endothelial dysfunction, inflammation, microvascular thrombosis, fibrotic remodeling, and, finally, bone and tissue necrosis, are thought to be the causes of ORN (38). Even if the delivery of RT ceased, the structural deformation within the bone would typically endure and get worse. Because of the progressive and irreversible loss of capillaries, it is critical to note that the risk of ORN following RT in HNC patients does not lessen over time (25). In light of these fundamental mechanisms, it is reasonable to assume that prolonging the time between RT and implant placement will probably result in an increased risk of ORN and decreased implant survival in the irradiated bone. Similarly, because ablative surgery causes significant and unfavorable alterations in the bone anatomy, too-early implant placement practices may also be problematic (81). Dental implants cannot be positioned correctly in this circumstance due to the deformed bone, and the patient may be unable to maintain good oral hygiene due to the wide surgical wound, which may result in gingival infections and implant loss (81).

## **CONCLUSION**

Several factors affect the success of implant-supported rehabilitation in patients with irradiated HNC. Dental implants can, however, be difficult to place into a jawbone that has undergone RT or C-CRT. To make matters worse, our knowledge of the best implant application timing remains incoherent due to the retrospective nature and methodological discrepancies of the existing research on this vital subject. However, it is doubtful that waiting

only six months after RT to place dental implants is the best course of action. Instead, healing times of at least one year may be preferred. On the other hand, both waiting periods run counter to our knowledge, which advises that dental extractions be carried out as soon as possible before the end of the fibroatrophic bone healing process to prevent ORN. As a result, because the existing information is insufficient, well-designed clinical trials are required to reach definitive conclusions on the appropriate timing of implant placement relative to RT in order to obtain the maximum implant success rates with a minimum ORN risk. Finally, taking into account all of these conflicts, we suggest deciding on the ideal time for implant placement based on a patient's particular situation on the tumor board and discussing any potential risks with the patient. Whether the procedure is to be done before or after RT, the advice is still relevant.

## REFERENCES

1. Serindere G, Bolgul B, Gursoy D, Hakverdi S, Savas N. Comparison of Head and Neck Cancer Distribution in Turkish and Syrian Populations. *Iran J Public Health.* 2019;48(10):1810-1816.
2. Jemal A, Murray T, Ward E, et al. Cancer statistics, 2005. *CA Cancer J Clin.* 2005;55:10–30.
3. Vigneswaran N, Williams MD. Epidemiologic trends in head and neck cancer and aids in diagnosis. *Oral Maxillofac Surg Clin North Am.* 2014;26(2):123-41.
4. Hammerlid E: Quality of life in head and neck cancer. Thesis, University of Gothenburg, Sweden, 1997
5. Somay, E., Yilmaz, B., Topkan, E., Kucuk, A., Pehlivan, B., & Selek, U. Assessment of the Impact of Osteoradionecrosis on Quality-of-Life Measures in Patients with Head and Neck Cancer. *Exon Publications*, 2022; 41-56.

6. Meraw SJ, Reeve CM. Dental considerations and treatment of the oncology patient receiving radiation therapy. *J Am Dent Assoc.* 1998;129:201–205.
7. Linsen SS, Martini M, Stark H. Long-term results of endosseous implants following radical oral cancer surgery with and without adjuvant radiation therapy. *Clin Implant Dent Relat Res.* 2012;14:250–258
8. Jawad H, Hodson NA, Nixon PJ. A review of dental treatment of head and neck cancer patients, before, during and after radiotherapy: part 1. *Br Dent J.* 2015;218(2):65-8.
9. Brown L R, Dreizen S, Handler S, Johnston D A . Effect of radiation-induced xerostomia on human oral microflora. *J Dent Res* 1975; **54**: 740–750.
10. Dreizen S, Brown L R, Daly T E, Drane J B . Prevention of xerostomia-related dental caries in irradiated cancer patients. *J Dent Res* 1977; **56**: 99–104.
11. Somay, E., Yilmaz, B., Kucuk, A. and Topkan, E. 2022. Quality of Life Changes in Patients with Osteoradionecrosis and Their Measurement. *Journal of Advances in Medicine and Medical Research.* 2022;21; 48-61.
12. Nelson K, Heberer S, Glatzer C. Survival analysis and clinical evaluation of implant-retained prostheses in oral cancer resection patients over a mean follow-up period of 10 years. *J Prosthet Dent.* 2007;98:405–410.
13. Buddula A, Assad DA, Salinas TJ, Garces YI, Volz JE, Weaver AL. Survival of turned and roughened dental implants in irradiated head and neck cancer patients: a retrospective analysis. *J Prosthet Dent.* 2011;106:290–296
14. De Angelis F, Papi P, Mencio F, et. Implant survival and success rates in patients with risk factors: results from a long term retrospective study with a 10 to 18 years follow-up. *Eur Rev Med Pharmacol Sci.* 2017; 21(3): 433-437

15. Ogawa T, Sitalaksmi RM, Miyashita M, Maekawa K, Ryu M, Kimura-Ono A, Suganuma T, Kikutani T, Fujisawa M, Tamaki K, Kuboki T. Effectiveness of the socket shield technique in dental implant: A systematic review. *J Prosthodont Res.* 2022;66(1):12-18.
16. Le Guéhennec L, Soueidan A, Layrolle P, Amouriq Y. Surface treatments of titanium dental implants for rapid osseointegration. *Dent Mater.* 2007;23(7):844-54.
17. Ihde S, Kopp S, Gundlach K, Konstantinovic VS. Effects of radiation therapy on craniofacial and dental implants: a review of the literature. *Oral Surg Oral Med Oral Pathol Oral Radiol Endod.* 2009;107:56–65
18. Granström G. Radiotherapy, osseointegration and hyperbaric oxygen therapy. *Periodontol* 2000. 2003;33:145-62.
19. De la Plata M, Gías LN, Díez PM, et al. Osseointegrated implant rehabilitation of irradiated oral cancer patients. *J Oral Maxillofac Surg.* 2012;70:1052–63
20. Yerit KC, Posch M, Seemann M, et al. Implant survival in mandibles of irradiated oral cancer patients. *Clin Oral Implants Res.* 2006; 17:337–44
21. Marx RE, Johnson RP. Studies in the radiobiology of osteoradionecrosis and their clinical significance. *Oral Surg Oral Med Oral Pathol.* 1987; 64:379–9
22. Brauner E, Di Carlo S, Ciolfi A, et al. Use of porous implants for the prosthetic rehabilitation of fibula free flap reconstructed patients. *J Craniofac Surg.* 2019; 30 (4): 1163-1169
23. Sammartino G, Marenzi G, Cioffi I. Implant therapy in irradiated patients. *J Craniofac Surg.* 2011; 22:443
24. Tanaka TI, Chan HL, Tindle DI, et al. Updated clinical considerations for dental implant therapy in irradiated head and neck cancer patients. *J Prosthodont.* 2013;22:432–438

25. Schiegnitz E, Al-Nawas B, Kämmerer PW, et al. Oral rehabilitation with dental implants in irradiated patients: A meta-analysis on implant survival. *Clin Oral Investig*. 2014;18:687–698.
26. Parithimarkalaigan S, Padmanabhan TV. Osseointegration: an update. *J Indian Prosthodont Soc*. 2013;13(1):2-6.
27. Albrektsson T, Brånemark PI, Hansson HA, Lindström J. Osseointegrated titanium implants. Requirements for ensuring a long-lasting, direct bone-to-implant anchorage in man. *Acta Orthop Scand*. 1981;52(2):155-70.
28. Schenk RK, Buser D. Osseointegration: a reality. *Periodontology 2000*. 1998;17:22–35.
29. Linsen SS, Martini M, Stark H. Long-term results of endosteal implants following radical oral cancer surgery with and without adjuvant radiation therapy. *Clin Implant Dent Relat Res*. 2012; 14: 250–8
30. Pompa G, Brauner E, Jamshir S, et al. Quality of Life in Patients Rehabilitated with Palatal Obturator without Reconstruction Versus Fixed Implant-Prosthesis after Reconstruction of Maxillectomy Defects. *Journal of International Dental and Medical Research* ISSN 1309-100X
31. Anderson L, Meraw S, Al-Hezaimi K, Wang HL. The influence of radiation therapy on dental implantology. *Implant Dent*. 2013;22(1):31-8.
32. Marx R, Stern D. *Oral and Maxillofacial Pathology. A Rationale for Diagnosis and Treatment*. Chicago, IL: Quintessence; 2003
33. Minsk L, Polson AM. Dental implant outcomes in postmenopausal women undergoing hormone replacement. *Compend Contin Educ Dent*. 1998;19:859– 862, 864; quiz 866.
34. Lambert PM, Intriere N, Eichstaedt R. Clinical controversies in oral and maxillofacial surgery: Part one. Management of dental extractions in irradiated jaws: A protocol with hyperbaric oxygen therapy. *J Oral Maxillofac Surg*. 1997;55:268–274.

35. Delanian S, Lefaix JL. The radiation-induced fibroatrophic process: therapeutic perspective via the antioxidant pathway. *Radiother Oncol.* 2004;73(2):119-31.
36. Soares PBF, Soares CJ, Limirio PHJO, Lara VC, Moura CCG, Zanetta-Barbosa D. Biomechanical and morphological changes produced by ionizing radiation on bone tissue surrounding dental implant. *J Appl Oral Sci.* 2020;28;28:e20200191.
37. Granstrom G, Jacobsson MG, Tjellstrom A. Titanium implants in irradiated tissue: benefits from hyperbaric oxygen. *Int J Oral Maxillofac Implants* 1992;7(1):15–25
38. Aitasalo K. Bone tissue response to irradiation and treatment model of mandibular irradiation injury. An experimental and clinical study. *Acta Otolaryngol Suppl* 1986;428:1–54.
39. Beumer 3rd J, Roumanas E, Nishimura R. Advances in osseointegrated implants for dental and facial rehabilitation following major head and neck surgery. *Semin Surg Oncol* 1995;11(3):200–7
40. Javed F, Al-Hezaimi K, Al-Rasheed A, Almas K, Romanos GE. Implant survival rate after oral cancer therapy: a review. *Oral Oncol.* 2010;46(12):854-9.
41. Cao Y, Weischer T. Comparison of maxillary implant-supported prosthesis in irradiated and non-irradiated patients. *J Huazhong Univ Sci Technolog Med Sci.* 2003;23(2):209–12
42. Nack C, Raguse JD, Stricker A, Nelson K, Nahles S. Rehabilitation of irradiated patients with chemically modified and conventional SLA implants: five-year follow-up. *J Oral Rehabil.* 2015;42(1):57-64.
43. DeLuke D, Carrico C, Ray C, Stilianoudakis S, Holler S, Padilla L, Song S. Is Dose Volume a Better Predictor of Osteoradionecrosis Risk Than Total Dose for Patients Who Have Received Head and Neck Radiation? *J Oral Maxillofac Surg.* 2022;80(9):1557-1563.

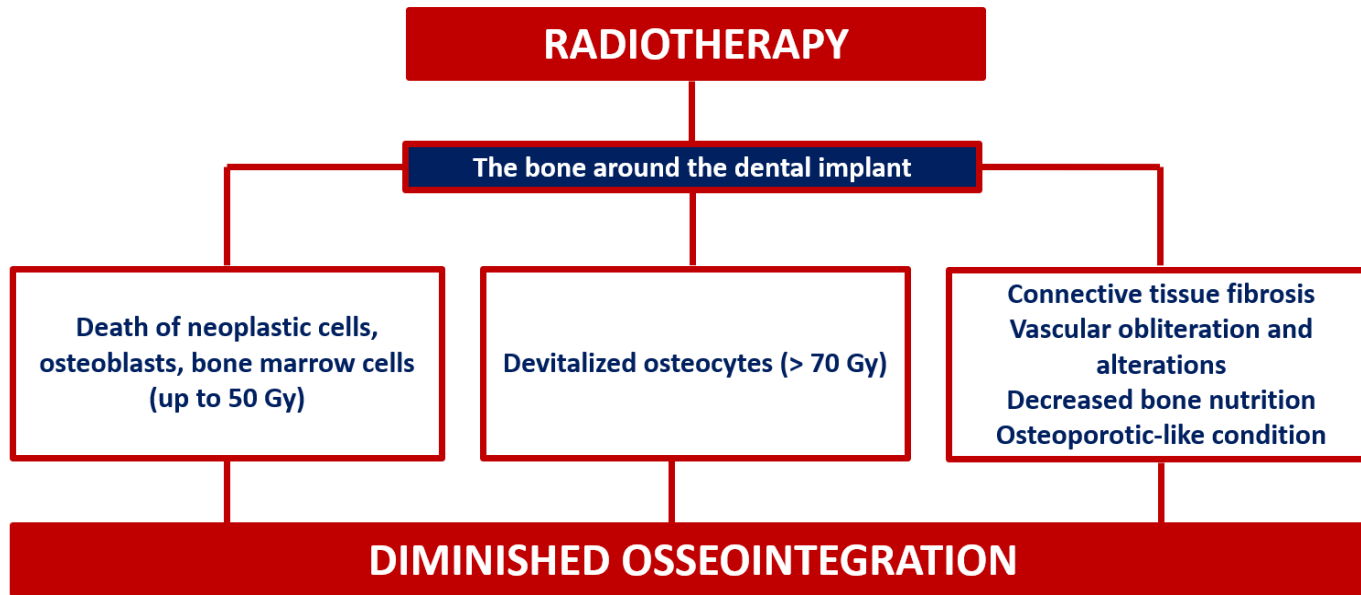
44. Caparrotti F, Huang SH, Lu L, et al. Osteoradionecrosis of the mandible in patients with oropharyngeal carcinoma treated with intensity-modulated radiotherapy. *Cancer*. 2017;123(19):3691-700.
45. Kubota H, Miyawaki D, Mukumoto N, Ishihara T, Matsumura M, Hasegawa T, et al. Risk factors for osteoradionecrosis of the jaw in patients with head and neck squamous cell carcinoma. *Radiat Oncol*. 2021;16(1):1.
46. Li J, Feng K, Ye L, Liu Y, Sun Y, Wu Y. Influence of radiotherapy on dental implants placed in individuals before diagnosed with head and neck cancer: focus on implant-bed-specific radiation dosage. *Clin Oral Investig*. 2022;26(9):5915-5922.
47. Curi MM, Oliveira dos Santos M, Feher O, Faria JC, Rodrigues ML, Kowalski LP. Management of extensive osteoradionecrosis of the mandible with radical resection and immediate microvascular reconstruction. *J Oral Maxillofac Surg*. 2007;65(3):434-8.
48. Huang B, Yao Q, Huang Y, Zhang L, Yao Y, Gong P, et al. Combination use of BMP2 and VEGF165 promotes osseointegration and stability of titanium implants in irradiated bone. *BioMed Res Int*. 2018;2018:8139424.
49. Dudziak ME, Saadeh PB, Mehrara BJ, Steinbrech DS, Greenwald JA, Gittes GK, et al. The effects of ionizing radiation on osteoblast like cells in vitro. *Cell Tissue Bank*. 2000;106(5):1049-61.
50. Nguyen H, Morgan DA, Forwood MR. Sterilization of allograft bone: effects of gamma irradiation on allograft biology and biomechanics. *Cell Tissue Bank*. 2007;8(2):93-105.
51. Barth HD, Zimmermann EA, Schaible E, Tang SY, Alliston T, Ritchie RO. Characterization of the effects of x-ray irradiation on the hierarchical structure and mechanical properties of human cortical bone. *Biomaterials*. 2011;32(34):8892-904.
52. Limirio P, Soares PB, Emi ET, Lopes CC, Rocha FS, Batista JD, et al. Ionizing radiation and bone quality: time-dependent effects. *Radiat Oncol*. 2019;14(1):15.

53. Nabil S, Samman N. Incidence and prevention of osteoradionecrosis after dental extraction in irradiated patients: a systematic review. *Int J Oral Maxillofac Surg.* 2011;40(3):229-43.
54. Kotsakis GA, Romanos GE. Biological mechanisms underlying complications related to implant site preparation. *Periodontol 2000.* 2022;88(1):52-63.
55. Granstrom G. Osseointegration in irradiated cancer patients: An analysis with respect to implant failures. *J Oral Maxillofac Surg.* 2005;63:579–585.
56. Stone HB, Coleman CN, Anscher MS, et al. Effects of radiation on normal tissue: Consequences and mechanisms. *Lancet Oncol.* 2003;4:529–536.
57. Epstein J, van der Meij E, McKenzie M, et al. Post radiation osteonecrosis of the mandible: A long-term follow-up study. *Oral Surg Oral Med Oral Pathol Oral Radiol Endod.* 1997;83:657–662
58. Javed F, Al-Hezaimi K, Al-Rasheed A, Almas K, Romanos GE. Implant survival rate after oral cancer therapy: a review. *Oral Oncol* 2010;46(12):854–859.
59. Anderson L, Meraw S, Al-Hezaimi K, Wang HL (2013) The influence of radiation therapy on dental implantology. *Implant Dent.* 2013; 22(1): 31–38.
60. De Felice F, De Vincentiis M, Valentini V, et al. Management of salivary gland malignant tumor: the Policlinico Umberto I, “Sapienza” University of Rome Head and Neck Unit clinical recommendations. *Crit Rev Oncol Hematol.* 2017; 120:93-97.
61. Barber AJ, Butterworth CJ, Rogers SN. Systematic review of primary osseointegrated dental implants in head and neck oncology. *Br J Oral Maxillofac Surg.* 2011; 49: 29–36
62. Lorenzi C, Arcuri L, Lio F, Dolci A, Arcuri C. Radiosurgery in dentistry: a review. *Clin Ter.* 2019;170(1):e48-e54.

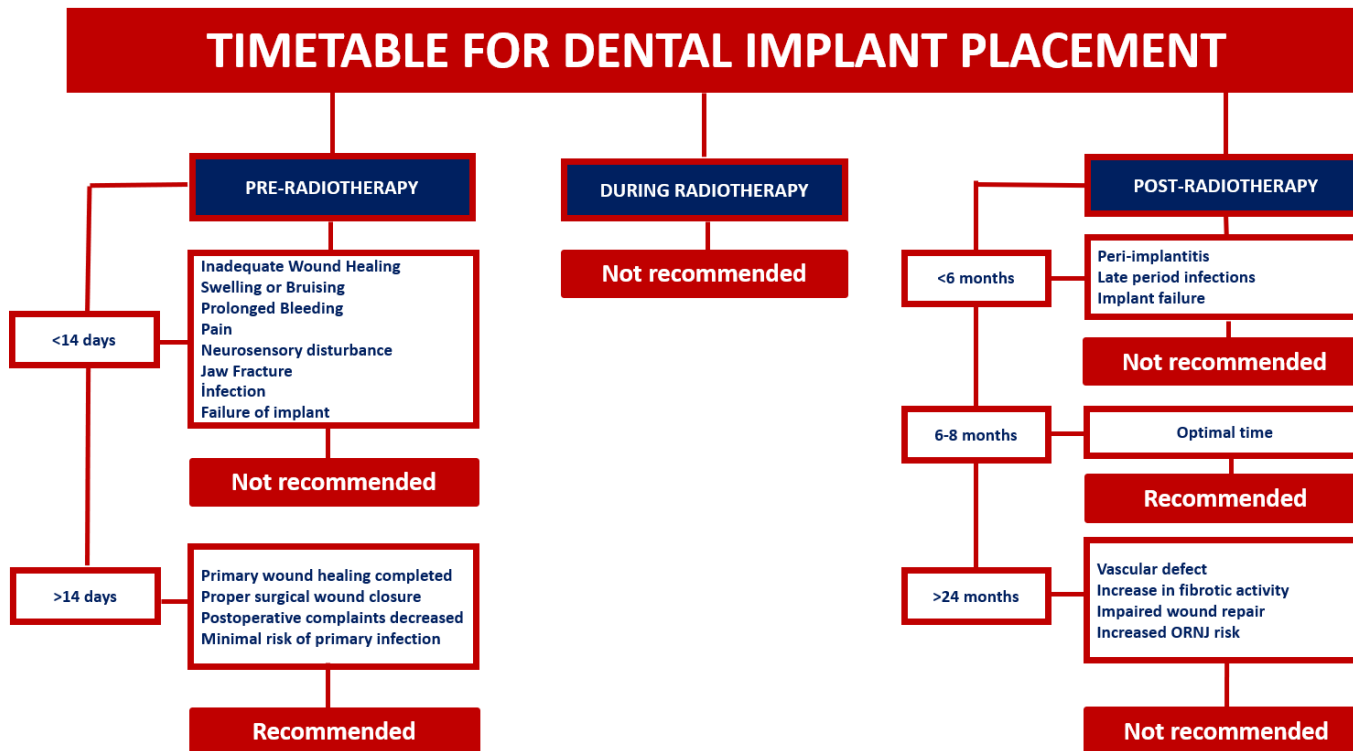
63. Korfage A, Schoen PJ, Raghoobar GM, et al. Benefits of dental implants installed during ablative tumor surgery in oral cancer patients: a prospective 5-years clinical trial. *Clin Oral Implants Res.* 2010; 21: 971–9
64. Atanásio Pitorro TE, de Araújo Reis NT, Paranhos LR, Ferreira Soares PB. Survival of Dental Implants Placed Pre-Radiotherapy Versus Post-Radiotherapy in Native Bone: A Systematic Review. *Int J Oral Maxillofac Implants.* 2022;37(6):1100-1109.
65. Colella G, Cannavale R, Pentenero M, Gandolfo S. Oral implants in radiated patients: a systematic review. *Int J Oral Maxillofac Implants.* 2007;22(4):616-22.
66. Kim DD, Ghali GE. Dental implants in oral cancer reconstruction. *Oral Maxillofac Surg Clin North Am.* 2011;23(2):337-45, vii.
67. Schoen PJ, Reintsema H, Raghoobar GM, Vissink A, Roodenburg JL. The use of implant retained mandibular prostheses in the oral rehabilitation of head and neck cancer patients. A review and rationale for treatment planning. *Oral Oncol.* 2004;40(9):862-71.
68. Petrovic I, Rosen EB, Matros E, Huryn JM, Shah JP. Oral rehabilitation of the cancer patient: A formidable challenge. *J Surg Oncol.* 2018;117(8):1729-1735.
69. Claudy MP, Miguens SA Jr, Celeste RK, Camara Parente R, Hernandez PA, da Silva AN Jr. Time interval after radiotherapy and dental implant failure: systematic review of observational studies and meta-analysis. *Clin Implant Dent Relat Res.* 2015;17(2):402-11.
70. Nooh, N. Dental implant survival in irradiated oral cancer patients: A systematic review of the literature. *International Journal of Oral & Maxillofacial Implants.* 2013; 28;1233–1242.
71. Granström G. Radiotherapy, osseointegration and hyperbaric oxygen therapy. *Periodontology.* 2003;33;145–162.
72. Alberga JM, Vosselman N, Korfage A, Delli K, Witjes MJH, Raghoobar GM, Vissink A. What is the optimal timing for implant placement in oral cancer patients? A scoping literature review. *Oral Dis.* 2021;27(1):94-110.

73. Ouanounou A, Hassanpour S, Glogauer M. The influence of systemic medications on osseointegration of dental implants. *J Can Dent Assoc.* 2016;82:g7
74. Sharma D, Hamlet SM, Petcu EB, Ivanovski S. The effect of bisphosphonates on the endothelial differentiation of mesenchymal stem cells. *Sci Rep.* 2016;6:1–11.
75. Taylor TD, Worthington P. Osseointegrated implant rehabilitation of the previously irradiated mandible: results of a limited trial at 3 to 7 years. *J Prosthet Dent* 1993; 69:60–69
76. Sammartino G, Marenzi G, Cioffi I. Implant therapy in irradiated patients. *J Craniofac Surg.* 2011; 22:443
77. Schoen PJ, Raghoobar GM, Bouma J, et al. Rehabilitation of oral function in head and neck cancer patients after radiotherapy with implant-retained dentures: effects of hyperbaric oxygen therapy. *Oral Oncol.* 2007;43:379–388.
78. Brauner E, Guarino G, Jamshir S, et al. Evaluation of Highly Porous Dental Implants in Postablative Oral and Maxillofacial Cancer Patients: A Prospective Pilot Clinical Case Series Report. *Implant Dent.* 2015; 24(5):631-7
79. Ben Slama L, Hasni W, De Labrouhe C, Bado F, Bertrand JC. Ostéoradionécrose sur implants dentaires [Osteoradionecrosis and dental implants]. *Rev Stomatol Chir Maxillofac.* 2008;109(6):387-91; discussion 391-2.
80. Marx RE. Osteoradionecrosis: a new concept of its pathophysiology. *J Oral Maxillofac Surg* 1983; 41:283–288.
81. Zheng M, Li L, Tang Y, et al. How to improve the survival rate of implants after radiotherapy for head and neck cancer? *J Periodontal Implant Sci.* 2014; 44: 2–7
82. Sgolastra F, Petrucci A, Severino M, Gatto R, Monaco A. Periodontitis, implant loss and peri-implantitis. A meta-analysis. *Clin Oral Implants Res.* 2015;26(4):e8-e16.

UNDER PEER REVIEW



**Figure 1.** The effect of radiotherapy on osseointegration



**Figure 2.** Timing for dental implant placement in head and neck cancer patients