

## **Case study**

# **An unusual case of isolated cysticercosis of breast imitating breast malignancy**

### **ABSTRACT**

**AIMS:** Cysticercosis is a zoonotic disease caused by encysted larvae of the nematode *Taenia solium*. It can have variable clinical presentations, neurocysticercosis being the most common among them. Extraneural cysticercosis is relatively rare. Among them, isolated cysticercosis of the breast is extremely rare and medical literature in its entirety describes but a few cases of isolated cysticercosis of the breast. They can be easily mistaken for a fibroadenoma or breast malignancy. This may lead to an undue psychological burden on patients. Hence, properly diagnosing cysticercosis of the breast is essential in alleviating this burden to some extent. We encountered one such case when a patient presented with multiple painless lumps in the right breast.

**PRESENTATION OF CASE:** A 57-year-old female presented with multiple painless lumps in the right breast. On clinical examination, she was suspected to have numerous small fibroadenomas. She was sent for mammography in which two lesions showed features suggestive of fibroadenoma and the third, of an inflammatory abscess or inflammatory malignancy. She subsequently underwent a core biopsy and the histopathology report revealed that she had cysticercosis of breast.

**DISCUSSION:** Cysticercosis is a parasitic infection caused by the pork tapeworm. This case highlights the rarity and significance of properly diagnosing cysticercosis of breast. Mammography, high-resolution ultrasound or MRI can aid in the diagnosis. Definitive diagnosis is established by histopathological examination.

**CONCLUSION:** Cysticercosis is a major public health problem, especially in the developing world. It must be given due consideration as a possible differential diagnosis in patients presenting with breast lumps in areas of high prevalence.

*Keywords: cysticercosis, breast lump, Taenia solium*

### **1. INTRODUCTION:**

Cysticercosis is a parasitic infection caused by the pork tapeworm, *Taenia solium*. This infection is highly prevalent in sub-Saharan Africa, India, East Asia and South America [1], but can occur in any region where pigs are raised and sanitary conditions are suboptimal.

*Taenia solium* has a complex two-host life cycle. Human beings are the only definitive host and harbour the adult tapeworm, whereas pigs commonly act as intermediate hosts, although other animals can harbour the larval forms.

The most common mode of transmission is due to the ingestion of *Taenia solium* eggs shed in the stool of a human tapeworm carrier [2]. After ingestion, the ova hatch and larvae are distributed via the bloodstream to a variety of tissues. Cysticercosis can have variable clinical presentations, neurocysticercosis being the most common among them. Isolated cysticercosis of the breast is a rare entity. Patients generally present with a painless lump in the breast and on clinical examination, these can be easily mistaken for a fibroadenoma or breast malignancy. This may lead to an undue psychological burden on patients. Hence, properly diagnosing cysticercosis of the breast is essential in alleviating this burden to some extent.

High-resolution ultrasound/MRI can aid in diagnosis. Histopathological examination, however, is the confirmatory tool. On histopathology, three layers of cysticercus can be seen. A corrugated cuticular layer with hair-like protrusions in contact with host tissue, a thin middle layer, and a thick inner layer containing a loosely packed network of small canaliculi with infiltration of lymphocytes, plasma cells, and eosinophils [3].

## **2. PRESENTATION OF CASE:**

A 57-year-old female presented with complaints of multiple lumps in the right breast for 4 months. They were painless in nature and discovered on self-examination. She had no other symptoms and no relevant past medical or family history. The patient was otherwise in good health. On clinical examination, three lumps could be palpated in the right breast, in the upper outer, upper inner and lower central regions. The lesions in the upper inner and upper outer quadrants were approximately half a centimetre in length and width and the lesion in the lower central region was approximately 2 x 1cm. They were well-defined, fixed and tender on deep palpation.

She was sent for mammography, which revealed three isodense nodules in the right breast. On ultrasound correlation, a well-defined hypoechoic lesion was seen between the 6-7 o'clock position, measuring 0.9 x 0.5 cm. Another oval hypoechoic lesion with focal irregular margins and extensive hyperechogenic areas seen within it, seen at the site of palpable abnormality at the 12 o'clock position measuring 1.6 x 0.8 cm. Two of the lesions were suspected to be small fibroadenomas and they were categorised under BIRADS 3. The remaining lesion in the right breast 12 o'clock position was suspected to be an inflammatory abscess or an inflammatory malignancy and categorised under BIRADS 4 (Figure 1).

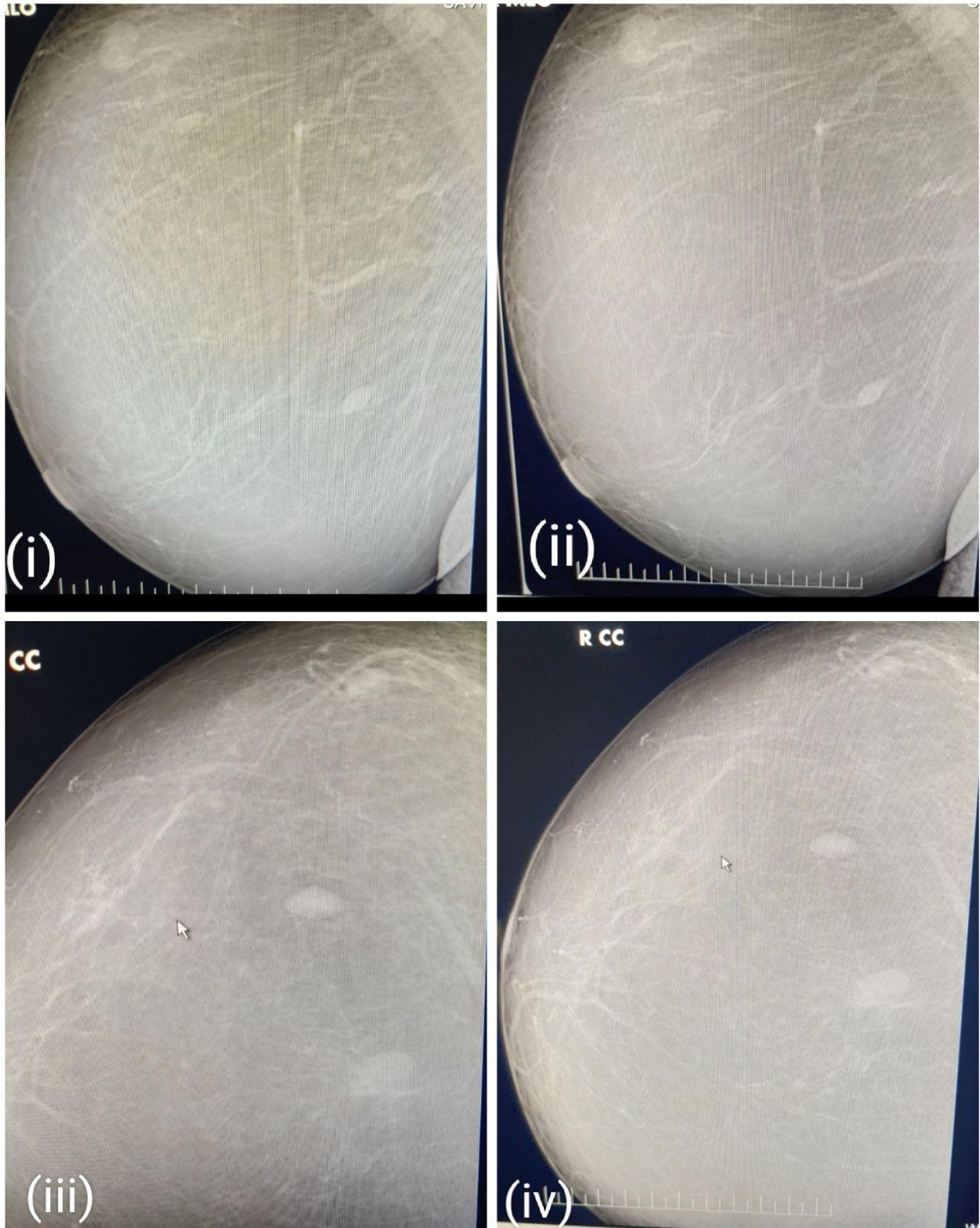


Figure 1: Mammography images of the right breast. (i) and (ii) show mediolateral oblique view(MLO) and (iii) and (iv) show craniocaudal view. Right breast 6-7 o'clock lesion suggestive of fibroadenoma. Another lesion in the upper outer quadrant is suggestive of fibroadenoma. A third lesion in the right breast, 12 o'clock position suggestive of inflammatory abscess or malignancy.

The patient subsequently underwent a core biopsy of the right breast nodules and histopathology showed tissue cores with parasitic wall surrounded by granulomatous response and chronic inflammatory cell infiltration including numerous eosinophils. The parasitic wall was made up of a double-layered eosinophilic membrane and parts of the scolex. The features were suggestive of parasitic infection- cysticercosis of the breast(Figure 2).

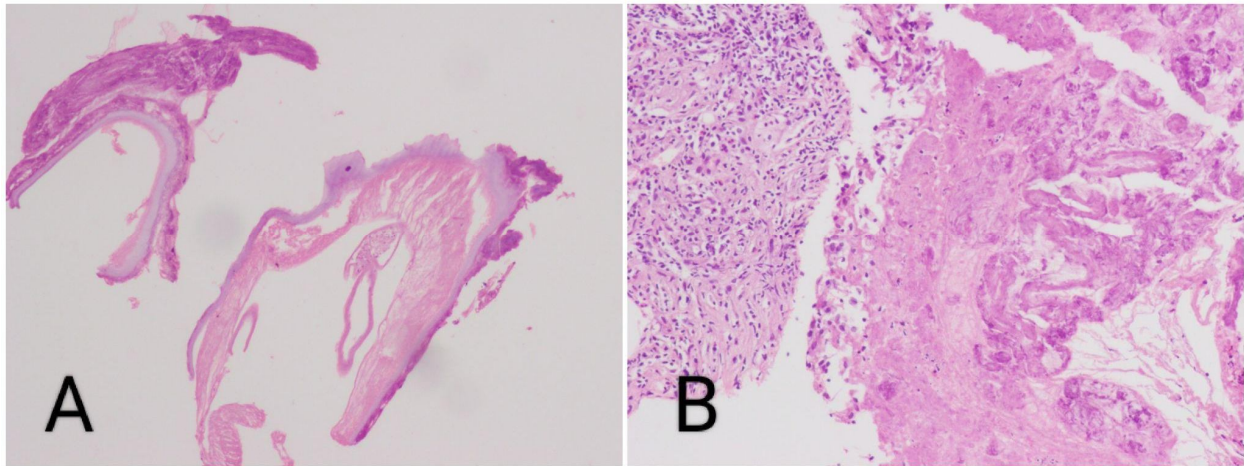


Figure 2: Image A shows the larval form of cysticercosis with invaginating membrane and scolex. Image B shows cysticercus parasite eliciting granulomatous reaction.

We probed into her dietary history and discovered that she was a vegetarian. With regards to her domicile, she resides in a town and has no domestic dwellings in the proximity of her home. There was no history of similar infections in other members of her family.

The patient underwent surgical excision of the breast lesions and the specimen was sent for microscopy. Sections showed breast parenchyma completely effaced by dense lymphoplasmacytic and eosinophilic infiltrate with lymphoid aggregates along with foci of degenerated cysticercus parasite with chitinous wall surrounded by foreign body giant cell reaction and dense eosinophils along with areas of necrosis. The peripherally preserved breast parenchyma was unremarkable.

## DISCUSSION:

Cysticercosis is a parasitic infection caused by the larval form of *Taenia solium*. It is common knowledge that humans acquire the infection by consuming undercooked pork containing cysticerci. The scolex attaches to the small intestine by both sucking disks and two rows of hooklets. The adult worm usually lives for a few years in the upper jejunum. It may have as many as 1000 proglottids, each of which produces thousands of eggs. These proglottids are released and excreted into the faeces, and the eggs in these proglottids are infective for both humans and animals. However, contrary to the popular belief, consumption of undercooked pork is not the most common mode of transmission of cysticercosis. The most common mode of transmission is due to the ingestion of *Taenia solium* eggs shed in the stool of a human tapeworm carrier [2]. After ingestion, the ova hatch and larvae are distributed via the bloodstream to a variety of tissues. Another way the infection can be acquired is by ingestion of produce, such as coriander, spinach etc. which have been irrigated with water contaminated with human faeces, as was suspected to be the case in our patient.

Cysticercosis can have variable clinical presentations, neurocysticercosis being the most common among them. Frequently reported extraneural sites of cysticercosis include skeletal muscle, subcutaneous tissue, breast and eyes [4]. More common among the aforementioned sites are muscle and subcutaneous tissues. Muscle or subcutaneous tissue involvement is more common in patients from Asia and Africa than in Latin America [5]. They usually occur as small asymptomatic nodules which can lead to discomfort when inflamed. These cysts can undergo calcification which gives rise to the characteristic "cigar-shaped calcifications" on radiographs [6].

Isolated cysticercosis of the breast is a relatively rare entity. A study conducted in Nepal which examined cases of cysticercosis in the region over a period of five years reported that among 62 cases of cysticercosis, only 8% occurred in the breast [7]. Another study published by Saigal et al., wherein 156 cases of cysticercosis were examined in Punjab, India occurring over 27 years, reported only 5 cases of cysticercosis of the breast [8].

Patients generally present with a painless lump in the breast and on clinical examination, these can be easily mistaken for a fibroadenoma or breast malignancy. Sending in the patient for mammography is the instinctive next step in establishing a diagnosis. In our patient, mammography showed no distinctive features suggesting cysticercosis, but in a few patients, it can show calcified larvae [9]. High-resolution ultrasound, on the other hand, can be an invaluable tool to diagnose cysticercosis. The distinctive feature of a cysticercus granuloma seen on ultrasound is the presence of an oval or rounded well-defined cystic lesion, with an eccentric echogenic nidus within. Other types of sonographic appearances described are, loculated collection of fluid with internal echoes with a well-defined round cyst within, with an eccentric echogenic protrusion from the wall, representing the scolex; irregular cyst with minimal fluid collection on one side with an extruded scolex in it; elliptical calcified cysticercus cysts [10]. MRI is also helpful in ascertaining the number, location and stages of the parasite. It is seen as a cystic lesion that appears hyperintense on T2W and scolex appears as a tiny hypointense speck within the hyperintense cyst [11]. However, since this infection predominantly occurs in middle to low-income countries, clinicians generally do not order an MRI scan since patients cannot be expected to encumber this financially. Instead, an FNAC or a biopsy seems to be the more prudent next step in the course.

On FNAC, hooklets and scolices in the background of the eosinophilic infiltrate can be seen on microscopy [12]. FNAC, however, is less reliable than biopsy with histopathological examination. On histopathology, three layers of cysticercus can be seen. A corrugated cuticular layer with hair-like protrusions in contact with host tissue, a thin middle layer, and a thick inner layer containing a loosely packed network of small canaliculi with infiltration of lymphocytes, plasma cells, and eosinophils. Multinucleate giant cells and foreign body granulomas are seen in the wall of the cyst [3].

Surgical excision is the treatment of choice in symptomatic patients. Antiparasitic drugs such as albendazole have also proven to be beneficial. Corticosteroids can be employed in patients with intense inflammatory reaction.

The high prevalence of cysticercosis in middle to low-income countries is a direct repercussion of inadequate public health measures. The infection can be prevented by eliminating the conditions necessary to maintain the life cycle of the parasite. Various control initiatives can be employed, first and foremost being improving sanitary measures. Proper disposal of human waste must be ensured. Domestic dwellings must be away from areas where human waste is dumped. Good personal hygiene and hand-washing techniques must be employed. Inspecting pork for cysticerci and adequate cooking of pork viscera must be done. Mass community anthelmintic programs using praziquantel or niclosamide in order to treat tapeworm carriers can also help reduce disease transmission [13].

## 4. Conclusion

Cysticercosis is a major public health problem, especially in the developing world. The most common site for cysticercosis is the central nervous system. Isolated cysticercosis of the breast is exceedingly rare and can be easily mistaken for a fibroadenoma or breast malignancy. Because of this, they must be given due consideration as a possible differential diagnosis in areas of high prevalence of cysticercosis.

Mammography, high-resolution ultrasound or MRI can aid in the diagnosis. Definitive diagnosis is established by histopathological examination.

## Consent

All authors declare that written informed consent was obtained from the patient for publication of this case report and accompanying images. A copy of the written consent is available for review by the Editorial office/Chief Editor/Editorial Board members of this journal.

## Ethical approval

Not applicable

## References

1. Del Brutto OH & Sotelo J. Neurocysticercosis: an update. *Reviews of infectious diseases* 1988, 10(6): 1075–1087. <https://doi.org/10.1093/clinids/10.6.1075>
2. Dixon MA, Winskill P, Harrison WE & Basáñez MG. Taenia solium taeniasis/cysticercosis: From parasite biology and immunology to diagnosis and control. *Advances in parasitology* 2021, 112: 133–217. <https://doi.org/10.1016/bs.apar.2021.03.003>
3. Agnihotri S, Talwar OP, Pudasaini S & Baral R. Cysticercosis of breast--a case report. *Polish journal of pathology : official journal of the Polish Society of Pathologists* 2006, 57(1): 53–54. <https://doi.org/10.3347/kjp.1978.16.2.123>
4. Chi HS & Chi JG. A Histopathological Study On Human Cysticercosis. *Kisaengch'unghak chapchi. The Korean journal of parasitology.* 1978, 16(2): 123–133. <https://doi.org/10.3347/kjp.1978.16.2.123>
5. Hamamoto Filho PT, Singh G, Winkler AS, Carpio A & Fleury A. Could Differences in Infection Pressure Be Involved in Cysticercosis Heterogeneity? *Trends in parasitology*, 2020, 36(10): 826–834.
6. Coyle CM. Neurocysticercosis: An Individualized Approach. *Infectious disease clinics of North America*, 2019, 33(1): 153–168. <https://doi.org/10.1016/j.idc.2018.10.007>
7. Amatya BM & Kimula Y. Cysticercosis in Nepal: a histopathologic study of sixty-two cases. *The American journal of surgical pathology*, 1999, 23(10): 1276–1279. <https://doi.org/10.1097/0000478-199910000-00014>
8. Saigal RK, Sandhu SK, Sidhu PK, Gupta KK. Cysticercosis in Patiala (Punjab). *J Postgrad Med* 1984: 30-46
9. Lucarelli AP, Martins MM, de Oliveira VM, Rinaldi JF, Roveda D, Jr Galvão MA, Aoki T & Piato S. Short report: cysticercosis of the breast, a rare imaging finding. *The American journal of tropical medicine and hygiene*, 2008, 79(6): 864–865

10. Vijayaraghavan SB. Sonographic appearances in cysticercosis. *Journal of ultrasound in medicine : official journal of the American Institute of Ultrasound in Medicine*, 2004, 23(3): 423–427. <https://doi.org/10.7863/jum.2004.23.3.423>
11. Rahalkar MD, Shetty DD, Kelkar AB, Kelkar AA, Kinare AS & Ambardekar ST. The many faces of cysticercosis. *Clinical radiology*, 2000, 55(9): 668–674. <https://doi.org/10.1053/crad.2000.0494>
12. Kala P & Khare P. Fine-needle aspiration cytology as a diagnostic modality for cysticercosis: A clinicocytological study of 137 cases. *Journal of cytology*, 2014, 31(2): 68–72. <https://doi.org/10.4103/0970-9371.138665>
13. Pan American Health Organization. Guideline for Preventive Chemotherapy for the Control of *Taenia solium* Taeniasis, 2021. Accessed on November 09, 2021  
Available: <https://www.paho.org/en/documents/guideline-preventive-chemotherapy-control-taenia-solium-taeniasis>

UNDER PEER REVIEW