

Case study

Trichoscopic aspects of alopecia areata in children: a series of 30 cases.

ABSTRACT

Aims: Alopecia areata is a non-scarring autoimmune disease, quite frequent in the pediatric population. Trichoscopy plays a fundamental role in its diagnosis, prognosis and therapeutic evaluation. Our objective was to describe the trichoscopic signs of alopecia areata in children while showing the most frequent signs in the pediatric population and their correlation with disease activity.

Study design: Retrospective descriptive study.

Place and Duration of Study: Dermatology department of the CHU of Rabat Morocco over a two-year period.

Methodology: We conducted a retrospective descriptive study collecting the cases of **infantile** alopecia areata followed in the dermatology department of the CHU of Rabat Morocco over a two-year period.

Results: A female predominance was noted (63.3%) with a sex ratio of 0.58. Concerning the antecedents, anxiety was at the top of the list with 56.7% of cases. 96.7% of the alopecia areata had been evolving for more than six months, mainly in the form of patchy alopecia 56.7%. In 60% of the this alopecia areata was due to an emotional shock. Concerning trichoscopy the most common sign found in our study was black dots with a percentage of 80%, followed by : yellow dots 67.7% , exclamation point hair 60% , fluffy hair 53.3% , empty follicular openings 50% , tapered hair 40% , white hair 40%, angled hair 36.7% , biphasic hair 26.7 % , pigtailed hair 16,7% . Sign of Pohl Pinkus has not been reported.

Conclusion: Trichoscopy is a major tool in the diagnosis of alopecia areata in the pediatric population but also in the evaluation of the severity of the disease and its prognosis.

Keywords: Alopecia ,areata , children , trichoscopy.

1. INTRODUCTION

Alopecia areata is a multi-component autoimmune disease that causes non-scarring alopecia. It is a chronic and inflammatory disease that evolves by flare-ups, of unpredictable rhythm and severity. It is a frequent reason for consultation in pediatric capillary dermatology [1] . Its clinical diagnosis is easy, based essentially on trichoscopy, but its management remains difficult with a significant impact on the quality of life of children. Through our study, we report on the main trichoscopic signs of alopecia areata in the pediatric Moroccan population.

2. MATERIAL AND METHODS

This is a retrospective descriptive study of a series of 30 cases~~???~~sample size calculation, collecting the cases of infantile alopecia areata followed in the dermatology department of the CHU of Rabat Morocco (consultation and hospitalization). This study is spread over a period of two years and clinical and dermoscopic examination were performed in all our patients.~~?????~~IRB NO. AND APPROVAL

The results were recorded on a paper form and then entered on a computer form and analyzed using the Jamovi software in the epidemiology department of the Faculty of Medicine in Rabat. The objective of this study is to describe the trichoscopic signs of alopecia areata in the pediatric population.

3. RESULTS AND DISCUSSION

We collected 30 cases with a mean age of 11+ 4 years, a female predominance was noted (63.3%) with a sex ratio of 0.58 (M/F: 11/19). Concerning the antecedents, anxiety was at the top of the list with 56.7% of cases, followed by allergic rhinitis 55.2% and thyroid diseases 33.3%. The rest of our patient's medical history is detailed in (Table 1).

In 60% of the children this alopecia areata was due to an emotional shock.

96.7% of the alopecia areata had been evolving for more than six months(chronic??????). A positive traction sign was found in 50% of our patients, with the presence of functional signs in 73.3% of cases: itching was the most frequent sign found in 66.7% followed by tingling in 53.3%, while burning sensations represented only 36.7% of the cases collected.

Patchy alopecia was the most common form 56.7% .

~~A positive traction sign was found in 50% of our patients, with the presence of functional signs in 73.3% of cases: itching was the most frequent sign found in 66.7%~~ followed by tingling in 53.3%, while burning sensations represented only 36.7% of the cases collected.

Concerning trichoscopy the most common sign found in our study was black dots (Fig.1a) with a percentage of 80%, followed by : yellow dots (Fig.1b) 67.7% , exclamation point hair (Fig.1c) 60% , fluffy hair 53.3% , empty follicular openings (Fig.2a) 50% , tapered hair 40%, white hair (Fig.2b) 40%, angled hair 36.7% , biphasic hair (Fig.2c) 26.7 % (8) , pigtailed hair (Fig.3) 16,7% . Sign of Pohl Pincus has not been reported.

Table 2 summarizes the trichoscopic signs found in our study.

Table 1. Patient's medical history

Medical history	n=30 (%)
Anxiety	17 (56,7%)
Allergic rhinitis	16 (55,2%)
Thyroid diseases	10 (33.3 %)
Anemia	5 (16,7%)
Depression	4 (13.3 %)
Atopic dermatitis	4 (13,3 %)
Trisomy 21	2 (6,7%)
Asthma	2 (6,7%)
Urticaria	1 (3,3%)
Public road traffic accident	1 (3,3 %)

Table 2 .Trichoscopic signs in our cases

Trichoscopic sign	n= 30 (%)
-------------------	-----------

Black heads	24 (80%)
Yellow dots	20 (67,7%)
Exclamation point	18 (60 %)
Fluffy hair	16 (53,3%)
Empty follicular openings	15 (50%)
Tapered hair	12 (40%)
White hair	12 (40%)
Angled hair	11 (36,7%)
Biphasic hair	08 (26,7%)
Pigtailed hair	05 (16,7 %)

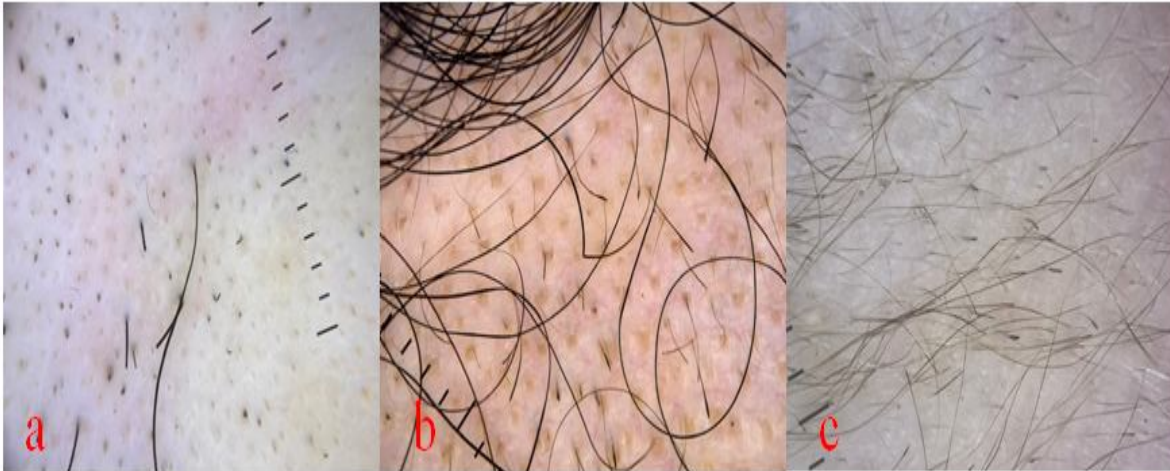


Fig. 1 .Trichoscopic images showing : Black dots on (a) , yellow dots (b) and exclamation point hair (c).

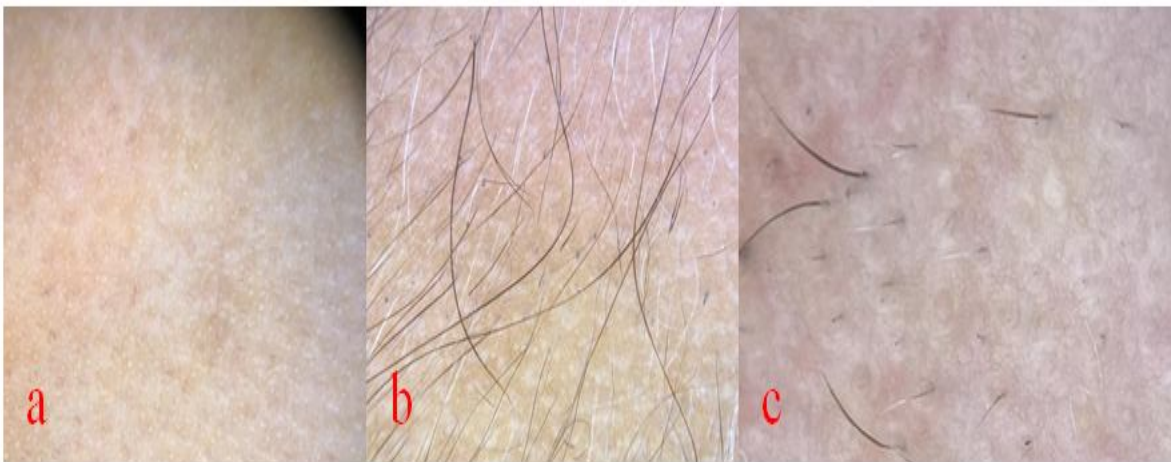


Fig.2 .Trichoscopic images showing : Empty follicular openings on (a) , white hair (b) and biphasic hair (c).

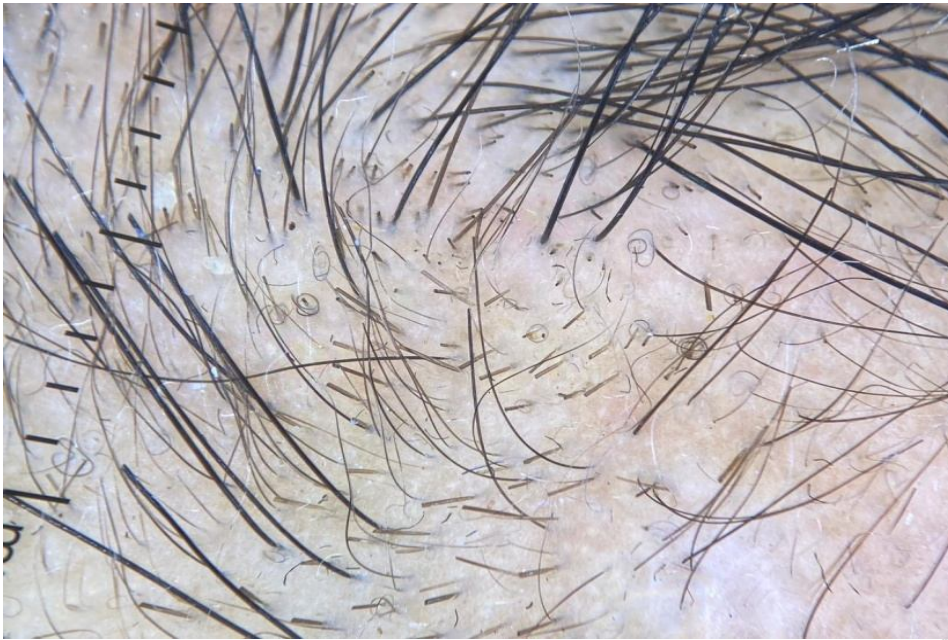

Fig.3 .Pig-tail appearance on trichoscopy.

4. DISCUSSION

Alopecia areata is a chronic, inflammatory and autoimmune disease that affects the hair follicle. It can be manifested by a single or multiple plaque. Trichoscopy plays an important role in the diagnosis but also in clinical monitoring. The trichoscopic signs most often found in alopecia areata are :

Blackheads that represent broken or destroyed pigmented hairs at the level of the scalp. Blackheads predominate in areas of acute alopecia with active hair loss, and are therefore a marker of severity [2]. In our study, black dots were the most frequently encountered trichoscopic sign

Yellow dots correspond to hair follicles filled with keratotic material and/or sebum. Some authors suggest that yellow dots are less present in children because the sebaceous glands are less functional before puberty [3] . It should also be noted that the color of these yellow dots is different compared to adults, they tend to have an egg yolk color in children, this is related to the difference in the composition of sebum that varies with age. This trichoscopic sign testifies to an old inactive alopecia areata, but also their presence in great number is correlated with the severity of the disease.

Exclamation point or tapered hairs are dystrophic hairs produced by hair follicles less severely affected by alopecia areata . Their proximal end is fine in contrast to their distal end which is swollen. Exclamation point hairs are more common in acute and progressive forms of alopecia areata, but they are also present in non-progressive and stable forms of the disease [4].

The empty follicular openings are a very sensitive and characteristic sign of alopecia areata in children, this is explained by the fact that in children, these follicular openings are not filled with sebum and/or keratin unlike adults. In our case series, half of our patients had this trichoscopic sign.

Coiled or pigtailed hair indicates hair regrowth either spontaneously or after successful treatment [5] . This dermoscopic sign is more frequently found in children than in adults. Pigtail hair is also seen in tinea but is thinner in alopecia areata.

Tapered hairs are hairs that can also be seen with the naked eye, they are larger than the exclamation point hairs. They correspond to less inflammatory damage but more durable. It is a non-stop decrease in mitotic activity. Some authors consider them as exclamation marks [6]. They constitute a trichoscopic sign pathognomonic of alopecia areata .

Broken or kinked hair is secondary to rapid regrowth or inflammatory phenomena; it indicates a good response to treatment [7] .

Broken dystrophic hair is evidence of mitotic activity in the anagen follicles [8] and indicates active alopecia areata.

During alopecia areata, the inflammatory process attacks the melanin; the hair becomes white to protect itself from this process. In many of the cases described, the hair grows back initially as fine hypopigmented hairs and it will take a few weeks for the hair to gradually regain its standard thickness and color ; which may explain the appearance of biphasic hair during this evolution. All this suggests that the mechanism of melanogenesis is involved in the etiopathogeny of alopecia areata[9].

Pohl-Pinkus hair is not a common trichoscopic feature of alopecia areata. They are constrictions that occur due to the rapid and repeated suppression of the mitotic and metabolic activity of the hair follicles. They represent a repetition of the inflammatory process over a short period of time .The sign of Pohl Pinkus was not noted in our study.

5. CONCLUSION

Trichoscopy in childhood alopecia areata is an essential tool not only for diagnosis but also for follow-up and monitoring of the response to the various treatments offered.????????????????

6. CONSENT AND ETHICAL APPROVAL

The cases' parents or legal guardians provided informed consent.

8. REFERENCES

1. Mazereeuw- Hautier J, Maza-Rioland A, Royer M. Pelade de l'enfant. *Annales de dermatologie et de vénéréologie* 2012. 139, 151-155.
2. Inui S, Nakajima T, Nakagawa K, Itami S. Clinical significance of dermoscopy in alopecia areata: analysis of 300 cases. *Int J Dermatol*. Juill 2008;47(7):688-93.
3. Waskiel- Bumatek A, Rakowska A, Sikora M, Olszewska M, Rudnicka L. Trichoscopy of alopecia areata in children . A retrospective comparative analysis of 50 children and 50 adults. *Pediatric Dermatology* .Wiley 2019. DOI: 10.1111/pde.13912.
4. Atis G, Altan Ferhatoglu Z. Trichoscopic clues for the diagnosis of alopecia areata. *Turk J Dermatol Venereology* 2020 ;54 :76-8.
5. Lacarrubba F, Dall'Oglio F, Rita Nasca M, Micali G. Videodermoscopy enhances diagnostic capability in some forms of hair loss. *Am J Clin Dermatol*. 2004;5:205-208.
6. Kibar M, Aktan Ş, Lebe B, Bilgin M: Trichoscopic findings in alopecia areata and their relation to disease activity, severity and clinical subtype in Turkish patients. *Australas J Dermatol* 2015;56:1-6.
7. Waskiel A, Rakowska A, Sikora M, Olszewska M, Rudnicka L: Trichoscopy of alopecia areata: An update. *J Dermatol* 2018;45:692-700.
8. Strazzulla LC, Wang EHC, Avila L, et al: Alopecia areata: Disease characteristics, clinical evaluation, and new perspective on pathogenesis. *J Am Acad Dermatol* 2018;78:1-12.
9. Ask-Sigall D, Ortega-Springall M.F, Smith-Pliego M, Rodriguez-Lobato E, Martinez-Velasco M.A, Arenas R, et al . White hair in alopecia areata : Clinical forms and proposed physiopathological mechanisms. *Journal of the American Academy of Dermatology*(2019). doi: <https://doi.org/10.1016/j.jaad.2018.12.047>.