

# The Role of Exercise Testing in Wolff-Parkinson-White Syndrome: About Two Cases

---

## ABSTRACT

Exercise testing (ET) is a noninvasive test used both in the diagnosis of myocardial ischemia and in the risk stratification of sudden death in Wolff-Parkinson-white syndrome (WPW). However, in the latter, there are often false-positive results through ST-segment depression even though the coronaries are healthy. This has largely limited the interpretation of the clinical and electrical features suggestive of myocardial ischemia during ET in patients with WPW syndrome. The purpose of this study is to present two cases of myocardial ischemia revealed by ET in patients with WPW syndrome.

*Keywords: Wolff-Parkinson-White syndrome; exercise testing; myocardial ischemia; sudden death.*

## 1. INTRODUCTION

ET is a non-invasive test used in many circumstances such as diagnosis of coronary artery disease or sudden cardiac death risk stratification in WPW syndrome. However, it is not recommended to be performed for both indications at the same time because patients with an accessory pathway have ST depressions that are considered false-positive [1,2]. In this study, we report two cases of myocardial ischemia revealed by ET in patients with WPW syndrome.

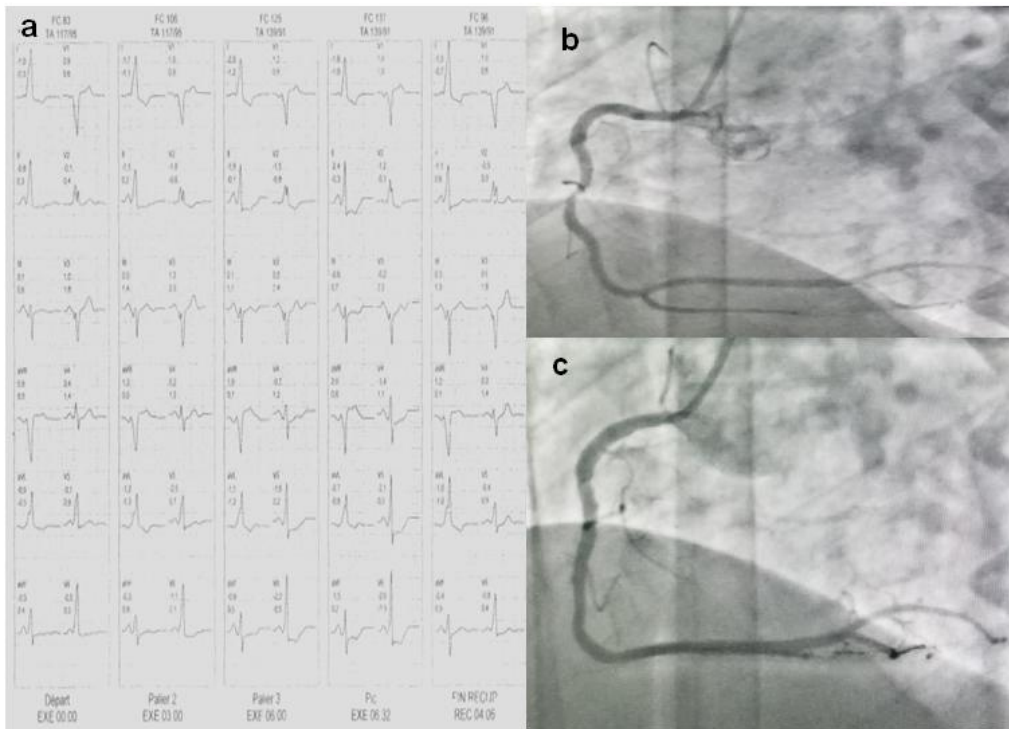
## 2. CASES REPORTS

### 2.1 Case 1

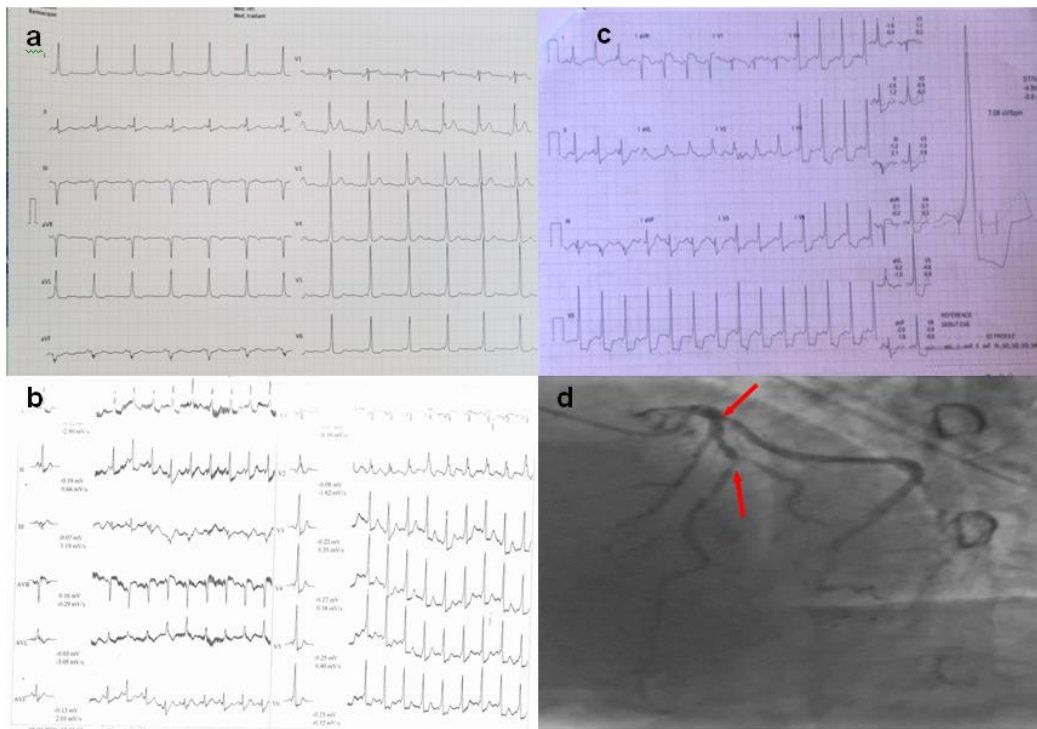
A 40-year-old male patient with no modifiable cardiovascular risk factors or other medical history consulted for atypical chest pain that had been persisting for four months. Physical examination was normal, with a Glasgow score (GSC) of 15/15, blood pressure (BP) of 135/72

mmHg, heart rate (HR) of 75bpm, and oxygen saturation (SpO<sub>2</sub>) of 98%. The resting ECG showed a rhythm compatible with pre-excitation with a delta wave, a QRS complex and a PR interval of 130ms and 60ms respectively (Fig. 1.a). Trans-thoracic echocardiography (TEE) found no congenital abnormalities or hypertrophic cardiomyopathy. The ET conducted according to the Bruce protocol found at level 3, a ST depression in leads V<sub>4</sub>, V<sub>5</sub>, V<sub>6</sub> with a maximum of 2.9 mm in lead V<sub>6</sub> (Fig. 1.a). At the same time the presence of an intense constrictive retrosternal pain, radiating to both shoulders, obliged the patient to stop the test and to administer sublingual trinitrine which calmed the pain. There was no suppression of the delta wave during the ET. A coronary angiography revealed severe occlusion of right coronary artery which underwent revascularization (Fig. 1.b and .c). Basic treatment of ischaemic cardiopathy was started and electrophysiological exploration was scheduled to stratify the risk of sudden death and possibly proceed to an ablation of the accessory pathway.

---



**Fig. 1. a: resting ecg; b: exercise testing ecg at level 4, c: right coronary stenosis on coronary angiogram; d: right coronary artery after revascularization**



**Fig. 2. a: resting ecg; b: first exercise testing ecg at level 4; c: second exercise testing at level 4; d: coronary angiogram with circumflex and left anterior descending arteries stenosis**

## 2.2 Case 2

A 60-year-old male patient with no modifiable cardiovascular risk factors consulted for atypical chest pain. He had a known accessory pathway and had undergone an ET which did not show any suppression of the delta wave with the presence of an ST depression from leads V2 to V6, reaching 3 mm in lead V4 (Fig. 2.b). His atypical chest pain had been prevailing for 1 month. Physical examination revealed: (GSC): 15/15, BP: 125/72mmHg, HR: 77 bpm, SpO2: 99%. The resting ECG showed a rhythm compatible with pre-excitation with a delta wave, a QRS complex and a PR interval of 120ms and 80ms respectively (Fig. 2.a). The trans-thoracic echocardiography did not find congenital anomalies or HCM. A new ET conducted using Bruce's protocol found at the peak of the exercise, a ST segment depression from leads V1 to V6 with a maximum of 6.7 mm at lead V5, as well as a ST segment elevation in AVR of 2.9 mm (Fig. 2.c). It should be noted that there was no suppression of the delta wave during the ET. Considering the elevated ST-segment and the increase in precordial ST-segment depression compared with the previous ET. A coronary angiography was requested. It revealed severe atheromatous lesions of the left anterior descending artery, and the circumflex artery (Fig.

2.d). The patient underwent coronary artery bypass graft with no postoperative complications. An electrophysiological exploration was scheduled to stratify the risk of sudden death and possibly proceed to an ablation of the accessory pathway.

## 3. RESULTS AND DISCUSSION

WPW syndrome is a congenital anomaly characterized by the presence of an accessory pathway connecting the atria to the ventricles that can cause reentrant tachycardia or ventricular fibrillation [3]. Its overall prevalence is 0.36/1000 with a peak of 0.61/1000 in people aged 20-24 years and a male predominance. The death and sudden death risks were 0.071% and 0.02% per patient-year, respectively. Other congenital pathologies are often associated with a frequency of 2.6% with a predominance of Epstein's disease [4]. The clinical symptomatology ranges from palpitations to sudden death, vertigo and chest pain [5]. The latter was the main symptom in our two patients, but was not attributed to coronary ischemia because both patients had no modifiable cardiovascular risk factors. The diagnosis on resting ECG was based on a short PR interval, delta wave, and QRS widening. The existence of a pre-excitation syndrome in a patient requires a

risk stratification of sudden death by an ET that has a positive predictive value of benignity of the accessory pathway at 100% in case of sudden disappearance of the delta wave during the test [6]. With this in mind, ET was requested in our two patients.

During the ET, ST depression, suggestive of myocardial ischemia, may occur. It usually regresses as soon as the delta wave disappears. This ST depression is considered as false positive because of the depolarization disorders induced by the existence of the accessory pathway [7]. Nevertheless, in case n°2, the elevation of the ST segment during the second ET in AVR, the male gender and the chest pain were arguments that pushed us to perform a coronary angiography. As for case 1, it is clear that he is a CAD patient with the occurrence of typical pain on exertion even though the ST elevation is not interpretable. It appears that, even in the patient with WPW syndrome, ET can be an argument to affirm the existence of coronary ischemia, as reported in the literature [8,9]. Thus, it is possible to rely on clinical and blood pressure criteria as well as a critical analysis of the ST segment, obviously taking into consideration the cardiovascular risk factors of the patient. ET is also a cost saving strategy because in front of sudden disappearance of delta wave, clinician doesn't need electrophysiology to affirm the benignity of the accessory pathway [10]. Remember that we indicated ET to assess the risk of sudden death. Since the delta wave has not disappeared during ET, the electrophysiological testing (EPT) will therefore be necessary to judge whether or not the accessory pathway is malignant. When the refractory period is less than 250 ms, ablation must be performed. Radiofrequency ablation is the best treatment even for septal locations that are said to be at risk [11]. Papone and al followed 212 asymptomatic patients with baseline EPT for 37.7 months. Among them, 15% became symptomatic. In the non-inducible, only 3.4% became symptomatic, while in the inducible more than 50% became symptomatic, including two sudden deaths. What makes EPT a reliable means of evaluation after ET [12].

#### 4. CONCLUSION

The concept of false positive in the detection of Coronary artery ischemia through ET in WPW syndrome is based solely on ST segment analysis. However, this should not absolutely contraindicate this test because the other clinical and blood pressure parameters are interpretable.

#### CONSENT

As per international standard or university standard, patient (s) written consent has been collected and preserved by the author (s)

#### ETHICAL APPROVAL

As per international standard or university standard, written ethical approval has been collected and preserved by the author(s).

#### COMPETING INTERESTS

Authors have declared that no competing interests exist.

#### REFERENCES

1. Knuuti J, Wijns W, Saraste A, Capodanno D, Barbato E, Funck-Brentano C, et al. 2019 ESC Guidelines for the diagnosis and management of chronic coronary syndromes. *Eur Heart J*. 2020;41(3):407–477.
2. Moltedo JM, Iyer RV, Forman H, Fahey J, Rosenthal G, Snyder CS. Is exercise stress testing a cost-saving strategy for risk assessment of pediatric wolff-Parkinson-white syndrome patients? *Ochsner J*. 2006;6(2):64–67.
3. Sapra A, Albers J, Bhandari P, Davis D, Ranjit E. Wolff-Parkinson-White Syndrome: A Master of Disguise. *Cureus*. 2020;12(6):e8672-e8673.
4. Lu C-W, Wu M-H, Chen H-C, Kao F-Y, Huang S-K. Epidemiological profile of Wolff-Parkinson-White syndrome in a general population younger than 50 years of age in an era of radiofrequency catheter ablation. *Int J Cardiol*. 2014;174(3):530–534.
5. Cain N, Irving C, Webber S, Beerman L, Arora G. Natural history of Wolff-Parkinson-White syndrome diagnosed in childhood. *Am J Cardiol*. 2013;112(7):961–965.
6. Benson DW, Cohen MI. Wolff-Parkinson-White syndrome: lessons learnt and lessons remaining. *Cardiol Young*. 2017;27(S1):S62–S67.
7. Mohan S, Balaji S. Management of asymptomatic ventricular preexcitation. *Indian Pacing Electrophysiol J*. 2019; 19(6):232–239.
8. Jezior M, Kent S, Atwood J. Exercise Testing in Wolff-Parkinson-White Syndrome \*: Case Report With ECG and

- Literature Review. *Chest*. 2005;127:1454–7.
9. Kanwal A, Bustin KM, Delasobera BE, Shah AB. Ischaemia during exercise stress testing in an athlete with Wolff-Parkinson-White pattern. *BMJ Case Rep CP*. 2020;13(4):e235055.
  10. Vijay Y, Sanjeev T, Ratna Mani G, Chandra Mani P, Bhawani M, Manju S, et al. A Wolff-Parkinson-White (WPW) Electrocardiographic Pattern in Asymptomatic Patient – State-of-the-Art-Review. *J Cardiol Cardiovasc Med*. 2022;7(2):045–052.
  11. Gatzoulis K, Apostolopoulos T, Costeas X, Sotiropoulos H, Papafanis F, Stefanadis C, Toutouzas P. Paraseptal accessory connections in the proximity of the atrioventricular node and the His bundle. Additional observations in relation to the ablation technique in a high risk area. *Europace*. 2004 ;6(1):1-9.  
DOI: 10.1016/j.eupc.2003.10.001
  12. Pappone C, Santinelli V, Rosanio S, Vicedomini G, Nardi S, Pappone A, Tortorello V, Manguso F, Mazzone P, Gulletta S, Oreto G, Alfieri O. Usefulness of invasive electrophysiologic testing to stratify the risk of arrhythmic events in asymptomatic patients with Wolff-Parkinson-White pattern: results from a large prospective long-term follow-up study. *J Am Coll Cardiol*. 2003;41(2):239-44.

---

© 2023 Hassan et al.; This is an Open Access article distributed under the terms of the Creative Commons Attribution License (<http://creativecommons.org/licenses/by/4.0>), which permits unrestricted use, distribution, and reproduction in any medium, provided the original work is properly cited.