

# Case study

## Ophthalmoplegia revealing an orbital metastasis secondary to breast cancer : case report

---

### ABSTRACT

Orbital metastases are uncommon and breast cancer is the most common primary in women. The clinical presentation varies depending on the location of the metastasis in the orbit. The diagnosis of metastasis is evoked in the context of the patient's background, particularly if there is a known history of cancer, and on the appearance of the lesion on imaging. We report the case of a patient presenting ophthalmoplegia of the left eye revealing orbital metastases of breast cancer.

*Keywords: Orbital metastases, breast cancer, ophthalmoplegia*

### 1. INTRODUCTION

Orbital metastases are rare. A history of cancer is found on questioning in 80% of patients, and the primary cancer is most often of breast, lung and prostate origin [1]. In most cases, the initial sign is a unilateral exophthalmos, sometimes associated with a decrease in visual acuity. We report the case of a patient presenting ophthalmoplegia of the left eye revealing orbital metastases of breast cancer

### 2. CASE PRESENTATION

We report the case of a 55 year old patient with no pathological history. She was consulted to the emergency department for diplopia. The best-corrected visual acuity was 10/10 in both eyes, the examination of the ocular motility objective ophthalmoplegia of the left eye. Slit lamp examination and the fundus of the both eyes were normal. A cerebral CT scan showed a hypodense lesion infiltrating the left orbit in favor of an orbital metastasis (Figure 1) with secondary sphenoidal localization with a lytic lesion of 33 mm invading the left cavernous groove and multiple nodular lesion cerebral(Figure 2). Ophthalmoplegia of the left eye is secondary to invasion of the cavernous cavity. A workup was performed in search of a primary tumor including a breast ultrasound which found a nodule of the breast with a malignant aspect and vascularized on echodoppler (Figure 3). A CT scan of the body did not find any other secondary location. A breast biopsy was performed which revealed a breast adenocarcinoma. The patient was referred for chemotherapy and localized radiotherapy. An occlusion of one eye was recommended to suppress the diplopia. After 3 months the evolution was marked by the regression of the diplopia.

### 3. DISCUSSION

Orbital metastases represent only 1-13% of the processes occupying the orbital space [1]. In a series of 1264 patients with orbital processes referred to an ocular oncology center, 7% were found to be orbital metastases [1]. The incidence of orbital metastases seems to be increasing due to the new anti-cancer therapies allowing a better survival of the patients, and perhaps also due to the increase in the incidence of certain cancers. The most common primary cancers involved in orbital metastases are adenocarcinomas, including breast cancer (40% of cases), lung cancer (11% of cases), and prostate cancer (8% of cases) [2]. Cutaneous melanoma is a common cause of orbital metastasis in the Australian population [2]. In some cases, the primary is not found during the initial workup. The average age of patients at diagnosis is 60 years. Orbital metastases are characterized by their rapid progression over an average of 2 months. The tumor can

be single or multiple, unilateral but rarely bilateral. One of the preferential locations is the oculomotor muscles because they are hypervascularized; a second site is the bone marrow of the sphenoid bone with lysis of the lateral wall. Finally, it can be intra- or extraconical. The most frequent ophthalmological signs are exophthalmos (63% of cases), strabismus (62% of cases), diplopia (48% of cases) and decreased visual acuity in one third of patients [3]. Enophthalmos as a sign of orbital metastasis is rare and is mainly found in retractile metastases of breast or gastric cancer, and is the consequence of muscle fibrosis associated with adjacent fatty atrophy [4]. Orbital pain is possible, especially in cases of bone invasion. Orbital metastases of breast cancer most often develop at the expense of orbital muscle and fat [5], unlike metastases of prostate cancer which are mainly bony. In 85% of cases there is a known history of breast cancer, with an average delay of 4.5 to 6.5 years between the diagnosis of the primary and the orbital metastasis [5]. For the remaining 15%, the metastasis is then revealing of the cancer. Since in most cases there are also concomitant non-orbital metastases, it is essential to perform an extension workup to look for them [6]. On imaging, there is often osteolysis with bone destruction and sometimes osteocondensation. On CT, the mass is highly contrasted and more or less limited, sometimes with intratumoral calcifications. On MRI, it often shows a T1 isosignal and a strong T2 hypersignal, and takes up gadolinium strongly. The prognosis for orbital metastases of breast cancer is generally poor, with a mean survival of 31 to 116 months [6]. Histological evidence of orbital metastasis is necessary before starting chemotherapy or radiotherapy, and hormone receptor positivity on immunohistochemistry is necessary to indicate hormone therapy. These data can be obtained by analysis of a cytopunction [7] or a biopsy of the lesion. Cytopuncture can be performed in cases where there is a known history of cancer and if the lesion is located anteriorly in the orbit [7], and only if positive can the diagnosis of orbital metastasis be made. There is a case report of orbital filariasis in a patient previously treated for breast cancer, and in this case the biopsy of the lesion allowed the initial diagnosis of orbital metastasis to be eliminated [8]. Surgical removal of an orbital metastasis is not indicated, as this would be a surgical procedure with significant morbidity and no proven benefit on patient survival. The main ophthalmological objectives of treatment with hormonal therapy, chemotherapy or radiotherapy are to maintain useful vision and to control pain [9;10]. Orbital radiotherapy with a total dose of 30 to 40 Gy leads to an improvement of symptoms in 80% of cases [11].

#### 4. CONCLUSION

Orbital metastases are uncommon and breast cancer is the most common primary in women. The clinical presentation varies depending on the location of the metastasis in the orbit. The diagnosis of metastasis is evoked in the context of the patient's background, particularly if there is a known history of cancer, and on the appearance of the lesion on imaging. The diagnosis of certainty is based on the anatomopathological analysis of the lesion. As with many cancers at the metastatic stage, the prognosis is generally poor.

#### 5. Figures

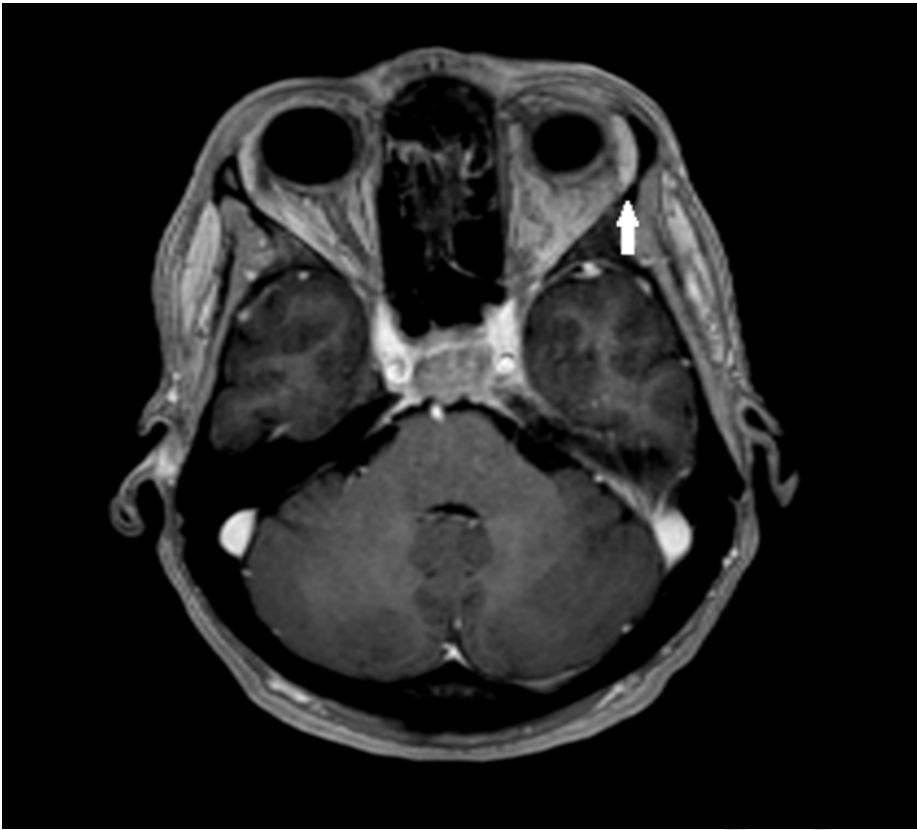

Figure 1: A cerebral CT scan showed a hypodense lesion infiltrating the left orbit in favor of an orbital metastasis (arrow).

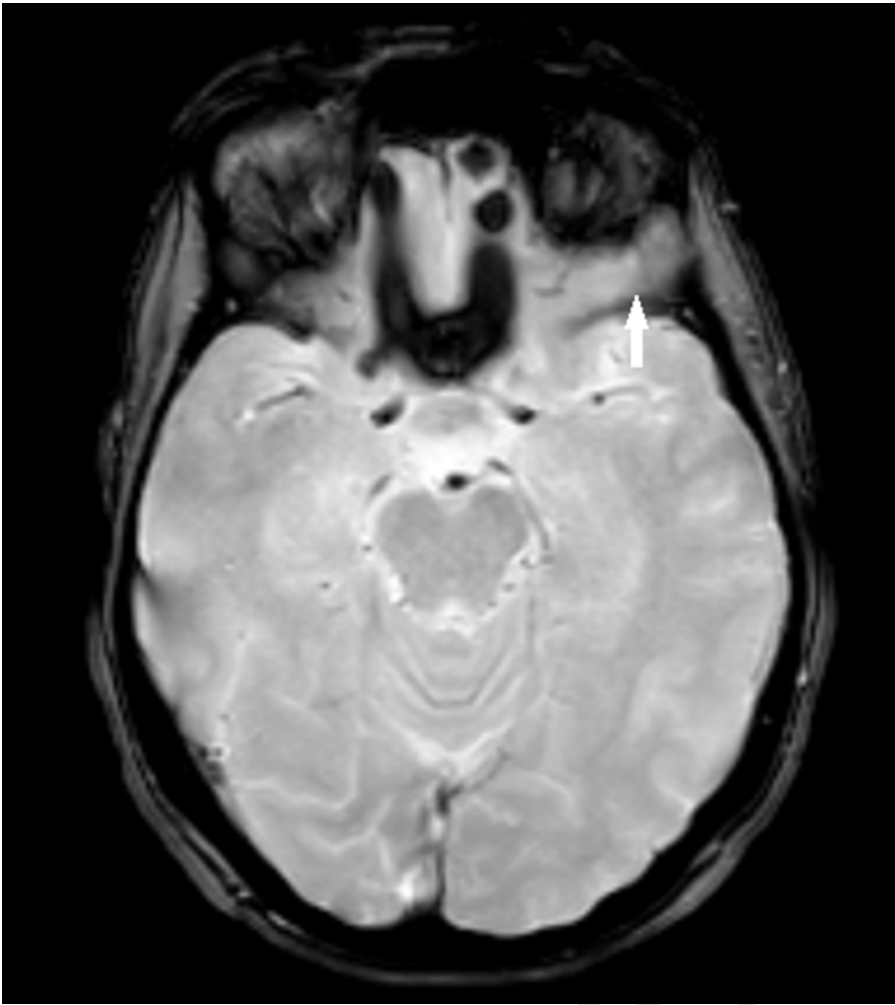


Figure 2 : A cerebral CT scan show a hypodense lesion infiltrating the left and sphenoidal localization with a lytic lesion invading the left cavernous groove (arrow) .

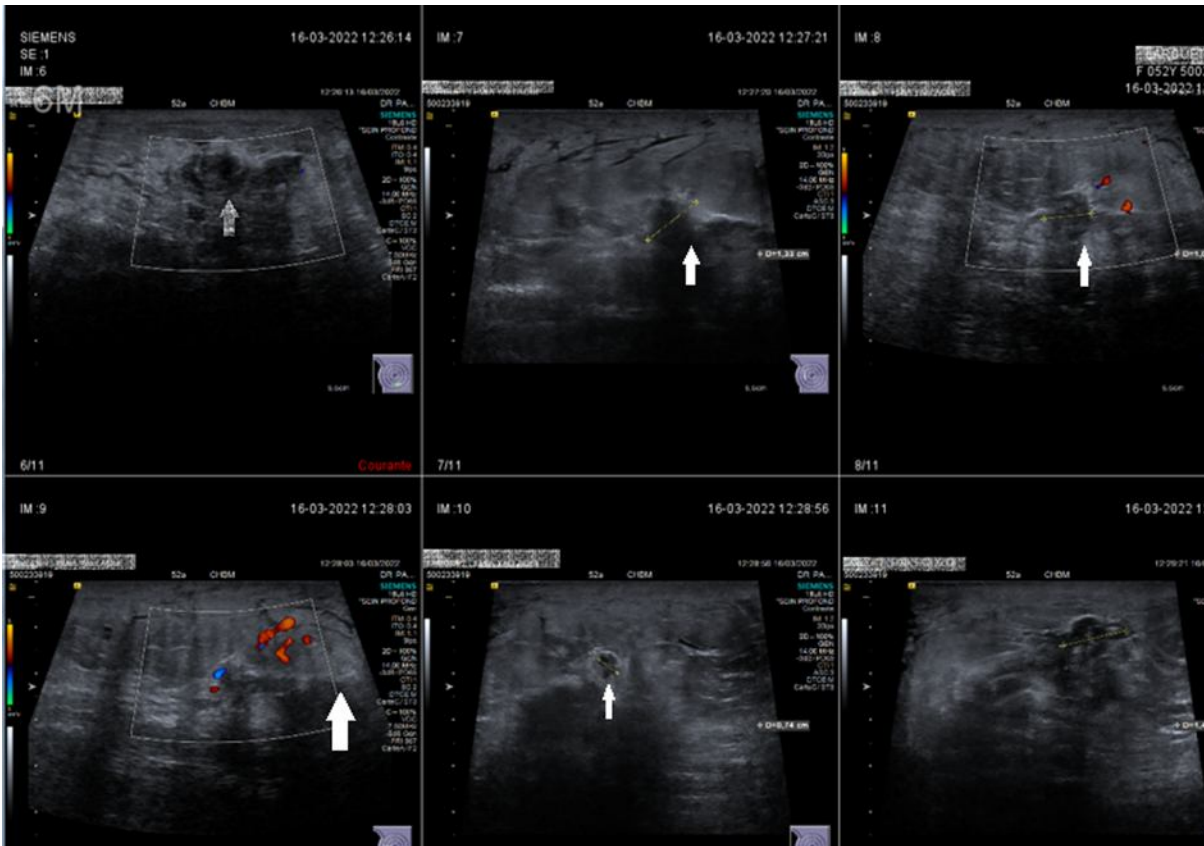


Figure 3 : A breast ultrasound found a nodule of the breast with a malignant aspect and vascularized on echodoppler (arrow) .

## CONSENT

The patient has given their informed consent for the case study to be published.

## Ethical Approval:

As per international standard or university standard written ethical approval has been collected and preserved by the author(s).

## REFERENCES

- [1] VLACHOSTERGIOS PJ, VOUTSADAKIS IA, PAPANDREOU CN. ORBITAL METASTASIS OF BREAST CARCINOMA. BREAST CANCER (DOVE MEDPRESS) 2009;3:91—7.
- [2] FRANCONI E, MURELLI F, PAROLDI A, MARGARINO C, FRIEDMAN D. ORBITAL SWELLING AS A FIRST SYMPTOM IN BREAST CARCINOMA DIAGNOSIS: A CASE REPORT. J MED CASE REP 2010;4:211.
- [3] ECKARDT AM, RANA M, ESSIG H, GELLRICH N-C. ORBITAL METASTASES AS FIRST SIGN OF METASTATIC SPREAD IN BREAST CANCER: CASE REPORT AND REVIEW OF THE LITERATURE. HEAD NECK ONCOL 2011;3:37.
- [4] AMICHETTI M, CAFFO O, MINATEL E, RONCADIN M, VALLI MC, LOZZA L, ET AL. OCULAR METASTASES FROM BREAST CARCINOMA: A MULTICENTRIC RETROSPECTIVE STUDY. ONCOL REP 2000;7:761—5.
- [5] SHIELDS JA, SHIELDS CL, SCARTOZZI R. SURVEY OF 1264 PATIENTS WITH ORBITAL TUMORS AND SIMULATING LESIONS: THE 2002 MONTGOMERY LECTURE, PART 1. OPHTHALMOLOGY 2004;111:997—1008.
- [6] CIVIT T, COLNAT-COULBOIS S, FREPPEL S. ORBITAL METASTASIS. NEUROCHIRURGIE 2010;56:148—51.
- [7] CORNELIS F, MEJDOUBI M, DOUSSET V. BILATERAL ORBITAL EXTENSION OF BREAST CANCER METASTASIS. J RADIOL 2007;88:684—6.
- [8] GARRITY JA, HENDERSON JW. METASTATIC CARCINOMAS. IN: MAYO FOUNDATION FOR MEDICAL EDUCATION AND RESEARCH, EDITOR. HENDERSON'S ORBITAL TUMORS. 4TH ED. PHILADELPHIA: LIPPINCOTT WILLIAMS & WILKINS; 2007. P. 313—26.
- [9] VALENZUELA AA, ARCHIBALD CW, FLEMING B, ONG L, O'DONNELL B, CROMPTON JJ, ET AL. ORBITAL METASTASIS: CLINICAL FEATURES, MANAGEMENT AND OUTCOME. ORBIT 2009;28:153—9.
- [10] KARTI, O., OZDEMIR, O., TOP KARTI, D., ZENGIN, M. O., TATLI, S., KUSBECI, T., & CELEBISOY, N. (2021). ORBITAL METASTASIS SECONDARY TO BREAST CANCER: A RARE CAUSE OF UNILATERAL EXTERNAL OPHTHALMOPLEGIA. NEURO-OPHTHALMOLOGY, 45(3), 181-183. [HTTPS://WWW.NCBI.NLM.NIH.GOV/PMC/ARTICLES/PMC8210869/](https://www.ncbi.nlm.nih.gov/pmc/articles/PMC8210869/)
- [11] SAAD, E. S. P., BAKRI, H. M., RAYAN, A., BARAKAT, D., & KHALEL, M. M. (2022). EYE METASTASIS IN BREAST CANCER: CASE REPORT AND REVIEW OF LITERATURE. ECANCER MEDICAL SCIENCE, 16. [HTTPS://WWW.NCBI.NLM.NIH.GOV/PMC/ARTICLES/PMC9023307/](https://www.ncbi.nlm.nih.gov/pmc/articles/PMC9023307/)