

## Review Article

# Cases of orbital cellulitis revealing neglected intraocular foreign bodies

### Abstract

**Background:** Orbital cellulitis is defined as acute inflammatory orbital swelling of infectious origin. Most often secondary to sinusitis. Intraocular foreign bodies neglected because of their small size, or sometimes radio-transparent nature, can be difficult to diagnose even with radiology and be responsible for orbital cellulitis. We demonstrate the diagnostic and therapeutic difficulties.

**Patients and methods:** This is a retrospective descriptive study of patients with unilateral orbital cellulitis revealing neglected intraocular foreign bodies, conducted in the Department of Adult Ophthalmology, Hospital August 20, 1953, involving 58 patients, from January 2015 until December 2020.

**Results:** The average age of the patients was 38.5 years. The most affected age group was between 21 and 30 years with a clear male predominance. A decrease in visual acuity was found in all patients (unilateral blindness 43%) and a cellulitis complicated by a purulent melt (43%). All patients received medical treatment, including intravitreal injections of antibiotics in 71% of cases, and surgical treatment consisting of extraction of the foreign body and immediate evisceration of the eyeball in 25% of cases.

**Conclusion:** Orbital cellulitis, although mostly secondary to sinusitis, can reveal various etiologies such as intra-orbital foreign bodies that can go unnoticed and be life-threatening and functionally damaging, especially when the diagnosis is made late and management is

inappropriate. The presence of an intraocular foreign body must be suspected in all cases of orbital trauma associated with a palpebral wound, even if it is minimal, or in the presence of a clinical aggravation. Any delay in diagnosis and/or treatment can lead to serious complications that can affect the functional and even vital prognosis. The surgical treatment consists of the extraction of the foreign body. The recourse to evisceration in our context unfortunately continues to persist at high rates; because of the delay of consultation and thus of the management.

**Keywords :** Neglected Intraocular foreign bodies, Orbital cellulitis, Orbital trauma, Orbital scanner, Antibiotics

## **INTRODUCTION :**

Orbital cellulitis is defined by the presence of an acute inflammatory orbital swelling of infectious origin. They are most often secondary to an infectious focus such as sinusitis [1,2]. Cellulitis complicating neglected intraocular foreign bodies is a non-obvious cause for diagnosis due to the mostly small size of the foreign body or the sometimes radiolucent nature difficult to diagnose even with radiology; or in the context of isolated treated palpebral wounds responsible for a delay in recognition and or adapted management. Hence the interest in highlighting this dramatic situation, insisting on its prevention and making patients aware of the importance of early consultation coupled with radiological exploration. This is the only way to avoid it.

## **AIMS :**

To highlight cases of neglected foreign bodies revealed in the late stages by orbital cellulitis and thus demonstrate the diagnostic and therapeutic difficulties and possible sequelae, having unfortunately sometimes ended up in evisceration.

## **MATERIALS AND METHODES :**

This is a retrospective descriptive study of patients with orbital cellulitis revealing neglected intraocular foreign bodies, conducted in the adult ophthalmology department at the 20 August Hospital in Casablanca, involving 58 patients, over a period of four and a half years, from January 2018 to July 2022. Orbital cellulitis of sinus origin, cellulitis secondary to lacrimal infection, cellulitis complicating endophthalmitis on corneal abscess, post-traumatic cellulitis, post-surgical cellulitis, or cellulitis revealing tumors were excluded from the study. All patients had a detailed ophthalmologic consultation. On each file, we noted the age of the patient, the time of consultation, the ophthalmological examination included visual acuity measurements. The ophthalmologic examination included visual acuity measurements. The presence of exophthalmos, lagophthalmos, chemosis or ophthalmoplegia was systematically noted. The status of the anterior and posterior segments was secondarily assessed in case of fundus examination. Medical imaging examinations: ocular ultrasound, CT scan, MRI, examinations of pus samples allowed us to proceed with an etiological or extension assessment and to isolate the germs involved. We noted the type (medical and/or surgical) and nature of the treatment the patient received, the route of administration and the evolution under treatment.

## **RESULTS :**

The average age of the patients was 38.5 years, with a minimum age of 21 years and a maximum age of 63 years. The most affected age group was between 21 and 30 years. Our study involved 13 men and 1 woman. Thus, the male/female sex ratio was 13 with a clear male predominance. The nature of the EC was dominated by metallic ECs in 57.14% of cases, followed by stone fragments in 21.42%, a plant thorn in 7.16% of cases, while it was of undetermined nature in 14.28% of cases (**Table 1**). 86% had no particular pathological

history. Delayed consultation was noted in all patients with an average of 4 days and self-medication in 21% of patients. The affected eye was in most cases the left eye. The portal of entry was dominated by corneal damage, which was found in 65% of patients.

Ophthalmological examination (**Pictures 1,2,3**) (**table 2**) showed decreased visual acuity (BAV) in all patients with unilateral blindness in 43% of cases, chemosis (93%), exophthalmos (52,71%), ophthalmoplegia (43%), orbital fistula (14%), purulent melting (43%). The majority of patients had an x-ray of the orbit, ocular ultrasound and orbital CT scan. MRI was not performed in any patient. The analysis of the CT scan results showed the presence of metallic CE (58%), pre-septal cellulitis (14%), orbital cellulitis (35%), and collected cellulitis (36%). All patients received medical treatment associated in 71% of cases with IVT of ATB, surgical treatment consisting of extraction of the foreign body by electromagnet or forceps in 36% of cases and evisceration of the eyeball unfortunately in a quarter of cases (**Table 3**).

## **DISCUSSION :**

Orbital cellulitis, although mostly secondary to sinusitis, may reveal various etiologies. Through this study, we have tried to show that the picture of orbital inflammation should not be labelled as sinusitis without a careful diagnostic approach. The diagnostic approach allows us not to ignore more unusual etiologies such as unnoticed intra-orbital foreign bodies. Indeed, the diagnosis and management of an intraorbital foreign body is often difficult because the patient's history is sometimes misleading and orbital wounds may be difficult to evaluate clinically or are underestimated [4,5]. Foreign bodies, essentially vegetal, have a high infectious potential due to their porous constitution which provides a good culture medium for bacterial agents [22,5,9] and due to the delay in diagnosis because they are sometimes difficult to detect on imaging [11,18,20,21]. The early signs that should lead to the suspicion of a foreign body are visual function disorders [4,11,18], persistent inflammation [8,16], severe infection, especially cellulitis with or without sinus or central nervous system

involvement [9,15,19], ptosis, ocular motility disorders, exophthalmos, dystopia of the globe, chemosis or persistent pain [1,4,6,11,16,18,22]. The consequences of foreign body retention in the orbit are multiple and potentially serious. Chronic orbital inflammation [16], orbital cellulitis [4], orbital abscess [1,11], foreign body granuloma [3,22], ophthalmoplegia [23], ptosis [17,19,23], palpebral retraction [22], chronic fistulous pathway and blindness have been described [3,4,11,18,19]. A case of osteomyelitis of the orbit [17] and a case of panophthalmitis with corneal perforation [21] have also been reported after foreign body trauma. In our series we noted unilateral blindness in 43% of cases, exophthalmos in 53%, ophthalmoplegia in 43% and unfortunately purulent melting in 43%. No cavernous sinus thrombosis was observed in our study. In a small series of 23 patients, Hodges et al. reported 52% blindness and 4% mortality due to cavernous sinus thrombosis [13]. Blindness is secondary to mechanical optic neuropathy, vascular origin by ischemia, thrombophlebitis or inflammatory origin (infectious neuritis) [7]. Thrombosis of the cavernous cavity was a frequent pathology before the advent of antibiotic therapy, with a mortality rate of 100% [14]. With antibiotic treatment, this rate has decreased to reach percentages between 23 and 50% [24]. The etiological assessment will necessarily include a careful clinical examination and then an orbital imaging, in emergency if necessary. The suspicion of a CE requires orbital imaging. Ultrasound and CT scans allow the visualization of metallic foreign bodies and very often glass debris. Other foreign bodies (plastic, stone, plant debris) are more difficult to detect [29]. Plant ECs are rare and no imaging technique is totally unable to detect "all" foreign bodies, since they can be detected in 95% of cases when they are located in the globe and in 70% of cases in intraorbital topography. This examination also allows to see if the foreign body is mobile with the movements of the globe or the head or if it is magnetizable [34]. On the other hand, its sensitivity is more limited if only plant foreign bodies are considered [5,13,35], and particularly in cases of very deep plant ECs (near the orbital apex) [29]. Moreover, it is very dependent on the experience of the operator. For many authors, MRI is the best examination for the detection of plant foreign bodies [11,21,23]. However, this examination is formally contraindicated in the case of a

magnetizable metallic foreign body: it is therefore more prudent to perform an X-ray or a CT scan of the orbits just before, to eliminate a metallic foreign body. However, MRI is not always available and remains an expensive examination [29]. In our series, orbital CT scans were performed in all patients (100% of cases) without the need for MRI. If diagnosed and treated early, orbital cellulitis evolves well and without sequelae; any delay in diagnosis and/or treatment can be a source of serious complications that can affect the functional and even vital prognosis. From a bacteriological point of view, the germ depends on the location, the portal of entry and the age of the patient [10]. The use of prior antibiotic therapy in more than 40% of cases would probably explain the low number of positive samples in our series. Broad spectrum antibiotic therapy should be instituted systematically after penetrating orbital trauma [19]. Tetanus prophylaxis is necessary if the vaccination is not up to date [29]. The surgical management of EC of the orbit must be entrusted to specialized teams because the surgical risk is not negligible. The surgical approach depends on the location of the foreign body, guided by imaging. A double team of ophthalmologists and neurosurgeons may be necessary [3,15,19,23]. The main surgical complications are the occurrence of iatrogenic lesions of the orbital structures, fragmentation of the foreign body and partial or total failure of the removal [37]. In the case of endophthalmitis or purulent melting despite a well adapted treatment, evisceration remains the surgical treatment of choice. In our context it was unfortunately performed in 25% of the cases. This explains the rather high rate of late cases in relation to the delay of consultation.

## **CONCLUSION :**

Orbital cellulitis, although mostly secondary to sinusitis, can reveal various etiologies such as intra-orbital foreign bodies that can go unnoticed and be life-threatening and functionally damaging, especially when the diagnosis is made late and management is inappropriate. The presence of an intraocular foreign body must be suspected in all cases of orbital trauma associated with a palpebral wound, even if it is minimal, or in the presence of a clinical

aggravation. Any delay in diagnosis and/or treatment can lead to serious complications. Surgical treatment consists of extraction of the EC. Unfortunately, recourse to evisceration in our context continues to persist at high rates, due to the delay in consultation and thus in management. Prevention is based on patient education on the importance of early consultation to improve the prognosis and avoid certain dramatic situations.

#### **CONFLICT OF INTEREST :**

No potential conflict of interest relevant to this article was reported.

#### **PATIENT CONSENT :**

Patients provided written informed consent for publication and the use of their images.

#### **REFERENCE:**

- [1] Reshef DS, Ossoinig KC, Nerad JA. Diagnostic and intraoperative localization of a deep orbital organic foreign body. *Orbit* 1987;6:3—15.
- [2] Mouriaux F, Rysanek B, Cattoir V, Babin E. Infections Orbitaires. *Emc Ophtalmologie*. 2011;8(4):1-9.
- [3] Liu D, Al Shail E. Retained orbital wooden foreign body. A surgical technique and rationale. *Ophthalmology* 2002;109:393-9.
- [4] Jabaly-Habib HY, Muallem MS, Garzosi HJ. An intraorbital injury from an occult wooden foreign body. *J Pediatr Ophthalmol Strabismus* 2002;39:300—2.
- [5] Cartwright MJ, Kutumety UR, Frueh BR. Intraorbital wood foreign body. *Ophthal Plast Reconstr Surg* 1995;11:44—8.
- [6] Macrae JA. Diagnosis and management of a wooden orbital foreign body: case report. *Br J Ophthalmol* 1979;63:848—51.
- [7] Ananth Kumar GB, Dhupar V, Akkara F, Praveen Kumar S. Foreign body in the orbital floor: a case report. *J Maxillofac Oral Surg* 2015;14:832-5.
- [8] Grove AS. Computed tomography in the management of orbital trauma. *Ophthalmology* 1982;89:433—40.

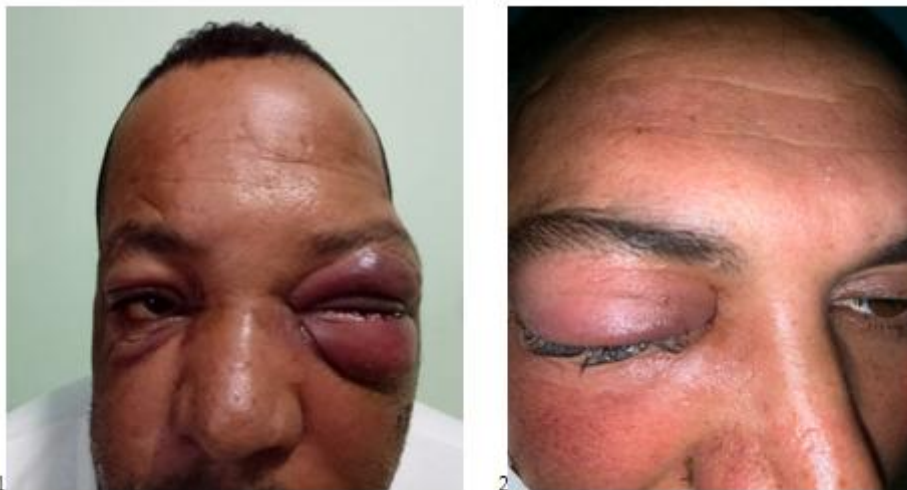- [9] T. P. Fulcher, A. A. McNab, and T. J. Sullivan, "Clinical features and management of intraorbital foreign bodies," *Ophthalmology*, 2002 vol. 109, no. 3, pp. 494–500
- [10] Nagae LM, Katowitz WR, Bilaniuk LT, Anninger WV, Pollock AN. Radiological detection of intraorbital wooden foreign bodies. *Pediatr Emerg Care* 2011;27:895-6.
- [11] Green BF, Kraft SP, Carter KD, Buncic JR, Nerad JA, Armstrong D. Intraorbital wood. Detection by magnetic resonance imaging *Ophthalmology* 1990;97:608–11.
- [12] Ailal F, Bousfiha A, Juhadi Z, Bennani M, Abid A. Cellulites orbitaires Chez l'enfant: à propos d'une étude rétrospective de 33 Cas. *Med Trop (Mars)*. 2004; 64(4): 359-62. PubMed | Google Scholar
- [13] Hodges E, Tabbara KF. Orbital cellulitis: review of 23 cases from Saudi Arabia. *Br J Ophthalmol*. 1989 Mar ; 73(3) : 205-8. PubMed | Google Scholar
- [14] Kriss TC, Kriss VM, Warf BC. Cavernous sinus thrombophlebitis: case report. *Neurosurgery*. 1996 Aug; 39(2): 385-9. PubMed | Google Scholar
- [15] Kazarian EL, Stokes NA, Flynn JT. The orbital puncture wound: intracranial complications of a retained foreign body. *J Pediatr Ophthalmol Strabismus* 1980;17:247–50.
- [16] Tsaloumas MD, Potamitis T, Kritzinger EE. Two cases of retention of wooden foreign bodies in orbit of eyes. *BMJ* 1998;316:1363–4.
- [17] Townsend DJ, Beyer-Machule C, Fabian RL. Osteomyelitis of the orbit. A case report. *Ophthalm Plast Reconstr Surg* 1986;2:15–9.
- [18] Weinacht S, Zaunbauer W, Gottlob I. Optic atrophy induced by an intraorbital wooden foreign body: the role of CT and MRI. *J Pediatr Ophthalmol Strabismus* 1998;35:179–81.
- [19] A.B. Callahan and M. K. Yoon, "Intraorbital foreign bodies: retrospective chart review and review of literature," *International Ophthalmology Clinics*, vol. 53, no. 4, pp. 157–165, 2013.
- [20] D'Hermies F, Halhal M, Morel X, Meyer A, Renard G. Corps étranger végétal intra-orbitaire. *J Fr Ophtalmol* 2001;24:517–21.
- [21] Charteris DG. Posterior penetrating injury of the orbit with retained foreign body. *Br J Ophthalmol* 1988;72:432–3.
- [22] V.H.Ho, M.W.Wilson, J.C.Fleming, and B. G. Haik, "Retained intraorbital metallic foreign bodies," *Ophthalmic Plastic and Reconstructive Surgery*, vol. 20, no. 3, pp. 232–236, 2004.
- [23] Yamashita T, Mikami T, Baba T, Minamide Y, Sugino T, Koyanagi I, et al. Transorbital intracranial penetrating injury from impaling on an earpick. *J Neuroophthalmol* 2007;27:48–9.
- [24] Nagi S, Kaddour C, Jeribi R, Marrakchi-Turki Z, Ben Yahmed A, Skandrani L, Ben Slama C Et Ben Hamouda M. Thrombose de la loge caverneuse secondaire a une sinusite. *J Radiol*. 2008 Jun;8 9(6): 803-5. PubMed | Google Scholar
- [25] S. Prazeresa,\*, P.-V. Jacometa, O. Galatoirea, et al. Diagnosis and therapeutic management of an intraorbital organic foreign body, in a *Journal français d'ophtalmologie* (2009) 32, 8–15.

[26] Gonullu ME, Filinte GT, Cardak NG, Kucuk S, Akoz T. The surgical strategy for the intraorbital foreign bodies. *J Craniofac Surg* 2016;27:1785-8.

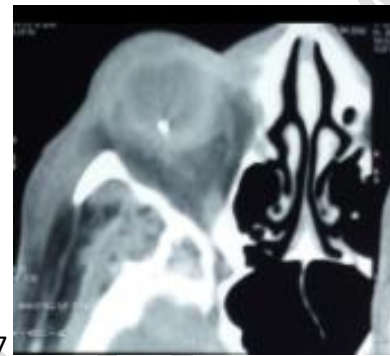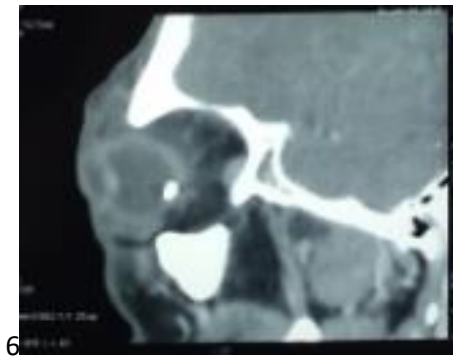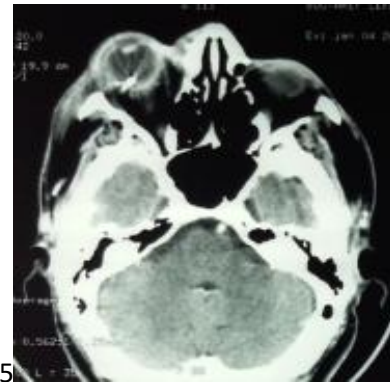
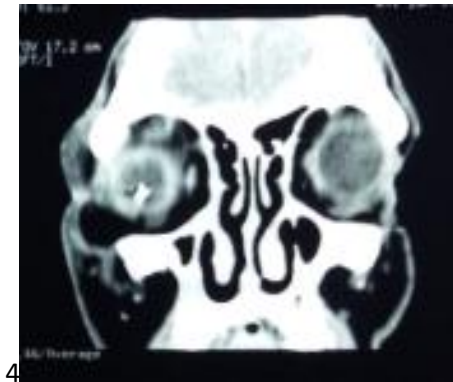[27] A. B. Callahan and M. K. Yoon, "Intraorbital foreign bodies: retrospective chart review and review of literature," *International Ophthalmology Clinics*, 2013 vol. 53, no. 4, pp. 157–165

[28] Sitaula S, Gautam V. Intraorbital wooden foreign body: a case report. *J Kathmandu Med Coll* 2014;3:119-21.

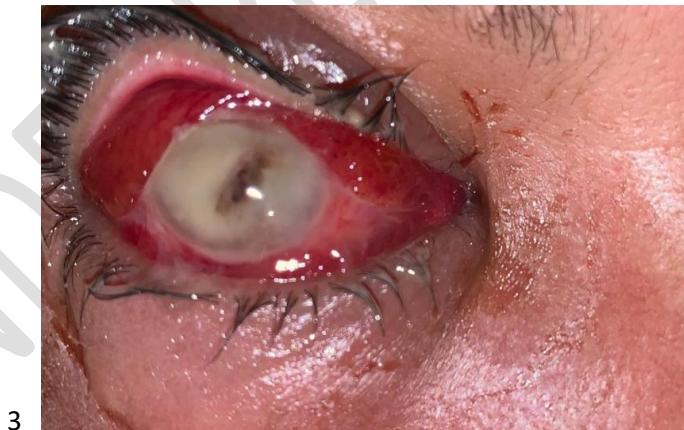[29] Y.-M. Tian, X.-W. Gao, B. Ren et al., "Clinical observation on removal of small foreign bodies touching the optic nerve in the deep orbital region: a case series," *Orbit*, vol. 33, no. 3, pp. 210–213, 2014.



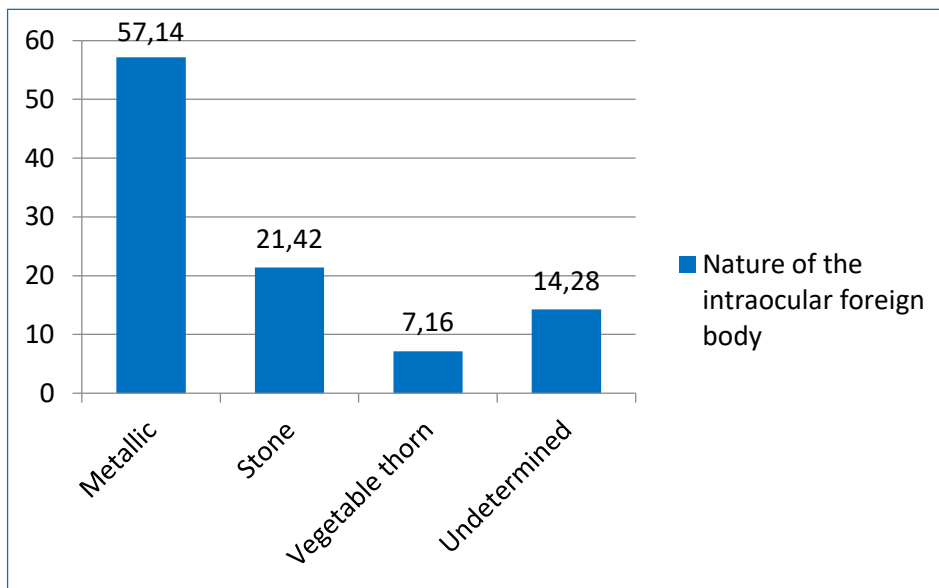
Pictures 1,2 : orbital cellulitis



Pictures 4,5,6,7 : Orbital scan showing intraocular foreign bodies



Picture 3 : Purulent cast



**Table 1 :** Nature of the intraocular foreign body

Ophthalmological examination	Number of cases	Percentage
Unilateral blindness	25	43%
Chemosis	54	93%
Exophthalmos	31	52.7%
Ophthalmoplegia	25	43%
Purulent melting	25	43%

**Table 2 :** Clinical examination data

	Number of cases	Percentage
General intravenous antibiotic therapy	58	100%
Intravitreal injection of antibiotic	41	71%
Surgical extraction of the foreign body	21	36%
Evisceration	14	25%

**Table 3 :** Therapeutic care