

Original Research Article

Comparison between efficacy of carboxytherapy, plasma gel injection and mesotherapy in treatment of periorbital dark circles

Abstract

Background: Periorbital dark circles (PODC) is also recognized as periorbital melanosis, dark eye circles, and infraorbital darkness. It's a public cosmetic skin disorder with relative darkness of the periorbital areas. This condition affects both sexes, it gets worse by aging which makes people look tired and older so it has a negative effect on the quality of life, particularly in

Women.

Methods: This comparative, simple randomized, controlled study was carried out on 30 patients with presented with periorbital dark circles did not receive any treatment 3 months before joining the study. The patients were equally allocated into three groups **Group A:** treated with bilateral injection of PRP gel, **Group B:** treated with bilateral intradermal injection of CO₂ with carboxytherapy machine and **Group C:** treated with intradermal injection of vitamin C. All patients received 4 sessions with 2 weeks a part.

All patients were subjected to complete history taking, general and dermatological examination and clinical assessment was done for all patients to determine the type of dark circles

Results: The improvement of PODC in Plasma gel injection and carboxytherapy mesotherapy were excellent in (50%) and (40%) in vitamin C group. There was gradual improvement of PODC with time, but recurrence rate of the studied groups after 6 months was 40%, 30%, 60% in group A, B and C respectively, showing higher recurrence rate in group C patients treated with vitamin C mesotherapy.

Conclusions: Gel injection, carboxytherapy and vitamin C mesotherapy were effective and safe therapeutic modalities in treatment of PODC.

Keywords: carboxytherapy, plasma gel injection, mesotherapy, periorbital dark circles

UNDER PEER REVIEW

Introduction:

Periorbital dark circles (PODC) are also identified as periorbital melanosis, dark eye circles, and infraorbital darkness. It is a cosmetic skin ailment characterised by relative darkening of the periorbital regions. This disorder affects both sexes, it worsens with age, making people appear fatigued and older, and it has a severe impact on women's quality of life [1].

Non-surgical options for the treatment of periorbital pathologies include hyaluronic acid injections, micro-needling, chemical peels, laser-resurfacing, microdermabrasion, nifedipine, botulinum toxin, and carbon dioxide (carboxytherapy) injections. Surgical options include fat transfers, blepharoplasty, and face-lifts [2].

Although there are several therapy options for PODC, the majority of them have negative results. Platelet-rich plasma (PRP) and carboxytherapy may hold promise for face rejuvenation and treatment of PODC in aesthetic dermatology [3].

Centrifugation generates autologous platelets in platelet-rich plasma. The platelet concentration is three to five times the average plasma concentration (1). At least seven important protein growth factors are secreted by platelets to initiate wound healing. The main premise of PRP therapy is to augment this natural regeneration process by administering a concentrated dose of platelets and higher concentrations of growth factors than those found in peripheral blood [4].

CO₂ is injected transcutaneously in carboxytherapy treatment, which is a noninvasive method. By boosting the amounts of growth hormones, this treatment encourages the development of new blood vessels. This increased blood flow delivers oxygen and nutrients to the skin and blood vessels, hence improving the skin's look [5].

Mesotherapy refers to a number of minimally invasive procedures that involve intracutaneous or subcutaneous injections of fluids. Some of the most popular substances injected in mesotherapy are vitamins, such as vitamin C, which can assist in the healing of face skin [5].

This study aims to examine the efficacy and safety of carboxytherapy, plasma gel injection, and vitamin-C mesotherapy in the treatment of PODC.

Patients and Methods:

This was a comparative, simple randomized, controlled study carried out on 30 patients presented with periorbital dark circles did not receive any treatment 3 months before joining the study who were admitted to Outpatient Clinic of Dermatology and Venereology Department, Tanta University Hospitals, from December 2019 to December 2020.

The study was started after being approved from Dermatology and Venereology Department, Tanta University Hospitals. Signed consent was obtained from all cases.

Exclusion criteria including Pregnant or lactating patients, heavy smokers, patients using anticoagulants, patients suffer from or having history of blood dyscrisis, active infection or inflammation in the treated area, patients with other systemic or skin diseases and history of keloid formation or foreign body reaction.

The patients were randomly allocated into three groups according to the therapeutic regimen;

Group A: 10 patients treated with bilateral injection of PRP gel, **Group B:** 10 patients treated with bilateral intradermal injection of CO₂ with carboxytherapy machine and **Group C:** 10 patients treated with intradermal injection of vitamin C. All patients received 4 sessions with 2 weeks a part.

All patients were subjected to Complete history taking, general and dermatological examination and Clinical assessment was done for all patients to determine the type of dark circles.

Plasma gel preparation: 10 mL of autologous whole venous blood sample was collected from antecubital vein. Each blood sample was centrifuged for 10 minutes at 3000 RPM at room temperature, The plasma layer was centrifuged for another 5 minutes at 1000 RPM to

obtain platelet-poor plasma (PPP) for injection subcutaneously through filler cannula of size 23G at the point of nasojugal fold projection line converges with the perpendicular line to the outer canthus of the eye, then treated area was massaged, a cool compress was applied for the next 4 to 6 hours to reduce bruises.

Carboxytherapy approach: The instrument used was carboxytherapy device; includes a CO₂ gas tube, power supply, CO₂ regulator, skin stabilizer, short extension tube, long extension tube, bacteria; filter and an injection gun (CONCERTO, BFP Electronique Pole Technologique de Vimenet 48 100 MONTRODAT – France). The injections were performed in specific points at 2 or 3 punctures, 1 or 2 cm spaced 1 or 2 seconds each, made all along the external inferior border of the eye orbit and at lateral upper eyelid, bilaterally by A 32G needle to perform the injections. The total amount of gas administered was equal to 1-2mL for each side with flow rate 1cc/sec.

Statistical analysis

Statistical analysis was done by SPSS v20 (Armonk, NY: IBM Corp). Quantitative variables were compared by Chi-square test and Monte Carlo correction and were presented as range (minimum and maximum), mean, standard deviation, median and interquartile range (IQR). Qualitative variables were presented as number and percentage (%). ANOVA test, Kruskal Wallis test, McNemar Bowker test were used to compare between more than 2 groups and Spearman correlation for non-parametric variables. P value ≤ 0.05 was statistically significant

Results

The demographic data were illustrated in Table 1

Table 1: Demographic data in studied groups.

Variables		Group A (n = 10)	Group B (n=10)	Group C (n=10)	P
Sex	Male	3(30%)	3(30%)	2 (20%)	1.000
	Female	7(70%)	7(70%)	8 (80%)	
Age (yr.) Mean \pm SD.		38.1 \pm 10.60	40.5 \pm 6.69	30.6 \pm 4.33	0.020*

Age groups	Early adulthood	6 (60%)	5 (50%)	10 (100%)	0.077
	Middle adulthood	4 (40%)	5 (50%)	0 (0.0%)	
Duration (yr.) Mean ± SD.		6.5 ± 1.96	7.3 ± 1.77	7.1 ± 1.79	0.524
Family history	- ve	6(60%)	4 (40%)	5(50%)	0.670
	+ ve	4 (40%)	6(60%)	5(50%)	

Data was presented as mean ± SD or frequency and percentage, * p ≤ 0.05 is statistically significant

There was a statistically insignificant relation between the studied groups regarding type of PODC (P value: 0.301). Table 2

Table 2: Type of PODC

Variables	Group A	Group B	Group C	P
Type of PODC				0.301
Structural	2 (20%)	0 (0.0%)	0 (0.0%)	
Pigmented	2 (20%)	1(10%)	5 (50%)	
Vascular	2 (20%)	2 (20%)	1(10%)	
Mixed				
• (VS)	2 (20%)	1(10%)	0 (0.0%)	
• (PS)	1(10%)	2 (20%)	2 (20%)	
• (PV)	1(10%)	4 (40%)	2 (20%)	

Data was presented as frequency and percentage, * p ≤ 0.05 is statistically significant

Cases distribution according to PODC grading before and after treatment was showed in

Table 3

Table 3: Distribution of group A, B and C patients according to PODC grading before and after treatment:

PODC grades	Group A		Group B		Group C	
	Before	After	Before	After	Before	After
Grade 0	0 (0.0%)	3(30%)	0 (0.0%)	2 (20%)	0 (0.0%)	1 (10%)
Grade I	0 (0.0%)	2 (20%)	0 (0.0%)	4(40%)	0 (0.0%)	5(50%)
Grade II	4(40%)	5(50%)	4(40%)	4(40%)	1 (10%)	4(40%)
Grade III	6 (60%)	0 (0.0%)	4(40%)	0 (0.0%)	8 (80%)	0 (0.0%)
Grade IV	0 (0.0%)	0 (0.0%)	2 (20%)	0 (0.0%)	1 (10%)	0 (0.0%)
P	0.036*		0.112		0.021*	

Data was presented as frequency and percentage, * p ≤ 0.05 is statistically significant

Cases distribution according to degree of improvement in relation to PODC type was showed

in Table 4

Table 4: Distribution of group A, B and C patients according to degree of improvement in relation to PODC type.

PODC	Group A			Group B			Group C			
	Excell-ent 50%	Fair 20%	Poor 30%	Excell-ent 50%	Good 10%	Fair 40%	Excell-ent 40%	Good 30%	Fair 20%	poor 10%

Structural	2 20%	-	-	-	-	-	-	-	-	-
Pigmented	-	-	2 20%	-	-	1 10%	4 40%	1 10%	-	-
Vascular	-	-	1 10%	2 20%	-	-	-	-	-	1 10%
Mixed	VS	2 20%	-	-	-	1 10%	-	-	-	-
	PS	1 10%	-	-	3 30%	1 10%	-	-	1 10%	1 10%
	PV	-	1 10%	-	-	-	2 20%	-	1 10%	1 10%
P	0.081			0.228			0.024*			

Data was presented as frequency and percentage, * $p \leq 0.05$ is statistically significant
 Comparison between the three studied groups according to the degree of improvement showed no statistically significant difference between them ($P= 0.245$). Table 5

Table 5: degree of improvement between studied groups

Degree of improvement	Group A (n = 10)	Group B (n=10)	Group C (n=10)	P
Excellent	5 (50%)	5 (50%)	4 (40%)	0.245
Good	0 (0%)	1 (10%)	3 (30%)	
Fair	2 (20%)	4 (40%)	2 (20%)	
Poor	3 (30%)	0 (0%)	1 (10%)	

Data was presented as frequency and percentage, * $p \leq 0.05$ is statistically significant
 There was a statistically significant relation between the studied. groups regarding duration of PODC ($P < 0.001$). Table 6

Table 6: Relation between degree of improvement and duration of PODC is studied groups

Variables	Degree of improvement				P
	fair	Poor	Good	Excellent	
Duration (yr.) Mean \pm SD.	8.5 \pm 2.38	8.0 \pm 1.93	6.0 \pm 1.22	3.0 \pm 1.15	<0.001*

Data was presented as mean \pm SD, * $p \leq 0.05$ is statistically significant
 Correlation between degree of improvement and duration of PODC according to spearman correlation showed statistically significant negative strong correlation ($P= 0.006$, $r_s= 0.494$).

Figure1

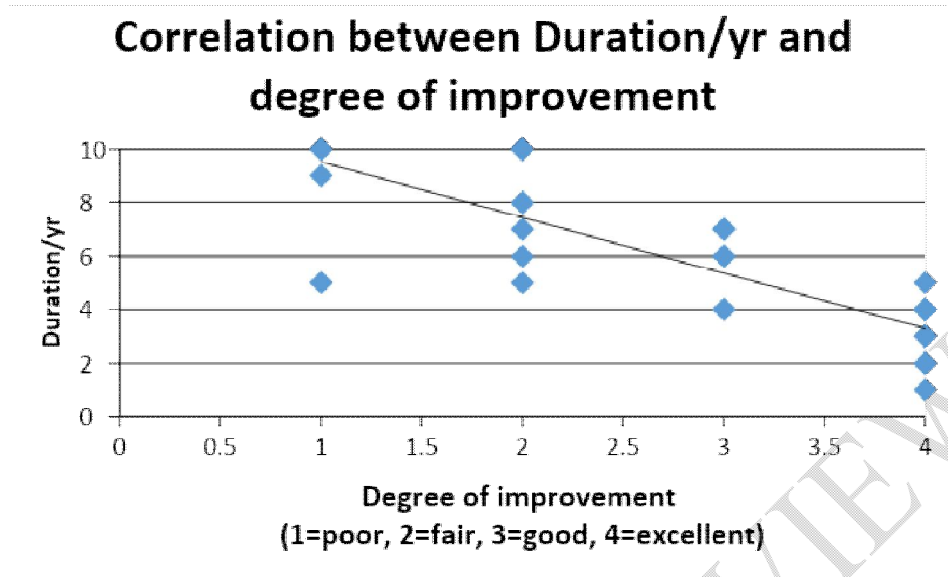


Figure 1: correlation between duration/yr and degree of improvement in all groups.

There was a statistically insignificant relation between the three studied groups regarding recurrence rate (P= 0.531). Table 7

Table (7): Recurrence rate after the end of treatment in studied groups:

Variables	Group A (n = 10)		Group B (n=10)		Group C (n=10)		P
	N.	%	N.	%	N.	%	
Recurrence							0.531
- ve	6	60.0	7	70.0	4	40.0	
+ ve	4	40.0	3	30.0	6	60.0	

Data was presented as frequency and percentage, * $p \leq 0.05$ is statistically significant

There was a statistically insignificant relation between the three studied groups regarding patient satisfaction (P= 0.895). Table 8

Table (8): Patient satisfaction in studied groups:

Variables	Group A (n = 10)	Group B (n=10)	Group C (n=10)	P
Patient satisfaction				0.895
Unsatisfied	5 (50%)	4 (40%)	3 (30%)	
Satisfied	5 (50%)	6(60%)	7 (70%)	

Data was presented as frequency and percentage, * $p \leq 0.05$ is statistically significant

Case (1)

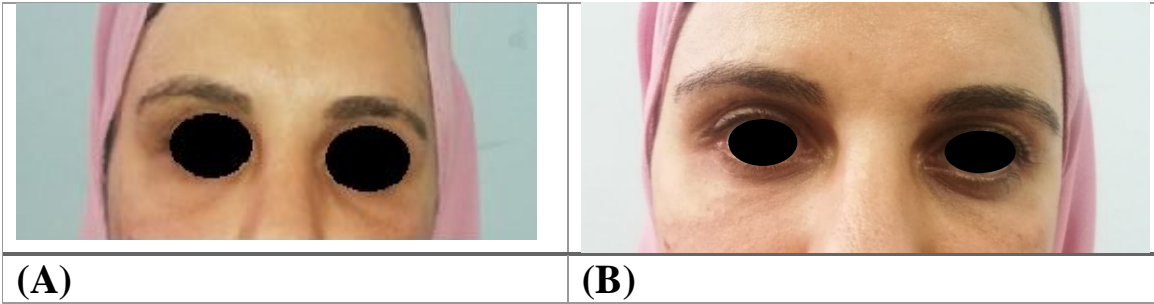


Figure 2: A 44-years old female patient with bilateral PODC, pigmented structural type (grade III). (A): Before treatment with PRP gel injection. (B): After treatment, showing excellent improvement (grade 0).

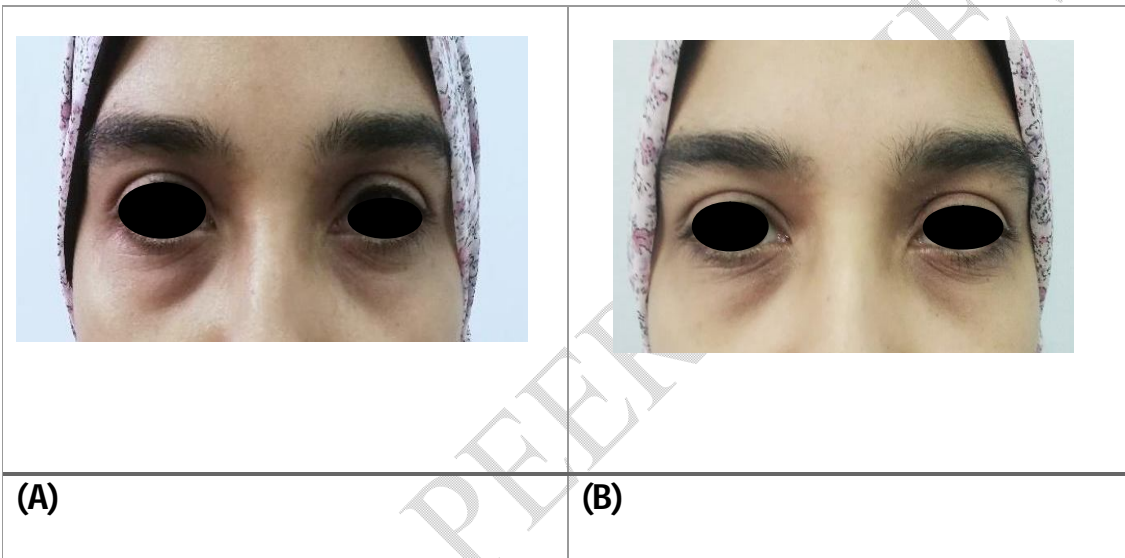
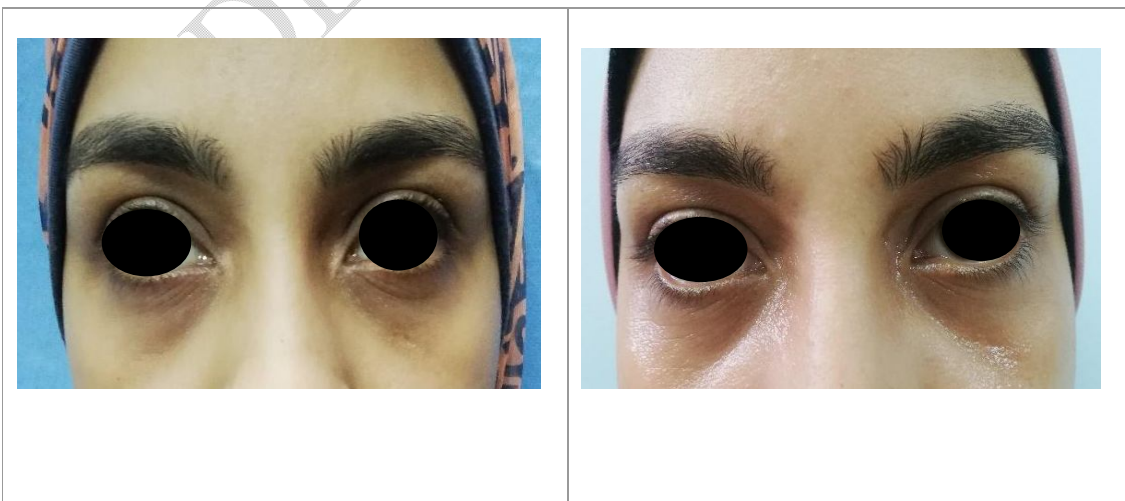

Figure 3: A 30-years old female with bilateral PODC, pigmented vascular type (grade III). (A): Before treatment with carboxytherapy. (B): After treatments, showing excellent improvement (grade I).



(A)	(B)
-----	-----

Figure 4: A 30-years old female with bilateral PODC, pigmented type (grade III). (A): Before treatment with vitamin C mesotherapy. (B): After treatment, showing excellent improvement (grade I).

Discussion

Periorbital dark circles (PODC) are characterised as bilateral, round, homogeneously pigmented macules on the periorbital areas; this condition is rather prevalent and affects people of all ages, sexes, and races. This condition develops with age and can be a serious aesthetic problem for female patients. PODC alter the facial appearance, giving the patient a fatigued, unhappy, or bloated appearance [6].

In reality, periorbital pigmentation can be caused by a number of reasons. It may be an indication of a systemic illness, skin issue, allergic response, nutritional deficit, or sleep disorder. On the other hand, it has been indicated that cutaneous hyperchromia of the orbital area is not always connected with systemic illness; it has also been observed in healthy individuals. Bleaching creams, topical retinoic acid, chemical peels, laser therapy, autologous fat transplantation, injectable fillers, microneedling, and carboxytherapy are available therapies for PODC [7].

Platelet-rich plasma (PRP) and carboxytherapy may hold promise for face rejuvenation and treatment of PODC in aesthetic dermatology. [8].

Up to our knowledge there was no previous study evaluated the effect of PRR gel on treatment of PODC. In this study, there were 50% of the studied cases in PRP gel group had an excellent improvement, A point of interest, there is a study done by **Al-Shami**, [2] in which Three months of monthly platelet-rich plasma injections were administered to patients. Six months after the initial session, two blinded dermatologists utilising standardised digital photography and the patient's self-assessment evaluated the final outcome. According to the dermatologists' judgement, the outcomes were highly excellent, as about 60% of patients had moderate to considerable improvement.

In group B; there were 1 (10%) patient with pigmented type, 2 (20%) patients with vascular type, 1(10%) patient with vascular structural type, 2 (20%) patients with pigmented structural type and 4 (40%) patients with pigmented vascular type.

As regard to the degree of improvement in group B who treated with carboxytherapy, 5 (50%) of the studied cases had excellent improvement, 2 (20%) of them were vascular type and 3 (30%) of them were pigmented vascular. Good improvement occurred in 1 (10%) of patients with pigmented vascular type. The other 4 (40%) of patients showed fair improvement, 1(10%) of them was pigmented type, 1(10%) was vascular structural type and 2 (20%) were pigmented structural type. Carboxytherapy showed excellent and good results mainly with patients with PODC vascular and mixed vascular types, however it showed fair results with structural and pigmented types, but the degree of improvement between the different types of PODC in this group was statistically insignificant ($P= 0.081$).

This was in agreement with the study done by **Hassan et al., 2016** ⁽⁸⁾, who stated that the degree of improvement of PODC for the group treated by carboxytherapy was excellent in 46.7% of the patients, while showing good and fair results in 40% and 13.3% of them, respectively.

In group C; there were 5 (50%) patients with pigmented type, 1 (10%) patients with vascular type, 2 (20%) patients with pigmented structural type and 2 (20%) patients with pigmented vascular type.

Regarding to degree of improvement in group C, 4 patients (40%) had excellent improvement who had mainly pigmented type. Good improvement occurred in 3 patients (30%), one of them was pigmented type, one was pigmented vascular, and the last one was pigmented structural type. Two (20%) of patients showed fair improvement, one of them were pigmented vascular and the other one was pigmented structural type. 10% of patients showed poor improvement who had mainly vascular type. Treatment with vitamin C mesotherapy

showed excellent results mainly with patients with PODC pigmented type. This finding suggests that the main cause of improvement might be due to the anti-pigmentary and antioxidant effect of vitamin C, so most patients noticed lightening of pigmentation after the first two sessions. However, it showed fair and poor results with mixed and vascular types. The degree of improvement between the different types of PODC in group C was statistically significant ($P= 0.024$).

In accordance with our study, **Ohshima et al.** ^[9], used two types of 10% vitamin C lotion, sodium ascorbate and ascorbic acid glucoside for six months in a splitfaced manner for dark circles and found that there was lightening of pigmentation owing to concealment of dark discoloration due to increase in dermal thickness.

In our study there was alteration in PODC grading before and after the treatment. **In group A**, before treatment, 6 (60%) patients had grade III and 4 (40%) patients had grade II. After treatment they became 3 (30%) patients with grade 0, 2 (20%) patients with grade I and 5 (50%) patients with grade II and there was a statistically significant improvement between patients of group A regarding grading of PODC before and after treatment ($P= 0.036$).

In group B, before treatment with carboxytherapy, there were 2 (20%) patients with PODC grade IV, 4 (40%) patients with grade III and 4 (40%) patients with grade II. After treatment, PODC grading of this group patients have changed into 2 (20%) patients with grade 0, 4 (40%) patients with grade I and 4 (40%) patients with grade II. There was statistically insignificant difference between patients of group B regarding grading before and after treatment, which agree with the study done by **West and Alter** ^[10], who studied 12 female patients with PODC grades ranged from 2 to 4 before treatment and after treatment ranged from 1 to 3 with non-significant difference in between.

In group C, before treatment with vitamin C mesotherapy, 1 (10%) patient had grade IV, 8 (80%) patients had grade III and 1 (10%) patient had grade II. After treatment with vitamin C

mesotherapy, they became 1(10%) patient with grade 0, 5 (50%) patients with grade I and 4 (40%) patients with grade II. There was statistically significant difference between group C patients regarding grading before and after treatment ($P= 0.021$) and this in agreement of the study done by **Ahmed et al.** ^[5] who found that the group treated with vitamin C mesotherapy showed a higher degree of excellent improvement with statistically significant improvement between group patients.

Regarding patient satisfaction there was no statistically significant difference in between the three treatment modalities in PODC with $P= 0.895$

In accordance with our study, a study done by **Ahmed et al.** ^[5] found that there was no statistically significant difference between carboxy therapy and mesotherapy groups regarding patient satisfaction after treatment ($P > 0.05$). However, mesotherapy group showed a higher degree of excellent satisfaction after treatment and that agrees with our study.

Regarding the duration of PODC, we found statistically significant negative strong correlation between degree of improvement and duration of PODC according to spearman correlation. This mean that the shorter the duration of PODC, the better the improvement with treatment. This agrees with the study done by **Hassan AM et al.** ^[11] who found negative moderate correlation between duration of PODC and degree of improvement.

Plasma gel, as one of the platelets formulations, works through release of several growth factors upon degranulation of their platelets' α -granules including PDGF, TGF-B, IGF, VEGF, and EGF ^[12].

Carboxytherapy which is transcutaneous and intradermal injection of CO_2 that is recognized subcutaneously as an oxygen deficit and this causes an increase in blood flow and growth factors like VEGF that stimulates neo angiogenesis and so increase transcutaneous oxygen tension due to increase capillary blood flow^[14]. Carboxytherapy is also effective in reducing

the maximum circumference of the treated area as CO₂ infiltration showed fracturing of the adipose, with lysis of the adipocytes not involving the vessel structure. This lipolytic effect was observed in patients with adipose bags under the eye, so it is effective in improving skin irregularities and texture.

The vitamin C acts as an antipigmentation agent. It inhibits the function of tyrosinase, the major enzyme responsible for the conversion of tyrosine to melanin, by interacting with copper ions at tyrosinase-active sites[15]. Vitamin C also directly stimulates the transcription factors involved in collagen production and stabilises the procollagen mRNA that controls the synthesis of Type I and Type III collagen. In addition, vitamin C enhances collagen gene expression and tissue MMP-1 inhibitor production, which lowers collagen breakdown. [16]

Conclusions:

Gel injection, carboxytherapy and vitamin C mesotherapy were effective and safe therapeutic modalities in treatment of PODC, Improvement of PODC was shown by decline of its severity and improvement of skin texture of periorbital area, Improvement of PODC occurred from the first session mainly with PRP gel injection and carboxytherapy, Plasma gel was effective in all types of PODC with marked improvement in structural type, while carboxytherapy showed marked improvement in vascular type of PODC and vitamin C mesotherapy was effective mostly with pigmented type of PODC, Minimal and temporary side effects as pain, edema, erythema and ecchymosis were noticed and well tolerated with no needed medical treatment.,

References:

1. Nilforoushzadeh MA, Heidari-Kharaji M, Alavi S, Mahmoudbeyk M, Torkamaniha E, Peyrovan A, et al. Assessing the effectiveness of the combination therapy with fractional Er-YAG laser and platelet-rich plasma in treatment of periorbital dark circles patients: A clinical trial. *J Cosmet Dermatol*. 2021;20:3526-36.

2. Evans AG, Ivanic MG, Botros MA, Pope RW, Halle BR, Glassman GE, et al. Rejuvenating the periorbital area using platelet-rich plasma: a systematic review and meta-analysis. *Arch Dermatol Res.* 2021;313:711-27.
3. Michelle L, Pouldar Foulad D, Ekelem C, Saedi N, Mesinkovska NA. Treatments of Periorbital Hyperpigmentation: A Systematic Review. *Dermatol Surg.* 2021;47:70-4.
4. Everts PA, van Erp A, DeSimone A, Cohen DS, Gardner RD. Platelet Rich Plasma in Orthopedic Surgical Medicine. *Platelets.* 2021;32:163-74.
5. Arora G, Arora S. Periorbital Rejuvenation: A Study on the Use of Dermal Threads as Monotherapy, with a Review of Literature. *J Cutan Aesthet Surg.* 2022;15:48-57.
6. Sarkar R, Ranjan R, Garg S, Garg VK, Sonthalia S, Bansal S. Periorbital Hyperpigmentation: A Comprehensive Review. *J Clin Aesthet Dermatol.* 2016;9:49-55.
7. Friedmann DP, Goldman MP. Dark circles: etiology and management options. *Clin Plast Surg.* 2015;42:33-50.
8. Mehryan P, Zartab H, Rajabi A, Pazhoochi N, Firooz A. Assessment of efficacy of platelet-rich plasma (PRP) on infraorbital dark circles and crow's feet wrinkles. *J Cosmet Dermatol.* 2014;13:72-8.
9. Ohshima H, Takiwaki H. Evaluation of dark circles of the lower eyelid: comparison between reflectance meters and image processing and involvement of dermal thickness in appearance. *Skin Res Technol.* 2008;14:135-41.
10. West TB, Alster TS. Improvement of infraorbital hyperpigmentation following carbon dioxide laser resurfacing. *Dermatol Surg.* 1998;24:615-6.
11. Ahmed NA, Mohammed SS, Fatani MI. Treatment of periorbital dark circles: Comparative study of carboxy therapy vs chemical peeling vs mesotherapy. *J Cosmet Dermatol.* 2019;18:169-75.

12. Nofal E, Elkot R, Nofal A, Eldesoky F, Shehata S, Sami M. Evaluation of carboxytherapy and platelet-rich plasma in treatment of periorbital hyperpigmentation: A comparative clinical trial. *J Cosmet Dermatol*. 2018;17:1000-7.
13. Yang L, Ma J, Gan S, Chu S, Maldonado M, Zhou J, et al. Platelet poor plasma gel combined with amnion improves the therapeutic effects of human umbilical cord-derived mesenchymal stem cells on wound healing in rats. *Mol Med Rep*. 2017;16:3494-502.
14. McArdle F, Rhodes LE, Parslew R, Jack CI, Friedmann PS, Jackson MJ. UVR-induced oxidative stress in human skin in vivo: effects of oral vitamin C supplementation. *Free Radic Biol Med*. 2002;33:1355-62.
15. Duarte TL, Cooke MS, Jones GD. Gene expression profiling reveals new protective roles for vitamin C in human skin cells. *Free Radic Biol Med*. 2009;46:78-87.
16. Fujii J. Ascorbate is a multifunctional micronutrient whose synthesis is lacking in primates. *J Clin Biochem Nutr*. 2021;69:1-15.