

Indications for cerebral CT in neurological emergencies in the pediatric emergency department: is there an abuse?

Abstract:

The CT scan is a common tool in the management of pediatric emergencies, especially in the diagnosis of intracranial pathologies, since it provides rapid responses allowing vital decisions to be made. However, by giving an easy access to this kind of examination calls for caution. The advantages and disadvantages of the CT scan, particularly in the pediatric population, must be carefully assessed.

The polemic about the indication for brain CT and the increase possibility of its prescription motivated this evaluation of professional practices. We conducted a retrospective descriptive study of 205 patients for whom brain CT was indicated for a non-traumatic neurological emergency in the pediatric emergency department of the mother-child hospital of the CHU Mohamed VI of Marrakech, over a period of one year. The aim was to describe the conditions for prescribing brain CT, its indications and their compliance with international recommendations, as well as the CT results found and their implications on management

Our study included 141 patients: 72 boys and 69 girls, with a mean age of 2 years and 3 months (45 days to 15 years) and a sex ratio of 1.04. Seizures were the main cause of consultation (50.4%), followed by headaches (12.8%), motor deficits and consciousness disorders, which represented 11.3% each. Neurological abnormalities were found in 28% of patients (11% hydrocephalus, 6% epilepsy, 4% psychomotor retardation, 3% central nervous system infections, 2% ischemic stroke, 2% intracranial tumors).

Indications for brain CT were dominated by seizures in 38%, HTIC syndrome in 19%, disorders of consciousness in 11%, and neurological deficits in 11%. More than half of the brain CT scans (58%) were considered normal. The CT scans showing abnormalities were related to sequelae or non-evolving pre-existing abnormalities in 25.4%, evolving pre-existing abnormalities in 10.2%, newly discovered abnormalities in 64.4%. Brain MRI was performed in 18% of cases. Among the patients with abnormal brain CT scans, 41% had required emergency medical or surgical intervention. These were intracranial compressive processes, stroke and complicated central nervous system infections.

In our context, we found that 75% of brain CT scans complied with international recommendations, whereas 25% were prescribed despite of the recommendations.

In the light of our study, we assume that the implementation of the guidelines taking into consideration the conditions of each care facility, as well as adapted training for the attending physicians, would help in personalized decision making in pediatric emergencies, and could improve the use of CT among the pediatric population.

Key words: cerebral CT. neurological diseases, pediatric emergencies, child

Introduction:

Non-traumatic neurological emergencies include a wide variety of clinical situations: sudden focal deficit, headaches, impaired consciousness, delirium, seizures.

The principle of carrying out an emergency imaging examination is based on the urgency of the implementation of the treatment (surgical, medical or endovascular) which must make it possible to improve the vital or functional prognosis of the patient.

The CT scan is a tool widely used in the management of pediatric emergencies, more particularly in the diagnosis of intracranial pathologies, since it provides rapid answers, thus making it possible to make vital decisions.

Several studies have shown that brain CT is the most common test used in the pediatric population(1). On the other hand, recourse to abdominal and pelvic CT is predominant among the other age groups.(2.3).

Having your hands free for this exam, however, calls for caution. The advantages and disadvantages of the scanner for the patient and also for the health system must be well measured.

Indeed, in addition to the economic aspect linked to the additional costs generated by the multiplication of imaging, CT carries a significant risk of malignancy due to its ionizing radiation. Despite the declaration of the FDA (The Food and Drug Administration) that the probability of radiation-induced cancers from the doses delivered by the brain scanner remains low, no exposure to irradiation can be considered absolutely harmless.(4).

At a time when there are clear guidelines concerning the indication of brain CT in the context of head trauma, the same observation is not well established for non-traumatic

neurological emergencies.(4.5). This implies that the indications behind these brain scans can be more or less imprecise and CT scans are thus requested in excess.

The problem of the indication of the cerebral scanner and possibly the increase in its prescription motivated this evaluation of professional practices.

This is a study conducted in the pediatric emergency room of the mother-child hospital of the CHU Mohamed VI in Marrakech. It involved 141 files of patients for whom brain CT was indicated for a non-traumatic neurological emergency. Its purpose is to describe the conditions for prescribing brain CT, its indications and their compliance with international recommendations, as well as the results found and their implications for treatment.

Material and methods

This is a descriptive retrospective study, during a period of one year from January 2020 to December 2020, carried out in the pediatric emergency department at CHU MOHAMEDVI from Marrakesh

Patients admitted to the pediatric emergency department, between 1 month and 15 years old, having carried out a brain scan during their visit, outside of a traumatic context.

Our study initially consisted in describing the circumstances of prescription of the cerebral CT, then in deducing its indications from the anamnestic, clinical and biological data of each file including the good examinations if they were available.

Secondly, we assessed the validity of these indications by comparing them with the recommendations in the literature.

Our references in terms of recommendations were the French High Authority for Health (HAS), the French Society of Radiology, the Royal College of United Kingdoms of Radiologists (the UK Royal College of Radiologists) and the American College of Radiology (ACR).

Information was collected using patient records. A data sheet had been drawn up for each patient and made it possible to collect the data necessary for the analysis.

The various diagnoses were retained on the epidemiological, clinical, biological and radiological criteria.

The data collected was recorded on an Excel file and the statistical analysis consisted of calculations of quantitative variables described in the form of averages and qualitative variables in the form of frequency.

Results

-The number of CT scans performed in pediatric emergencies during the year 2020 was estimated at 1958 examinations.

-The brain scans prescribed in a non-traumatic context in 2020 numbered 205, thus constituting 10.5% of all CT scans performed in pediatric emergencies, i.e. an average of 17 brain scans in a non-traumatic context per month.

-The average age of our population was 2 years and 3 months with an interval of 45 days to 15 years.

-The sex ratio was 1.04; slightly in favor of boys (n=72).

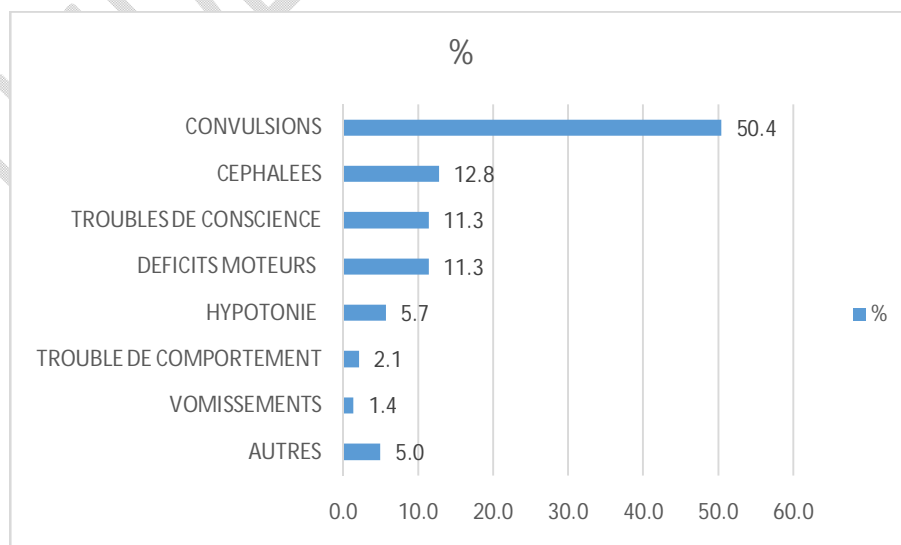


Figure 1: Percentage of CT scans performed by reason for consultation

✓ Convulsions therefore represented the main cause of consultation in patients who performed a cerebral CT scan in the pediatric emergency room (50.4%), followed by headaches (12.8%), motor deficits and disorders of consciousness which represented 11, 3% each.

-The Other category includes the following reasons: Acute loss of visual acuity

- Unilateral epistaxis, scalp mass, balance disorder, retro-auricular swelling.
- 63.8% of patients had no particular pathological history
- Among our patients, 65.2% were admitted in a febrile picture.

Consciousness disorders were found in 15 patients (10.6%) including 14 patients with a GCS between 14 and 10 (light coma) and one patient in a deep coma (GCS 6/15).

According to the context: febrile disorders of consciousness accounted for 7.1% (10 cases).

✓ **Meningeal syndrome:** Meningeal stiffness was found in 23 patients (16.3%), two of whom were afebrile and axial febrile hypotonia was found in 8 patients (5.7%), all of whom were under 2 years old.

✓ **Motor disorders:** A motor deficit was found in 24 patients (17% of cases).

✓ Focal signs were reported in 55 patients (39%).

✓ Partial seizures were found in 29 people (20.6%)

✓ Vestibular syndrome was reported in 2 patients.

- An ICHS syndrome was observed in 14 patients (10%), including: eight cases in a febrile context and 3 cases in patients followed for hydrocephalus.

-Among the admitted patients, 54.6% presented convulsions before or during the admission examination. Among these children, 64 cases or 45% cases were admitted for first seizure and 13 cases (9.2%) were followed for epilepsy.

-biologically: A lumbar puncture was performed in 78 patients (55.3%), of which 54 cases (69%) were in a febrile context.

-Concerning the PL results, 7 revealed CSF abnormalities.

- The ionogram concerned 113 patients (80%), of which 10 analyzes showed hyponatremia, followed by 3 cases of hypoglycemia and one case of hypocalcemia.
- ETF was performed in 5 patients aged 1 to 4 months. Two ETFs were normal while 3 showed moderate hydrocephalus.
- As for the prescribing physicians, they were dominated by pediatric residents with 124 CT scans, followed by those in neurosurgery (n=13).
- We note that 68% of cerebral CT scans were performed without injection of contrast product while 32% of CT scans were performed without and with injection.
- The indications for cerebral CT in our context were retrieved and grouped as follows:
 - ✓ The cerebral CT scans prescribed for comitiality constituted more than a third (38%) of all the CT scans studied, whether in status epilepticus, partial convulsions or generalized convulsions. The CT prescribed for ICHS syndrome accounted for 19%.
 - ✓ The cerebral CT scans prescribed for consciousness disorders were 15 (10.6%).
- Motor deficits and focal signs accounted for 11.3% of cerebral CT indications, while Among cerebral CT scans, 5 (3.5%) were indicated for headache

The rest of the brain CT scans (17%) were indicated for:

Table 1: Enumeration of unclassified cerebral CT indications

| Directions | Workforce |
|---|-----------|
| Search for contraindication to lumbar puncture | 9 |
| Suspicion of complicated meningitis | 1 |
| Acute decline in visual acuity | 1 |
| Behavioral problems | 1 |
| Psychomotor regression | 1 |
| Suspicion of cerebral venous thrombosis | 2 |
| Checking the ventriculoperitoneal shunt valve | 6 |
| Preoperative assessment for cephalic collection | 1 |
| Hydrocephalus at ETF | 1 |
| In total | 23 |

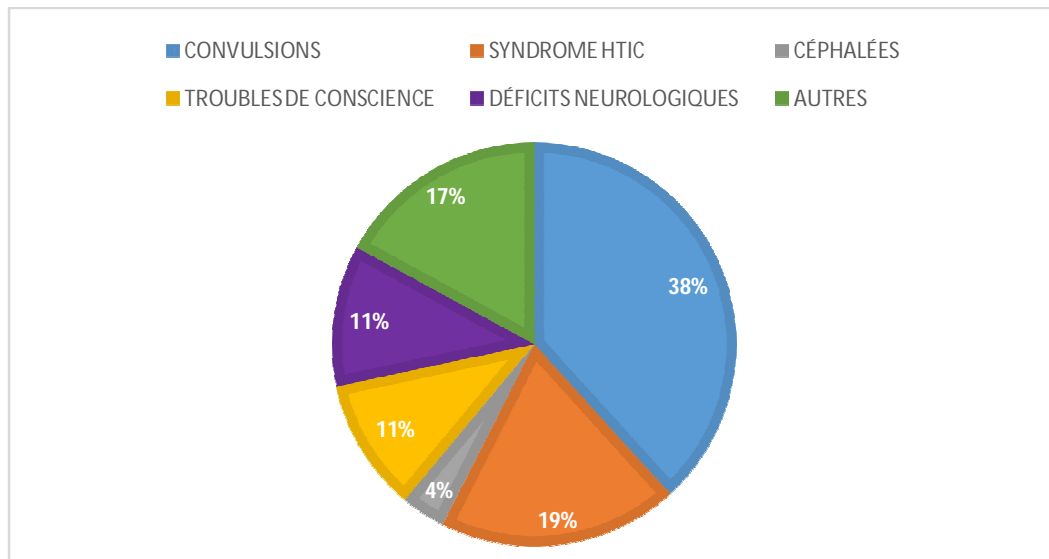


Figure 2: Simplified Classification of Cerebral CT Indications

The context of convulsions represented the largest proportion of brain scan requests (38%), followed by ICHS syndrome which represented 17%, then by consciousness disorders (11%) and neurological deficits (11%).

-More than half of brain CT scans (58%) were considered normal.

-15 cerebral CT scans objectified pre-existing or sequelae abnormalities, whose evaluation did not show any evolution or complications:

Table 2: Results of brain scans in patients without a history of brain abnormalities

| Results | Workforce |
|--|-----------|
| • Brain malformations and hydrocephalus | 7 |
| • Tumor causes | 6 |
| • Stroke | 6 |
| • ENT disorders (sinusitis, polyposis, etc.) | 5 |
| • Neuro-meningeal infections | 4 |
| • Inconclusive results: foci of hypodensities that may be of infectious or ischemic origin | 4 |
| • Cerebral cortical atrophy | 2 |
| • periventricular white matter hypodensity | 1 |
| • Scalp abscess | 1 |
| • Contusion focus without mass effect | 1 |
| • Status Epilepticus | 1 |

| | |
|------------|----|
| • In total | 38 |
|------------|----|

Table 3: Results of brain scans in patients with a history of progressive brain abnormalities

| Results | Workforce |
|---|-----------|
| Hydrocephalus on tumor process with onset of cerebral involvement | 2 |
| Subdural hematoma on derived hydrocephalus | 2 |
| Active derived hydrocephalus | 1 |
| Subdural empyema + ventriculitis on derived hydrocephalus | 1 |

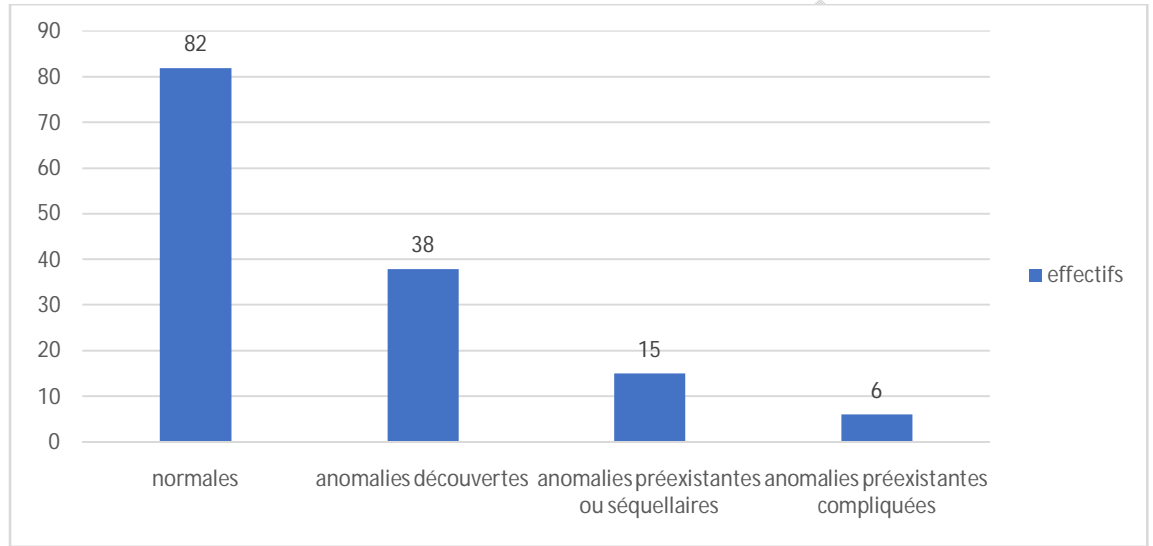


Figure 3 : Distribution of brain CT scans according to their results

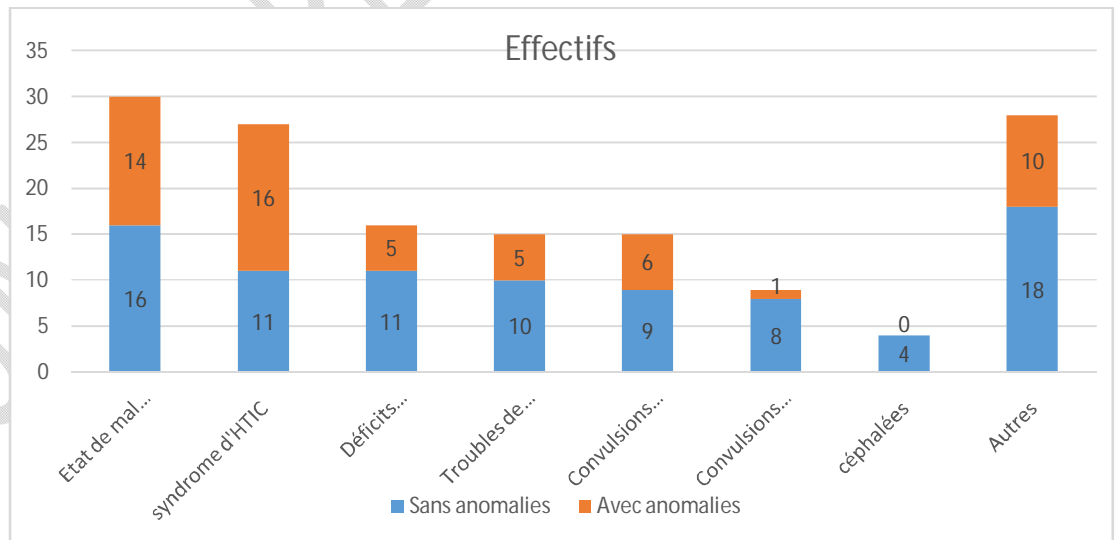


Figure 4: Distribution of brain scans according to indications and results

-Of 59 cerebral CT scans highlighting intracranial pathologies, 24 patients (41%) required emergency medical or surgical intervention. Among these patients 21 cases were related to

intracranial compressive processes, strokes and complicated central nervous system infections.

-IN TOTAL, percentage of patients requiring urgent intervention among pathological CT was 48%

-Almost two-thirds of patients have returned home (66%), 18% were hospitalized in pediatric wards and 5% in neurosurgery.

DISCUSSION

I. Evolution of cerebral exploration:

Evaluation of pediatric patients in the emergency setting is often restricted by limited history and physical examination, which often results in overlapping findings with multiple disease processes. Imaging therefore can play an essential role in establishing an accurate and rapid diagnosis. In addition to a clinical examination and with other investigations such as biological examinations.

Knowledge of the clinical and radiological manifestations typical of the most common pediatric emergencies and congenital anomalies allows the radiologist to interpret and identify the cause of the condition as well as the associated complications that may warrant immediate surgical management.

The specific imaging protocol depends on the suspected etiology and the patient's clinical status. X-ray, ultrasound, and CT scan may all be appropriate modalities for an initial examination. In specific cases, the use of magnetic resonance imaging makes it possible to better characterize the lesional process.

Medical imaging is also an essential element in clinical research, the study of diseases and the development of new treatments.

-As for the scanner, On October 1, 1971, the first cranial scan was performed in a London hospital. So progress was very rapid, and in 1973 scanners spread to the United States and Europe. In France, it was in 1975 that the first device was installed in Marseille. In Morocco, it was not until 1983 that the first device was installed at the CHU Ibn Rochd in Casablanca.

-During the year 2020, the number of CT scans performed in pediatric emergencies is estimated at 1958 examinations. The number then increases in 2021 to reach 2634 TDM, an increase of 34.5%. If we went back to the year 2019 we also found that the figure was high (2952 CT) compared to the year 2020.

-This difference can be explained mainly by the emergence of the COVID 19 pandemic and its repercussions on the conduct of the service's activities in order to comply with the established health measures.

-Most of the studies found in the literature are studies describing an increase in the prevalence of CT use in emergency departments without any real detailed description of brain CT activity(1,6,7).

-In our cohort, the average age was 2 years and 3 months with an interval of 45 days to 15 years. This joined the Machingaidze et al study(8) where the average age was 3 years and 3 months.

-In our series, the context of comitality was the indication for cerebral CT in 38% of cases, followed by the suspicion of ICHS syndrome in 19%. The study by Machingaidze et al(8) also reports that brain CT prescriptions were dominated by seizures in 54.3%.

-Concerning the results of our study, the cerebral scanner detected abnormalities in 42% of cases (59 CT scans). Hydrocephalus constituted 41% of the anomalies found, whether isolated or associated with other anomalies. Of which 27% were in patients with a shunt.

- As for the study by Machingaidze et al(8), she described a rate of brain CT abnormalities in 30.2% of cases. Hydrocephalus, as in our study, was the predominant abnormality in 57.4%, with 19.9% of patients being shunted.

- In our patients, 24 cases (17%) benefited from medical or surgical interventions following the results of the brain scan, of which 12 patients (8.5%) benefited from surgical treatment.

- The study by Machingaidze et al(8)also reports the performance of 47 surgical interventions (15.1%), predominated by ventricular drainage.

-In our study, eight patients (6%) had died. The mortality rate in the study by Machingaidze et al(8)was 2.6% (8 patients). The disparity between these two results may be due to the difference in the size of our samples.

-adults and children who consult the emergency department for an inaugural seizure are often evaluated by CT(9-11)

- Seizures are defined as "a transient occurrence of motor signs due to abnormally excessive or synchronous neuronal activity in the brain"(12).

-Epilepsy is one of the most common neurological disorders in children. It is defined by the occurrence of convulsive or non-convulsive seizures, recurrently and not caused by a known lesional process.

- The Centers for Disease Control and Prevention (CDC), estimates that approximately 470,000 (0.6%) of children under 17 have epilepsy and that approximately 50,000 new cases are diagnosed in this group of age each year in the United States(13).

-For Morocco, we have little information on this subject because very few studies have been published in this direction. A study done in 1989 established the prevalence of epilepsy in Morocco at 1.1%.(14). Another retrospective study was carried out in Rabat on the population of the epileptology consultation. According to this study, the frequency of epilepsy in the multidisciplinary consultation was estimated at 12% of cases, all consultations combined. The ages between 12 and 13 years were the most represented in the population of patients followed for epilepsy(15). A more recent study carried out in Marrakech, estimated that cases of childhood epilepsy represented 8.5% of pediatric department consultants.(16).

-Many authors affirm that cerebral CT finds all its importance in the evaluation of epileptic children only if MRI was not available at the level of the care structure. And that CT can fail to detect epileptogenic lesions in 41% of cases such as small tumors or vascular malformations.(22)

- ✚ Considering the controversial aspect of the indications of the cerebral scanner during the first convulsive episodes, some authors had concluded that the CT should not be systematically prescribed in the evaluation of the inaugural convulsions.(23.24)
- ✚ Given the heterogeneity of the clinical pictures of seizures and their management,

In our study, 56 cerebral CT scans were prescribed in the context of seizures with fever in patients aged 1 month to 15 years. Among these patients, 6 cases fulfilled the criteria for a simple febrile seizure and 22 cases had complex febrile seizures.

The main indication that seems to motivate the realization of cerebral CT in our study was the elimination of a contraindication to lumbar puncture, in particular an HTIC on an intracranial expansive process.

Indeed the main objective in the management of febrile convulsions is to manage the crisis first, then to seek the etiology of the fever. Central nervous system infections are the most serious and should be ruled out first based on history and clinical examination. The use of a lumbar puncture must be carried out in the slightest doubt.(25)

- in infants under 12-18 months or patients who have already started antibiotic therapy, the meningeal syndrome could be discreet or even absent, hence the interest of performing a systematic lumbar puncture in these patients(26)

- Neuroimaging (brain CT or MRI) is not routinely indicated in febrile seizures(24)

-it can be performed in patients for whom the complex febrile seizure is part of the differential diagnosis of seizures with other etiologies such as meningoencephalitis or suspected trauma(25.26)

- Some clinical signs can direct us towards the presence of cerebral anomaly:

- ✚ microcephaly, macrocrania, signs in favor of intracranial hypertension: (irritability and persistent drowsiness, uncontrollable vomiting, filling of the anterior fontanel in young infants, nerve paralysis), or quite simply a toxic appearance. Children who do not have these signs will not need neuroimaging to perform the lumbar puncture(24)

-In a cohort of 71 patients admitted for complex febrile seizures, ten children in whom brain CT was performed, in addition to 36 cases who underwent brain MRI one week after admission. No intracranial abnormality that would have required urgent medical or neurosurgical intervention was found in these patients.(25)

-In another study, children with recurrent febrile seizures within 24 hours had 7.45% of neuroimaging abnormalities; but none of the anomalies found made it possible to establish the origin of the convulsions or their prognosis.(25)

-From a practical point of view, the interest of using cerebral CT in complex febrile seizures could be determined by answering the following question:

✚ What important discovery that will require urgent intervention will bring us the immediate realization of the brain scan in this patient?(24.23)

-This method could also be used in all situations where the interest of emergency neuroimaging is questioned(22).

-In our study, among 28 children who had febrile seizures, 7 had abnormalities on the brain scan, of which only 3 cases (1%) required emergency medical or surgical intervention. These were the discovery of hydrocephalus, cerebral edema on Status epilepticus and suspicion of choroid plexus carcinoma. Our results were consistent with results from the literature.(10,11,24,).

-Indeed, retrospective studies have demonstrated different rates of use of neuroimaging in patients with complex febrile seizures. However, there were only a few children who presented abnormalities on neuroimaging, knowing that the scanner was used more than the MRI and that these abnormalities did not require additional medical or surgical interventions.

CONCLUSION

Brain computed tomography has revolutionized the diagnosis and management of pediatric neurological diseases.

Nevertheless, its prescription must be well regulated in order to avoid its harmful repercussions essentially linked to ionizing radiation.

In our context, we were able to show that physicians generally respected international recommendations concerning the prescription of brain scans in the context of non-traumatic emergencies.

The non-recommendation brain CT groups highlighted were related to; situations where the clinical examination and the anamnesis alone could explain the symptomatology or else in a context where a metabolic, hydroelectrolyte or toxic disorder was most likely to be incriminated. In addition brain CT prescribed for simple febrile convulsions or in epileptic patients with a normal neurological examination.

The request for CT is similar to that for a specialized clinical consultation and with a view to optimizing the prescription of brain imaging in the pediatric population, it would seem relevant to rely on anamnestic and physical elements to rule out etiologies of clinical diagnosis, to consider a period of hospital surveillance in situations where one hesitates on the benign or severe origin of the symptomatology and to favor the use of non-irradiating imaging techniques as much as possible.

The implementation of behaviors to be taken taking into account the conditions of each structure as well as adapted training would help in personalized decision-making in pediatric emergencies, and could make it possible to improve the use of the scanner in the pediatric population.

REFERENCES

1. **Mettler FA, West PW, Locken JA, Kelsey CA.**
CT scanning: patterns of use and dose. *J Radiol Prot.* 2000 Dec;20(4):353-9.
2. **Mettler FA, Bhargavan M, Faulkner K, Gilley DB, Gray JE, Ibbott GS, et al.**
Radiologic and Nuclear Medicine Studies in the United States and Worldwide: Frequency, Radiation Dose, and Comparison with Other Radiation Sources—1950–2007. *Radiology.* 2009 Nov 1;253(2):520–31.
3. **Khalifa M, Gallego B.**
Grading and assessment of clinical predictive tools for pediatric head injury: a new evidence-based approach. *BMC EmergMed.* 2019 Jun 14;19(1):35.
4. **Lyttle MD, Crowe L, Oakley E, Dunning J, Babl FE.**

Comparing CATCH, CHALICE and PECARN clinical decision rules for pediatric head injuries. *Emerg Med J* 2012 Oct;29(10):785-94.

5. **Larson DB, Johnson LW, Schnell BM, Goske MJ, Salisbury SR, Forman HP.**
Rising Use of CT in Child Visits to the Emergency Department in the United States, 1995–2008. *Radiology*. 2011 Jun;259(3):793-801.
6. **Menoch MJA, Hirsh DA, Khan NS, Simon HK, Sturm JJ.**
Trends in Computed Tomography Utilization in the Pediatric Emergency Department. *PEDIATRICS*. 2012 Mar 1;129(3):e690-7.
7. **Machingaidze PR, Buys H, Kilborn T, Muloiwa R.**
Clinical use and indications for head computed tomography in children presenting with acute medical illness in a low- and middle-income setting. Ashkenazi I, editor. *PLOS ONE*. 2020 Sep 28;15(9):e0239731.
8. **Maytal J, Krauss JM, Novak G, Nagelberg J, Patel M.**
The Role of Brain Computed Tomography in Evaluating Children with New Onset of Seizures in the Emergency Department. *Epilepsy*. 2000;41(8):950-4.
9. **Warden CR, Brownstein DR, Del Beccaro MA.**
Predictors of abnormal findings of computed tomography of the head in pediatric patients presenting with seizures. *Ann Emerg Med*. 1997 Apr;29(4):518-23.
10. **Itri M, Hadj Khalifa H.**
Epidemiological survey of childhood epilepsies. *Doctor's notebooks; Flight 1; Issue 9; 36 – 38; 1998.*
11. **Kissani N, Belaidi H, Othmani M.**
Comparison of the profile of epileptic patients in Morocco several years apart. *Rev Epilepsies* 2001; Flight 13; 251 - 257; 2001.
12. **Bourrous M.**
Characteristics of children with epilepsy followed at the University Hospital of Marrakech [Internet]. *EM-Consult*. [cited 2022 Mar 12]. Available at: <https://www.em-consulte.com/article/270718/caracteristiques-des-enfants-ayant-une-epilepsie-s>
13. **Gastaut H.**
Dictionary of epilepsy. Geneva Switzerland World Health Organisation.;
14. **16 Outin H, White T, Vinatier I.**
Management in emergency situations and in resuscitation of status epilepticus in adults and children (newborn excluded). Formalized recommendations from experts under the aegis of the French-language Resuscitation Society☆. *Intensive care*. 2009 Jan;18(1):4-12.
15. **Chen JWY, Wasterlain CG.**
Status epilepticus: pathophysiology and management in adults. *Lancet Neurol*. 2006 Mar;5(3):246-56.
16. **Russo LS, Goldstein KH.**

The diagnostic assessment of single seizures. Is cranial computed tomography necessary?
Arch Neurol. 1983 Nov;40(12):744-6.

17. Leung AK, Hon KL, Leung TN.

Febrile seizures: an overview. DIC. 16 Jul 2018;7:1-12.

18. Depiero AD, Teach SJ.

Febrile seizures. Pediatr Emerg Care. 2001 Oct;17(5):384-7.

19. Subcommittee on Febrile Seizures,

American Academy of Pediatrics. Neurodiagnostic evaluation of the child with a simple febrile seizure. Pediatrics. 2011 Feb;127(2):389-94.

20. cristina victori.

Febrile seizures - Pediatrics [Internet]. MSD Manual Professional Edition. [cited 2022 Jan 13]. Available at: <https://www.msmanuals.com/fr/professional/p%C3%A9diatrie/neurological-disorders-in-children-convulsions-f%C3%A9briles>

21. Fetveit A.

Assessment of febrile seizures in children. Eur J Pediatr. 2007 Nov 21;167(1):17-27.

22. Leung AKC, Robson WLM. Febrile Seizures. Journal of Pediatric Health Care.

2007 Jul;21(4):250-5.

23. DiMario FJ.

Children presenting with complex febrile seizures do not routinely need computed tomography scanning in the emergency department. Pediatrics. 2006 Feb;117(2):528-30.

24. Teng D, Dayan P, Tyler S, Hauser W, Chan S, Leary L, et al.

Risk of Intracranial Pathologic Conditions Requiring Emergency Intervention After a First Complex Febrile Seizure Episode Among Children. Pediatrics. 2006 Mar 1;117:304-8.

25. Yucel O, Aka S, Yazicioglu L, Ceran O.

Role of early EEG and neuroimaging in determination of prognosis in children with complex febrile seizure. Pediatr Int. 2004 Aug;46(4):463-7.