

Case report

NATURE'S CURE – BIOMIMETICS FOR APEXIFICATION

Abstract

Teeth with open apices present a continuing challenge to even the most experienced dentists. The lack of an apical stop makes obturation and achieving a good apical seal more difficult. Apexification is seen to be the best option for treating such instances. In the past, calcium hydroxide was commonly employed for apexification. However, the drawbacks of long treatment times, tooth fracture, and incomplete calcification of the apical bridge have led to the development of newer biocompatible materials such as MTA as the material of choice due to its superior clinical properties and clinical success in hermetically sealing the pulp space and preventing bacterial contamination from the outside. The existence of a damaged upper central incisor is highlighted in this case report. The radiographic examination revealed blunderbuss apices, the canal was cleaned using intracanal instruments and 3% NaOCl and saline. Following that, 3-4 mm of MTA was applied and left to set in consecutive sessions. The root canals were then obturated with a thermoplasticized approach before being recalled for endodontic repair. As a result, the use of MTA as an apical stopper in teeth with an open apex has a favourable clinical outcome.

Keywords – apexification, MTA, thermoplasticized, blunderbuss, plug

INTRODUCTION

"The maxillary anterior teeth are prone to many impact injuries because of their position in the jaw. In endodontic practice, the apical 3-4 mm is the most important. When the enamel and dentin reaches the cemento-enamel junction, a cervical loop forms, from which root growth begins. If the pulp becomes necrotic as a result of trauma or caries exposure, dentin production stops and root growth is halted. Endodontic treatment of a tooth with an open apex and necrotic pulp involves a number of complications" [1]. These teeth have apical anatomy that is characterized by larger width at the apical region, lack of apical constriction, and thin dentinal walls. Endodontic treatment for these teeth necessitates full bacterial removal from the root canal as well as prevention of re-infection of the canal space. Standard root canal techniques cannot be used to clean and disinfect the infected root canal [2].

Apexification is a treatment modality for apical healing that involves the creation of a hard tissue barrier through the apex. Traditionally, a calcium hydroxide (CaOH₂) mixture is used to

induce a calcified barrier. However, calcium hydroxide has several drawbacks, including inadequate calcification of the dentinal bridge and a protracted treatment time (5 to 20 months), which may cause patient compliance issues[2,3]. There is a risk of reinfection due to the breakdown of the coronal seal between sessions, and long-term usage of calcium hydroxide weakens the tooth's fracture resistance, making it more susceptible to fracture. In light of these disadvantages, single-visit apexification is recommended for management of teeth with an open apex[4].

This report describes the management of a tooth with open apex managed with apical barrier technique.

CASE REPORT

A 26 year old, male patient, reported to the Department of Conservative Dentistry and Endodontics in DY Patil School of Dentistry, Navi Mumbai with a chief complaint of discolored tooth in the upper front tooth region (Fig 1). History revealed that the patient had suffered trauma around the age of 10 years. Clinical examination revealed Ellis class IV fracture in the maxillary left central incisor and discoloration. Radiographic examination demonstrated incomplete root formation (blunderbuss canal) with periapical radiolucency in relation to 21 (Fig 2). Tooth gave no spontaneous pain/positive response to thermal tests which was suggestive of non vital tooth. Root canal treatment using MTA as an apical plug followed by obturation with thermoplasticized gutta-percha was planned.

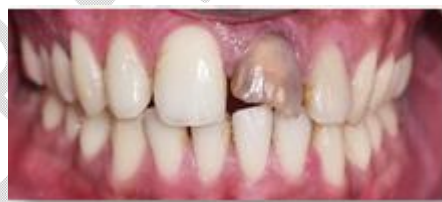

Figure 1 - Pre operative view shows discoloration present in 21

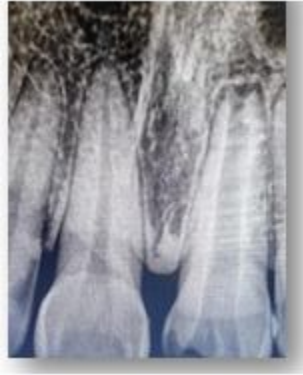

Figure 2: Intra operative radiograph – 11 and 21

In the first session, standard endodontic access was made from the palatal aspect in relation to 21 after the rubber dam isolation (Fig 3). Initial working length was predicted by using paper point method. Then radiograph was made and working length was confirmed (Fig 4). Cleaning and shaping was done with circumferential filing up to #80 K-file. The canal was irrigated with 3% of sodium hypochlorite (Prime Dental Products Pvt. Ltd., Thane, India) and saline. Canal was dried with multiple absorbent points and calcium hydroxide dressing (RC Cal; Prime Dental Products Pvt. Ltd., Thane, India) was placed. Access was sealed with Cavit (3M/ESPE, Seefeld, Germany).and patient was recalled.

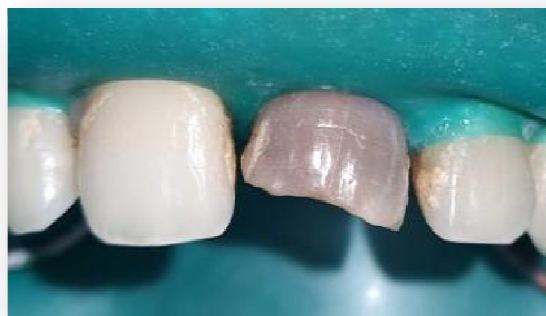

Figure 3- rubber dam isolation

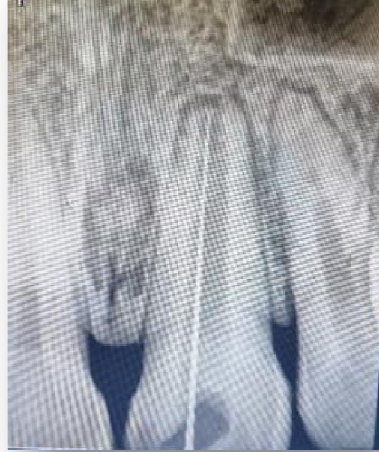

Figure 4 – Working length determination

One week later, tooth was again isolated and canal thoroughly irrigated with saline to remove any remnants of calcium hydroxide. The canal was dried with sterile paper points. Following the drying of the canal, MTA (Dentsply Tulsa Dental, Tulsa, OK, USA) powder was combined with distilled water and then transferred into the canal using an amalgam carrier and packed using hand pluggers to establish an apical plug of about 4 mm, followed by a confirmation radiography (Fig 5). A moistened cotton pellet was applied over the canal orifice and the tooth was temporarily restored. Subsequently, backfill was performed using thermoplasticized gutta-percha (Calamus) in association with AH Plus sealer (Dentsply; Detrey, Konstanz) (Fig 6).

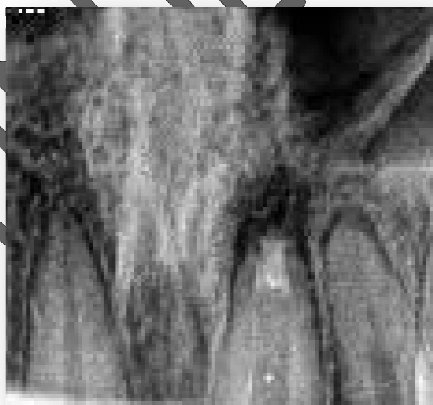

Figure 5 – MTA plug

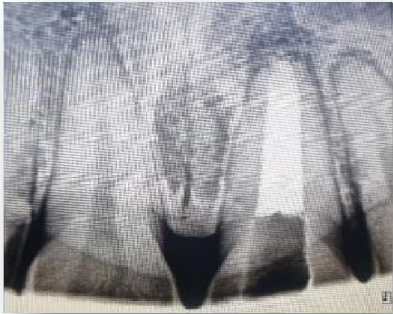


Figure 6 – Obturation using thermoplasticized technique

Water-soluble cream (Vaseline) was applied to soft tissues to protect the gingiva, and rubber dam isolation was achieved; subsequently, 2-3 mm of gutta-percha was removed in an apical direction beyond the cemento-enamel junction. 2-3 mm glass ionomer cement foundation was placed over the gutta percha to ensure a barrier between the sealed root canal and the bleaching gel (mechanical seal). Non vital bleaching with 35% hydrogen peroxide gel (Pola office, SDI, Australia) was done. The bleaching agent was expressed into the opened pulp chamber and on the labial surface, and curing light was applied to activate the bleaching gel from the labial and palatal sides. The gel was changed and repeated until desired results were obtained (Fig 7 and 8). Clinical evaluation was recorded by comparing the tooth shade with its original one before treatment using the Vita classic shade guide and photographs⁶.

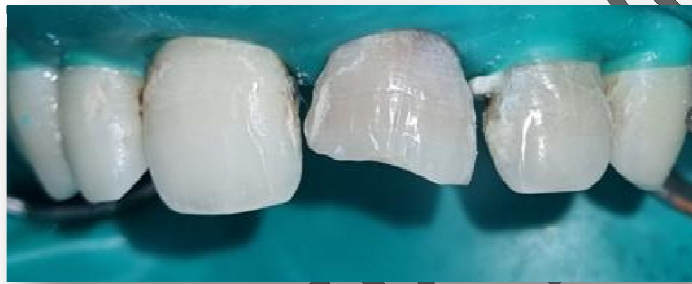

Figure 7- Non vital bleaching in relation to 21

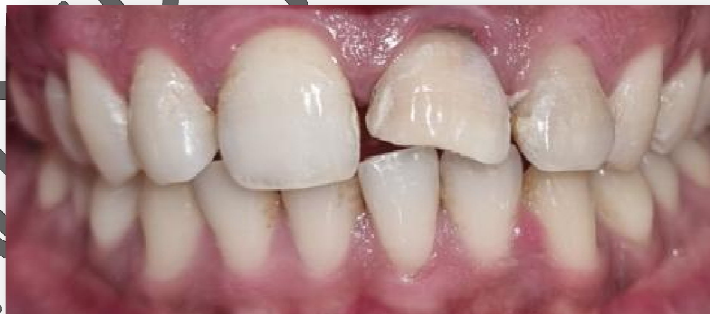

Figure 8 – after bleaching (21)

E-max crown(Lithium disilicate) was chosen to repair the maxillary anterior tooth to meet the patient's aesthetic and functional needs (Fig 9), taking into account the patient's age, career, and interest in and understanding of the newest available restorative material.

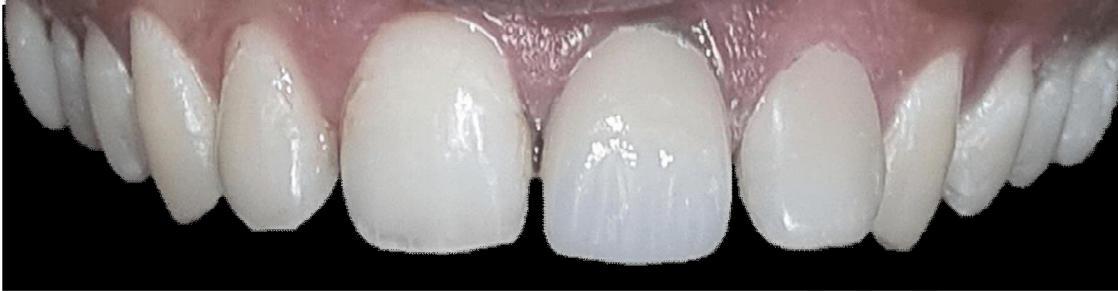

Figure 9 – Fabrication of the E-max crown in 21

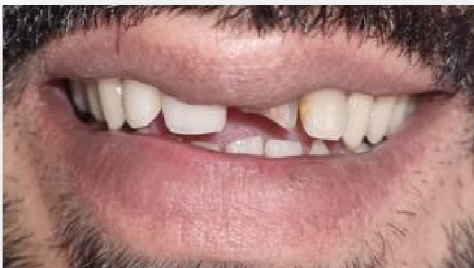

Figure 10- Pre operative smile

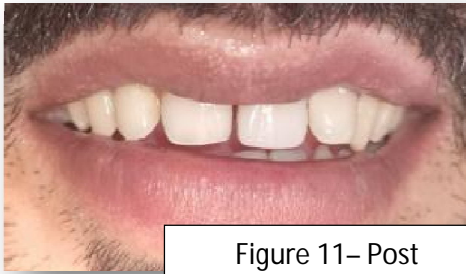


Figure 11– Post operative smile

DISCUSSION

The traditional apexification procedure or revascularization are two endodontic therapy options for teeth with open apex. Pulp revascularization is an excellent therapeutic option for such situations, since it allows more root growth and dentinal wall reinforcement, however it is usually limited to individuals aged 8–16 years. The therapeutic option of apexification was chosen here, taking into account the patient's age[5,6].

For the induction of an apical calcific barrier, calcium hydroxide has been the substance of choice[7]. However, it has several disadvantages, such as the time it takes to build an apical barrier, which can range from 5 to 20 months, patient compliance, the risk of reinfection owing to the loss of a temporary restoration in between treatments, and the tooth's fracture resistance[8]. MTA is a good alternative for getting consistent and predictable outcomes. By creating a hard-tissue barrier, MTA can help in maintaining normal periradicular architecture[9]. Its great biocompatibility, capacity to set in the presence of blood, and ability to rebuild teeth with minimum delay without affecting dentine mechanical qualities, as observed with continuous usage of calcium hydroxide, make it even more acceptable. Moisture contamination at the apex of the tooth prior to barrier development is a common issue with alternative apexification materials[10].

Because apex locators have shown inconsistent findings in open apices, working length was determined using the paper point approach in this case report following access

preparation[11]. Baggett *et al* evaluated “a tactile technique using paper points and claimed it to be comparable to radiography and unaffected by the size of the apex or the presence of periapical pathology. The technique involved using a size 30 paper point placed in the canal and advanced until resistance was felt. The authors found that this method was accurate to within 1 mm of the radiographic diagnostic length 95% of the time and concluded that a working length radiograph was unnecessary when this method was employed”[12].

The broad canal was instrumented with a #80 H-file circumferentially to adequately clean it without exerting excessive pressure to avoid fracture of the thin dentinal walls. Irrigation with 3% NaOCl was used in the interim. “Irrigation cannot be done actively because there is a risk of irrigant extrusion beyond the apex. One of the proposed safe irrigation techniques for teeth with immature or open apices is negative apical pressure. This technique may avoid extrusion of irrigants beyond the apex, but it is not as powerful as the other techniques in pushing the irrigants inside the lateral anatomies and dentinal tubules. When treating teeth with immature apices associated with periapical lesions, the resistant biofilms can be formed in the main canal and deep inside the lateral anatomies and dentinal tubules. For this reason, it is critical to use high-performance activation techniques for irrigants. Consequently, the collagen apical barrier (CAB) technique, has been developed. This technique permits irrigants activation, in case of an open apex, without risking the extrusion”[13].

“In contrast to lateral condensation, obturation was accomplished with thermoplasticized gutta-percha, which may be applied without applying any compaction stresses on thin dentinal walls in contrast to lateral condensation method”[14].

CONCLUSION

MTA as an apical plug minimizes the number of appointments, prevents micro leakage, has great biocompatibility and serves to contain the obturating material without impinging on the periodontal tissues and achieve a fluid-tight seal. Crowns can be given subsequently to prevent coronal microleakage, thereby contributing to endodontic success.

Consent

As per international standard or university standard, patient(s) written consent has been collected and preserved by the author(s).

Ethical Approval:

As per international standard or university standard written ethical approval has been collected and preserved by the author(s).

REFERENCES

1. Muhamad, Abu-Hussein & Abdulgani, Azzaldeen & Abdulgani, Mai. (2016). Open Apex with Mineral Trioxide Aggregate- Case Report. IOSR Journal of Dental and Medical Sciences, October. 2016, Volume 15, Issue 10, PP 81-87
2. Beliz Özel,¹ Raif Erisen², Management of non-vital anterior teeth with open apex: A report of two cases, Turk Endod J 2020;5(1):7–10 doi: 10.14744/TEJ.2020.09609
3. Veedu RP, Nair KR, et al. Endodontic Management of Tooth with Open Apex Using MTA as an Apical Barrier: A Case Report. Cons Dent Endod J 2019;4(1):14–17.
4. Sanjana A Patil, ² Avinash A Patil, ³ Preeti K Dodwad, Management of Non-Vital Teeth with Open Apices using MTA as an Apical Plug: Two Case Reports, World Journal of Dentistry, January-March 2011;2(1):45-48
5. Koh ET, Torabinejad M, Pitt Ford TR, Brady K, McDonald F. Mineral trioxide aggregate stimulates a biological response in human osteoblasts. *J Biomed Mater Res.* 1997;37(3):432-439.
6. Abdelkader NN. Modified Technique for Nonvital Tooth Bleaching: A Case Report. *Electron Physician.* 2015;7(6):1423-1426. doi:10.14661/1423
7. Manawar Ahmad^{1*}, Hina Naim¹, Hussain Hadi Hussain AlSagoor², Mohammad Ali Zailai Alomar², Ali Mohammed Bakri Madkhali² et al, Reconstruction of esthetically compromised maxillary anterior teeth with CAD CAM zirconia crowns – A case report, Dent Oral Craniofac Res, 2017, Volume 3(5): 1-4, DOI: 10.15761/DOCR.1000214
8. Wigler R, Kaufman A, et al. Revascularization: a treatment for permanent teeth with necrotic pulp and incomplete root development. *J Endod* 2013;39(3):319–326. DOI: 10.1016/j.joen.2012.11.014
9. Sheehy EC, Roberts GJ. Use of calcium hydroxide for apical barrier formation and healing in non-vital immature permanent teeth: a review. *Br Dent J* 1997;183(7):241–246. DOI: 10.1038/sj.bdj.4809477.
10. Giuliani V, Baccetti T, Pace R, et al. The use of MTA in teeth with necrotic pulps and open apices. *Dent Traumatol* 2002;18:217-21
11. Dr. Fahd A A Karim , Dr. Kazi Hossain Mahmud, Dr. Asma Sultana, Dr. Shirin Sultana Chawdhari, Dr. MuktaDir Hossain Shaihan Mohamed et al, Management of non-vital anterior tooth with open apex by MTA apical plug -A case report. *Update Dental College Journal.* 2019 April; 9(1): 42-45

12. Kim, Y-JA, Chandler, NP. Determination of working length for teeth with wide or immature apices: a review. *International Endodontic Journal*, 46, 483– 491, 2013
13. Iandolo A, Amato A, Pantaleo G, Dagna A, Ivaldi L, di Spirito F, Abdellatif D. An innovative technique to safely perform active cleaning in teeth with open apices: CAB technique. *J Conserv Dent*. 2021 Mar-Apr;24(2):153-157. doi: 10.4103/jcd.jcd_42_21. Epub 2021 Oct 9. PMID: 34759581; PMCID: PMC8562844.
14. Jahnvi B, Reddy KS, Prasad SD et al . Management of open apex using MTA and reinforcement of weekend root with customized fiber post a case report . *Int J Health Sci Res*. 2017; 7(7): 370375 .

UNDER PEER REVIEW