

Bone involvement in pediatric acute myeloid leukemia: what can we currently infer?

Abstract:

Introduction: Acute myeloid leukemia (AML) is a clonal disease of the hematopoietic tissue characterized by abnormal proliferation of myeloid lineage progenitor cells, resulting in insufficient generation of normal mature blood cells.

Bone pain is often present at the diagnosis of pediatric acute lymphoblastic leukemia but is very rare in acute myeloid leukemia. It may also indicate the presence of pathological fracture, lytic lesions, arthritis, or associated osteitis, which may delay diagnosis.

Objective: To study the incidence of children with acute myeloid leukemia (AML) with bone involvement. Clinico-biological description and analysis of the prognostic impact of age, sex, treatment, type of bone involvement associated with acute myeloid leukemia.

Methodology: This partly prospective/retrospective descriptive study included 17 children with AML diagnosed at the Department of Hematology and Pediatric Oncology CHU Mohamed VI Marrakech Morocco, during the period from March 2011 to November 2021. A form gathering the main items necessary for the study was made for 17 cases.

Results: In order to describe the bone involvement (BA) in pediatric AML, we reviewed the records of 47 patients followed in our unit for AML. The overall incidence of OA was 36.17% or 17 cases. At diagnosis, patients had a revealing AO in 47.05% of cases, i.e. 8 cases,

one of which, the diagnosis of AML was delayed by 6 months. During and after treatment, respectively 23.5% and 29.4% of patients presented bone complications (bone pain, vertebral compression, osteolysis).

The average age of the patients with AO was 8.5 years. A predominance of female gender at 52.94% (9 cases).

In our study, the majority of AO were resolved after AML treatments without short-term sequelae. However, a death rate was marked at 58.80% (10 cases).

Keywords: Acute myeloid leukemia. Bone involvement, chemotherapy, Child

Introduction

Approximately 40% of childhood cancers are leukemias and 15% of these are acute myeloid leukemias (AML). Although the first descriptions of isolated musculoskeletal involvement as the inaugural manifestation of pediatric AML date back to 1913 (1), this mode of presentation remains a diagnostic challenge because the signs of such involvement are not specific to leukemias. According to the literature, the prevalence of the various possible inaugural bone disorders (pain, fracture, lytic lesion, arthritis, etc.) at the time of diagnosis of AML varies from 11% to 19% (2) and are sometimes isolated. Among the mostly common musculoskeletal pain in children, it is essential to identify those caused by cancer, because an erroneous diagnosis of orthopedic, rheumatic or infectious disease may lead to the administration of corticosteroids. Corticosteroids, by inducing a temporary remission, delay the diagnosis and worsen the prognosis of AML, which will then be more difficult to cure when it recurs, or cool the disease down until metastasis and death occur. The cause of inaugural bone damage (OA) and bone complications in AML is multifactorial: related to the patient, the disease or the treatments (3-

9). Promoting factors identified so far are AML of immunophenotype type 3 for inaugural involvement, age ≥ 10 years and female gender for osteonecrosis and osteolysis (8). The bone toxicity of anti-leukemic treatments such as glucocorticoids is well recognized. The improvement in the survival rate of children with AML is less because the treatment of acute mesoblastic leukemia has progressed less in children over the last twenty years and the best results are currently obtained using intensive protocols combining essentially aracytin and anthracyclines. The value of bone marrow transplantation in first complete remission from a geno-identical donor has been demonstrated in children. Cure is obtained in 50% of cases of acute myeloid leukemia in children (10). However, AML has a poor prognosis with a survival of 30% at 5 years in young subjects and children. (11)

Currently, the analysis of AO associated with leukemia justifies the search for a reduction in the toxicity of treatments such as bone demineralization and its consequences (pain, fractures) or avascular necrosis (AVN). The incidence of AVN, previously estimated at 2 to 9% according to retrospective studies (8), could be around 24% according to a prospective study (10). The severity of this complication is underlined by the need for joint replacement surgery in a quarter of affected patients (11). The question of how to reduce the incidence of bone complications without reducing the efficacy of treatment is therefore not clearly defined. The overall prognostic value of inaugural OA is not clear (2, 8). In addition, severe OA requires immobilization to reduce the risk of weight-bearing aggravation (vertebral fracture, neurological injury) that impairs the quality of life of children with leukemia.

The aim of this retrospective study, involving a cohort of children with AML treated in our unit between 2011 and 2021, is to determine the incidence of OA in this population from diagnosis to the end of treatment, to describe their clinical, biological and radiological

characteristics, to analyze the factors favoring their occurrence and to compare these data with those of the literature

Material and method

Among patients with AML admitted and treated between 2011 and 2021 in our Pediatric Hematology-Oncology Unit of the Mohammed VI University Hospital Center in Marrakech, Morocco, 47 records with analyzable clinical data were included and retrospectively reviewed. The following clinical data were analyzed: age at diagnosis, sex, and history of pathology. All patients underwent clinical and biological evaluation at diagnosis according to international standards: morphological examination, biological analysis, immunophenotyping and standard cytogenetics. The characteristics of their disease were analyzed. Each patient was treated according to the AML treatment protocol established in our unit at the time of diagnosis (AML 2003, AML2011). No patient received a hematopoietic stem cell transplant. The occurrence of relapse, death and duration of follow-up were also analyzed. For each patient, the presence of one or more OA at the time of diagnosis, during or up to 6 months after the end of anti-leukemic treatments, and their location were analyzed. The following were considered as OA: bone pain (DO), lameness, fracture, osteolytic lesion, NAV, arthritis, bone densitometry abnormality (BMD measured by biphoton X-ray absorption) such that osteopenia was considered statistically significant. Different variables were compared. Epidemiological data were analyzed and compared according to the time of onset of OA.

Statistical analyses: For our entire cohort, data are expressed as mean or number and frequency (percentage). A database was established to group and compare all descriptive and analytical elements.

Results

The characteristics of the 17 patients are presented in Table 1. Our cohort was almost half female (52.94%). It was a prepubertal cohort, with 53% of the children older than 10 years at diagnosis.

The mean age was 8.5 years with extremes ranging from 2 to 15 years. 76.47% of the patients were of urban origin, i.e. 13 cases, whereas 23.52% of the cases, i.e. 4 cases, were from rural areas.

Consanguinity was 17.64% or 3 cases (1st degree) and the average delay of consultation in the pediatric hematology-oncology department was 1 month and 17 days

Bone involvement was present in all patients in our study, patients had a revealing AO in 47.05% of cases, i.e. 8 cases, of which one of them, the diagnosis of AML was delayed by 6 months. Thus, OA was prominent during and after treatment, respectively by 23.5% and 29.4%.

Only 5.88% of the children in this cohort had a significant osteoarticular history, i.e., only 1 case: chronic arthralgias diagnosed as juvenile idiopathic arthritis (n = 1). Promyelocytic AML3 in 35.29% of cases, i.e. 6 cases. Detection of specific immunophenotypic markers (CD13, CD33, CD34, CD117) by immunophenotyping was positive in 7 cases, i.e. 41%, and not done for the rest. As well as the cytogenetic abnormalities commonly observed in our series included the following rearrangements: trisomy 21, t (8 ;21), inv. (16) or t (16;16) and Philadelphia Chr and this was done in only 5 cases or 29.41%.

3 patients among those whose karyotype was done had an unfavorable prognosis (3 cytogenetic anomalies)

29.40% of the patients had metastases, i.e. 5 cases (two pulmonary locations, two spinal locations and one osteomedullary location)

Laboratory data related to the diagnosis of AML (leukocytes, platelets and neutropenia) and to the morphological classification of FAB are described in the table

9 patients completed their chemotherapy treatment, i.e. 52.90%. However, only one patient did not receive any treatment (delayed diagnosis with death before initiation of therapy). In total, the evolution was marked by: a cytological remission of 11.70%, i.e. 2 cases, 29.41% of the patients relapsed, i.e. 5 cases, 11.7% of recurrence, i.e. 1 case, 11.7% of loss of sight, i.e. 1 case (patient not present at the consultation with a non-functional telephone number), none of the patients were transplanted in first complete remission or in relapse. Ten patients died, i.e. 58.80% (one of them died at home before the start of therapy and another during the induction phase). The main causes of death were infections, bleeding episodes, leukostasis and tumor lysis syndrome.

The median follow-up of our cohort is 9 years.

Le suivi médian de notre cohorte est de 9 ans.

Signs/symptoms	Number of cases	percentage
Anemic syndrome	17 case	100%
Hemorrhagic syndrome	15 case	88.35%
Tumor syndrome	15 case	88.35%
Infectious syndrome	13 case	76.47%
Alteration of the general state	17 case	100%
Bone pain	17 case	100%
Respiratory symptomatology	1 case	5.88%

Table 1: Signs and symptoms at diagnosis in number (n) and percentage (%) of patients with acute myeloid leukemia

Number of GB	Number of cases	percentage
<i>t</i> <10,000	6 cases	35,29%
10,000---50,000	8 cases	47,05%
>50,000---100,000	2 cases	11,76%
>100,000	1 cas	5,88%
FAB Classification		
M0	0 Cas	0 %
M1	1 Cas	5,88%
M2	1 Cas	5,88%
M3	4 Cases	23,5%
M4	3 Cases	17,64%
M5	1 Case	5,88%
M6	0 Case	0%
M7	0 case	0%
N.B imunophénotypage non fait dans 10 cas		

Table2: hematological abnormalities

General description of patients with bone involvement:

Among the 64 children in our study, 17 cases or % had one or more episodes of OA: episode at the time of diagnosis for 8 /17 patients or

47.05%, during treatments for 4/17 or 23.52% or after treatments for 5/17 or 29.47%. Most of the patients were diagnosed at the time of diagnosis. The patients with AO did not have BMD. At the time of diagnosis, 8 patients had OA: 5 with isolated OD, 1 with isolated lameness, 2 with vertebral compression, while arthritis, osteitis or osteomyelitis were not objectified. When they had bone or joint pain at diagnosis, 94% (16/17) of the patients had a work-up (X-rays, CT scan, MRI) among the examinations that were performed. MRI among the examinations that proved abnormal in patients followed by AML with AO plus, we objectified necrosis of the rock, otomastoiditis, lytic bone lesions of the internal extremity of the right clavicle blowing the bone cortex, cortical rupture and settlements of the vertebral bodies. In patients with DO at diagnosis and normal workup, OA occurred during or after treatment. In 52.14% (9/17) of the patients, no BMD was performed at diagnosis without having any bone complaint.

The characteristics of the 3 groups of patients according to the time of occurrence of OA are shown in **Table III**. Although the differences were not statistically significant, patients with OA during AML treatments were more often girls and patients >10 years old than in the full cohort.

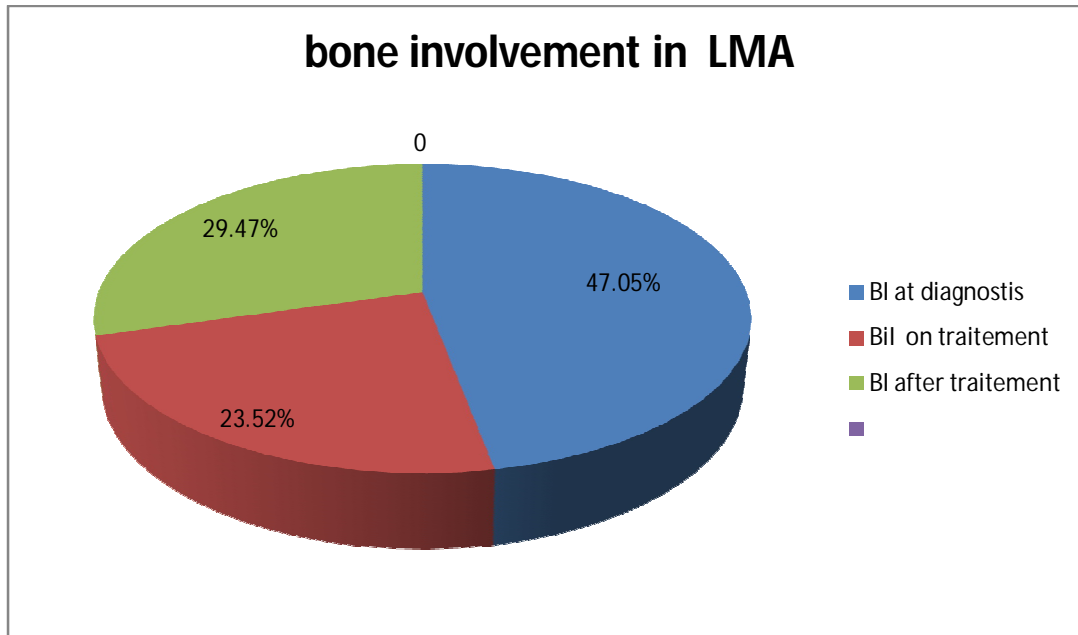


Figure 1: Characteristics of pediatric AML patients with bone involvement at diagnosis, during or after anti-leukemia therapy

2. Location of bone involvement: Patients who presented with AML with OA (OD, bone pain. The location of bone pain was 53% in the lower limbs with accentuation in the pelvic girdle, 24% in the back and 20% in the upper limbs.

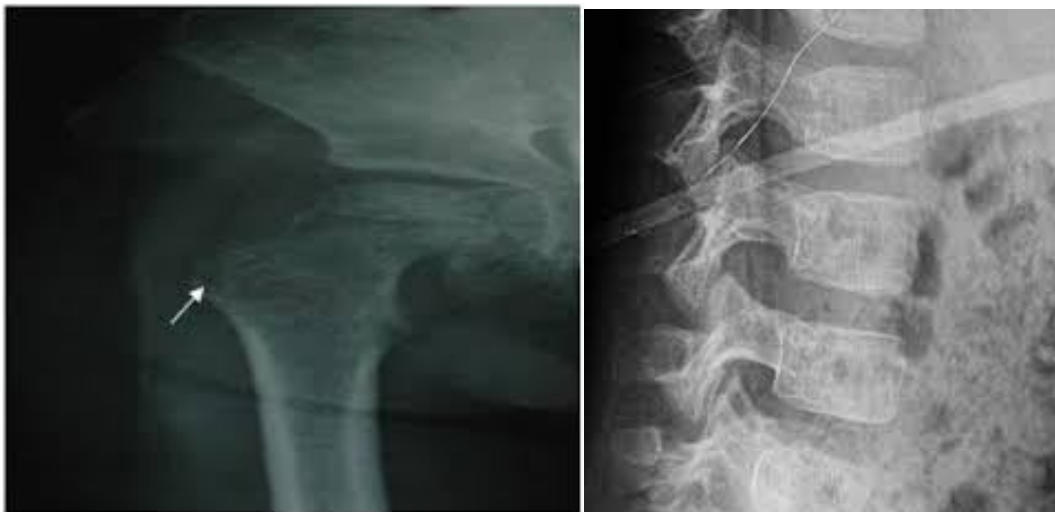

figure 2 : bone demineralisation of the femoral head
 figure 3 : 5-year-old patient with LLA (standard radiography with compression of L5)

- In total, patients with OA received at least one symptomatic treatment based on analgesics: paracetamol and morphine. Among patients with OA, none received calcium and vitamin D supplements or biphosphonate treatment.
- For living patients, no other long-term sequelae after treatment were found in our cohort and no neurological complications were noted following vertebral compression.

Discussion

Musculoskeletal disorders in children are frequent, mostly transient and benign. However, some of them are the inaugural signs of a cancerous disease and the absence of associated pathognomonic signs may lead to a delay in diagnosis and to therapeutic errors. Some studies estimate the incidence of cancer in musculoskeletal diseases to be less than 1% in a series of children with arthritis (12), or 3.7% among children referred to an infectious diseases clinic (13). In the latter series, 2.3% had AML. In our series, no patient received corticosteroids before the diagnosis of AML was made, but for several children, the delay before a marrow aspiration revealed AML was significantly long. According to Zombori et al. (14), certain warning signs may raise the suspicion of cancer with a musculoskeletal complaint: atypical location of pain, disproportion between pain intensity and normal imaging, any abnormality on the blood count, elevated LDH, presence of adenopathy/hepatosplenomegaly. In our study, the incidence of OD was 24% at diagnosis, which is comparable to the figures in the literature (9, 15, 16), and the overall incidence of symptomatic OA of 31% in our series is consistent with the 47% rate of OA reported by Tragiannidis et al. (2). Chell et al. (17) even report an incidence of bone necrosis around 1% and OD in 99% of cases. Marwaha et al. (18) describe that 6% of patients with AML had an inaugural presentation of juvenile idiopathic arthritis. A high prevalence of vertebral involvement or fractures (thoraco-

lumbar) is noted at the time of diagnosis of AML or ALL or during treatment as reported in recent prospective studies (19). In our series, bone pain was more frequent in areas with abundant bone marrow, such as the pelvis (hips) or the sternum. This is due to crowding of the bone marrow with an excessive number of abnormal white blood cells. In children, parents may notice that a child is not drinking or walking normally, without any form of injury to explain the symptom. Minor abnormalities of phospho-calcium metabolism in patients with LA are frequently observed. They reflect the imbalance of phosphocalcic homeostasis by disturbance of bone resorption, renal excretion, gastrointestinal absorption and increased intake (via transfusions). Hypercalcemia, which occurs in only 1% of cases, is the most serious complication (20-22) and is often accompanied by skeletal abnormalities mimicking metabolic bone disease. This malignancy-induced hypercalcemia may be humoral (secretion of PTH-related protein, TNF, interleukin or cytokines) or secondary to osteolytic activity (20,21). During AML treatment, we observed 36% AO, which is comparable to the prevalence of bone morbidity reported in the literature (around 20%) (2). Osteopenia (15.5%), fractures (8.7%), and NAV (2.91%) were the most notable bone lesions at diagnosis. The causes of this morbidity are multifactorial: patient-related, disease-related, and anti-leukemia treatment-related. Age greater than 10 years has been identified as a factor favoring bone complications of LA treatments. In our series, there are no more preadolescents in the AO group, but they represent 38% of the subgroup of patients with bone complications during treatment (vs 47% at diagnosis and 26% after treatment). Several recent prospective studies, using next-generation sequencing techniques, have identified SNPs in the COL11A1 and NELL1 genes as predisposing factors for decreased bone mineralization (23). As in published series, AO in our experience was mostly encountered in patients with AML type M2 M3 M4, proliferation leads more rapidly to hematologic and clinical symptoms, and bone involvement probably does not have time to

become symptomatic. Leukemic AO is probably related to pressure on or damage to the periosteum from bone marrow infiltration (2), and cytokine-mediated stimulation of osteoclasts leads to weakening of the bone matrix, resulting in fractures or vertebral compression (8). However, these drugs are essential to achieve the current survival figures in these diseases. Neither the prognostic value of OA at diagnosis nor that of bone complications occurring during treatment has been clearly determined. However, one series showed a statistically better 5-year overall survival for patients with juvenile idiopathic arthritis-like involvement at diagnosis of their LA (n = 49 JIA/762 LA)(18). Therefore, primary and secondary prevention is certainly crucial for the reduction of morbidity. Indeed, secondary bone damage, although significantly disabling (fractures, NAV, immobilization), is partially or completely reversible thanks to the administration of calcium and vitamin D supplements, as well as the administration of biphosphonate for the most severe cases. Despite this management, a proportion of patients will retain osteopenia in 13-24% according to the literature (10), and this proportion is expected to increase as the survival rate of LA improves (25). In our cohort, we could not have an idea of which patients had persistent residual osteopenia after the end of treatment, hence the interest of early and prospective follow-up by BMD, as soon as the diagnosis is made, would make it possible to identify asymptomatic osteopenia and, by early management, to avoid its aggravation. However, in young children, the value of BMD is debated because of the lack of clear reference values in this age group. In addition, standard radiography can only visualize changes when the loss of bone mass is greater than 30%. For prevention and follow-up of TANs, a prospective study of patients >10 years of age with targeted MRI could help to identify extensive epiphyseal lesions earlier with high sensitivity and specificity, allowing early medical or surgical intervention. It is interesting, however, to note that despite the undisputed morbidity of fractures and vertebral compression in patients with LA, the incidence

of secondary neurological damage is very low (8). The positive impact of physical exercise encouraged during cancer treatment is being evaluated. In contrast to studies in adults, there does not appear to be increased survival in children. However, the positive impact on bone mineralization and quality of life appears to be significant (26-28). Thus, particular attention should be paid to other supportive care such as optimization of nutrition, mobilization and maintenance of physical activity during treatment. Various studies, without demonstrating a survival advantage, argue for a gain in quality of life. These types of management should therefore be integrated into the primary or secondary prevention of AO associated with pediatric LA.

Conclusion

Skeletal development in children, characterized by rapid accumulation of bone mass, is particularly vulnerable to the effects of AML and its treatments. AO, such as pain, arthritis, osteitis, or fractures, may be the inaugural signs of AML and these AO should be routinely sought. In addition to initial OA, bone toxicity from anti-leukemia therapy is also a concern. Early identification of OA (imaging) and severe asymptomatic demineralization (bone densitometry), whether initial or secondary to treatment of AL, allows for early management, better follow-up, avoidance of worsening, and resolution after the end of treatment in the majority of cases. Evaluation of all other factors influencing bone health (phosphocalcic metabolism, hormones, nutrition, and biomechanical load) should be part of a primary (e.g., systematic BMD at diagnosis) and secondary (e.g., serial BMD and calcium and vitamin D supplementation, exercise program,) prevention strategy for LA-related OA.

Conflicts of Interest:

The authors declare no conflicts of interest.

References :

1. Strauch A.— Acute lymphocytic leukemia in early life. *Am J Dis Child*, 1913, 5, 43-57.

2. Tragiannidis A, Vasileiou E, Papageorgiou M, et al.— Bone involvement at diagnosis as a predictive factor in children with acute lymphoblastic leukemia. *Hippokratia*, 2016, 20, 227–230.
3. Lahloul Z, Lafhel K, Maani J, Hachim A.— Leucémies aigües de l'enfant : étude de 142 cas. *Archives de pédiatrie*, 2014, 21, 357.
4. Hafiz MG, Islam A, Siddique R, et al.— Back pain and vertebral compression: an unusual presentation of childhood acute lymphoblastic leukemia. *Mymensingh Med J*, 2010, 19, 130-136.
5. Santangelo JR, Thomson JD.— Childhood leukemia presenting with back pain and vertebral compression fractures. *Am J Orthop*, 1999, 28, 257-260.
6. Shahnazi M, Khatami A, Shamsian B, et al.— Bony lesions in pediatric acute leukemia: pictorial essay. *Iran J Radiol*, 2012, 9, 50-56.
7. Salim H, Ariawati K.— Osteoporosis resulting from acute lymphoblastic leukemia in a 7-year-old boy: a case report. *J Med Case Report*, 2014, 8, 168.
8. Kunstreich M.— Osteonecrosis in children with acute lymphoblastic leukemia. *Haematologica*, 2016, 101, 1295–1305.
9. Mostoufi-Moab S, Halton J.— Bone morbidity in childhood leukemia: epidemiology, mechanisms, diagnosis, and treatment. *Curr Osteoporos Rep*, 2014, 12, 300–312.
10. Niinimäki R, Harila-Saari A., Jartti A. et al. High
11. Martins SL, Falcão RP. A importância da imunofenotipagem na leucemia mieloide aguda. *Rev Assoc Med Bras*. 2000;46:57--62.
12. Rubnitz JE, Gibson B, Smith FO. Acute myeloid leukemia. *Pediatr Clin North Am*. 2008;55:21---51.
13. Pereira WV. Leucemia mielocítica aguda da infância e adolescência --- Fracassos e vitórias. *Rev Bras Hematol Hemoter*. 2006;28:239---41.
14. Cristofani LM. Leucemia mieloide aguda. 1 ed. In: Filho VO Jr, Maluf PT, Cristofani LM, Almeida MTA, Teixeira RAP, editors. *Doenças neoplásicas da criança e do adolescente*. Barueri: Manole; 2012. p. 81---7
15. Zanichelli AA, Cristofani LM, Almeida MT, Maluf Júnior PT, Filho VO. Perspectivas para a leucemia mieloide aguda na infância após observação de um grupo de pacientes tratados convencionalmente. *Rev Bras Hematol Hemoter*. 2006;28:246---52.
16. Xu XJ, Tang YM, Song H, Yang SL, Shi SW, Wei J. Long-term outcome of childhood acute myeloid leukemia in a developing country: experience from a children's hospital in China. *Leuk. Lymphoma*. 2010;51:2262---9
17. Kaspers GJ, Zwaan CM. Pediatric acute myeloid leukemia: towards high-quality cure of all patients. *Haematologica*. 2007;92:1519---32
18. Gamis AS, Alonzo TA, Perentesis JP, Meshinchi S. Children's Oncology Group's 2013 Blueprint for Research: acute myeloid leukemia. *Pediatr Blood Cancer*. 2013;60:964---71.
19. Viana MB, Cunha KC, Ramos G, Murao M. Leucemia mieloide aguda na criança: experiência de 15 anos em uma única instituição. *J Pediatr (Rio J)*. 2003;79:489---96.
20. Nouvelles approches dans le traitement des leucémies aiguës de l'enfant Service d'immuno-hématologie pédiatrique et de transplantation de moelle osseuse Hôpital Debrousse 29, rue Sœur-Bouvier 69322 Lyon cedex 05, France
21 :Prise en charge thérapeutique des leucémies aiguës myéloïdes
- 22 : Les leucémies de l'enfant
23. Creutzig U, Heuvel-Eibrink MM, Gibson B, Dworzak MN, Adachi S, Bont E. Diagnosis and management of acute myeloid leukemia in children and adolescents: recommendations from an international expert panel. *Blood*. 2012;120:3187---205.
24. Imamura T, Iwamoto S, Kanai R, Shimada A, Terui K, Osugi Y, et al. Outcome in 146 patients with paediatric acute myeloid leukaemia treated according to the AML99 protocol in the period 2003-06 from the Japan Association of Childhood Leukaemia Study. *Br J Haematol*. 2012;159:204---10
25. Rubnitz JE, Inaba H. Childhood acute myeloid leukaemia. *Br J Haematol*. 2012;159:259---87.

26. Kern W, Haferlach T, Schoch C, Löffler H, Gassmann W, Heinecke A, et al. Early blast clearance by remission induction therapy is a major independent prognostic factor for both achievement of complete remission and long-term outcome in acute myeloid leukemia: Data from the German AML Cooperative Group (AMLCG) 1992 Trial. *Blood*. 2003;101:64--70.
27. Pinheiro RF, Pelloso LA, Yamamoto M, Chauffaille ML, Bordim JA. Síndrome atrófica: experiência de 2 anos. *Rev. Bras. Cancerol.* 2003;49:27--31.
28. Tarlock K, Meshinchi S. Pediatric acute myeloid leukemia: biology and therapeutic implications of genomic variants. *Pediatr Clin North Am*. 2015;62:75--93
29. Cooper TM, Hasle H, Smith FO. Acute myeloid leukemia, myeloproliferative, and myelodysplastic disorders. In: Pizzo PA,
30. Martins SL, Falcão RP. A importância da imunofenotipagem na leucemia mielóide aguda. *Rev Assoc Med Bras*. 2000;46:57--61.
31. Rubnitz JE, Gibson B, Smith FO. Acute myeloid leukemia. *Pediatr Clin North Am*. 2008;55:21--51.3