

## Case study

### Fentanyl patch intoxication in an 8-year-old child: A case report

#### Abstract

Opioid intoxication in pediatrics is rare in Morocco. In our hospital, it is the third case that has been recorded in recent years. It is about a boy of 8 years old who after a benign trauma at the level of the back, his father attached to him a patch of Fentanyl dosed at 75  $\mu\text{g}/\text{h}$  given by a friend returning from abroad. After 8 hours, the father found his child unconscious with abnormal breathing, motivating him to bring him back to the emergency room of our hospital where he presented a convulsive seizure before being urgently intubated and transferred to intensive care. The patient woke up and was extubated after 24 hours, but he kept a divergent strabismus of the right eye for which he was sent to the ophthalmology department for further management.

#### Key words

Intoxication, Fentanyl, Child, management, prevention.

#### Introduction

Fentanyl is a 3rd tier opioid analgesic, marketed as an injectable or transdermal patch, and prescribed for the management of acute and chronic pain.

The increasing prescription of these drugs for adults is strongly associated with increased exposure and intoxication in children.

We describe here a case of acute intoxication at home by a fentanyl patch in an 08-year-old boy in a context of misuse.

#### Case report

Child E.A (ELGARI AHMED) aged 08 years, elder of a brotherhood of 02.

Brought by his father to the medical emergency of the children's hospital of Rabat on 12/09/2022 at 3 am for unconsciousness and abnormal breathing.

The child had no particular medical history. In his surgical history we note a circumcision at the age of 2 years done under locoregional anesthesia.

The story goes back to the evening of 11/09/2022 around 9 pm when the child presented lumbar pain following a fall during a soccer game at the cartier. The father stuck a fentanyl patch at 75  $\mu\text{g}/\text{h}$  on his back in the painful area (Image 1), given by a friend coming back from abroad.

At 05:00 am the father woke up for prayers and noticed that his child had abnormal breathing and did not wake up despite the stimuli. The father quickly removed the patch and brought the child back to the emergency room of our hospital for treatment.

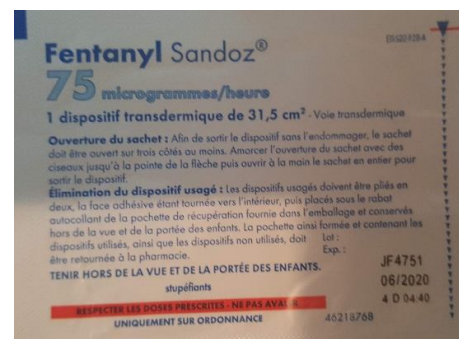


Image 1: Fentanyl patch specification card dosed at 75 micrograms/hour

The patch remained attached for 8 hours, which is an equivalent dose of 600 µg of fentanyl delivered.

In the emergency room, the patient presented with a generalized tonic-clonic seizure that had ceased under 2mg of intravenous Midazolam.

Clinical examination in the emergency room found the patient unconscious with a Glasgow Coma Scale (GCS) of 4 (OY=1, RV=1, RM=2) pupils in serous miosis.

The patient presented with stertorous breathing, cyanotic, saturated between 88 and 92% under MHC at 10l/min with diffuse snoring rales on auscultation.

He was hemodynamically stable with a BP of 110/66 mmHg with a HR of 101 bpm.

Dextro at 1.5g/l T°= 36.8°C Pds= 30 kg

We decided to intubate the patient on site.

After conditioning and monitoring, a peripheral venous line was taken and filled with 200 ml of saline 0.9% and a urinary catheter was inserted.

Complementary induction with 150 mg of Propofol and 20 mg of Rocuronium then orotracheal intubation with an N°5 tube fixed to the left labial commissure, marker at 15 cm to the dental arch.

Then the patient was transferred to the pediatric intensive care unit for further management.

In the intensive care unit, the patient underwent the following workup:

CBC: Hg= 11.6 HCT= 36% WBC=21370 PLQ=420000

PT= 92% APTT= 25.9 s

Blood ionogram: Na<sup>+</sup>=136 K<sup>+</sup>=4.5 Cl<sup>-</sup>=104 HCO<sub>3</sub><sup>-</sup>=19 Blood glucose=1.41 Urea=0.36 Creatinine=8.8 Protein=68 ALT=76 ASAT=43

GDS: Ph = 7.38 PaO<sub>2</sub>=180 under 50% FiO<sub>2</sub>PaCO<sub>2</sub>= 42 HCO<sub>3</sub><sup>-</sup>=20 lactates= 1.6

Chest x-ray: small right basal focus.

A blood toxicology test showed high opioid levels.

We start the following treatment:

Mechanical ventilation in VAC mode

Amoxicillin + clavulanic acid 500mg/08h

Naloxone 0.4mg/08h and 0.4 mg/24 in PSE.

PPI 20mg

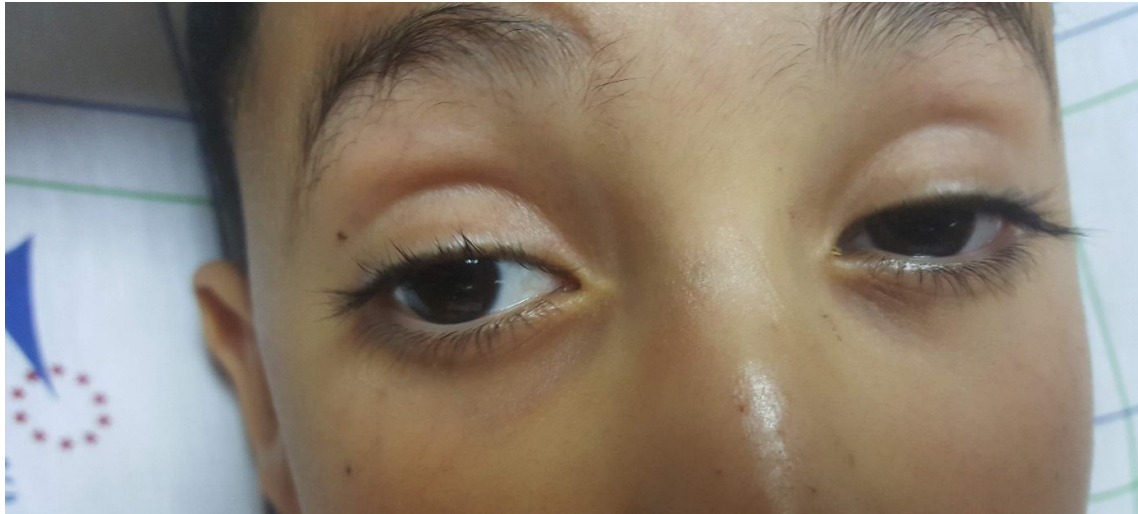

Image 2: Divergent strabismus of the right eye as a neurological sequela.

The pharmacovigilance center was notified by e-mail.

The evolution was marked by the patient's awakening after 24 hours of mechanical ventilation allowing him to be extubated. The complete clinical examination after extubation showed a divergent strabismus of the right eye probably related to a right VI nerve palsy of anoxic origin (Image 2).

A brain MRI was performed and came back without any particularities.

The patient was discharged from the ICU after 48 hours and referred to the neurology and ophthalmology departments for further management.

### Discussion

Fentanyl is an opioid analgesic, derived from phenylpiperidine, which interacts primarily at  $\mu$ -morphine receptors in the brain, spinal cord and smooth muscle.

It has a rapid analgesic effect and a short duration of action. Fentanyl has an analgesic effect approximately 100 times more potent than morphine. Its main therapeutic effects are analgesic and sedative.

The fentanyl patch is indicated in the long-term treatment of severe chronic pain in children from 2 years of age receiving opioid analgesics for the treatment of chronic pain of cancerous origin, intense or resistant to analgesics, in case of stable pain.

The application of fentanyl transdermal patches has resulted in significant morbidity and mortality since their development [1].

However, there are few studies concerning fentanyl intoxication in pediatrics.

In our case, it is a case of intoxication by misuse of a fentanyl patch intended for adults and dosed at 75 micrograms/hour. The young child received a total equivalent dose of 600 micrograms during 06 hours.

The most serious and feared adverse effect of opioids is respiratory depression. Deaths secondary to opioids occur as a result of decreased sensitivity to hypoxia and hypercapnia that cause respiratory depression. Fentanyl is known to cause chest rigidity due to muscle spasm. [2]

Miosis, nausea and vomiting, pruritus, constipation, and urinary retention are also frequently reported symptoms of overdose. [3]

In our case the clinical picture was dominated by generalized tonicoclonic convulsion most likely of hypoxic origin in addition to bradypnea and tight miosis.

In our case the management of the patient consisted in the support of the respiratory function by mechanical ventilation associated with Naloxone administered in bolus of 0.4mg/08 hours associated with 1 continuous infusion of 0.4mg in 24h. [4]

Naloxone is a pure and specific antagonist of morphinomimetics. When injected into subjects who have received morphinomimetics, naloxone antagonizes their effects (respiratory depression, miosis, analgesia). Its action depends on the dose, the potency of the morphinomimetic to be antagonized and the interval between injections of the two products. [5]

It is administered in case of toxic coma at the dosage of 0.4mg three times a day from the age of 3 years with a maximum dosage of 10mg/24h. [6]

Despite the Naloxone, the patient's awakening was obtained only after 24 hours of respiratory assistance testifying to the importance of the dose received and the duration of exposure, the clinical examination after extubation found a divergent strabismus of the right eye as a sequel. [7]

In our case, the neurological lesion may be due to direct neurotoxicity or secondary to hypoxia induced by respiratory depression.

In our referral hospital, this is the 3rd case of accidental morphinomimetic intoxication that has been recorded and the national data concerning these intoxications in pediatrics are insufficient.

Internationally, several studies have shown that morphinomimetic intoxication has become epidemic with devastating consequences for children and their families due to the increase in the prevalence of opioid use and abuse. [8]

Given the easy access to these drugs, accidental ingestion and or misuse in children is becoming increasingly common. [9]

Prevention remains the most effective means of combating these tragedies and that includes educating patients about the potential risks and proper use. [10]

Pharmaceutical companies must step up their efforts to make fentanyl patch safety a top priority. Label warnings should be improved, and secure disposal containers for patches should be designed and made widespread.

Prescribers and pharmacists also need ongoing education regarding the proper use, storage, and disposal of opioid-containing products.

## Conclusion

This case report highlights the severity of pediatric opioid intoxication and underscores the importance of primary prevention in combating this scourge.

Patient and caregiver education is the cornerstone of this prevention strategy.

Further studies must be undertaken in **our country** to evaluate the incidence and improve the management of these intoxications.

**COMPETING INTERESTS DISCLAIMER:**

Authors have declared that they have no known competing financial interests OR non-financial interests OR personal relationships that could have appeared to influence the work reported in this paper.

UNDER PEER REVIEW

## References

### [1] Child Fatalities Due to Heroin/Fentanyl Exposure: What the Case History Missed

Rebecca T. DeRienz\*†, Daniel D. Baker, Nancy E. Kelly, Amber M. Mullins, Rachel Y. Barnett, Jennifer M. Hobbs, John A. Daniels, Kent E. Harshbarger, and Anahi M. Ortiz Franklin County Coroner's Office, 520 King Avenue, Columbus, OH 43201, USA [book? Article? Date?](#)

### [2] Fentanyl Exposure. This presentation only discussed Cases 1 and 2. Acute Cytotoxic Cerebellar Edema Subsequent to Fentanyl Patch Intoxication in an Infant

Lindsey N. Haut, Rupa Radhakrishnan, Riad Lutfi, Louise W. Kao, and Laurie L. Ackerman [book? Article? Date](#)

### [3] Intoxications mortelles par mésusage de fentanyl et traitement substitutif aux opiacés : description de 2 cas

Edouard Le Carpentier, Guillaume Deslandes, Laurent Boidin, Caroline Paget, Renaud Clément, Catherine Monteil-Ganière Laboratoire de Pharmacologie-Toxicologie, CHU Nantes, Nantes, France Médecine légale, CHU Nantes, Nantes, France [book? Article? Date](#)

### [4] Intoxication mortelle d'un nourrisson par le fentanyl : homicide ou accident ?

[Author links open overlay panel](#) G. Hoizey<sup>1</sup>C. Rey Salmon<sup>2</sup>P. Meyer<sup>3</sup>M. Chèze<sup>1</sup>F. Billault<sup>1</sup>E. Médrano<sup>1</sup>M. Deveaux<sup>1</sup> Death by band-aid: fatal misuse of transdermal fentanyl patch Marija Bakovic, Marina Nestic & Davor Mayer International Journal of Legal Medicine volume 129, pages 1247–1252 (2015)

### [5] Fatal outcome in a child after ingestion of a transdermal fentanyl patch

Jörg Teske, Jens-Peter Weller, Klaus Larsch, Hans Dieter Tröger & Matthias Karst International Journal of Legal Medicine volume 121, pages 147–151 (2007) [Neta Cohen, Mathew Mathew, Adrienne Davis, Jeffrey Brent, Paul Wax, Suzanne Schuh, show all Pages 702-707 | Received 02 Dec 2021, Accepted 30 Jan 2022, Published online: 25 Mar 2022](#)

### [6] Toxic Leukoencephalopathy Due to Transdermal Fentanyl Overdose

Foy, Lindsey MD\*†; Seeyave, Desiree M. MBBS†; Bradin, Stuart A. DO†

### [7] Fatal fentanyl-associated cerebellitis in a young man Fentanyl Patch Fatalities: We ALL Have a Role in Prevention!

Matthew Grissinger, RPh, FASCP Mr. Grissinger, an editorial board member of P&T, is Director of Error Reporting Programs at the Institute for Safe Medication Practices (ISMP) in Horsham, Pennsylvania (www.ismp.org). [book? Article? Date](#)

### [8] Randomized Controlled Feasibility Trial of Intranasal Ketamine Compared to Intranasal Fentanyl for Analgesia in Children with Suspected Extremity Fractures

Stacy L. Reynolds, MD, Kathleen K. Bryant, MD, Jonathan R. Studnek, PhD, Melanie Hogg, Connell Dunn, Megan A. Templin, MS, Charity G. Moore, PhD, MSPH, James R. Young, MD, Katherine Rivera Walker, BSN, and Michael S. Runyon, MD, MPH [book? Article? Date](#)

### [9] Accidental Opioid Intoxication in Children Treated With Low Doses of Naloxone: A Case of Fentanyl Patch Exposure and a Case of Morphine Tablet Ingestion

El Kihel H<sup>1\*</sup>, Arfaoui M<sup>1</sup>, Chaker A<sup>1</sup>, Bentalha A<sup>1</sup>, Elkoraichi A<sup>1</sup>, Echcherif El Kettani S<sup>1</sup> Intensive care department, Children's Hospital of Rabat, Morocco [book? Article? Date](#)

**[10] Les opiacés chez l'enfant Geneviève Laflamme, Annie Lavoie**

Annie Lavoie CHU-Sainte-Justine 3175 Côte Sainte-Catherine Montréal (Québec) H3T 1C5 Téléphone : 514 345-4603 Télécopieur : 514 345-4820 Courriel : [annie.lavoie.hsj@sss.gouv.qc.ca](mailto:annie.lavoie.hsj@sss.gouv.qc.ca) [book? Article? Date](#)

UNDER PEER REVIEW