

Case report

Internal carotid-internal jugular vein arteriovenous fistula: case report of an incidental Radiological finding

ABSTRACT: Internal carotid-internal jugular vein fistula is a direct abnormal connection between the internal carotid artery and internal jugular vein. This entity, be it congenital or acquired is rare. We present a case report of a 67 years old woman with an incidental left internal carotid-internal jugular fistula diagnosed on routine contrast enhanced CT of the brain and carotid duplex ultrasound scan. Radiologists can play a vital role in arteriovenous fistula diagnosis and treatment. Adequate assessment of cross-sectional imaging studies can identify uncommon asymptomatic arteriovenous fistulae.

Key words: carotid-internal jugular, fistula arteriovenous, Ultrasound ,Doppler mode

INTRODUCTION:

Arteriovenous fistulae could be as common in Nigeria as they are in other geographical locations of the globe. [1-2] The etiology of carotid-jugular fistulae can be idiopathic, iatrogenic, or can be due to complication of gunshot injuries and stab wounds. [3-5] If untreated this vascular lesion may lead to cardiac failure, atrial fibrillation and catastrophic embolization (e.g. ischemic stroke from atrial fibrillation). [6] The diagnosis of both symptomatic and asymptomatic cases of carotid-jugular fistulae can be easily missed clinically. Imaging is vital in making the definitive diagnosis with a variety of readily available imaging modalities with high sensitivity and specificity. [7] Asymptomatic or clinically silent fistulas between the internal carotid artery and internal jugular vein are very exceptional disorders, not regarded as a common finding in imaging.

Hence, this case is presented for its rarity, and to highlight the possibility of missing such a diagnosis when patients have no symptoms or present with non-specific symptoms.

CASE REPORT:

PR is a 67 years old woman who presented at the General outpatient clinic of UPTH, Rivers State Nigeria with a history of mild head trauma and recurrent headaches of two week's duration. The head trauma was sustained in her house from a fall in which her head impacted an open door. This incident was followed by recurrent frontal headaches that was temporarily relieved by Acetaminophen tablets. No loss of consciousness, dizziness, nausea, vomiting or fever was reported. The patient was a known hypertensive diagnosed 5 years ago compliant on antihypertensive (lasotarn, amlodipine, amiloride and hydrochlorothiazide). She also had a 20 year's previous history of involvement in a road traffic accident in which she was a passenger on a motorcycle that was knocked down. However, she claimed to have sustained no serious injuries and did not present to a hospital.

On physical examination, she was healthy looking with GCS of 15; not anemic anicteric, afebrile and not dehydrated. Examination of the CNS revealed no neurological deficit. Further examination revealed bilateral cataracts. Review of other systems including the CVS were within normal limits.

A CT scan of the brain was scheduled and done in the Radiology department. Series of pre and post contrast axial and multi-planar reformatted images showed a left internal jugular vein (IJV) with markedly increase caliber and tortuous course, which takes up contrast in the arterial phase (figures 8, 9 and 10). An abnormal side-to-side connection with the medially located ipsilateral internal carotid artery (ICA) was noted at the level of C3 vertebra body (figures 6, 7 and 8). It measured 0.83cm x 0.59cm x 0.45cm in the antero-posterior, cranio-caudal and Medio-lateral dimension respectively. Incomplete circumferential mural calcification was seen at the level of the fistula and cranial to the level of the fistula (figure 6). Similar changes were seen in the contralateral ICA in the distal segments of the cervical ICA. The cerebral hemispheres were normal with grey – white matter differentiation.

There was asymmetry of the lateral ventricles with the right lateral ventricles appearing slightly wider (anatomical variant). The third and fourth ventricles were normal. Also, bilateral irregular cortical thickening of the inner table of the frontal bone was seen, suggestive of hyperostosis frontalis interna. A diagnosis of left internal carotid-internal jugular vein arteriovenous fistula (IC-IJV AVF) was made and the patient was scheduled to have left carotid duplex Ultrasound scan for further evaluation.

A left carotid duplex ultrasound scan was done subsequently. It showed a tortuous and dilated left IJV with a fistula connection to the left ICA on B – mode images (figure 1). The fistula measured 0.521cm x 0.449cm in cranio-caudal and Medio-lateral dimension respectively (figures 3 and 4). Color Doppler mode showed aliasing artefact across the fistula (figure 2). Spectra Doppler mode showed arterialization of the left IJV wave pattern with a PSV of 32.3cm/s and EDV of 24.0cm/s was recorded (figure 5). The left ICA demonstrated normal spectral wave pattern with PSV of 50.2cm/s and EDV of 20.2cm/s in its mid cervical segment proximal to the fistula, while the left common carotid artery (CCA) demonstrated normal spectral wave patterns with PSV of 73cm/s and EDV of 38.0cm/s. An assessment of Left IC-IJV AVF was also made.

Laboratory investigations showed elevated serum uric acid levels (466 umol/L) only. Lipid profile, Fasting Blood Sugar (FBS), and full blood count investigation were within normal limits. Plain chest radiography showed hypertensive cardiovascular changes evidenced by left ventricular cardiomegaly and aortic unfolding, plain radiographs of the knee joints revealed early osteoarthritic changes, and plain lumbosacral radiographs showed spondylosis.

She was subsequently counselled and referred to the vascular surgical outpatient clinic for further management. on follow up She remained asymptomatic and clinically stable. Hence, she was managed conservatively.

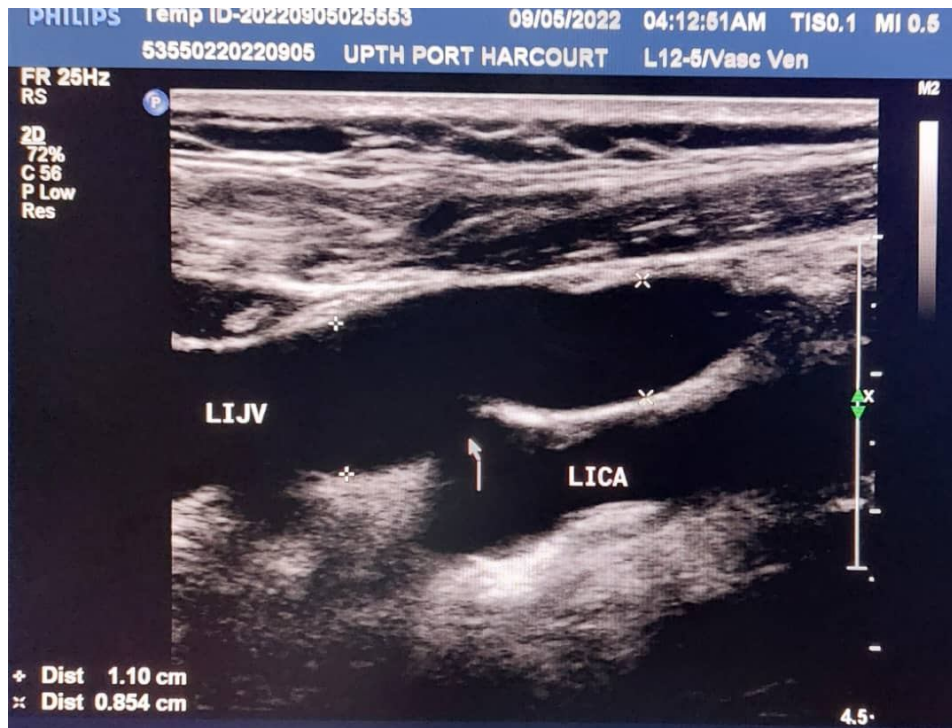


Figure 1. Longitudinal B mode sonogram demonstrating a Left IC-IJV AVF.

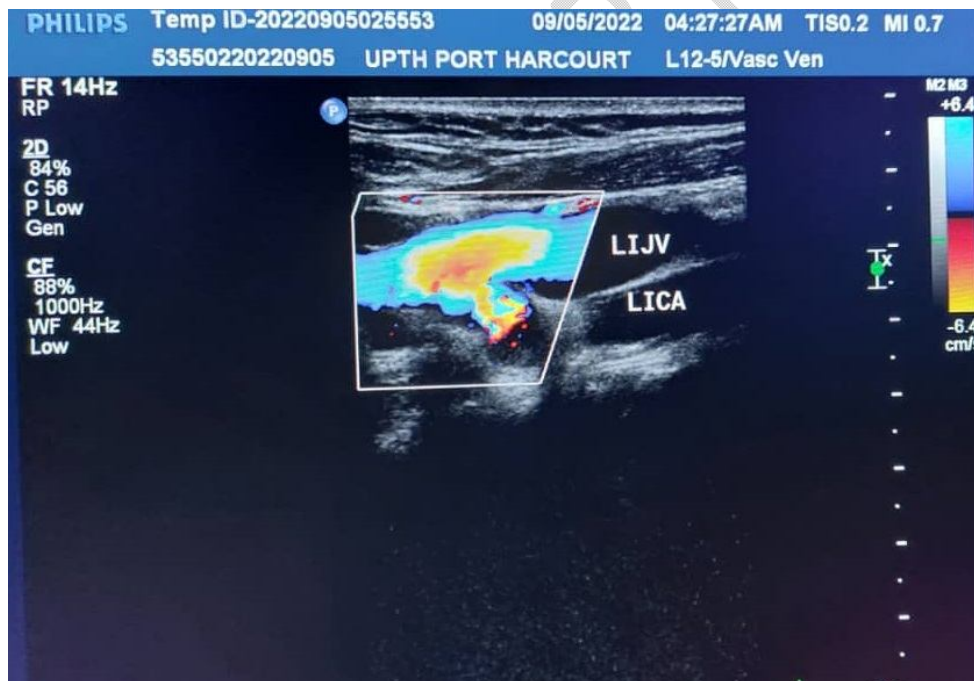

Figure 2. Longitudinal Colour mode sonogram shows turbulent high-velocity flow at the fistula tract.

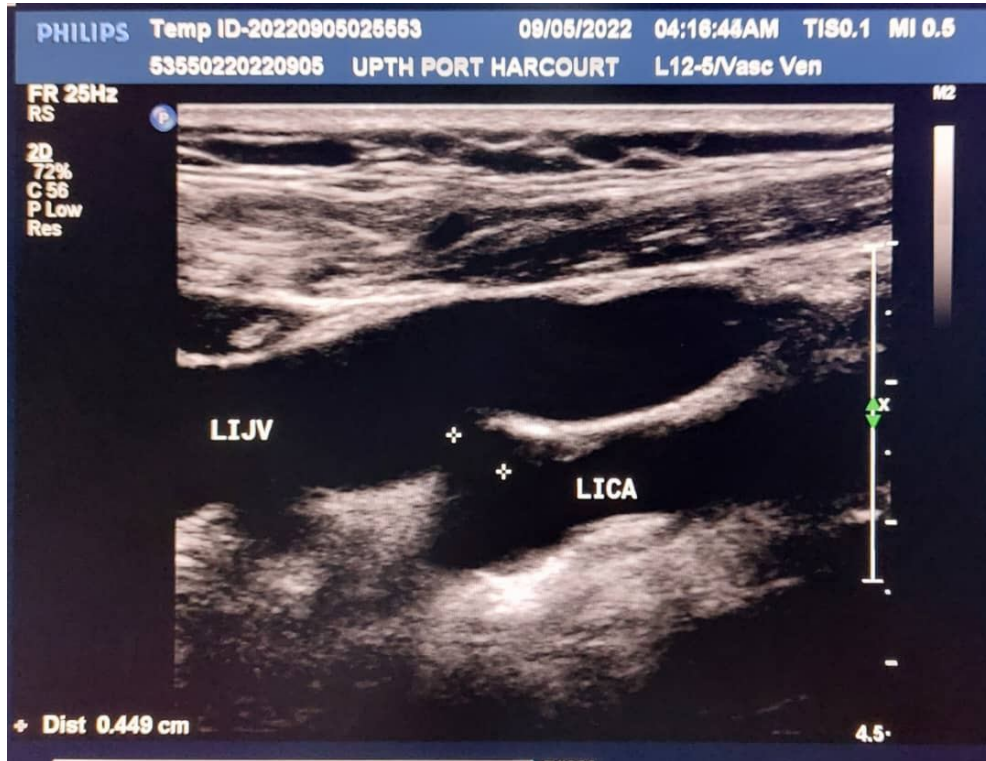


Figure 3. Longitudinal B mode sonogram showing the length of the fistula tract.

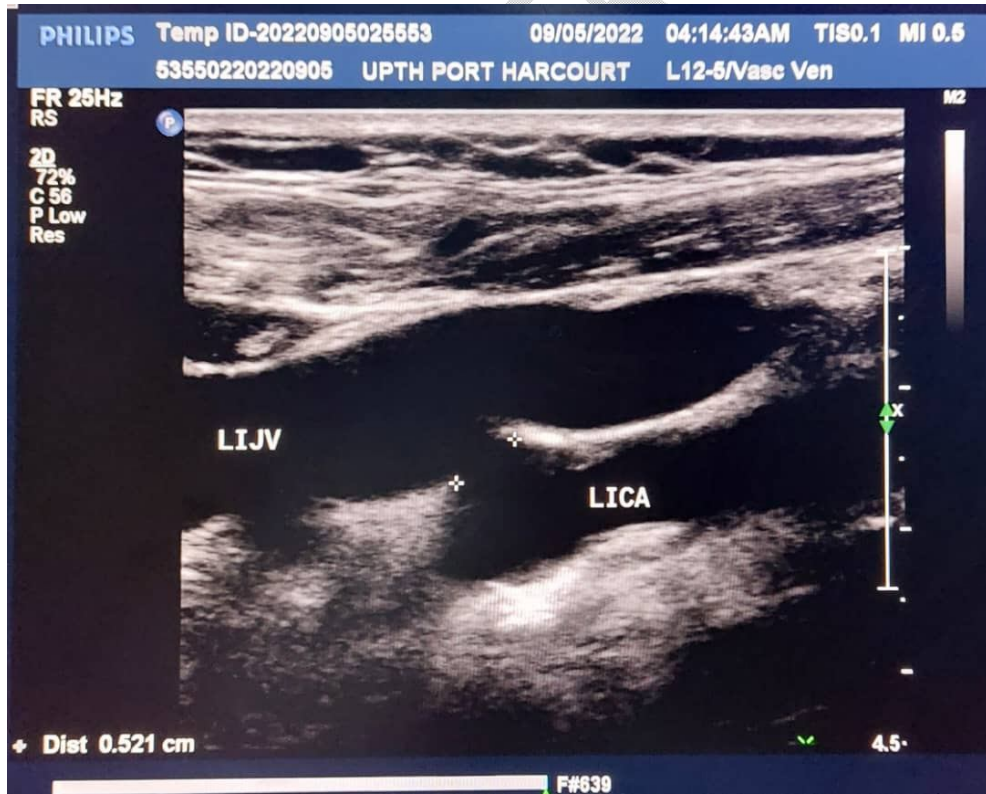

Figure 4. Longitudinal B mode sonogram showing the width of the fistula tract.

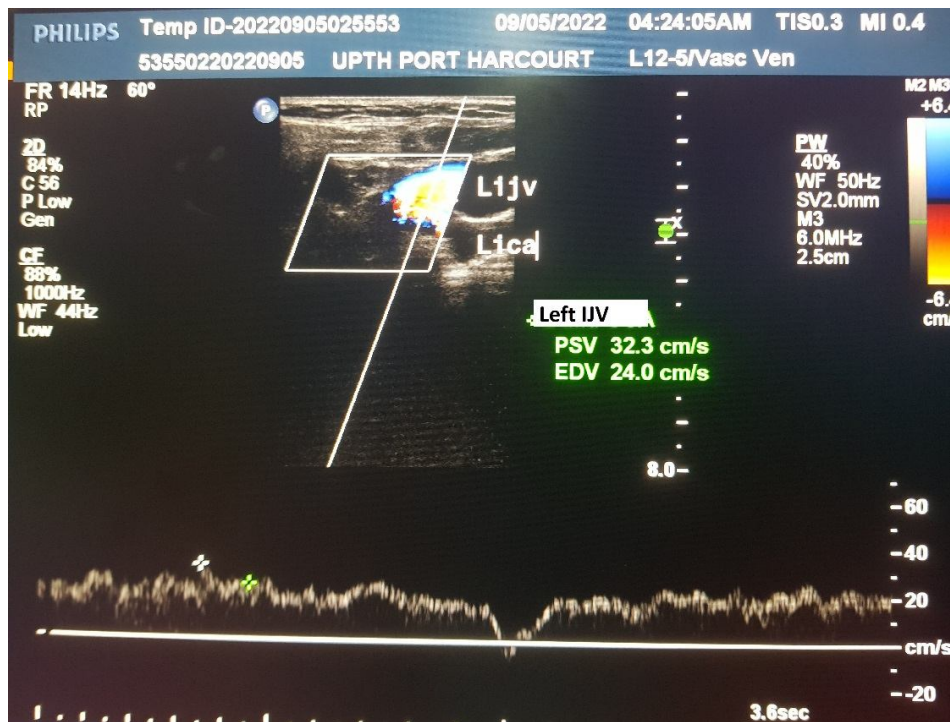


Figure 5. Longitudinal spectral wave sonogram showing high-velocity arterIALIZED waveform in the left IJV.

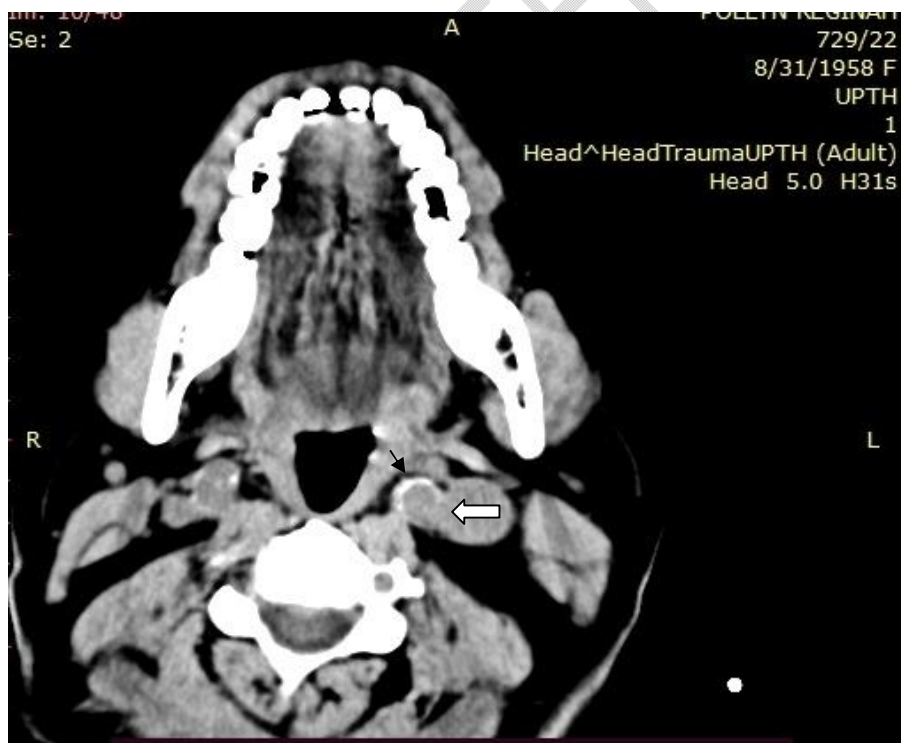


Figure 6. Non-contrast axial CT showing a Left IC-IJV AVF (indicated by the white arrow) with mural calcification of the ICA (indicated by the black arrow).

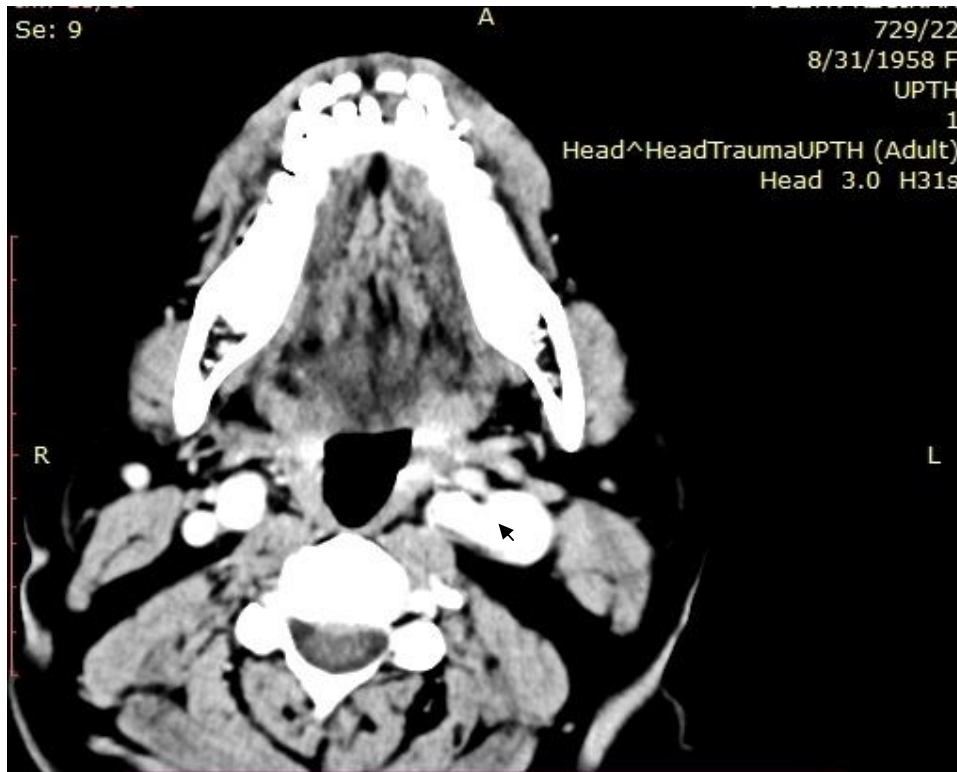


Figure 7. Contrast axial CT showing a Left IC-IJV AVF (indicated by the arrow).

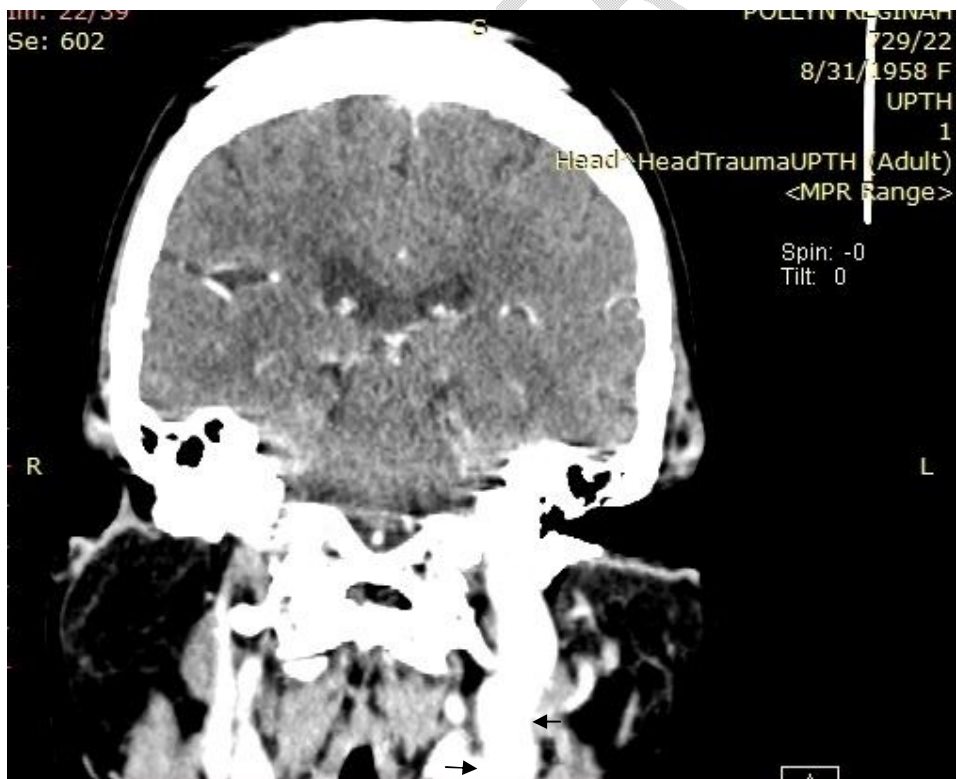


Figure 8. Contrast sagittal CT showing a Left IC-IJV AVF with a markedly dilated and tortuous IJV (indicated by the arrows).

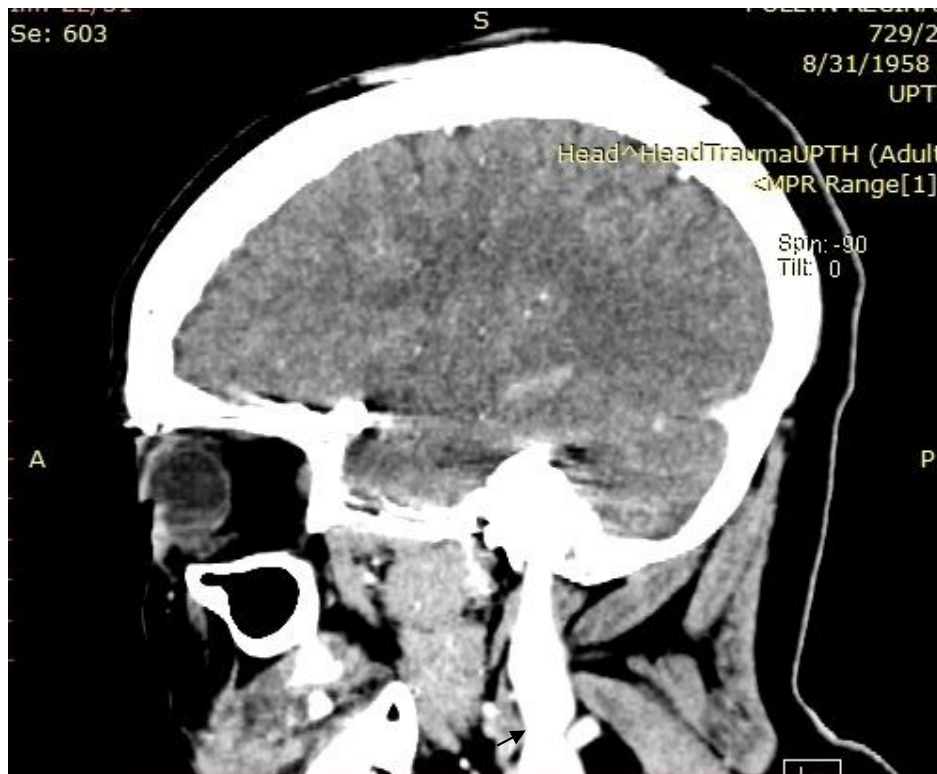


Figure 9. Contrast coronal CT showing a markedly dilated and tortuous left IJV (indicated by the arrow).

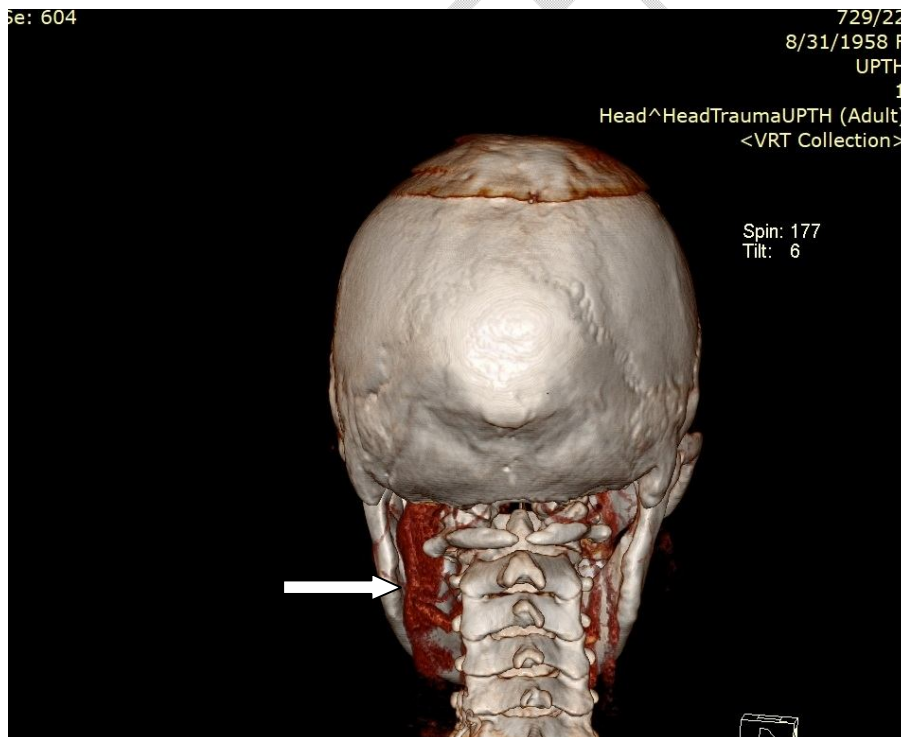


Figure 10. Contrast reconstructed 3-D CT showing markedly dilated and tortuous left IJV (indicated by the arrow).

DISCUSSION:

Arteriovenous fistulas (AVFs) can be separated into congenital which are less common, and acquired which are **common**. Fistulas which are acquired typically have a sole large connection between artery and vein which are fallouts from either instrumental trauma e.g. Intravenous catheter placement or penetrating injury as in bomb blast injuries. [8] **The** index patient was suspected to have an acquired AVF based on the history.

Acquired common carotid-jugular fistulas are scarce in the region of the head and neck, accounting only for 4 to 7% of all the traumatic AVFs encountered all over the body [9], and internal carotid-jugular fistulas can be expected to be more uncommon as data on this type of fistula was difficult to come by following. Of the 9 acquired cases of carotid-jugular fistulas (CJF) reported up to the year 2000, 7 were sited between the CCA and the IJV, and only 2 were sited between the ICA and the IJV. [10] Also, cases of acquired carotid-jugular fistula published from 2000 to 2012 involving 23 patients revealed that, 16 were between the CCA and IJV, 5 were between the ICA and the IJV, and 2 were between the ECA and the IJV. [10] Acquired AVFs may take a very long time to manifest with a time of presentation of up to 58 years from the original injury. [11] Although the index patient had no symptoms that specifically suggests the presence of an AVF, a chest radiograph revealed left ventricular cardiomegaly and aortic unfolding which were regarded as hypertensive cardiovascular changes. Caldarelli et al [10] and Ezemba et al [12] suggested that signs and symptoms of smaller diameter arteriovenous fistulas (<5mm), with low output, may appear many years after injury and generally consist of mild left ventricular hypertrophy and cardiomegaly devoid of congestive heart failure.

Catheter angiography is regarded as the gold standard for diagnosis, and it offers the possibility of concurrent endovascular treatment. Studies have shown that duplex ultrasound imaging has comparable sensitivity and specificity to conventional angiography in evaluation of vascular lesions in the neck when it is performed by an experienced physician. [7] Carotid-jugular fistulas manifest as early visualization of the draining jugular vein in the arterial phase on conventional angiography. Ultrasonography (US) is a sensitive and noninvasive modality for detecting AVFs. Color and duplex US findings include turbulent IJV flow, increased velocity and low pulsatility carotid flow, increased velocity and high pulsatility IJV flow, and change in calibre of the carotid around the AVF and focal IJV dilation caudal to the AVF. Color Doppler US is very sensitive for visualizing AVFs and may be the reference standard, but it is said to overestimates the diameter of the fistula tract. [10]

Other modalities include CT angiography (CTA) and MR angiography (MRA). CTA provides the best spatial resolution of catheter angiography and offers the best three-dimensional localization of the AVF within the tissues if surgical repair is planned. MRA offers flow information via dynamic sequences and phase velocity mapping, though hemodynamic information is inferior to US. MRA spatial resolution is good though inferior to CTA. [10]

Embolization or sclerotic agents such as absolute ethanol, polidocanol, ethanolamine oleate, n-butyl cyanoacrylate, various coils, polyvinyl alcohol foam powder and superabsorbent polymer microspheres have been used in interventional radiologic management of AVF. [13] However, based on the small diameter of the arteriovenous fistula (<6mm) and absence of significant signs and symptoms in the index patient, any form of intervention is deemed unnecessary at this time.

CONCLUSION:

In conclusion, radiologists can play a vital role in AVF diagnosis and treatment. Adequate assessment of cross-sectional imaging studies can identify uncommon asymptomatic AVFs.

Consent

As per international standard or university standard, patient(s) written consent has been collected and preserved by the author(s).

Ethical Approval:

As per international standard or university standard written ethical approval has been collected and preserved by the author(s).

REFERENCES

1. Anyanwu CN, Ude AC, Swarup AS, Umerah BC, Udekwu FA. Traumatic aneurysms and arteriovenous fistulas in Nigeria. *Thorac Cardiovasc Surg* 1980; 28: 265-8.
2. Adeyemi-Doro HO. Traumatic aneurysms and arteriovenous fistula of the upper limb. *West Afr J Med*. 1989; 8: 143-9.
3. A E. Puca, F Pignatelli. An Adult Case of Idiopathic Internal Carotid–Internal Jugular Vein Arteriovenous Fistula. *Annals of vascular surgery* volume 29(4) may 2015 page 842.
4. Kurt P Droll, Alan G Lossing. Carotid-jugular arteriovenous fistula: case report of an iatrogenic complication following internal jugular vein catheterization. *Journal of clinical anesthesia* volume 16(2) march 2004 pages 127-129.
5. A. Dammaka, H. BenJmaà, S. Hadhria, H. Cheikhrouhoub, F. Dhoubi, S. Haddarc, L. Kammound, T. Ben, J maàe, B. Hammamif, S. Masmoudia, N. Elleucha, M. Ben

- Jmaàel. Frikhaa. Post-traumatic carotido-jugular fistula: Case report and review of the literature. *Jmv (journal de médecine vasculaire)* volume 42(6) December 2017 pages 388-391.
6. Kakkar S, Angelini P, Leachman R, Cooley D A. Successful closure of post traumatic carotid-jugular arteriovenous fistula complicated by congestive heart failure and cerebrovascular insufficiency. *Cardiovasc Dis* 1979; 6: 457-62.
 7. Demetriades D, Theodorou D, Cornwell E 3rd, Weaver F, Yelling A, Velmahos G, Berne T V. penetrating injuries of the neck in patients in stable condition: physical examination, angiography, or colour flow Doppler imaging. *Arch Surg* 1995; 130: 971-5.
 8. Yousaf KM, Bhagwani AR, Bilal N. Managemnt of chronic traumatic arteriovenous fistula of the lower extremities. *Eur J Trauma Emerg Surg* 2013; 39:393-6.
 9. M. Vera, L. Quintana, J. Blasco, M. Real, and J. M. Macho, "Treatment with the placement of carotid stent of jugular- carotid fistula after the insertion of hemodialysis catheter," *Nefrologia*, vol. 25, no. 5, pp. 568–571, 2005.
 10. Caldarelli C, Biricotti M, Materazzi G, Spinelli C, Spisni R. Acquired carotid-jugular fistula: its changing history and management. *ISRN Vascular Medicine* 2013; Volume 2013:1-8. <http://dx.doi.org/10.1155/2013/320241>
 11. J. H. Kong, S. M. Park, T. H. Kim, D. H. Choi, and D. Y. Lee, "Late-onset congestive heart failure in a patient with a 58- year-old huge traumatic carotid-jugular fistula and pseudoa- neurysm: endovascular treatment with a stent-graft," *Annals of Vascular Surgery*, vol. 24, no. 7, pp. 955.e5–955.e10, 2010.
 12. N. Ezemba, E. E. Ekpe, H. A. Ezike, and C. H. Anyanwu, "Traumatic common carotid-jugular fistula: report of 2 cases," *Texas Heart Institute Journal*, vol. 33, no. 1, pp. 81–83, 2006.
 13. Osuga K, Hori S, Kitayoshi H, Khankan A, Okada A, Sugiura T, Murakami T, Hosokawa K, Nakamura H. Embolization of high flow arteriovenous malformations: experience with use of superabsorbent polymer microspheres. *J Vasc Interv Radiol* 2002; 13: 1125-1133.