

A RARE INCIDENCE OF ETHAMBUTOL INDUCED TOXIC OPTIC NEUROPATHY

ABSTRACT

Ethambutol induces toxic optic neuropathy (EON), which most typically presents as bilateral symmetrical loss of vision and, due to a lack of early detection and adequate treatment, often causes serious irreversible visual impairment. EON is time- and dose-dependent. In this case report, we will discuss a 59-year-old female patient who came in with complaints of visual impairment, inclusive of a colour vision defect (dyschromatopsia) and blurred vision (scotoma). Her past medication history includes use of first-line anti-tubercular therapy (ATT) with four drugs: Rifampicin, Isoniazid, Ethambutol, and Pyrazinamide. Pyrazinamide was taken for two months, and other medications (Rifampicin, Isoniazid, and Ethambutol) were taken for a period of seven months. From this case report, we will get a clear picture necessitating continuous monitoring for ocular toxicity.

Keywords: Ethambutol-induced optic neuropathy (EON), Anti-tubercular therapy (ATT), Reversible, Duration and dose dependent

1. INTRODUCTION

India is a tropical country, and people are more susceptible to acquiring bacterial infections. *Mycobacterium tuberculosis* (MTB) causes tuberculosis (TB) infection^[1]. More than 40% of the population in India is affected by TB. MTB that also affects other parts of the body other than the lungs is referred to as extrapulmonary tuberculosis (EPTB). In India, EPTB accounts for 20%. First-line drugs for treating MTB are Rifampicin, Isoniazid, Ethambutol, and Pyrazinamide^[2]. Among these, ethambutol has a higher affinity to cause toxic optic neuropathy, which is dose- and duration-dependent. This condition is usually reversible once the drug is discontinued^[3]. Toxic optic neuropathy (TON) is a complex, multifactorial disease that can affect people of all ages, races, locations, and socioeconomic backgrounds. Nutritional, environmental, toxicologic, and genetic factors all play a role in etiology. Toxic optic neuropathy is characterised by bilateral, often symmetrical vision loss, papillomacular bundle damage, central and cecocentralscotomas, and diminished colour vision. Early identification and treatment can help to alleviate and possibly prevent serious vision impairment^[4].

2. CASE PRESENTATION

A 59 years old female patient came to the hospital with the complaints of visual impairment inclusive of colored vision defect (dyschromatopsia) and blurred vision(scotoma). Her past medical history includes hypothyroidism and C7 body destruction with quadriplegia, D12 left paravertebral collection. For this she was planned for C7 corpectomy, decompression, debridement, stabilization C6C7D1 with biopsy. Her histopathology report showed C6-C7 soft tissue and bone tissue biopsy: Necrotizing granulomatous inflammation, possibly of

tubercular origin. Her gene xpert report revealed *Mycobacterium tuberculosis* (MTB) detected very low and rifampicin resistance not detected. So, she was started on anti-tubercular therapy (ATT) that includes a combination capsule of Rifampicin & Isoniazid (600 mg & 300 mg) 800 mg of Tab. Ethambutol, 1500 mg of Tab. Pyrazinamide and 40 mg of Tab. Pyridoxine for 9 months. Tab. Pyrazinamide- 1500 mg was taken for 2 months and Rifampicin Isoniazid and Ethambutol were to be taken for a period of 7 months. She was adherent to the ATT, by the end of the seventh month she developed with the complaints of visual impairment inclusive of colored vision defect (dyschromatopsia) and blurred vision(scotoma).So she was referred to Ophthalmologist and ophthalmologist advised for Optical Coherence Tomography (OCT)(Fig. 1). From her OCT report , found that she is having mild cataract and cecocentralscotoma. So Tab. Ethambutol- 800 mg was withdrawn from the therapy. In the following hospital visit her condition was improved gradually.

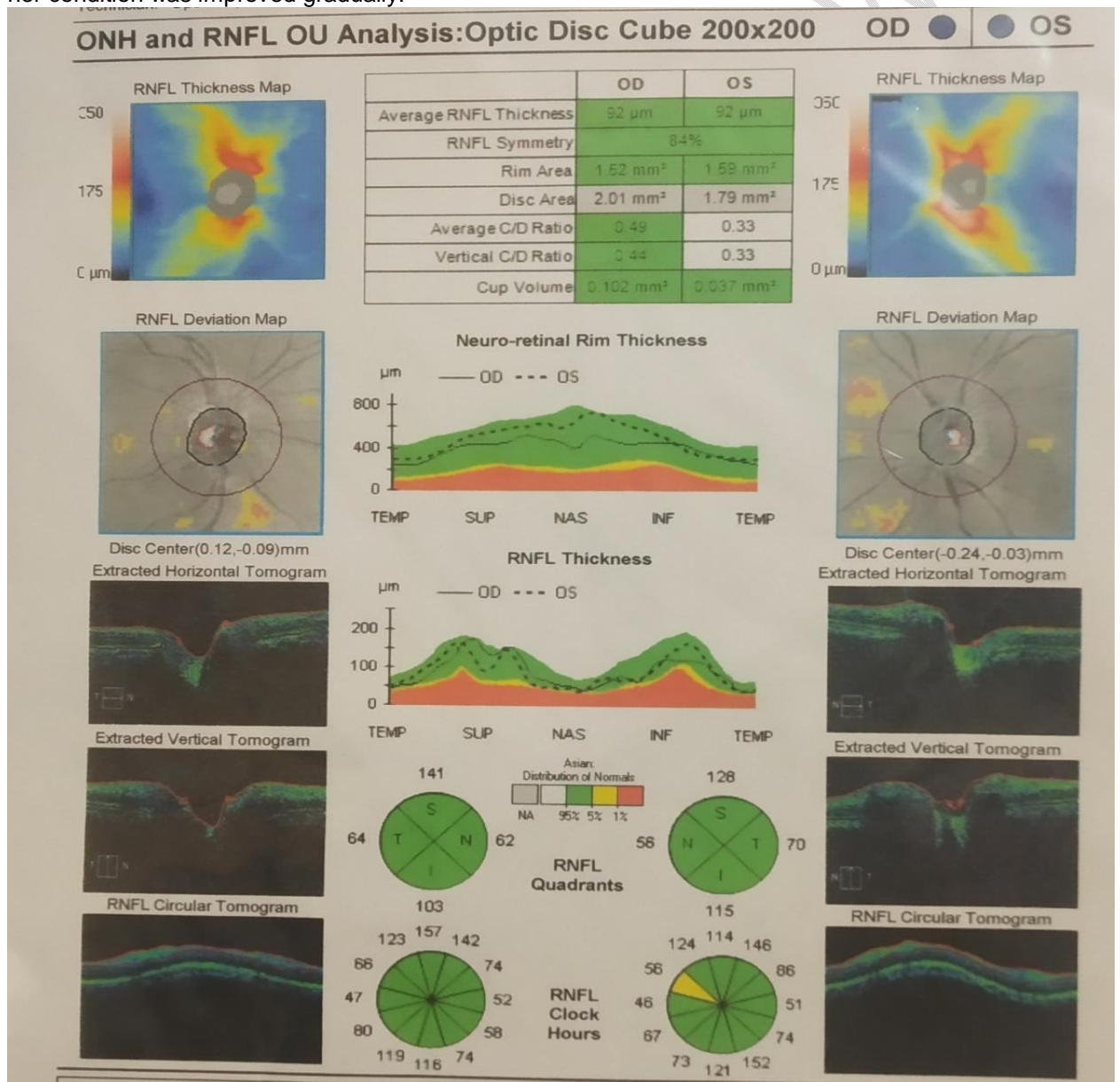


Fig:1 Optical Coherence Tomography

3. DISCUSSION

While prescribing ATT drugs all physicians explain to the patient and attender about the treatment course and the possible side effects of the drugs. The doctor always enquire the patient about the possible side effects which they can experience after starting the therapy in the following visits, and was monitored by doing Liver function tests (LFT), Renal function tests (RFT) and Complete blood count (CBC) which helps to recognize the events at the earlier stage. This early detection helps to prevent the worsening of the condition and able to withdraw the drug as early as possible.

In recent studies, it has been reported that 1-2% of patients receiving ethambutol may develop EON. Although the precise pathophysiological mechanism behind EON is still unknown, it may be owing to reduced lysosomal activation as a result of zinc chelation or by impaired oxidative phosphorylation subsequent to decreased available copper in human mitochondria. Studies have shown that the adverse effect of EON is dose- and time-dependent.^[5]

As a matter of evidence same findings were reported in the following case reports :

Monika et.al EON does not have a predictable onset time. This can occur from a few days to two years after the start of drug producing, ocular symptoms. The majority of the patients shared the usual cecocentral scotomas seen by this patient. In the initial period of presentation, the disc will enlarge and become hyperemic during fundus examination. Because of the early diagnosis, it is possible to prevent the complications.^[6]

Wen-Yan Sheng et.al Ocular examination indicates impaired colour vision and a bilateral, painless, often symmetric loss of visual acuity in more than 60% of EON patients. It initially starts with one eye and progresses to affect both the eyes. Green and red are frequently the colours for which colour vision loss is recorded, while blue-yellow colour alterations can also happen. The optic disc may initially seem normal, but as the condition worsens, it finally turns into a pale optic disc. OCT analyses revealed decreased thickness of ganglionic cell inner plexiform layer (GCIPL) and the retinal nerve fiber layer RNFL as well.^[7]

Sagnik Sen et.al OCT is used to measure the thickness of the retinal fibre and ganglion cell layers in order to search for early signs of degeneration and alterations.^[8]

4. CONCLUSION

Ethambutol induced toxic optic neuropathy is rare but not unusual. It is reversible when the drug is withdrawn. The patient should not neglect even the small changes that occurs after the treatment is initiated. The process of improving the quality of life is always a two-way between the patient and the medical practitioner. From this case report we conclude that early detection of an adverse effect after taking ATT drugs (Ethambutol) is reversible, if patient is properly counselled at every hospital visit.

CONSENT

AS PER INTERNATIONAL STANDARD OR UNIVERSITY STANDARD, PATIENT(S) WRITTEN CONSENT HAS BEEN COLLECTED AND PRESERVED BY THE AUTHOR(S).

ETHICAL APPROVAL:

AS PER INTERNATIONAL STANDARD OR UNIVERSITY STANDARD WRITTEN ETHICAL APPROVAL HAS BEEN COLLECTED AND PRESERVED BY THE AUTHOR(S).

REFERENCES

1. More than 40% of the population in India carry Tuberculosis infection in their body but only 10% get TB disease: Chief Medical Officer, National Tuberculosis Institute [Internet]. Gov.in. [cited 2022 Nov 18]. Available from: <https://pib.gov.in/PressReleasePage.aspx?PRID=1808092>
2. Shamseeda, Jayasree. Epidemiological profile of extrapulmonary tuberculosis and its association with diabetes in tertiary care center in Northern Kerala. *Int J Community Med Public Health* [Internet]. 2022 [cited 2022 Nov 18];9(6):2590. Available from: <https://www.ijcmph.com/index.php/ijcmph/article/view/9762/6005>
3. Song W, Si S. The rare ethambutol-induced optic neuropathy: A case-report and literature review. *Medicine (Baltimore)* [Internet]. 2017 [cited 2022 Nov 18];96(2):e5889. Available from: <http://dx.doi.org/10.1097/md.0000000000005889>
5. Kesler A, Pianka P. Toxic optic neuropathy. *CurrNeurolNeurosci Rep* [Internet]. 2003 [cited 2022 Nov 18];3(5):410–4. Available from: <https://pubmed.ncbi.nlm.nih.gov/12914684/>
6. Sheng W-Y, Wu S-Q, Su L-Y, Zhu L-W. Ethambutol-induced optic neuropathy with rare bilateral asymmetry onset: A case report. *World J Clin Cases* [Internet]. 2022 [cited 2022 Nov 18];10(2):663–70. Available from: <http://dx.doi.org/10.12998/wjcc.v10.i2.663>
7. Monika, Kumar J, Rathi M et.al. Ethambutol induced optic neuropathy: a rare case report. *International Journal of Research and Review*. 2020; 7(2): 13-17.
8. Sheng WY, Wu SQ, Su LY, Zhu LW. Ethambutol-induced optic neuropathy with rare bilateral asymmetry onset: A case report. *World J Clin Cases* 2022; 10(2): 663-670 [PMID: 35097092 DOI: 10.12998/wjcc.v10.i2.663]
9. Sen S, Mandal S, Banerjee M, Gk R, Saxena A, Aalok SP, et al. Ethambutol-induced optic neuropathy: Functional and structural changes in the retina and optic nerve. *SeminOphthalmol* [Internet]. 2022;37(6):730–9. Available from: <http://dx.doi.org/10.1080/08820538.2022.2085517>

ABBREVIATIONS

ATT – Anti-Tubercular Therapy
EON – Ethambutol- induced Optic Neuropathy
EPTB- Extrapulmonary Tuberculosis
GCIPL- Ganglionic Cell Inner Plexiform Layer
MTB- Mycobacterium Tuberculosis
RNFL- Retinal Nerve Fiber Layer
TB- Tuberculosis
TON- Toxic Optic Neuropathy