

Case study

A CASE OF SUPRACHOROIDDAL HEMORRHAGE DURING CATARACT SURGERY- A RARE COMPLICATION

ABSTRACT

A 58 year old female was planned for **right eye small incision cataract surgery** with corrected distance visual acuities of 6/18 and an intraocular pressure of 16mmHg in both eyes. However, during surgery, iris prolapse was noted, reposition attempted but not achieved due to large wound and deep scleral entry. Posterior chamber intraocular lens implantation was attempted when anterior chamber shallowing with intraocular pressure rise was noted. Persistent positive pressure was noted with vitreous in the wound. Posterior chamber intraocular lens was removed immediately. Before vitrectomy could be attempted, a dark mound was noted superonasally suspicious of suprachoroidal hemorrhage. Immediately, intravenous mannitol injection was given to lower the intraocular pressure and the wound was closed rapidly with Ethilon 10-0 sutures and the eye was left aphakic. The postoperative treatment regimen of intravenous dexamethasone 6mg three times a day, topical prednisolone hourly, moxifloxacin eye drops four times a day, timolol two times a day, brimonidine with brinzolamide eye drops two times a day, homide at night, oral acetazolamide two times a day and oral prednisolone 40 mg was commenced. 20 days postoperative USG B scan showed suprachoroidal hemorrhage (kissing choroids) with suspected choroidal and retinal detachment. 40 days postoperatively, choroidal drainage with pars plana vitrectomy was planned for the patient. Since there was an improvement in the vision and the suprachoroidal hemorrhage had reduced, the patient was continued on oral steroids and other topical medications as before. This study shows that with rapid diagnosis and intraoperative management and accurate postoperative intervention, it is possible to achieve good visual acuity after **suprachoroidal hemorrhage**.

KEYWORDS

Suprachoroidal hemorrhage, vitrectomy, intraocular pressure, steroids

INTRODUCTION

“Cataract surgery is the most common ophthalmic surgery performed throughout the world”.^[1] Suprachoroidal hemorrhage is one of the most frightening and devastating complications of ophthalmic surgeries. It occurs as a result of rapid blood accumulation in the suprachoroidal space due to increased tension and rupture of the posterior ciliary arteries or vortex veins”^[2]. “An intraoperative SCH is defined as a sudden haemorrhagic swelling of the choroid which develops at time of intraocular surgery and is associated with expulsion of some or all of the intraocular contents. Intraoperative SCH is thought to be a result of acute hypotonia or fluctuation of the IOP”^[3]. “Risk factors for development of SCH include glaucoma, ocular comorbidity (specifically uveitis, past trauma), previous intraocular procedure, axial length, intraocular pressure (IOP) prior to cataract surgery and preoperative visual acuity”.^[4]

SCH presents with severe eye pain, marked decrease in visual acuity, shallow anterior chamber, and severe increase in intraocular pressure (IOP) [5]. The more recent national cataract surgery survey estimated the incidence of SCH to be 0.1%. [6] In this study, we present a case of intraoperative SCH that can be managed appropriately and a satisfactory good visual acuity can be achieved after proper intervention.

CASE REPORT

A 58 year old female patient was admitted with decreased vision in both eyes. Corrected distance visual acuity was 6/18 in both eyes. Her slit-lamp examination, IOP measurements, fundus examination and optical coherence tomography findings were within normal limits. She had Grade 3 nuclear sclerosis with cortical 1 and thick central posterior subcapsular cataract in both eyes. The patient had no comorbidities. Right eye small incision cataract surgery with posterior intraocular lens implantation was planned for the patient.

However, during surgery, iris prolapse occurred, reposition attempted but not achieved due to large wound and deep scleral entry. Posterior chamber intraocular lens implantation was attempted when anterior chamber shallowing with intraocular pressure rise was noted. Persistent positive pressure was noted with vitreous in the wound. Posterior chamber intraocular lens was removed immediately and vitrectomy was planned. Before vitrectomy could be attempted, a dark mound was noted superonasally suspicious of suprachoroidal hemorrhage. Immediately intravenous mannitol injection was given to lower the intraocular pressure and the wound was closed rapidly with Ethilon 10-0 sutures. Following suturing of the incision, the eye was left aphakic.

The postoperative treatment regimen of intravenous dexamethasone 6mg three times a day, topical prednisolone hourly, moxifloxacin eye drops four times a day, timolol two times a day, brimonidine with brinzolamide eye drops two times a day, homide at night, oral acetazolamide two times a day and oral prednisolone 40 mg was started.

The patient's vision was limited to hand movements close to face, with perception of light and projection of rays accurate.

20 days postoperative USG B scan showed suprachoroidal hemorrhage (kissing choroids) with suspected choroidal and retinal detachment (Figure 1).

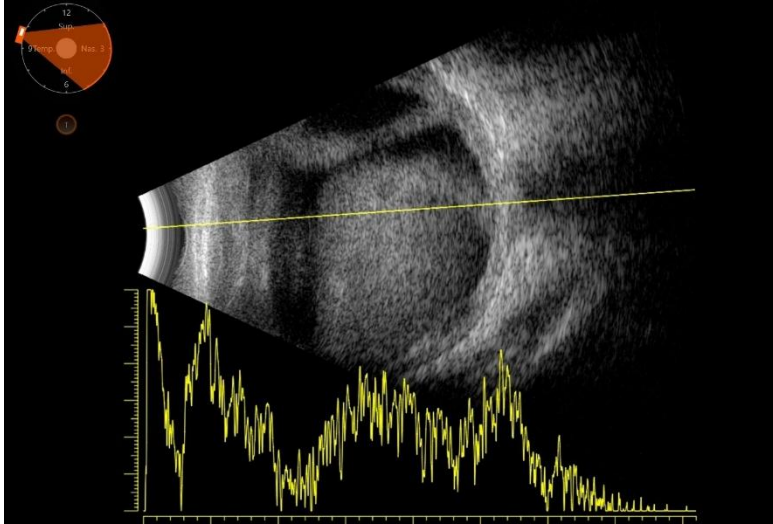


Figure 1- B mode ultrasound showing suprachoroidal hemorrhage with “kissing choroids” at postoperative 20th day

40 days postoperatively, choroidal drainage with pars plana vitrectomy was planned for the patient. Since there was an improvement in the vision and the suprachoroidal hemorrhage had reduced (Figure 2), the patient was continued on oral steroids and other topical medications as before. Patient’s vision in the right eye improved to 6/24 with 10 dioptre lens after appropriate postoperative management.

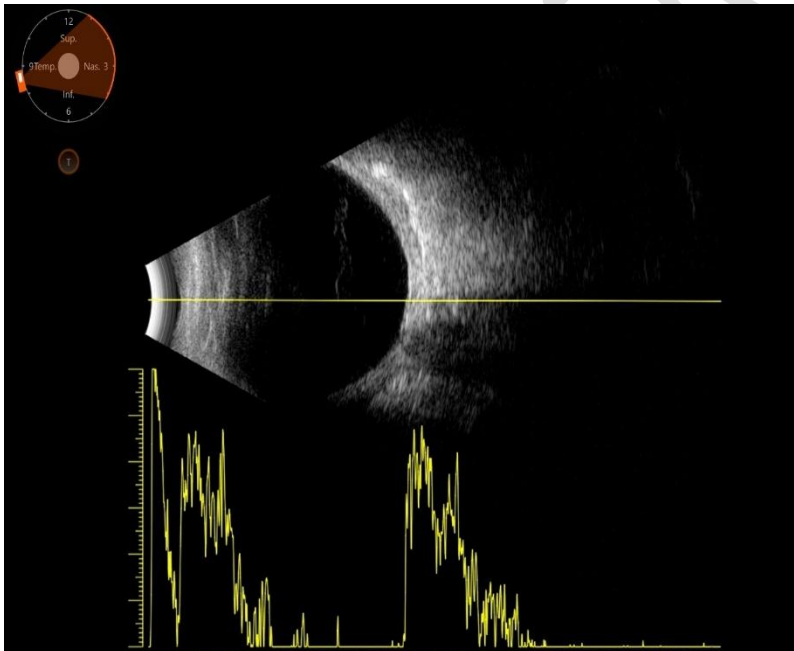


Figure 2 – B mode ultrasound showing resolving suprachoroidal hemorrhage at postoperative 40th day

DISCUSSION

“SCH is characterized by a rapid and massive accumulation of blood in the suprachoroidal space”^[7]. “The incidence of SCH after cataract surgery ranges from 0.03% to 0.13%”^[2,8]. “It has been shown that the use of smaller incisions or scleral tunnels is more beneficial for SCH control”^[9].

“Findings indicating the development of SCH during surgery are shallow anterior chamber (78%), increased IOP (59.6%), posterior capsule stretching (39.4%), loss of red reflex (36.7%), and prolapse of intraocular structures (iris, lens, vitreous, and retina). In these cases, early diagnosis and rapid suturing of incisions without vitreous and iris prolapse are important to achieve optimal visual acuity. The osmotic effects of SCH should be controlled by giving intravenous mannitol”^[10]. “The drainage process is recommended to be performed 10–14 days after SCH, to allow blood liquefaction to occur”^[11].

Klinika Oczna, reported “a case of massive suprachoroidal hemorrhage during cataract surgery and the main reason of expulsive hemorrhage development was a Valsalva effect, caused by unexpected cough during surgery. In a Valsalva maneuver, a sudden increase in venous pressure may lead to vessel-wall rupture, by an apparently excessive pressure gradient across the vessel wall”^[12].

In a study by Seher Koksaldi, C. Utine, a patient developed massive suprachoroidal hemorrhage during cataract surgery where the intraocular pressure was lowered with intravenous mannitol and the incision was sutured. Transscleral SCH evacuation with limited pars plana vitrectomy was performed in the postoperative third week and the visual acuity improved slowly.^[13]

Fei et al, reported “a patient with massive SCH during cataract surgery who underwent an early successful tissue plasminogen activator assisted vitrectomy and attained a good visual outcome”^[14].

A study by M G Speaker, showed that “the incidence of SCH was 0.19% overall, 0.16% for lens-related procedures, 0.15% for glaucoma surgery, 0.41% for retinal and vitreous procedures, and 0.56% for keratoplasty”^[15].

CONCLUSION

In this case, SCH occurred due to increased tension and rupture of choroidal vessels as a result of the sudden fluctuation in IOP during cataract surgery. Although it is one of the serious and sight-threatening complications of cataract surgery, fortunately, its incidence is low. With rapid diagnosis and intraoperative management and accurate postoperative intervention, good visual acuity was achieved after SCH.

Consent

As per international standard or university standard, patient(s) written consent has been collected and preserved by the author(s).

Ethical Approval:

As per international standard or university standard written ethical approval has been collected and preserved by the author(s).

REFERENCES

1. Turner EL, Sweeting MJ, Lindfield RJ, Deangelis D. Incidence estimation using a single cross-sectional age-specific prevalence survey with differential mortality. *Stat Med*. 2014 Feb 10;33(3):422-35
2. Stein JD, Grossman DS, Mundy KM, Sugar A, Sloan FA. Severe adverse events after cataract surgery among medicare beneficiaries. *Ophthalmology*. 2011;118:1716–23
3. Speaker MG, Guerriero PN, Met JA, Coad CT, Berger A, Marmor M. A case-control study of risk factors for intraoperative suprachoroidal expulsive hemorrhage. *Ophthalmology*. 1991;98:202–9
4. Ling R, Kamalarajah S, Cole M, et al. Suprachoroidal haemorrhage complicating cataract surgery in the UK: a case control study of risk factors *British Journal of Ophthalmology* 2004;88:474-477.
5. Tuli SS, WuDunn D, Ciulla TA, Cantor LB. Delayed suprachoroidal hemorrhage after glaucoma filtration procedures. *Ophthalmology*. 2001;108:1808–11
6. Desai P, Minassian DC, Reidy A. National cataract surgery survey 1997–8: a report of the results of the clinical outcomes. *Br J Ophthalmol* 1999;83:1336–1340
7. Chu TG, Green RL. Suprachoroidal hemorrhage. *Surv Ophthalmol*. 1999;43:471–86.
8. Song W, Zhang Y, Chen H, Du C. Delayed suprachoroidal hemorrhage after cataract surgery: A case report and brief review of literature. *Medicine (Baltimore)* 2018;97:e8697
9. Davison JA. Acute intraoperative suprachoroidal hemorrhage in extracapsular cataract surgery. *J Cataract Refract Surg*. 1986;12:606–22
10. Savastano A, Rizzo S, Savastano MC, Piccirillo V, Forte R, Sbordone S, et al. Choroidal effusion and suprachoroidal hemorrhage during phacoemulsification: intraoperative management to prevent expulsive hemorrhage. *Eur J Ophthalmol*. 2016;26:338–41
11. Chu TG, Cano MR, Green RL, Liggett PE, Lean JS. Massive suprachoroidal hemorrhage with central retinal apposition. A clinical and echographic study. *Arch Ophthalmol*. 1991;109:1575–81.
12. **Klinika Oczna**, Massive suprachoroidal hemorrhage during cataract surgery. February 2022,104(5-6):406-10
13. Koksaldi S, Utine CA, Kayabasi M. Management of Suprachoroidal Hemorrhage during Cataract Surgery: A Case Report. *Beyoglu Eye J*. 2022 Feb 18;7(1):66-70.

14. Fei P, Jin HY, Zhang Q, Li X, Zhao PQ. Tissue plasminogen activator-assisted vitrectomy in the early treatment of acute massive suprachoroidal hemorrhage complicating cataract surgery. *Int J Ophthalmol.* 2018;11:170–1

15. Speaker MG, Guerriero PN, Met JA, Coad CT, Berger A, Marmor M. A case-control study of risk factors for intraoperative suprachoroidal expulsive hemorrhage. *Ophthalmology.* 1991 Feb;98(2):202-9

UNDER PEER REVIEW