

Case study

HEPATIC SUBCAPSULAR HAEMATOMA—A FATAL COMPLICATION OF ERCP

Abstract

Endoscopic Retrograde cholangiopancreatography (ERCP) is one of the most commonly performed procedures in Gastroenterology. ERCP has the highest rate of complications, some of which can be life threatening like duodenal perforation and hepatic subcapsular hematoma (HSH). Here, we report a case of Hepatic subcapsular Hematoma in an elderly patient with choledocholithiasis and cholangitis.

Introduction

Endoscopic Retrograde cholangiopancreatography (ERCP) is one of the most commonly performed minimally invasive Pancreaticobiliary procedure in Gastroenterology. Hepatic subcapsular hematoma is an uncommon complication of ERCP. Since 2000, when the first case report of HSH was described¹, world literature has described more than 60 cases. Here, we report a case of Hepatic subcapsular Hematoma in an elderly patient with choledocholithiasis and cholangitis.

CASE REPORT---A 76 years old nondiabetic, hypertensive gentleman was admitted with pain abdomen for 1 month and was treated elsewhere with analgesics and antibiotics. He had a history of ECRP for choledocholithiasis followed by laparoscopic cholecystectomy 15 years back. He was evaluated and diagnosed as recurrent choledocholithiasis. He gave history of intermittent fever and pain abdomen since and he delayed his hospital admission due to the COVID-19 pandemic. He

underwent ERCP a day after admission. The procedure was uneventful. CBD was selectively cannulated followed by sphincteroplasty and stone extraction with balloon sweep. Lot of pus was drained and a 10fr double pigtail plastic stent was deployed. He was shifted to the ward in a stable condition.

After around 3 hours of the procedure he complained of pain in the right upper quadrant and giddiness. On examination he had tachycardia and hypotension (BP=80/60 mm of Hg). Bolus IV fluids were infused and blood Pressure improved. He did not stabilize and had hypotension again. He was shifted to ICU and started on vasopressors, initially noradrenaline followed by vasopressin. Urine output decreased and ABG showed metabolic acidosis with high lactate (>15). Hematocrit in ABG was 24, which meant a significant drop from baseline. He maintained blood Pressure with high dose of inotropes. USG screening of abdomen showed heterogenous collection in the sub diaphragmatic space. There was no overt GI bleed. Ryle's tube aspiration was clear.

A plain CT abdomen showed a hepatic subcapsular hematoma measuring 11cm x 9cm compressing the liver parenchyma. There was no free air in the abdomen which ruled out perforation. Meanwhile 2 units of packed cells were transfused and an IR consultation was sought. Angiographic CT abdomen showed hepatic subcapsular hematoma of size 13cm x 10 cm and ongoing active bleed from multiple sub segmental hepatic arteries across segments 6, 8 and 4. The portal vein was patent. He was taken up for an emergency embolization. Procedure was completed uneventfully with super selective coil embolization of three segmental arteries. There was gross derangement of liver enzymes with coagulopathy. Blood products (FFP) were transfused. He underwent hemodialysis as there was no urine output, however he remained hemodynamically stable and inotropes could be stopped. The following day, he had a further significant hemoglobin drop. Given the possibility of a watering can liver due to multiple sub capsular tears, he underwent a second session of embolization, this time with lobar injection of 300-500um microspheres. Hemoglobin was stable for the

next 2 days. His liver function improved but he had no urine output and developed leukocytosis. Antibiotics were augmented as per the culture reports and hospital protocol. On 7th day of hospitalization he had significant hemoglobin drop and profound leukocytosis and metabolic acidosis. He was hemodynamically unstable, hemodialysis could not be done and he succumbed on 7th post ERCP day.

DISCUSSION

Therapeutic ERCP is a commonly performed endoscopic procedure with complication rate of 2.5 -- 8% and mortality rate of 0.5 to 1%.^{2,3}

Hepatic subcapsular hematoma (HSH) is a rare complication of ERCP with around 60 cases reported in literature.⁴ Its pathology is poorly understood and can be potentially life threatening.

The etiology of these hematomas is unclear and two hypotheses have been raised. The first suggests that the subcapsular bleed is secondary to the traction force applied to the CBD during stone extraction by the balloon which might cause rupture of biliary vessels and branches under the capsule and bleed subsequently.^{5,6} The second hypothesis suggests that the guidewire used to cannulate CBD might perforate the CBD and cause hepatic parenchymal injury and cause rupture of intrahepatic vessels which collects under the Glisson's capsule.⁷⁻¹² The high rate of infection in the hematoma can be explained by the use of guide wire and other ERCP accessories.¹³ In Digital subtraction angiography (DSA) this has been described as "watering-can" appearance due to contrast extravasation from multiple torn surface vessels secondary to the stripped off liver capsule by the expanding subcapsular hematoma. The stripping of the capsule from the underlying liver results in tearing of adjacent vessels that further increases bleeding.¹⁴

Clinical presentation of HSH are varied including pain abdomen, anemia, fever, shoulder pain and signs of hypotension. The diagnostic

method of choice is CT angiography. Treatment should be individualized on a case to case basis. Antibiotic therapy is always recommended considering the high rate of associated infection. Surgical treatment should be considered for hemodynamically unstable patients. Angiography with selective embolization with particles to control bleeding is an effective modality of treatment in hemodynamically stable patients.

References

1. Ortega Deballon P, Fernández Lobato R, García Septern J, et al. Liver hematoma following ERCP. *Surg Endosc.* 2000;14:767.
2. Hart R, Classen M. Complications of diagnostic gastrointestinal endoscopy. *Endoscopy.* 1990;22:229–233.
3. Fei BY, Li CH. Subcapsular hepatic haematoma after endoscopic retrograde cholangiopancrea-tography: an unusual case. *World J Gastroenterol.* 2013;19:1502–1504.
4. Luca Giovanni Antonio Pivetta. Hepatic subcapsular hematoma post-ERCP: Case report and literature review . *International Journal of Surgery Case Reports* 72 (2020) 219–228
5. F. Orellana, J. Irarrazaval, J. Galindo, P. Balbontin, L. Manríquez, R. Plass, R. Araya, H. Ríos, R. Sáenz, Subcapsular hepatic hematoma post ERCP: a rare or an underdiagnosed complication? *Endoscopy* 44 (Suppl 2) (2012), UCTN: E108-E109.
6. J.S.Baudet,X.Arguín arena,I.Redondo,etal.,Subcapsularhepatichematoma: an uncommon complication of endoscopic retrograde cholangiopancreatography, *Gastroenterol. Hepatol.* 34 (2) (2011) 79–82.
7. K.D. Chi, I. Waxman, Subcapsular hepatic hematoma after guide wire injury during ERCP, *Endoscopy* 36 (2004) 1019–1021.
8. T.L. Horn, L.R. Pena, Subcapsular hepatic hematoma after ERCP: case report and review, *Gastrointest. Endosc.* 59 (2004) 594–596.

9. S.P. Lynch, J.A. Evans, Difficult biliary cannulation, *Curr. Gastroenterol. Rep.* 12 (2010) 135–140.
10. A. Cárdenas, G. Crespo, D. Balderramo, J.P. Bordas, O. Sendino, J. Llach, Subcapsular liver hematoma after Endoscopic Retrograde Cholangiopancreatography in a liver transplant recipient, *Ann. Hepatol.* 7 (2008) 386–388.
11. K.S. McArthur, P.R. Mills, Subcapsular hepatic hematoma after ERCP, *Gastrointest. Endosc.* 67 (2008) 379–380.
12. C.S. Bhati, N. Inston, S.J. Wigmore, Subcapsular intrahepatic hematoma: an unusual complication of ERCP, *Endoscopy* 39 (1) (2007) E150.
13. M. Zizzo, A. Lanaia, I. Barbieri, C. Zaghi, S. Bonilauri, Subcapsular hepatic hematoma after endoscopic retrograde cholangiopancreatography: a case report and review of literature, *Medicine (Baltimore)* 94 (2015) e1041.
14. S Garge , Hepatic Subcapsular Haemorrhage: Watering-can Appearance. *Hong Kong J Radiol.* 2016;19:141-4

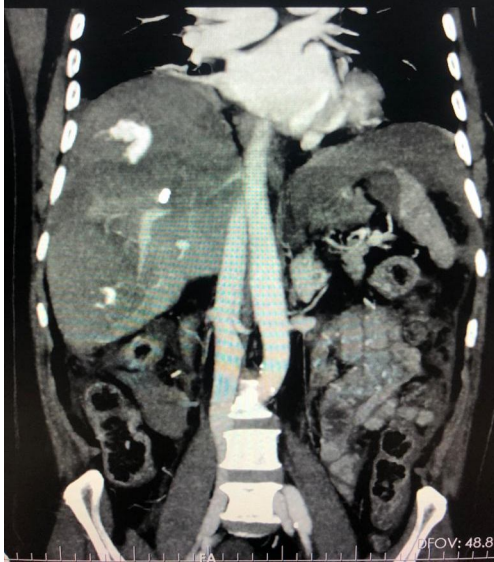

FIG 1 A----

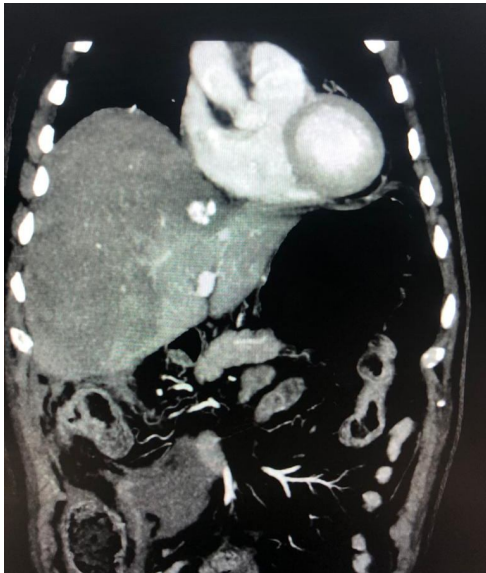

FIG 1 B

Fig 1: Coronal CT reformat of an arterial phase acquisition of the abdomen.. This shows a hypodense hematoma confined within the liver capsule and compressing the normal liver parenchyma. Active arterial bleeding is noted as a dense blush in segment 4 (A) and segments 8 and 6 (Fig 1B)

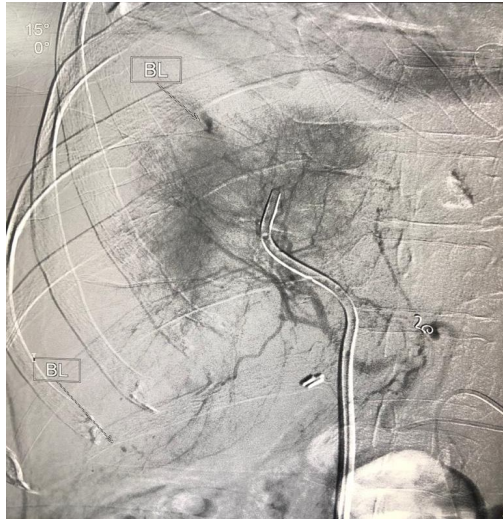

FIG 2 A

Fig 2: Late angiographic phase of a digital subtraction angiogram from the hepatic artery confirms the sub capsular active bleeding from the sub segmental arteries (arrows). These were subsequently embolized.

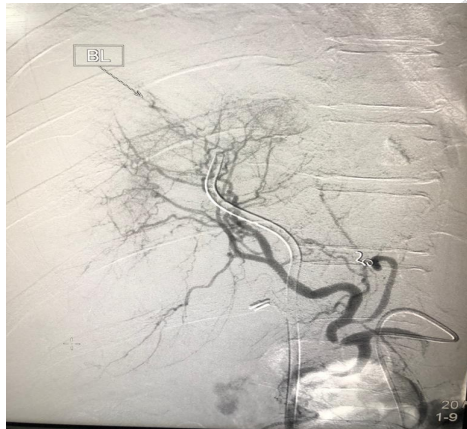


FIG 2 B

UNDER PEER REVIEW